

In vitro fertilization outcomes in VACTERL association (vertebral defects, anal atresia, cardiac defects, tracheoesophageal fistula, renal anomalies and limb anomalies): report of 2 cases

Lindsey LePoidevin, M.D.,^a Timothy Dunn, M.D.,^b Sara E. Arian, M.D., M.S.C.I.,^b Khalied Kaskar, Ph.D.,^b and Amy Schutt, M.D.^b

^a Department of Obstetrics and Gynecology, Baylor College of Medicine, Houston, Texas; and ^b Department of Reproductive Endocrinology and Infertility, Baylor College of Medicine, Houston, Texas

Objective: To report 2 cases of women with vertebral defects, anal atresia, cardiac defects, tracheoesophageal fistula, renal anomalies, and/or limb anomalies (VACTERL association) and the outcomes of their in vitro fertilization (IVF) cycles.

Design: A case report. We obtained informed consent from both the patients for this case report.

Setting: Outpatient clinic at an academic hospital.

Patient(s): Patient 1 was a 23-year-old woman with scoliosis, tethered spinal cord, tracheoesophageal fistula, duodenal atresia, and a common cloaca at birth. Patient 2 was a 36-year-old woman with dextrocardia, congenital heart disease, scoliosis, and an imperforate anus at birth.

Intervention(s): Both the patients underwent IVF.

Main Outcome Measure(s): Oocyte yield, oocyte quality, and number of embryos.

Result(s): Patient 1 underwent 1 IVF cycle, with 16 oocytes retrieved, of which 6 were mature. However, during intracytoplasmic sperm injection, the oocytes were noted to be extremely fragile and degenerated immediately after sperm injection. No oocyte was fertilized. Patient 2 underwent 3 IVF cycles, and 2 oocyte retrievals, with a total of 7 oocytes under cryopreservation.

Conclusion(s): Both the patients' cases presented challenges due to aberrations in pelvic anatomy and poor IVF outcomes. There is a paucity of data regarding fertility outcomes and, specifically, oocyte quality in patients with vertebral defects, anal atresia, cardiac defects, tracheoesophageal fistula, renal anomalies, and/or limb anomalies association. Their care requires a multidisciplinary assessment, an individualized approach, and continued investigation of their IVF and fertility outcomes. (Fertil Steril Rep[®] 2022;3:280–4. ©2022 by American Society for Reproductive Medicine.)

Key Words: VACTERL, fertility, IVF, müllerian, egg quality, oocyte

Discuss: You can discuss this article with its authors and other readers at <https://www.fertstertdialog.com/posts/xfre-d-22-00066>

INTRODUCTION

Vertebral defects, anal atresia, cardiac defects, tracheoesophageal fistula, renal anomalies, and/or limb anomalies

(VACTERL) association is a constellation of anomalies that tend to co-occur. The association occurs when there is presence of at least 3 of these

congenital malformations. Its incidence is approximately 1 in 10,000 to 1 in 40,000 among live-born infants, and if adequate surgical correction is possible, these patients generally have a positive prognosis (1). The pathogenesis of the association is unknown, with likely heterogeneous etiologies, whether environmental, genetic, or spurious factors are possibly contributing (1, 2). Given the association of multiple affected anatomic systems, some postulate that the association is

Received April 6, 2022; revised and accepted June 29, 2022.

L.L. has nothing to disclose. T.D. has nothing to disclose. S.E.A. has nothing to disclose. K.K. has nothing to disclose. A.S. has nothing to disclose.

Correspondence: Lindsey LePoidevin, M.D., Department of Obstetrics and Gynecology, Baylor College of Medicine, 1 Baylor Plaza, Houston, Texas 77030 (E-mail: lindseylepoidevin@gmail.com).

Fertil Steril Rep[®] Vol. 3, No. 3, September 2022 2666-3341

© 2022 The Authors. Published by Elsevier Inc. on behalf of American Society for Reproductive Medicine. This is an open access article under the CC BY-NC-ND license (<http://creativecommons.org/licenses/by-nc-nd/4.0/>).

<https://doi.org/10.1016/j.xfre.2022.06.006>

a form of a developmental field defect that occurs early during embryonic development (1). Multiple risk factors have been believed to be possibly involved, such as maternal diabetes, maternal infertility or hormonal therapies, or some medications or environmental exposures such as lead (1). However, many of the risk factors considered are speculative, given the thought that there is a multifactorial etiology driving this uncommon association.

In patients with VACTERL association, given the close association of the genitourinary and gastrointestinal systems with reproductive anatomy, there appears to be a high risk of gynecologic abnormalities and likely a high risk of subfertility in women. For example, up to 29% of patients with renal anomalies have concomitant müllerian anomalies due to the intimate development of these systems during organogenesis (3, 4). When considering men with VACTERL association, minimal data exist regarding their fertility outcomes; however, some data have shown comorbid genitourinary abnormalities that could affect male fertility, such as cryptorchidism, micropenis, hypospadias, or as 1 case showed, testicular biopsy-confirmed obstructive azoospermia (5, 6).

With advances in neonatal, pediatric, and adult care, patients with VACTERL association can present to fertility clinics to explore reproductive options or with desires for fertility preservation. Fertility outcomes and obstetric data in these patients are limited, and there is lack of guiding literature on advanced reproductive technology, such as in vitro fertilization (IVF). We present 2 cases of patients with VACTERL association and their IVF outcomes at our clinic.

CASE REPORT

Case 1

At birth, the patient was diagnosed with multiple anomalies, including scoliosis and a tethered cord, tracheaesophageal fistula, duodenal atresia, and a common cloaca, all consistent with VACTERL association. Her surgical history included a posterior sagittal anorectal vaginoplasty, which was complicated by a urogenital sinus requiring repair. Her tethered cord repair resulted in neurogenic bladder symptoms, and therefore, she underwent an appendicovesicostomy and right ureteral reimplantation. Because of stenosis several years later, she underwent a cutaneous urinary diversion through an ileovesicostomy. Lastly, because of vaginal introitus stenosis, she required a vaginoplasty with buccal graft placement. Genetic evaluation did not reveal any genetic etiology for her clinical syndrome. She had presented to several outside clinics to discuss fertility goals, where she reported regular menstrual cycles and timed-intercourse guided by ovulatory predictor kits for over 1 year without successful conception before presenting to our clinic.

For her fertility workup, a hysterosalpingogram was attempted twice at an outside institution, and both attempts were aborted because of anatomic difficulties. Although the hysterosalpingograms were not completed, there was concern for significant tubal adhesive disease or tubal factor, given her extensive surgical history and variations in pelvic anatomy. Her partner's semen analysis revealed oligospermia, without a clear etiology. During her initial

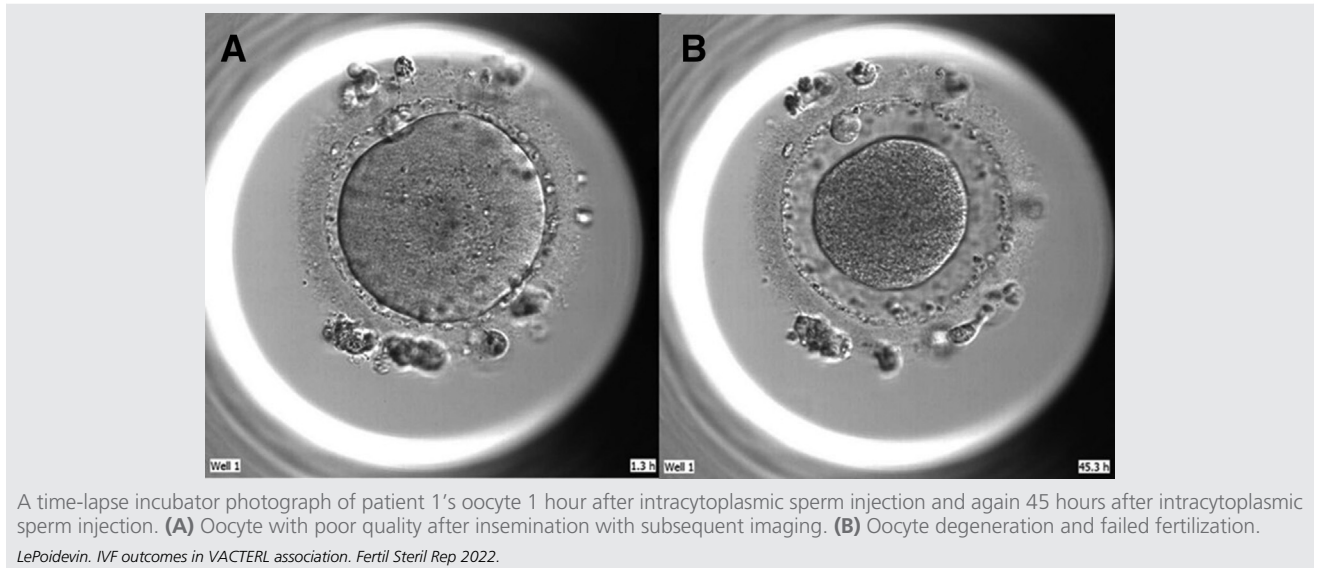
evaluation at our clinic at the age of 23 years, the cervix could not be visualized during a speculum examination and was additionally nonpalpable in a bimanual examination because of altered vaginal anatomy and length. Ultrasound revealed a normal uterus but with sharp deviation to the right hemipelvis, raising concern for intrapelvic adhesive disease. The right ovary was noted posterior to the uterus, and it had an antral follicle count of 8. The left ovary could not be visualized. Laboratory workup revealed an anti-müllerian hormone level of 2.84 ng/mL (the assay range is 0.401–16.015 ng/mL in women aged 18–29 years). The semen analysis was repeated after the partner was evaluated by an outside urologist, who started him on clomiphene citrate, with values of 13.8×10^6 total motile sperm, 46% motility, and mildly abnormal sperm morphology (approximately 2% had normal forms).

Discussions in the reproductive endocrinology and infertility (REI) division at our institution revolved around concerns pertaining to the inability to safely access the pelvis in the event of a medical emergency, such as missed abortion, ectopic pregnancy, or the need for cesarean section. Additionally, nonvisualization of the cervix eliminated even the theoretical possibility of offering intrauterine insemination or IVF as treatment options for male factor infertility. The patient had a prior preconception visit to an outside maternal-fetal medicine (MFM) specialist, who had recommended, at minimum, a planned cesarean delivery under general anesthesia with a multidisciplinary team, given her prior reconstructions, should she become pregnant. Because of the concerns listed previously, the consensus among the REI faculty was to recommend IVF using autologous oocytes and a gestational carrier to minimize risk to the patient. The couple agreed with this plan and proceeded with IVF.

She was started on day 2 of the cycle and a gonadotropin-releasing hormone antagonist protocol with plans to use maximum gonadotropin dosing, given the concern that only 1 ovary would be accessible for retrieval. Furthermore, she was started on 450 IU of follitropin α and 150 IU of menotropins. The antagonist was started on day 7 of gonadotropins, and her peak estradiol level was 2,376 pg/mL and progesterone level was 1.2 ng/mL. During her stimulation, both ovaries were accessible using transvaginal ultrasound when significant abdominal pressure was used to further maneuver the left ovary into the pelvis. On stimulation day 14, she had one 20-mm, three 19-mm, three 18-mm, and thirteen other 14–17-mm follicles. She was triggered that evening with 10,000 units of human chorionic gonadotropin (HCG).

She underwent an uncomplicated transvaginal oocyte retrieval, with 16 oocytes retrieved, minimal blood loss, and no complications. On the day of the retrieval, the semen analysis showed 20.4×10^6 total motile sperm with 76% motility and normal forward progression. Of the 16 oocytes retrieved, only 6 were in metaphase II at the time of insemination. Of the immature oocytes, 2 were germinal vesicles (GVs) and 8 spontaneously degenerated. When intracytoplasmic sperm injection was attempted, the oocytes were extremely fragile and degenerated immediately after sperm injection (Fig. 1 and 2). No oocyte was fertilized.

FIGURE 1



Case 2

This patient was found to have dextrocardia, congenital heart disease, scoliosis, and an imperforate anus at the time of birth. She had undergone surgical repair of partial anomalous pulmonary venous return, atrial and ventricular septal defects, and a hypoplastic right lung. She also had a colostomy created with subsequent takedown after repair of her imperforate anus. Later in life, she was diagnosed with duplicate right renal collecting system and ureters.

She had been evaluated by a reproductive geneticist before our consultation, after which a chromosomal microarray was performed and was found to be normal. Her

antimüllerian hormone level was noted to be 0.78 ng/mL before her initial visit to our clinic. She presented to our clinic at the age of 36 years to discuss oocyte cryopreservation. At that time, her body mass index was 23 kg/m², and an examination revealed a thickened longitudinal vaginal septum that could not accommodate a speculum or vaginal ultrasound probe. Using abdominal ultrasound, both ovaries were visualized, which had an antral follicle count of 5 and 4. Pelvic magnetic resonance imaging was ordered, which revealed a complete uterine septum extending into the cervix, duplicate cervixes and vaginal canals, and a longitudinal vaginal septum (Fig. 3 and 4).

FIGURE 2

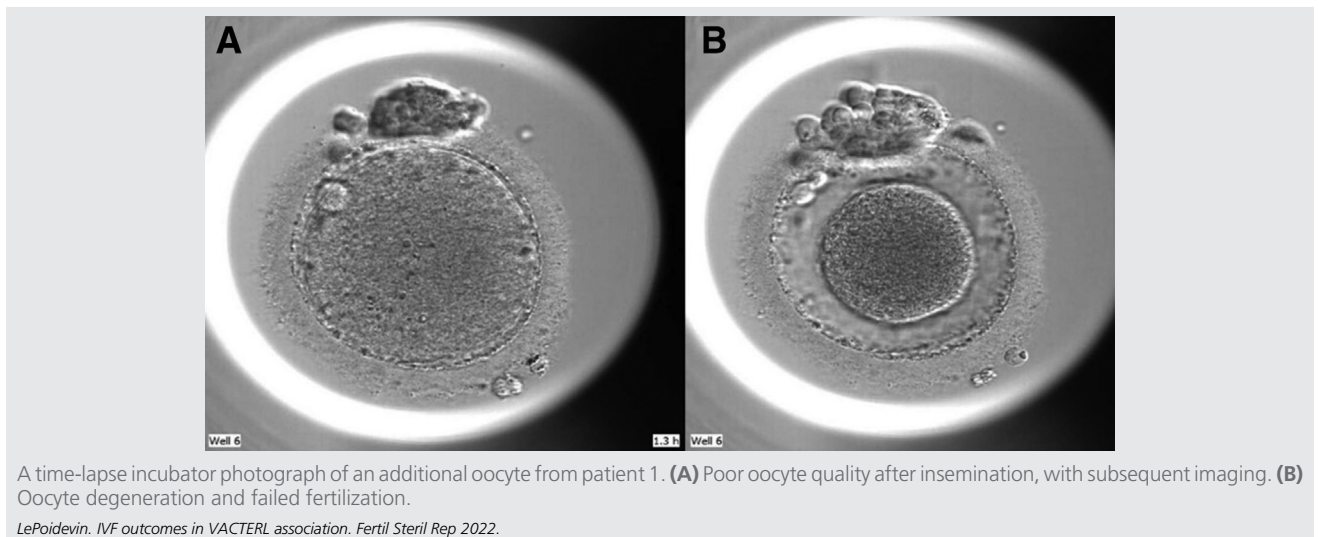
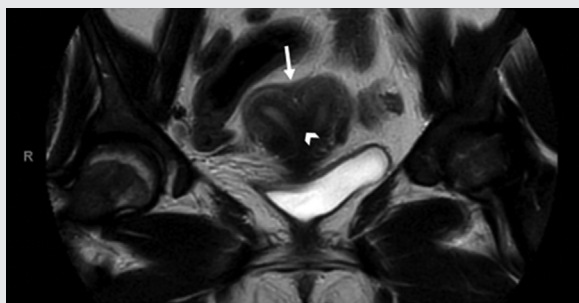


FIGURE 3



T2-weighted coronal section of abdominopelvic magnetic resonance imaging in patient 2. This was interpreted as a flat fundal zone (arrow), with subsequent complete uterine septum (arrowhead).

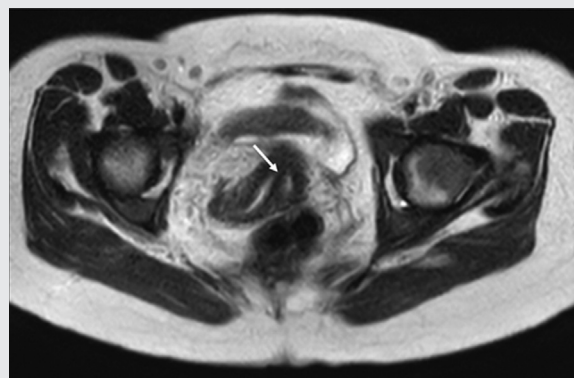
LePoidevin. IVF outcomes in VACTERL association. *Fertil Steril Rep* 2022.

Given the difficulty in accessing the ovaries vaginally, she was counseled on options that included repair of the vaginal septum or of both the vaginal and uterine septums, followed by a transvaginal oocyte retrieval vs. an abdominal oocyte retrieval. Given that she was not sexually active, was not experiencing any symptoms related to her vaginal or uterine septum, and was not pregnant at that time, she expressed interest in vaginal septum resection in the future. She elected to proceed with a possible transabdominal approach initially, given that her priority was to begin stimulation as soon as possible because of her diminished ovarian reserve. She was also counseled by her REI physician about the potential need for a gestational carrier for future pregnancies because of her anatomic comorbidities. Of note, she was referred to and evaluated by an MFM specialist during the REI workup, who recommended continued multidisciplinary discussions should she elect to try for pregnancy along with discussing the potential role of using a gestational carrier in the future. After extensive counseling, she elected to proceed with ovarian stimulation for oocyte cryopreservation.

She underwent a total of 3 IVF cycles for oocyte cryopreservation, with 2 resulting in oocyte retrieval. For the first stimulation cycle, the patient was placed on luteal estrace priming before an antagonist protocol, given her diminished ovarian reserve and concern for poor response. She was started on 375 IU of follitropin α and 225 IU of menotropins along with a low dose of a growth hormone during stimulation. The antagonist was started on day 9 of gonadotropins, with a peak estradiol level of 2,647 pg/mL and a progesterone level of 1.1 ng/mL on stimulation day 14, when she was triggered with 10,000 units of HCG. On the day of trigger, she had one 23-mm, one 19-mm, one 18-mm, two 17-mm, and two 16-mm follicles seen transabdominally.

At the time of oocyte retrieval, the ovaries, which had been monitored transabdominally during stimulation without issue were not felt to be safely accessible for transabdominal puncture because of overlying bowel. After discussions among the clinical team and considerations of prior conversations with the patient, in which she expressed the desire for future septum removal, the decision was made to excise the vaginal septum before oocyte retrieval to allow for

FIGURE 4



T2-weighted axial section of abdominopelvic magnetic resonance imaging in patient 2. Evidence of longitudinal vaginal septum (arrow) dividing 2 hemivaginal canals.

LePoidevin. IVF outcomes in VACTERL association. *Fertil Steril Rep* 2022.

vaginal access and, thus salvage the patient's stimulation cycle. After completion of the septum resection with the patient under anesthesia, a vaginal ultrasound probe could be placed in the vagina, which allowed visualization of both ovaries and transvaginal retrieval of 9 oocytes. Only 3 oocytes were mature and frozen, with 1 in metaphase I, 2 GVs, and 3 degenerating oocytes. On follow-up, her septum resection was healing well, and she expressed a desire for additional ovarian stimulation. She was started on a microdose-lupron flare protocol, but the cycle was canceled because of poor response, because she only developed one 15-mm and one 12-mm follicle. Because she reported a further desire for oocyte cryopreservation, plans were made to return to her initial protocol for an additional attempt. For her third stimulation, she was again placed on luteal estrace priming with an antagonist protocol. She was started on 450 IU of follitropin α and 150 IU of menotropins, with the antagonist started on day 8 of gonadotropins. Her peak estradiol level was 3,352 pg/mL, with a peak progesterone level of 1.5 ng/mL on stimulation day 13, when she was triggered with 10,000 units of HCG and an additional dose of follicle-stimulating hormone with the hope of improving oocyte maturity. In her second retrieval, 9 oocytes were again retrieved vaginally, but only 4 were found to be mature. Among the immature oocytes, 4 were in metaphase I and 1 was a GV. The 4 mature oocytes were cryopreserved, giving her a total of 7 oocytes under cryopreservation.

DISCUSSION

In this report, we present 2 cases of women with VACTERL association who underwent controlled ovarian hyperstimulation to demonstrate the challenges encountered in their fertility care. To our knowledge, no published reports evaluating fertility, ovarian stimulation outcomes, or even maternal pregnancy outcomes in patients with VACTERL have been indexed in PubMed.

The etiology of VACTERL association remains unknown, with likely heterogeneous causes. However, some posit if

there is a mitochondrial dysfunction component to the syndrome (2). Patients with VACTERL association with mitochondrial etiologies typically present with additional symptomatology, but poor oocyte yield, low maturity, and low fertilization rates in these cases are notable because oocytes carry all the developing embryos' mitochondria. Patient 1 had 16 oocytes retrieved, but only 38% of them were mature. Further, when intracytoplasmic sperm injection was performed, the oocytes immediately degenerated, leaving none fertilized. Patient 2 presented with diminished ovarian reserve, poor response to maximum doses of gonadotropins, and only 39% mature oocytes among the retrieved oocytes between her 2 IVF stimulations.

An additional hypothesis for the etiology of VACTERL association is X-linked origin because the incidence of VACTERL association appears to be higher in men than in women. A large case-control study using data from 28 European based registries for the epidemiological surveillance of congenital anomalies assessed 329 cases of VACTERL association and found 67% to be men, whereas the proportions of women and men were equal in the control population (7). One gene reported to be associated with the phenotypes of VACTERL association is *ZIC3*, which is located on the X chromosome, thus raising the possibility of an isolated X-linked mutation that could present more commonly in men (8). However, because many genetic associations have revealed other candidate genes that are not on the X chromosome, it cannot serve as a unifying feature.

Copy number variant mutations in certain pathways have been additionally proposed as mechanisms for the association. One case report noted a de novo microduplication at chromosome region 22q11.21 in a patient with VACTERL association. This chromosomal region is a common location for rearrangements and is indicated in patients with other conditions such as velo-cardio-facial and DiGeorge deletion syndromes (9). In animal studies, sonic hedgehog pathway genes (such as *Shh* and *Gli*) as well as the Hox and retinoic acid signaling pathways have been implicated in VACTERL association. Because the sonic hedgehog signaling pathway is an important component of follicle development, oocyte maturation, and embryo development, one can postulate if it had an effect on the patients presented (10). Unfortunately, there is no unifying or clear etiology for both VACTERL association and oocyte dysfunction to where more research in animal models is needed.

Some of the primary challenges faced during the management of these cases were the extensive surgical history and one patient's comorbid complex müllerian anomaly. In the setting of multiple prior pelvic surgeries, accessing the ovaries was challenging in both patients. Further, multiple case reports have noted müllerian anomalies occurring in patients with VACTERL association (11–13). Although müllerian anomalies can comprise part of the müllerian, renal, cervicothoracic somite abnormalities association, care should be taken to assess for the presence of müllerian anomalies in patients with VACTERL association because of the intimate relationship between the developing renal and müllerian systems. In the case of our second patient, she had desired surgical excision of her septum, and we were

able to excise it safely to allow for transvaginal ovarian access for her 2 oocyte retrievals. If comorbid müllerian anomalies exist, we would likely recommend, based on the experience with our patient, optimizing the anatomy first by resecting the vaginal septum if it is present before attempting stimulation to allow easier access.

To date, we have not found other documented cases or reports of controlled ovarian hyperstimulation and IVF outcomes in patients with VACTERL association. Each case presented here displayed challenges due to aberrations in pelvic anatomy and poor IVF outcomes. An MFM specialist was also consulted in both the cases to counsel the patients on pregnancy options and recommendations as well as discuss the role and utility of a gestational carrier. Both the patients' IVF stimulation cycles revealed unexpected challenges, with reduced oocyte yield, low oocyte quality, low maturity, and low fertilization rates. As more patients with VACTERL association age, they may present to REI clinics to discuss fertility options. Their care requires a multidisciplinary assessment, an individualized approach, and continued investigation regarding their IVF and fertility outcomes.

REFERENCES

- Solomon BD. Vacterl/Vater association. *Orphanet J Rare Dis* 2011;6:1–12.
- Siebel S, Solomon BD. Mitochondrial factors and VACTERL association-related congenital malformations. *Mol Syndromol* 2013;4:63–73.
- O'Flynn O'Brien KL, Bhatia V, Homafar M, Gong YY, Winsten MT, Gerber J, et al. The prevalence of Müllerian anomalies in women with a diagnosed renal anomaly. *J Pediatr Adolesc Gynecol* 2021;34:154–60.
- Oppelt P, von Have M, Paulsen M, Strissel PL, Strick R, Brucker S, et al. Female genital malformations and their associated abnormalities. *Fertil Steril* 2007;87:335–42.
- Solomon BD, Raam MS, Pineda-Alvarez DE. Analysis of genitourinary anomalies in patients with VACTERL (Vertebral anomalies, Anal atresia, Cardiac malformations, Tracheo-Esophageal fistula, Renal anomalies, Limb abnormalities) association. *Congenit Anom* 2011;51:87–91.
- Bing Z. Obstructive azoospermia in a patient with VATER association. *Open J Pathol* 2012;02:159–61.
- van de Putte R, Van Rooij IA, Haanappel CP, Marcelis CL, Brunner HG, Addor MC, et al. Maternal risk factors for the VACTERL association: a EURO-CAT case-control study. *Birth Defects Res* 2020;112:688–98.
- Chen Y, Liu Z, Chen J, Zuo Y, Liu S, Chen W, et al. The genetic landscape and clinical implications of vertebral anomalies in VACTERL association. *J Med Genet* 2016;53:431–7.
- Schramm C, Draaken M, Bartels E, Boemers TM, Aretz S, Brockschmidt FF, et al. De novo microduplication at 22q11.21 in a patient with VACTERL association. *Eur J Med Genet* 2011;54:9–13.
- Lee S, Jin JX, Taweechaipaisankul A, Kim GA, Ahn C, Lee BC. Sonic hedgehog signaling mediates resveratrol to improve maturation of pig oocytes in vitro and subsequent preimplantation embryo development. *J Cell Physiol* 2018;233:5023–33.
- Kang J, Mao M, Zhang Y, Ai FF, Zhu L. Congenital anal atresia with rectovesitibular fistula, scoliosis, unilateral renal agenesis, and finger defect (VACTERL association) in a patient with partial bicornuate uterus and distal vaginal atresia: a case report. *Medicine* 2018;97:e12822.
- Nunes N, Karandikar S, Cooper S, Jaganathan R, Irani S. VATER/VACTERL syndrome (vertebra/anus/cardiac/trachea/esophagus/radius/renal/limb anomalies) with a noncommunicating functioning uterine horn and a unicornuate uterus: a case report. *Fertil Steril* 2009;91:1957:e11–2.
- Obeidat RA, Aleshawi AJ, Tashtush NA, Alsarawi H. Unicornuate uterus with a rudimentary non-communicating cavitary horn in association with VACTERL association: case report. *BMC Women's Health* 2019;19:1–5.