

A 42-Month Follow-Up of Double Root Fracture of a Lateral Mandibular Incisor

 Fatou LEYE BENOIST,  Anta SECK,  Henri Michel BENOIST

ABSTRACT

This case report describes the treatment of a double root fracture of a lateral mandibular incisor and its follow-up over 3.5 years.

The reason for the consultation was a tooth mobility following a fall that had occurred 2 days earlier. A test of pulp vitality for tooth 42 was positive. Periodontal probing at the level of the gingival sulcus confirmed the intactness of the epithelial attachment. Retro-alveolar radiographic examination revealed a double root fracture of tooth 42.

A semi-rigid extra-coronal splinting was performed and a light grinding of the incisal edge of tooth 42 was then carried out in light of the dislocation of the coronal fragment, and the occlusion was checked with a strip of articulating paper. The outcomes at 6 months revealed that pulp vitality was still preserved, consolidation of the apical fracture had occurred, and the coronal root fracture was starting to heal. The 1-year, 2-year and 3-year follow ups revealed preserved pulp vitality, an absence of a fracture line in apical images, and no root resorption.

This case report provides evidence for the preservation of vitality in the setting of a double root fracture.

Keywords: Dental pulp test, splints, tooth fractures, tooth mobility

HIGHLIGHTS

- This case report provides evidence for the preservation of vitality in the setting of a double root fracture for which one fracture site was at the level of the coronal third of the tooth.
- Root fractures need to be perceived as complex traumas since they affect both the hard tissues and the soft periodontal tissues.
- In the absence of communication between the line of fracture and the oral cavity, therapeutic abstinence in endodontics should be the treatment of choice for the preservation of the pulp vitality.

INTRODUCTION

Root fractures need to be perceived as complex traumas since they affect both the hard tissues and the soft periodontal tissues. They are the result of pronounced pressure that elicits areas of compression at the root (1, 2). Fractures are divided into three categories depending on occurrence location. They can sit in the apical third, central third and cervical third. The prevalence of root fractures is 0.5-7% for permanent teeth (3, 4). Root fractures occur primarily with the upper and lateral central incisors (68% and

27%, respectively) due to their more exposed position. At 5%, the lower incisors are considerably less affected (1, 5). These fractures constitute an emergency.

In the absence of dislocation of fragments, the fracture cannot be detected. This necessitates resorting to two-dimensional imaging at various angles or in three dimensions for the diagnosis (6, 7). The healing process following a fracture is much better in young individuals for whom root formation and growth has not yet ceased. The prognosis is better when the sensitivity test is positive at the time of the accident and there is no dislocation or substantial movement of the coronal fragment (8).

The therapeutic options have the same objective: reducing the fracture line either by restorative dental techniques or by partial (resection) or total (amputation, extraction) root subtraction techniques (1, 7, 8).

Please cite this article as: Leye Benoist F, Seck A, Benoist HM. A 42 Month Follow-Up of Double Root Fracture of a Lateral Mandibular Incisor. *Eur Endod J* 2017; 2: 26

From the Department of Conservative Dentistry and Endodontics (F.L.B. ✉ fatou.leye@ucad.edu.sn, A.S.), University Cheikh Anta Diop of Dakar, Dakar, Senegal; Department of Periodontics (H.M.B.), University Cheikh Anta Diop of Dakar, Dakar, Senegal

Received 29 March 2017, revision requested 21 June 2017, last revision received 23 July 2017

Published online: 13 October 2017
DOI: 10.5152/eej.2017.17021

This work is licensed under a Creative Commons Attribution-NonCommercial 4.0 International License.



These lesions have many consequences at a socioeconomic level since their treatment involves significant cost, in addition to the prognostic uncertainty for the afflicted teeth.

This case report describes the treatment of a double root fracture of a lateral mandibular incisor and its follow-up over 3.5 years.

CASE PRESENTATION

A 23-year-old Senegalese female presented for consultation to the conservative dentistry clinic of the University Cheikh Anta Diop's Dental School on 01 July 2013. At the time of presentation, she was enrolled for a Bachelor's degree in dental surgery. The reason for the consultation was a tooth mobility following a fall that had happened 2 days earlier in her bathroom. Upon questioning, she said that the pain ceased upon self-medication with ibuprofen. Inspection of her face did not show lesions of the integuments or swelling. Examination of the oral cavity did not reveal lesions of the dental crowns or the mucosa or loss of maxillary substances. Palpation of the alveolar process at the vestibular and palate level did not reveal any sign of fracture or collapse. Apical palpation did not cause pain although tooth 42 exhibited mobility (grade 2 on the Mühlemann index mobility tooth). A cold test of pulp vitality (tetrafluoroethane cryoanaesthetic spray, Septodont, St Maur des Fosses, France) for tooth 42 was positive, and this was confirmed by an electric test (Electric Pulp Tester Avero[®] PT 2.0, VEGA-PRO, Ekaterinburg, Russia). Periodontal probing at the level of the gingival sulcus confirmed the intactness of the epithelial attachment. Retro-alveolar radiographic examination revealed a double root fracture of tooth 42, the first one situated at the apical level and the second situated more towards the crown (Figures 1, 2).

Treatment and outcomes

A semi-rigid extra-coronal splinting was performed as an emergency treatment using a 3/10 mm braided steel wire cut to size and glued in place with light-polymerisable composite resin (Herculite[®] XRV Ultra, Kerr Hawe, USA) on the lingual side of teeth 41, 42 and 43 (Figure 3). A light grinding of the incisal edge of tooth 42 was then carried out in light of the dislocation of the coronal fragment, and the occlusion was checked with a strip of articulating paper (BK-01, 200mm; Bausch Articulating Papers, Inc. Nashua, NH, USA) to avoid any detrimental pressure on the tooth and on the stability of the immobilisation splint. A control X-ray was taken (Figure 4).

No medication was prescribed in light of the lack of functional signs. The patient was advised in regard to oral hygiene and eating, and a follow-up schedule was implemented. A check-up was carried out on day 15 and then every month up to the sixth month, followed by yearly check-ups. In these check-ups, the edge of the gum, discoloration of the tooth and the pulp vitality were evaluated. X-rays were taken at regular intervals from 1-6 months and then annually over a 3-year period to note whether consolidation, resorption, or canal obliteration occurred. Considering the position of the extra-alveolar fracture line, the semi-rigid immobilisation was permanently retained in place. The outcomes at the sixth month revealed that pulp vitality was still preserved, consolidation of the apical fracture had occurred, but coronal root fracture showed no signs of calcification (Figure 5).

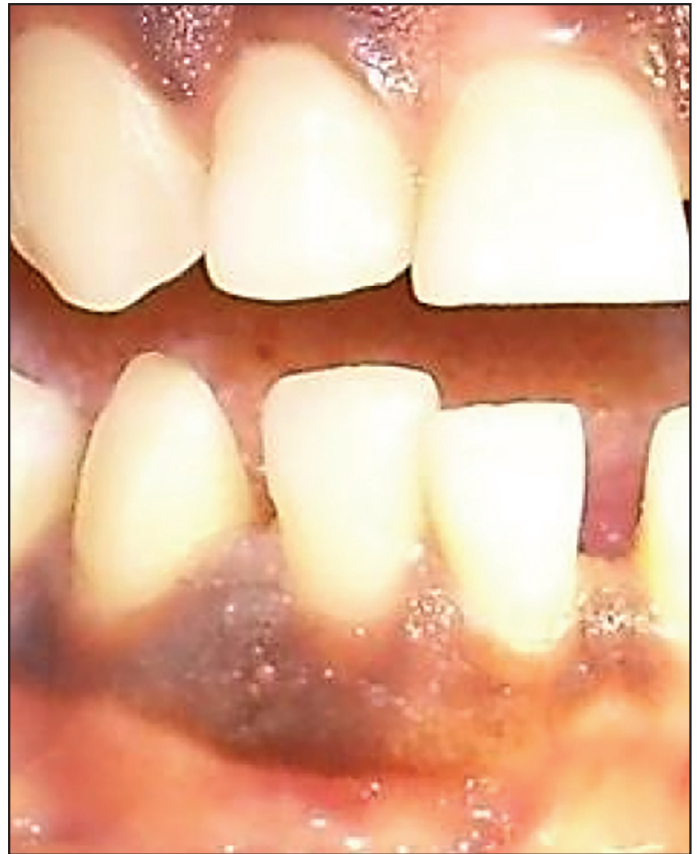

Figure 1. Clinical view showing the intactness of the dental-periodontal tissues

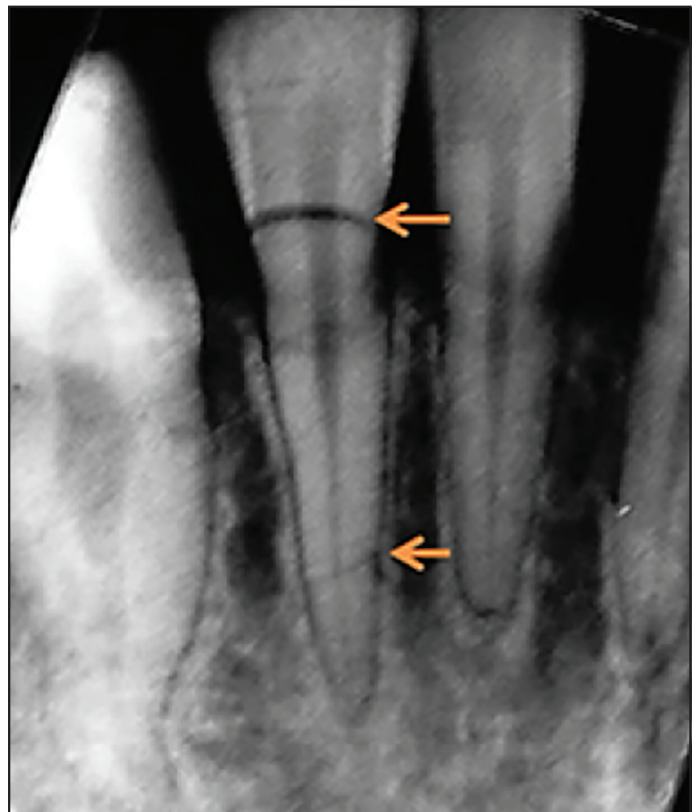


Figure 2. Radiography after the trauma and the double root fracture for tooth 42, with a fracture line in the apical third and another at the crown involving dislocation of the coronal fragment (arrows)

The follow ups at days 30, 60 and 90 and 1 year, 2 years and 3 years revealed preserved pulp vitality, an absence of a fracture line in apical images, and no root resorption (Figures 6-8).

DISCUSSION

According to Machtou and Naulin (5), root fractures have diverse clinical presentations. The reduction of the fracture is more difficult than the movement of fragments is important.

Authors investigating this subject area are in agreement regarding the more frequent affliction of the upper central inci-

sors, which are involved in >85% of trauma cases, due to their extremely forward position that renders them a 'bumper'; then, in decreasing order, there are the upper lateral incisors and the central lower incisors (1). In the present case, the patient exhibited misalignment of the lower incisor-canine set. The degree of movement depends on the severity of the trauma and the location of the fracture line. The movement can be considerable when the fracture is located in the coronal one-third. If the fracture line is located in the apical one-third,

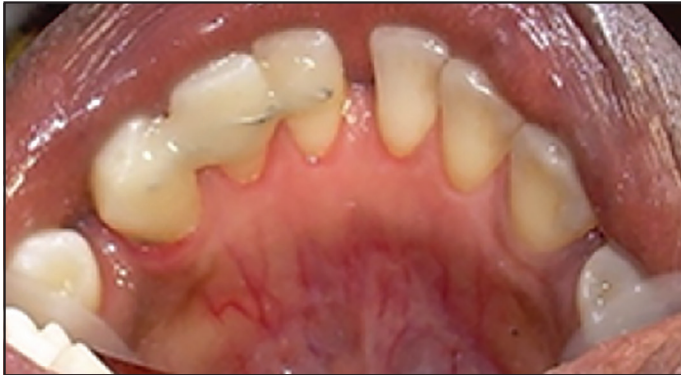

Figure 3. Clinical lingual view of the oral cavity after installing the splinting system from tooth 41 to tooth 43

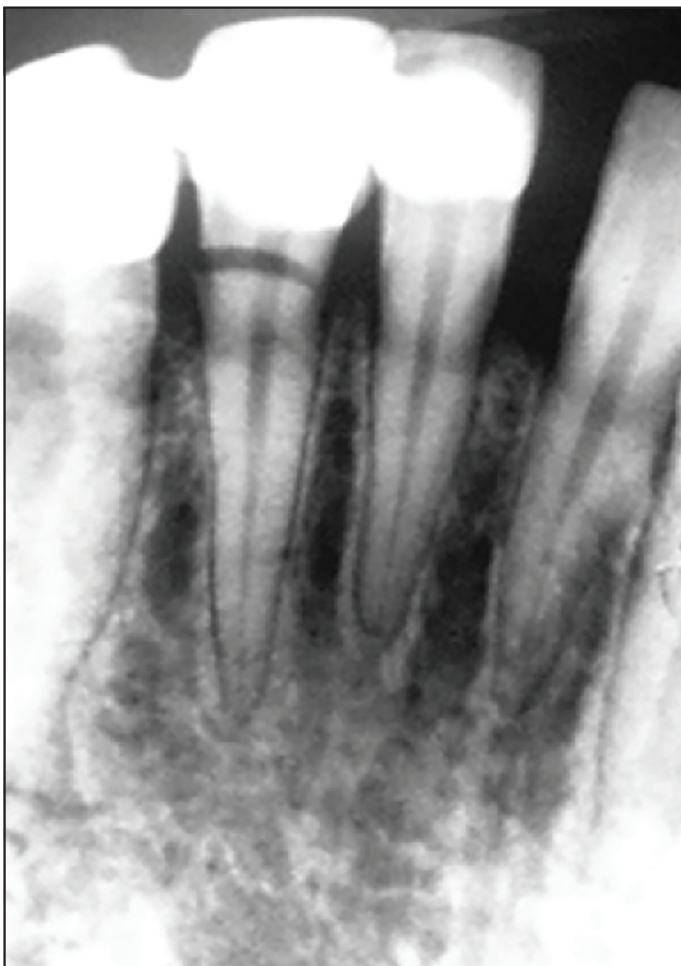

Figure 4. Radiographic X-ray control after splinting

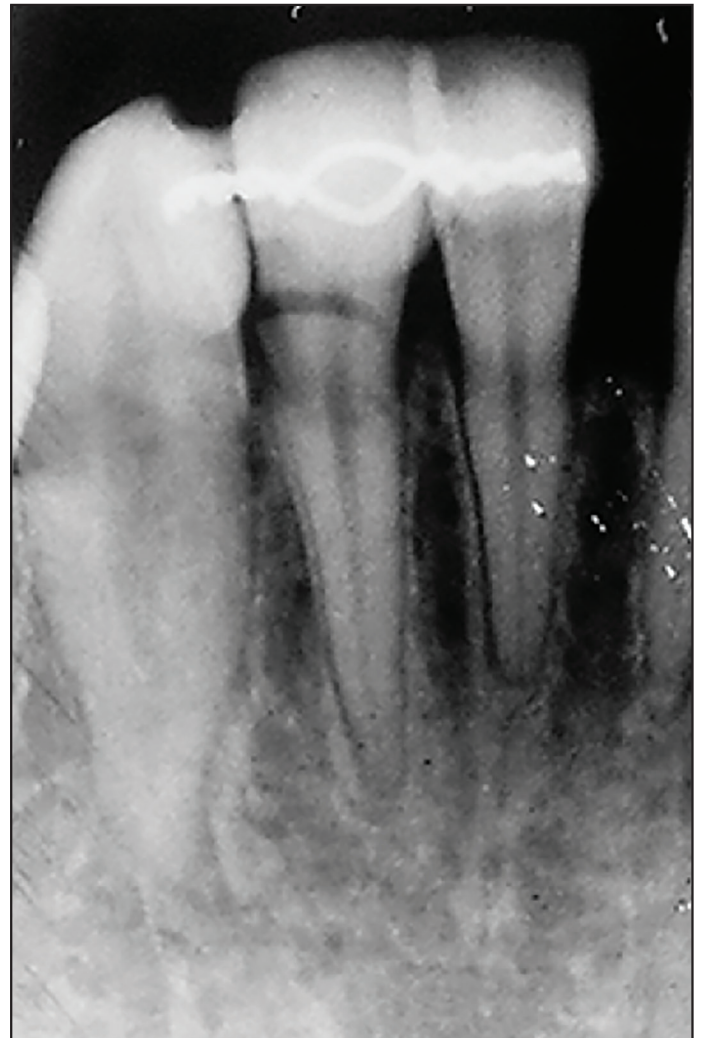

Figure 5. Radiographic X-ray at 6 months showing consolidation of the apical one-third fracture and absence of consolidation of the coronal one-third one

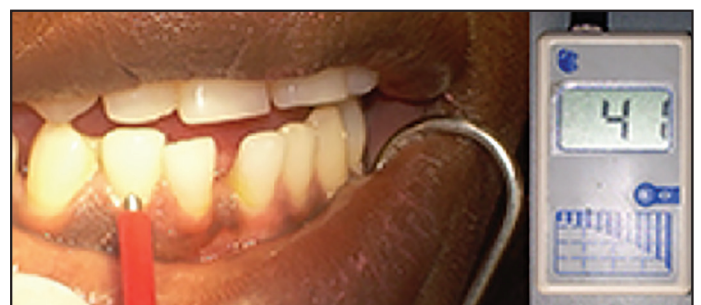

Figure 6. Positive electrical test of pulp vitality (PT O2 Dental Pulp Tester, Aeron) for tooth 42

the tooth exhibits little or no movement. In this case, the root fracture is detected during the radiological examination (5). This particular case exhibited a grade 2 degree of movement, as the fracture line was located in the coronal one-third. Despite the delayed consultation, the immobilisation performed as part of the overall treatment allowed to reduce the degree of movement.

The tests for pulp vitality were positive from the time of the clinical examination until the last check-up performed at 3 years of follow-up. If the tooth reacts immediately and in a

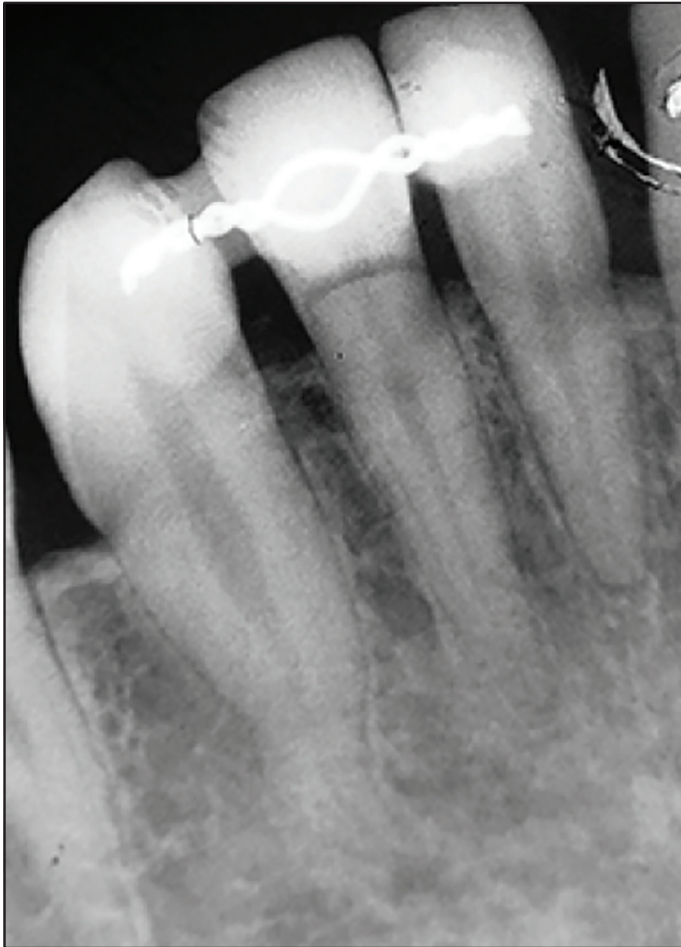

Figure 7. Radiographic control at three years showing probable consolidation process on the 1/3 coronal

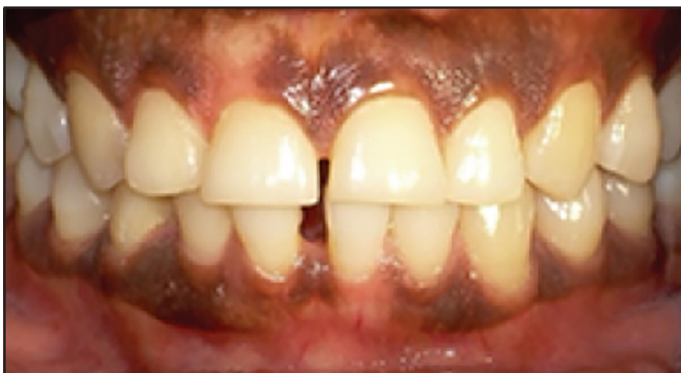

Figure 8. Clinical view at 3.5 years showing stability of the aesthetics and the hard and soft tissues

marked manner to an appropriate sensitivity test (thermal and electrical), there is a clear sign of pulp vitality. If there is no or minimal reaction, the result initially has no informative value. A complete rupture of the pulp is possible, which would result in necrosis of the pulp of a tooth for which growth has ceased. Yet, an apical irritation can lead to a temporary loss of sensitivity, which is generally not linked with a loss of vitality (5). At the first consultation, any tooth exhibiting a root fracture without contacting the oral cavity should be treated as a live tooth without considering the sensitivity test (8).

A radiological examination is essential, and it can allow a clinically unsuspected fracture of the apical third to be discovered, as was the case in this report. It requires several incidences. An occlusal view is essential and is completed by retroalveolar incidences captured at various angles (3). Fractures of the apical third are more readily seen by an occlusal incidence. The retroalveolar radiography allows the observation of the more coronal fractures. The fracture line is only visible on radiography if the vertical angulation of the beam is directed between 15° and 20° relative to the fracture line. If a radio clear line appears on the initial radiography, it is recommended to record two other retro-alveolar X-rays by modifying the vertical angulation of 15° more or less compared to the initial radiography, to verify that it is not a radiological artefact. Use of a radiographic angulation instrument (e.g. Rinn® Dentsply De Trey GmbH, Konstanz, Germany) is highly recommended in traumatology and particularly in case of root fracture. This procedure allows X-rays to be captured under the same conditions at various times, thereby allowing detection of any changes. The use of a conebeam computed tomography (CBCT) has a more accurate diagnostic value for a root fracture, compared to intra-oral radiography. However, CBCT needs to be used with caution due to its higher level of associated radiation (9).

The healthy pulp of an asymptomatic tooth responds normally to the various vitality tests and to percussion and palpation. Such a tooth shows neither radiographic signs of canal obliteration by 'asynchronous' calcification as compared to the pulp of the adjacent teeth nor signs of root resorption, but rather an intact lamina dura and a normal periodontal ligament space along the entire radicular length (10, 11). Pulp healing, pulp canal calcification, or pulp necrosis are the three major possible responses of the pulp following dental trauma. All three responses can occur at different times. The most desirable outcome after dental trauma is pulp healing, recovery and return to normalcy (12). According to Andreasen and Kahler (7), the healing process of root fractures depends on several variables, such as patient age, movement of the coronal fragment, the site of the fracture and the stage of root formation. According to Machtou and Naulin (5), the treatment should be geared towards maintaining pulp vitality. A fracture of the apical one-third is the best situation, since in the majority of cases, no movement or displacement of the fragments is observed. For the present case, healing was noted at the sixth month after the trauma. Healing of root fractures of the coronal one-third or the middle occurs in two ways: formation of calcified tissue or interposition of conjunctive tissue. Reduction of the fragments and maintaining them in their original position allows the fracture to consolidate by formation of a callus that

resembles dentin on the pulp side and that resembles dental cement on the periodontal ligament side. This healing, which is common in case of immature teeth and when the associated periodontal trauma is minimal, varies from 2-3 months in the best cases (1, 13, 14). The immobilisation splint is kept in place for 4-12 weeks if movement of the coronal segment persists upon removal of the restraint, and another immobilisation will have to occur for a longer period of time (5, 11). According to Kahler et al. (15), the type of splint and fixation periods were generally not significant variables in studies that used a multivariate analysis for assessment of pulp necrosis and type of healing/non-healing of the root-fractured fragments. In this case, the restraint was retained in place, as we did not see a callus indicative of healing. In light of the position of the fracture line at the coronal third, we assumed that there would no longer be movement of the fragment despite the clear absence of a callus indicative of healing after 1 year. Nevertheless, radiographic control at 3.5 years showed signs of healing of the coronal fracture. The vitality was nonetheless preserved after 3 years of follow-up. This indicates that there is no direct communication between the fracture and the oral environment and contact of infectious events, which was probably due to a healthy periodontal environment stemming from the patient's level of relevant knowledge obtained through her dental surgery studies.

CONCLUSION

This case report provides evidence for the preservation of vitality in the setting of a double root fracture for which one fracture site was at the level of the coronal third of the tooth. Healing was achieved at the level of the apical fracture. Failure of the healing at the level of the coronal fracture did not preclude preservation of pulp vitality after 3.5 years of follow-up and continued immobilisation. The patient's educational background and the application of adequate oral hygiene measures may explain the preservation of pulp vitality in the absence of a callus indicative of healing.

Disclosures

Ethical Approval: N/A.

Informed Consent: Verbal informed consent was obtained from patient who participated in this study.

Peer-review: Externally peer-reviewed.

Authorship Contributions: Concept - F.L.B., A.S., H.M.B.; Design - F.L.B., A.S., H.M.B.; Supervision - F.L.B., A.S., H.M.B.; Materials - H.M.B.; Data Collection and/or Processing - F.L.B., H.M.B.; Analysis and/or Interpretation - F.L.B., A.S.; Literature Review - F.L.B.; Writer - F.L.B.; Critical Review - H.M.B.

Conflict of Interest: No conflict of interest was declared by the authors.

Financial Disclosure: The authors declared that this study has received no financial support.

REFERENCES

1. Mamaladze M, Nizharadze N, Vadachkoria O. The peculiarities of treatment of uncomplicated and complicated dental injuries caused by trauma. *Georgian Med News* 2017; (262):28-32.
2. Malhotra N, Kundabala M, Acharaya S. A review of root fractures: diagnosis, treatment and prognosis. *Dent Update* 2011; 38(9):615-616, 619-620, 623-624.
3. Andreasen JO, Andreasen FM. *Textbook and color atlas of traumatic injuries to teeth*, 3rd ed. Copenhagen: Munksgaard St Louis: Mosby, 1994: 771.
4. Chala S, Sakout M, Abdallaoul F. Repair of untreated horizontal root fractures: two case reports. *Dent Traumatol* 2009; 25:457-59.
5. Machtou P, Naulin Ifi C. Les fractures radiculaires. *Réal Clin* 200013(1):27-38.
6. Andreasen FM, Andreasen J.O. Diagnostic of luxation injuries: the importance of standardized clinical, radiographic and photographic techniques in clinical investigation. *Endod Dent Traumatol* 1985; 1:160-69.
7. Andreasen FM, Kahler B. Pulpal response after acute dental injury in the permanent dentition: clinical implications-a review. *J Endod* 2015; 41(3):299-308.
8. Aulakh KK, Gumber TK, Sandhu S. Prognosis of teeth in the line of jaw fractures. *Dent Traumatol* 2017; 33(2):126-32.
9. Makowiecki, A, Witek, J, Pol & J. Buczkowska-Radlińska. The maintenance of pulp health 17 years after root fracture in a maxillary incisor illustrating the diagnostic benefits of cone beam computed tomography. *Int Endod J* 2014; 47:889-95.
10. Weine FS. Diagnosis and treatment planning. In: Weine FS, editor. *Endodontic Therapy*. 5th 899 ed. St. Louis: Mosby; 1996:28-83.
11. Arnaldo Castellucci. Pulpal pathology. In: Arnaldo Castellucci, editor. *Endodontics volume1*. Florence: il Tridente 2004; 136-59.
12. Yu CY, Abbott PV Responses of the pulp, periradicular and soft tissues following trauma to the permanent teeth. *Aust Dent J* 2016; 61(1):39-58.
13. Silva L, Álvares P, Arruda JA Silva LV, Rodrigues C, Sobral AP, Silveira M. Horizontally root fractured teeth with pulpal vitality - two case reports. *World J Radiol* 2016; 8(12):928-32.
14. Brandini DA, Poi WR, Panzarini SR, Sonoda CK, de Castro JC, Luvizuto ER, Leal CR. Integrated treatment to resolve a horizontal root fracture. *Dent Traumatol* 2009; 25(2):16-20.
15. Kahler B, Hu JY, Marriot-Smith CS, Heithersay GS. Splinting of teeth following trauma: a review and a new splinting recommendation. *Aust Dent J* 2016; 61(1):59-73.