

Endometrial Cancer with Sarcoidosis in Regional Lymph Nodes: A Case Report

Satoshi Tamauchi^a Yuji Shimomura^b Hiromi Hayakawa^b

^aDepartment of Obstetrics and Gynecology, Nagoya University Graduate School of Medicine, Nagoya, and ^bDepartment of Obstetrics and Gynecology, Kasugai Municipal Hospital, Kasugai, Japan

Key Words

Endometrial cancer · Sarcoidosis · Noncaseating granulomas

Abstract

Sarcoidosis is a chronic, multisystemic disease commonly affecting the lungs and lymphatic system and is characterized by the formation of noncaseating granulomas. Although several reports are available on cases developing both sarcoidosis and cancer metachronously, cases of simultaneous diagnosis of these diseases have rarely been reported. A 67-year-old woman diagnosed with endometrial cancer had developed systemic lymph node swelling, including bilateral hilar, paraaortic, and a few pelvic lymph nodes, as observed on preoperative imaging. During surgery, frozen sections of a paraaortic lymph node were examined, revealing noncaseating granulomas compatible with sarcoidosis. Next, modified radical hysterectomy, bilateral salpingo-oophorectomy, and pelvic lymphadenectomy were performed. Postoperative pathological analysis revealed endometrioid adenocarcinoma of the uterus, and no metastasis but noncaseating granulomas were detected in the resected lymph nodes. Postoperatively, we identified cutaneous sarcoidosis and uveitis in the presence of a tuberculin-negative test. On the basis of these findings, we diagnosed the patients with endometrial cancer complicated by sarcoidosis. She underwent adjuvant chemotherapy, and at the 1-year follow-up, the lymph node swelling due to sarcoidosis was stable, and no recurrence of the cancer was observed. This turned out to be a case of early endometrial cancer mimicking advanced cancer by sarcoidosis. Histological confirmation and additional examination for sarcoidosis are necessary in cancer patients suspected of sarcoidosis.

© 2015 The Author(s)
Published by S. Karger AG, Basel

Introduction

Sarcoidosis is characterized by the widespread development of noncaseating epithelioid granulomas in multiple organ systems, but its etiology is unknown [1]. Although new onset of sarcoidosis in cancer patients and new cancer onset in sarcoidosis patients have been reported several times, reports documenting simultaneous diagnosis of cancer and sarcoidosis have only rarely been published. Here, we report a 67-year-old woman simultaneously diagnosed with endometrial cancer and sarcoidosis with enlarged regional lymph nodes due to sarcoidosis, but not metastasis.

Case Report

A 67-year-old woman was presented to our institution with irregular genital bleeding. Ultrasound examination revealed endometrial hypertrophy with a histopathology of endometrioid adenocarcinoma. A chest-abdomen computed tomography (CT) scan showed multiple enlarged lymph nodes including bilateral hilar, supraclavicular, paraaortic and pelvic lymph nodes (fig. 1). Serum tumor markers were normal except for a slight elevation of soluble interleukin-2 receptor (sIL-2R); CA125 = 30.2 U/ml, CA19-9 = 2.0 U/ml, CEA = 3.9 ng/ml, and sIL-2R = 549 U/ml. Moreover, angiotensin-converting enzyme was 24.5 U/l, and serum calcium was 9.4 mg/dl; the other results of blood examination, liver and renal function tests, electrolytes, and a complete blood count were all normal. Preoperatively, this case was speculated to be highly advanced endometrial cancer, otherwise associated with sarcoidosis or malignant lymphoma. At the beginning of the surgery, frozen sections of a paraaortic lymph node, potentially being the most remote regional lymph node of endometrial cancer metastasis, were examined, revealing noncaseating granulomas compatible with sarcoidosis. On the basis of the pathology result, modified radical hysterectomy, bilateral salpingo-oophorectomy, and pelvic lymphadenectomy were performed as curative surgery. Histopathological examination revealed grade-2 endometrioid adenocarcinoma of the uterus, with more than 50% myometrial invasion (fig. 2). Noncaseating granulomas were observed in paraaortic, right obturator, and right common iliac lymph nodes, but no evidence of cancer metastasis was found (fig. 3). Therefore, the patient was diagnosed with a grade-2 endometrioid adenocarcinoma, clinical stage 1b (pT1bN0Mx). Because of the lymph node cytology results, a tuberculosis test was performed, and the result was negative. A biopsy from a lower jaw exanthema revealed a subcutaneous granuloma (fig. 3). Furthermore, uveitis was detected in the fundus. On the basis of histological and clinical findings, the patient was diagnosed with sarcoidosis. The patient received adjuvant chemotherapy in the form of 6 cycles of docetaxel (75 mg/m²) and carboplatin (AUC 5). She also received ophthalmic steroids for uveitis. At the 1-year follow-up, lymph node swelling due to sarcoidosis was stable, and no cancer recurrence was observed.

Discussion

Sarcoidosis is characterized by noncaseating granulomas in multiple organs such as lungs, skin, eyes, nerves, bones, and heart [1]. Previously, several reports of sarcoidosis associated with cancer have been published [2–4]; however, most of these were cases developing one disease during follow-up of the other disease. In the scientific literature, reports on simultaneous diagnosis of cancer and sarcoidosis are limited.

Besides, to establish a diagnosis of sarcoidosis, identification of lesions in two or more organs is required. Noncaseating granulomas in lymph nodes are usually brought about by infections, environmental exposure to chemical substances, autoimmune disorders, or malignant diseases [5]. These are called 'sarcoid reactions', unless findings from other organs meet the criteria for sarcoidosis.

In the gynecologic field, Yamaguchi et al. [6] reported the frequent onset of uterine cancer during sarcoidosis follow-up. Although one case of endometrial cancer coinciding with granulomatous necrotizing lymphadenitis has been reported [7], the present case is the first report of sarcoidosis diagnosed simultaneously with endometrial cancer.

In cancer patients, sarcoidosis may mimic advanced-stage cancer, potentially leading to inappropriate management of the cancer [7]. To confirm a preoperative diagnosis of sarcoidosis is currently almost impossible because radiological examinations may not enable a distinction between cancer metastasis and sarcoidosis. Thus, a pathological diagnosis should be obtained when possible to differentiate these diseases. Frozen sections obtained during surgery can be used to inform decisions on appropriate treatment. In addition, the findings of noncaseating granulomas in one organ are not sufficient for establishing a diagnosis of sarcoidosis; therefore, additional examinations for sarcoidosis are necessary for accurate diagnosis.

Cutaneous granulomas are detected in 9–37% of sarcoidosis patients, and skin biopsies are typically easy to perform because of their relatively low extent of invasion compared with other organs [8]. In this case, however, attending gynecologists were not able to point out the rash of the lower jaw as abnormal. Because cutaneous manifestations of sarcoidosis are often difficult to detect for most oncologists because of their nonspecific appearance, asking for a physical examination by a dermatologist appears important.

The association between a malignant disease and noncaseating granulomas remains controversial, and several mechanisms have been proposed such as local nonspecific reaction to tumor cells, tissue reaction to tumor embolism in lymphatic and blood vessels, mucosal injury, abnormal local immune response, or autoimmune reaction caused by tumor-derived soluble antigen [9, 10]. Moreover, dysregulation of the T-cell system in sarcoidosis patients may be related to malignancy [11].

If cancer was the cause of sarcoidosis, sarcoidosis activity might be weakened after the cancer treatment. In the present case, however, the sarcoidosis remained stable after cancer treatment; hence, uterine cancer and the sarcoidosis had no shared etiology, at least in this case.

With persistent lymph node swelling, the follow-up is challenging. Approximately half of sarcoidosis cases resolve or can be cured within 12–36 months, and most within 5 years [12]. However, some cases persist for several decades, and conditions may deteriorate [13]. When lymph nodes are starting to become larger, it is difficult to differentiate whether this enlargement is due to cancer or sarcoidosis. At present, frequent observation combined with histological confirmation is the only way to early detect the recurrence of the cancer.

Acknowledgement

We acknowledge Dr. Tateyama for providing the photographs of the pathology specimens.

Statement of Ethics

The authors have no ethical conflicts to disclose.

Disclosure Statement

The authors declare that they have no conflicts of interest.

References

- 1 Newman LS, Rose CS, Maier LA: Sarcoidosis. *N Engl J Med* 1997;336:1224–1234.
- 2 Reich JM, Mullooly JP, Johnson RE: Linkage analysis of malignancy-associated sarcoidosis. *Chest* 1995;107:605–613.
- 3 Mayne AIW, Ahmad J, Loughrey M, Taylor MA: Sarcoidosis of the pancreas mimicking adenocarcinoma. *BMJ Case Rep* 2013, DOI: 10.1136/bcr-2013-009118.
- 4 Hunt BM, Vallières E, Buduhan G, Aye R, Louie B: Sarcoidosis as a benign cause of lymphadenopathy in cancer patients. *Am J Surg* 2009;197:629–632.
- 5 Brincker H: Sarcoid reactions in malignant tumours. *Cancer Treat Rev* 1986;13:147–156.
- 6 Yamaguchi M, Odaka M, Hosoda Y, Iwai K, Tachibana T: Excess death of lung cancer among sarcoidosis patients. *Sarcoidosis* 1991;8:51–55.
- 7 Mapelli P, Mangili G, Picchio M, Rabaiotti E, Gianolli L, Messa C, et al: Sarcoidosis mimicking metastatic gynaecological malignancies: a diagnostic and therapeutic challenge? *Rev Esp Med Nucl Imagen Mol* 2013;32:314–317.
- 8 Mañá J, Marcoval J, Rubio M, Labori M, Fanlo M, Pujol R: Granulomatous cutaneous sarcoidosis: diagnosis, relationship to systemic disease, prognosis and treatment. *Sarcoidosis Vasc Diffuse Lung Dis* 2013;30:268–281.
- 9 Kojima M, Nakamura S, Fujisaki M, Hirahata S, Hasegawa H, Maeda D, et al: Sarcoid-like reaction in the regional lymph nodes and spleen in gastric carcinoma: a clinicopathologic study of five cases. *Gen Diagn Pathol* 1997;142:347–352.
- 10 Neiman RS: Incidence and importance of splenic sarcoid-like granulomas. *Arch Pathol Lab Med* 1977;101:518–521.
- 11 Tana C, Giamberardino MA, Di Gioacchino M, Mezzetti A, Schiavone C: Immunopathogenesis of sarcoidosis and risk of malignancy: a lost truth? *Int J Immunopathol Pharmacol* 2013;26:305–313.
- 12 Costabel U, Hunninghake GW: ATS/ERS/WASOG statement on sarcoidosis. Sarcoidosis Statement Committee. American Thoracic Society. European Respiratory Society. World Association for Sarcoidosis and Other Granulomatous Disorders. *Eur Respir J Off J Eur Soc Clin Respir Physiol* 1999;14:735–737.
- 13 Reich JM, Johnson RE: Course and prognosis of sarcoidosis in a nonreferral setting. Analysis of 86 patients observed for 10 years. *Am J Med* 1985;78:61–67.

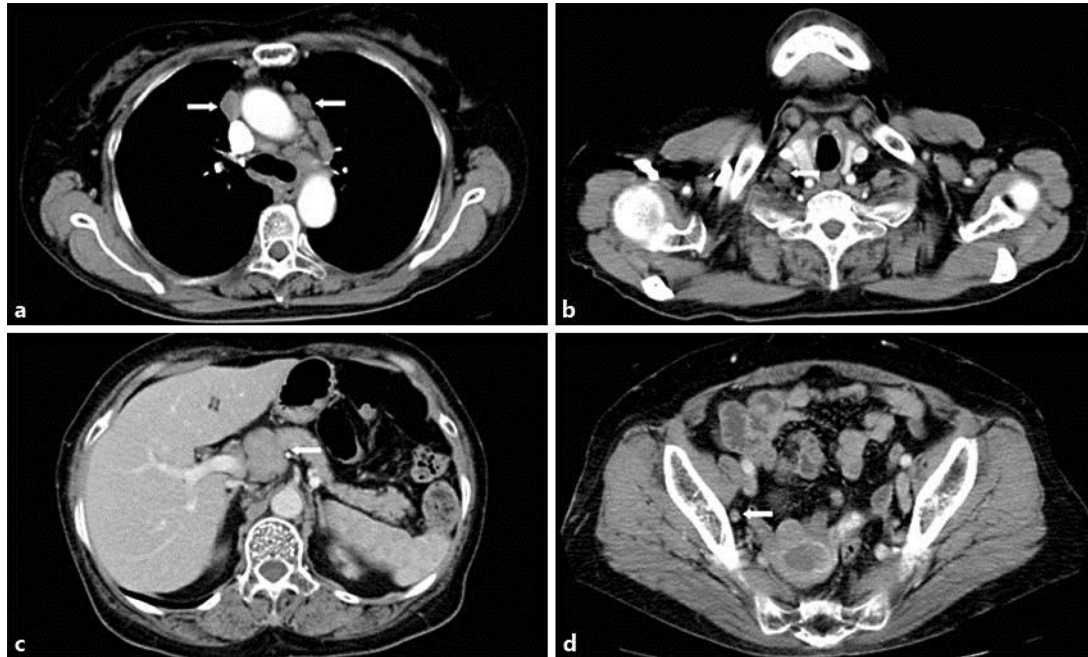


Fig. 1. CT findings of swollen lymph nodes. **a** Swelling of bilateral hilar lymph nodes (arrows). **b** Swelling of a right supraclavicular lymph node (arrow). **c** Swelling of a pancreatic head lymph node (arrow). **d** Swelling of a right pelvic lymph node (arrow).

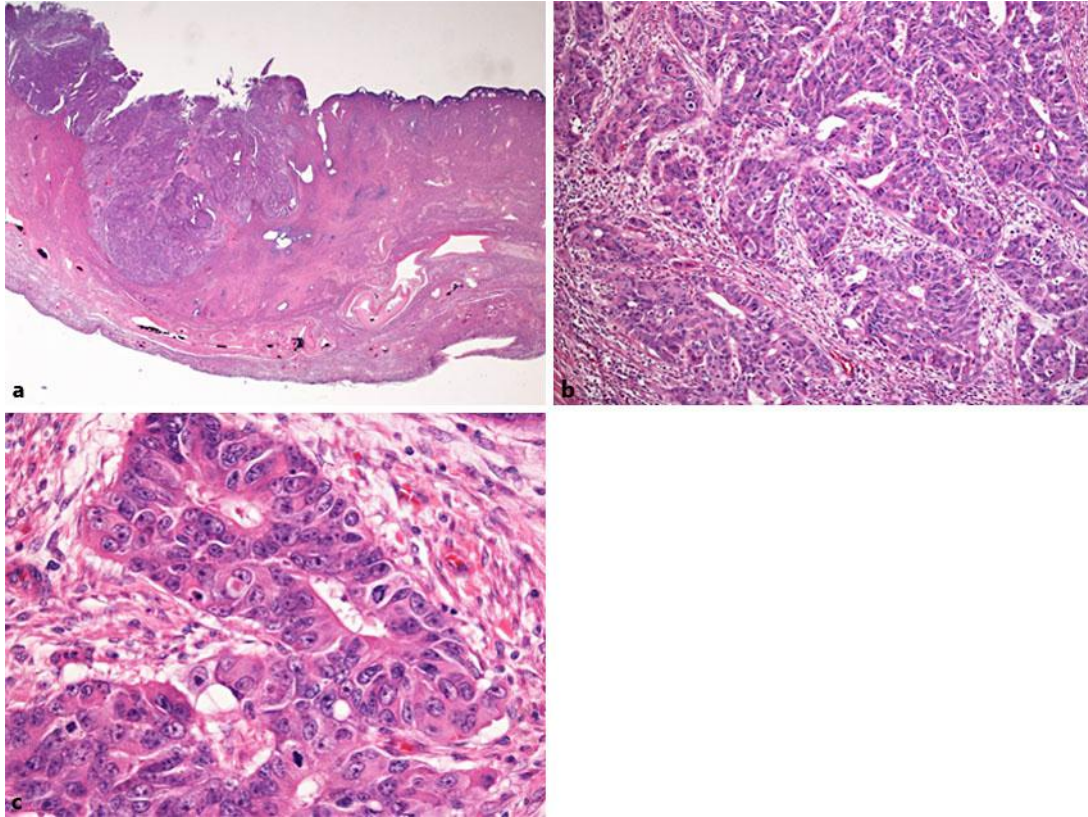


Fig. 2. Microscopic findings of the resected uterus. **a** More than 50% myometrial invasion was detected (hematoxylin and eosin stain, $\times 0.5$). **b, c** Moderately differentiated endometrioid adenocarcinoma (hematoxylin and eosin stain, **b** $\times 10$, **c** $\times 40$).

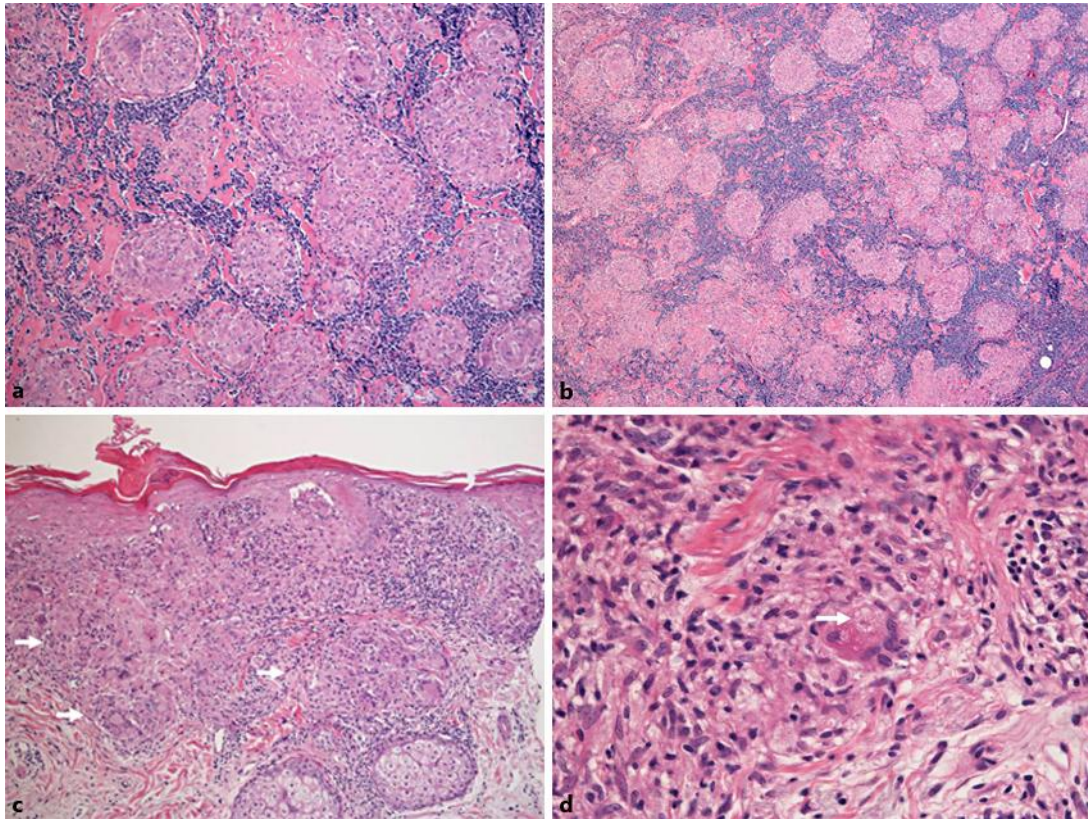


Fig. 3. Microscopic findings of the resected lymph nodes and the skin biopsy. **a** A right obturator lymph node with multiple noncaseating granulomas (hematoxylin and eosin stain, $\times 10$). **b** A paraaortic lymph node with multiple noncaseating granulomas (hematoxylin and eosin stain, $\times 4$). **c** Noncaseating granulomas (arrows) were observed under the epidermis (hematoxylin and eosin stain, $\times 10$). **d** An asteroid body (arrow) was observed under the epidermis (hematoxylin and eosin stain, $\times 40$).