

Postablation Right Atrial Dissection in Ebstein's Anomaly

Fatemat Hassan, MBBCh, Akash Patel, MD, Vadiyala Mohan Reddy, MD,
and Hythem Nawaytou, MBBCh, *San Francisco, California*

INTRODUCTION

Atrial dissection is a rare entity that has been described mainly in the left atrium.¹ The dissection usually occurs after a procedure, such as mitral valve surgery,² aortic valve surgery,³ percutaneous coronary intervention,⁴ and catheter-based or surgical arrhythmia ablation.⁵⁻⁸ Dissection has also been reported after trauma,⁹ myocardial infarction,¹⁰ and infective endocarditis.¹¹ There are reports of atrial dissection occurring without a known precipitating incident.¹² Here we present a case of right atrial dissection after ablation for incessant ventricular tachycardia in a patient with Ebstein's anomaly. The atrial dissection led to obstruction of tricuspid valve inflow and required emergent surgical intervention.

CASE PRESENTATION

A 6-year-old female patient with unrepaired Ebstein's anomaly presented with incessant ventricular tachycardia unresponsive to antiarrhythmic medications and cardioversion. Electrophysiologic mapping revealed two reentrant ventricular tachycardia pathways in the atrialized right ventricle adjacent to the tricuspid valve annulus. Initially 7-Fr small- and medium-curve catheters were trialed and were unable to reach the area of interest, so a large-curve radiofrequency ablation catheter was used to deliver energy to the basal lateral ventricle. Applications were delivered using a St. Jude Ampere generator (St. Jude Medical, St. Paul, MN), in temperature control mode. A total of 20 ablations lasting between 10 and 60 sec were delivered in the basal septal and basal lateral area of the atrialized right ventricle, with an average maximum temperature of 55°C and average maximum power of 49 W for a total of 627 sec with appropriate impedance change. The patient was successfully converted to sinus rhythm after the ablation with no recurrence of ventricular tachycardia. However, at the end of the procedure, she was noted to have multiple desaturation events that improved with inotropic support and blood transfusion. Transthoracic echocardiography (Figure 1, Video 1) was performed at the end of the procedure to investigate the underlying cause of the desaturation. It revealed what at that time was thought could be a fibrin strand or a thrombus that had formed over a catheter. The possibility of an intracardiac dissection was entertained, but because the patient was hemodynamically stable, no surgical intervention was recommended.

The patient was admitted to the cardiac intensive care unit for observation. Overnight she continued to have episodic desaturation

that progressed to persistent desaturation and hypotension. She also developed a right pleural effusion that required drainage. Further transthoracic echocardiographic imaging (Figure 2, Video 2) showed a hypoechoic, fluid-filled "cyst" in the atrialized right ventricle above the level of the tricuspid valve, with color Doppler showing flow around the fluid-filled cyst but not inside it. Agitated saline contrast (Figure 3, Video 3) showed contrast entering the cyst, thus indicating a direct communication with the cardiac cavity. The diagnosis of an atrial dissection was made. The dissection flap was obstructing the tricuspid valve inflow, resulting in decreased pulmonary blood flow and progressive hypoxemia with right-to-left shunting through an atrial septal defect.

The patient was taken emergently to the operating room, where transesophageal echocardiography confirmed the diagnosis (Figure 4, Video 4). A large hematoma within the wall of the atrialized right ventricle was found (Figure 5). There were two sites of ablation noted, with visible scarring in the vicinity of the dissection. Part of the tricuspid valve annulus was disrupted from the atrialized portion of the right ventricle, which is possibly where the dissection had started (Figure 6). The patient underwent hematoma evacuation, right atrial reduction with resection of the affected atrial tissue, partial atrial septal defect closure, and tricuspid annuloplasty. She recovered well postoperatively, with no further complications or arrhythmias.

DISCUSSION

This is the second report of right atrial dissection in the literature. The first was in an 18-year-old male patient who presented with tachycardia and dyspnea and was found to have an idiopathic right atrial dissection on surgical exploration.¹³ Left atrial dissection, on the other hand, is a known yet rare entity that develops because of blood entering through an area of necrotic tissue between the layers of the myocardium and forming a dissection tract.¹² To our knowledge, this is the first report of a dissection in the atrialized right ventricle in a patient with Ebstein's anomaly after catheter ablation. There are reports of atrial septal flap formation after transeptal approaches for ablations. These dissections do not cause hemodynamic compromise and resolve with conservative management.^{1,7,14} This case report, on the contrary, shows how an atrial dissection can be life threatening and rapidly progressive. Most previous reports used transesophageal echocardiographic imaging to diagnose these atrial dissections.¹⁵ In this case report we

From the Division of Cardiology, Department of Pediatrics (F.H., A.P., H.N.), and the Division of Cardiothoracic Surgery, Department of Surgery (V.M.R.), University of California, San Francisco, San Francisco, California.

Keywords: Ebstein's anomaly, Atrial dissection, Ablation, Echocardiography

Conflicts of interest: The authors reported no actual or potential conflicts of interest relative to this document.

Published by Elsevier Inc. on behalf of the American Society of Echocardiography. This is an open access article under the CC BY-ND-NC license (<http://creativecommons.org/licenses/by-nc-nd/4.0/>).

2468-6441

<http://dx.doi.org/10.1016/j.case.2017.08.004>

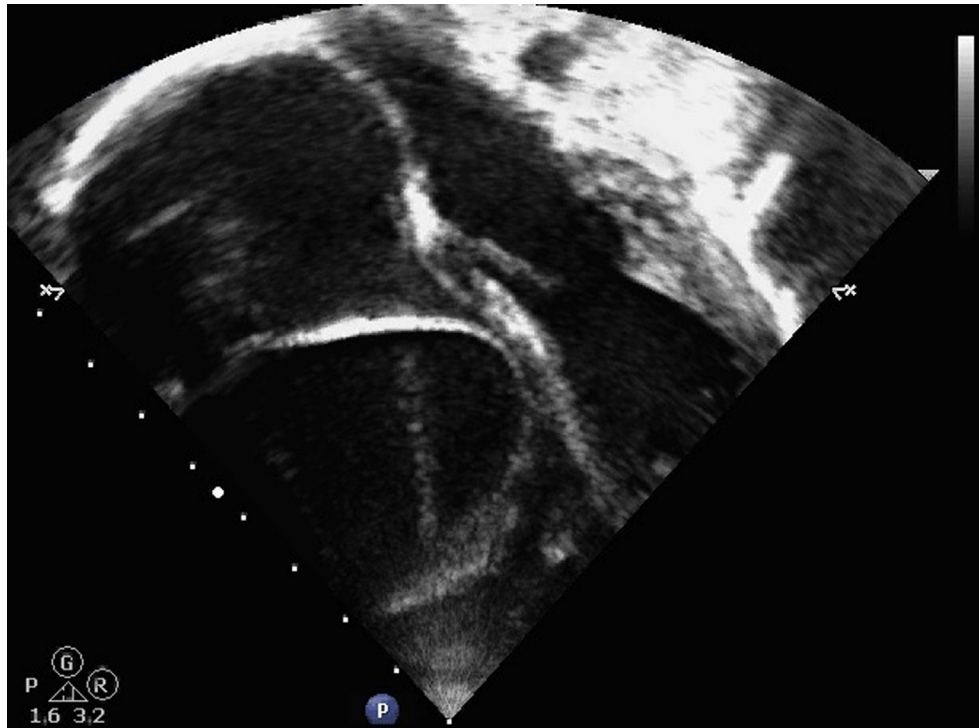


Figure 1 Transthoracic echocardiogram: apical four-chamber view showing the intramural hematoma/dissection flap in the atrialized right ventricle.

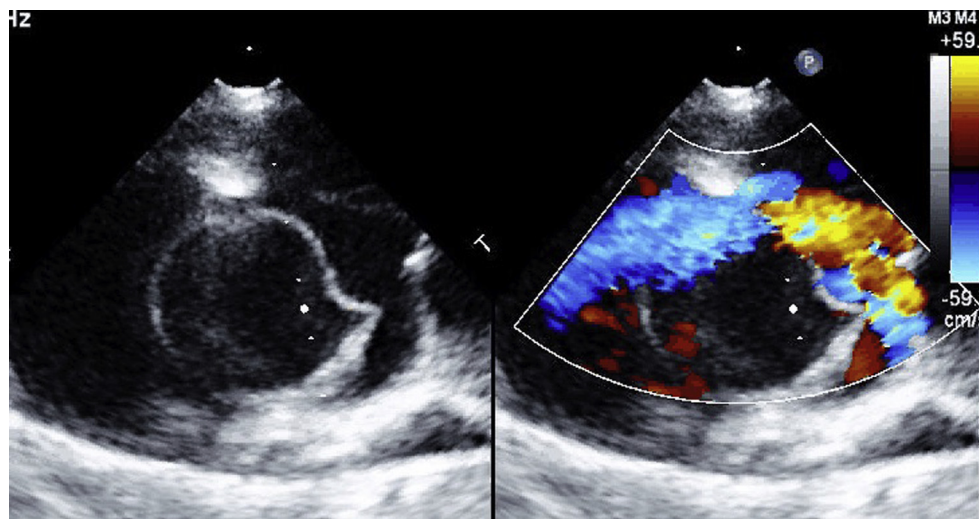


Figure 2 Transthoracic echocardiogram: short-axis view of the heart showing the intramural hematoma/dissection flap in the right atrium above the level of the tricuspid valve with simultaneous color Doppler demonstrating blood flow around the dissection but not inside it.

used transthoracic echocardiography with agitated saline contrast to make the diagnosis. Agitated saline contrast was helpful in showing a communication between the cavity of the dissection and the cardiac cavity. We speculate that the mechanisms of the dissection could be a partial wall thickness tear or separation of endocardial layers due to steam formation in the thin-walled

atrialized right ventricle. These mechanisms could be due to mechanical trauma and/or radiofrequency ablation of the thin-walled atrialized tissue. This report highlights the urgency of identifying this rare complication, the unique presentation due to the underlying anatomy, and the need for prompt referral for surgical management.

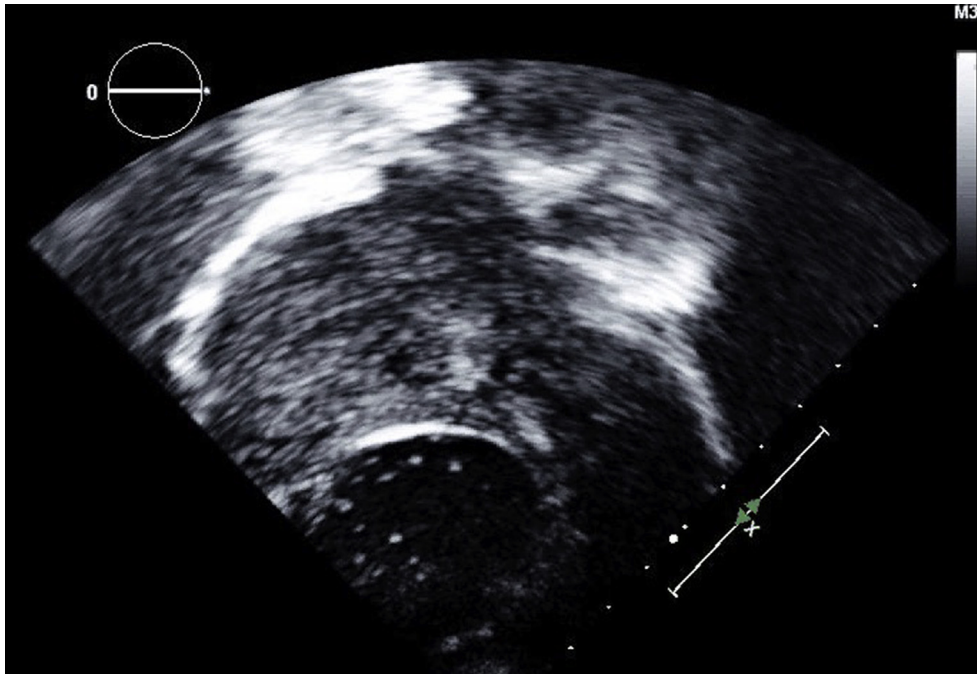


Figure 3 Transthoracic echocardiogram: apical four-chamber view with agitated saline contrast showing contrast entering the fluid-filled space enclosed within the dissection flap indicating direct communication with the cardiac cavity.

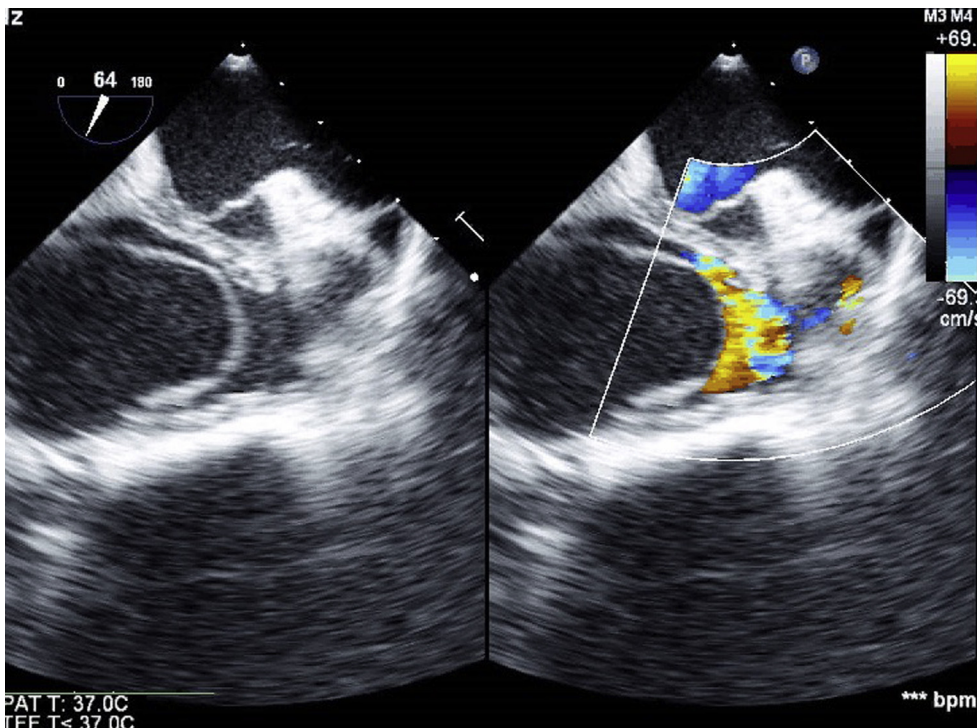


Figure 4 Transesophageal echocardiogram showing the intramural hematoma in the right atrium just above the level of the tricuspid valve interfering with tricuspid inflow.

CONCLUSION

Intracardiac dissection is a rare but potentially life-threatening complication of transcatheter ablations that can be identified with saline contrast transthoracic echocardiography.

SUPPLEMENTARY DATA

Supplementary data related to this article can be found at <https://doi.org/10.1016/j.case.2017.08.004>.

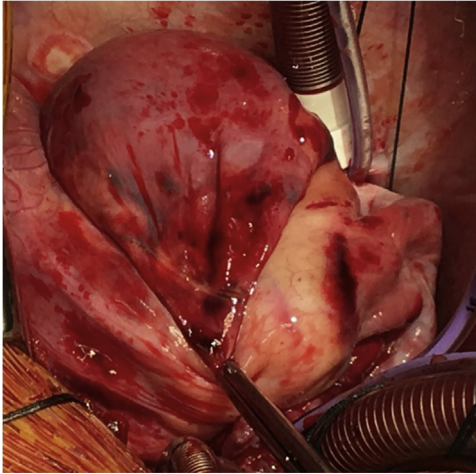


Figure 5 Intraoperative photograph showing the large intramural hematoma in the right atrium.

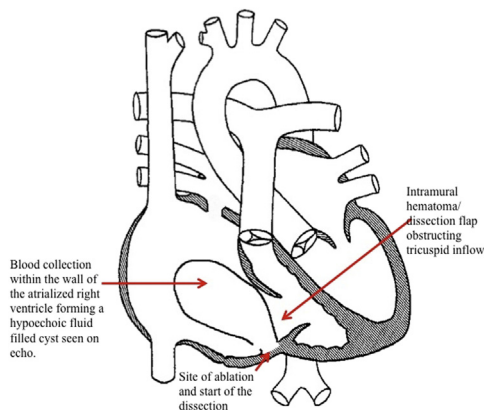


Figure 6 Diagram showing the possible site of break in endocardium and entry of blood between the layers of the atrial wall leading to formation of an atrial dissection. Atrial dissection obstructing the tricuspid valve inflow with right-to-left shunting possible through an atrial septal defect.

REFERENCES

1. Tsukui H, Iwasa S, Yamazaki K. Left atrial dissection. *Gen Thorac Cardiovasc Surg* 2015;63:434-45.
2. Naidu DP, Nigro J, Alboliras ET. Atrial septal hematoma after mitral valve and left coronary artery surgery in a child. *Pediatr Cardiol* 2013;34:2037-9.
3. Leissner KB, Srinivasa V, Beutler S, Matyal R, Badr R, Haime M, et al. Left atrial dissection and intramural hematoma after aortic valve replacement. *J Cardiothorac Vasc Anesth* 2011;25:309-10.
4. Cresce GD, Peluso D, Panfili M, Favaro A, Cannarella A, Picichè M, et al. Left atrial wall hematoma as a consequence of percutaneous coronary angioplasty. *Ann Thorac Surg* 2012;93:e57-9.
5. Ramakrishna G, Cote AV, Chandrasekaran K, Malouf JF. Endocardial flap of left atrial dissection following radiofrequency ablation. *Pacing Clin Electrophysiol* 2003;26:1771-3.
6. Echahidi N, Philippon F, O'Hara G, Champagne J. Life-threatening left atrial wall hematoma secondary to a pulmonary vein laceration: an unusual complication of catheter ablation for atrial fibrillation. *J Cardiovasc Electrophysiol* 2008;19:556-8.
7. Uçar O, Çiçekçiöğlü H, Diker E, Aydoğdu S. A rare complication of radiofrequency catheter ablation of left atrial tachycardia: atrial septal dissection and left atrial hematoma formation. *Türk Kardiyol Dern Ars* 2010;38:279-81.
8. Sah R, Epstein LM, Kwong RY. Images in cardiovascular medicine. Intramural atrial hematoma after catheter ablation for atrial tachyarrhythmias. *Circulation* 2007;115:e446-7.
9. Rowe SK, Porter CB. Atrial septal hematoma: two-dimensional echocardiographic findings after blunt chest trauma. *Am Heart J* 1987;114:650-2.
10. Kovacic JC, Horton MDA, Campbell TJ, Wilson SH. Left atrial hematoma complicating inferior myocardial infarction. *J Am Soc Echocardiogr* 2004;17:1201-3.
11. Osawa H, Saitoh T, Sugimoto S, Takagi N, Abe T. Dissection of intima on atrial septum patch after mitral valve replacement in a patient with infective endocarditis after incomplete atrio-ventricular septal defect repair: report of a case. *Ann Thorac Cardiovasc Surg* 2004;10:124-5.
12. Gallego P, Oliver JM, González A, Domínguez FJ, Sanchez-Recalde A, Mesa JM. Left atrial dissection: pathogenesis, clinical course, and transesophageal echocardiographic recognition. *J Am Soc Echocardiogr* 2001;14:813-20.
13. Song L, Wang B, Tao L. Spontaneous right atrial dissection resulting in tricuspid regurgitation. *Rev Esp Cardiol (Engl Ed)* 2016;69:606.
14. Fukuhara S, Dimitrova KR, Geller CM, Hoffman DM, Ko W, Tranbaugh RF. Left atrial dissection: etiology and treatment. *Ann Thorac Surg* 2013;95:1557-62.
15. Kumar GA, Nandakumar NM, Sudhir BV, Pasarad AK. Role of transesophageal echocardiography: a rare case of acute left atrial free wall dissection. *Ann Card Anaesth* 2015;18:593-5.