




Contents lists available at ScienceDirect

JPRAS Open

journal homepage: www.elsevier.com/locate/jpra



Case Report

Digital artery perforator flap transfer for volar soft tissue defect due to dissociation from joint contracture in camptodactyly

Yukiko Morimoto*, Yusuke Sogabe, Akira Kawabata, Kiyohito Takamatsu

Department of Orthopaedic Surgery, Yodogawa Christian Hospital, 1-7-50 Kunizima, Higashiyodogawa-ku, Osaka 533-0024, Japan

ARTICLE INFO

Article history:

Received 15 September 2020

Accepted 26 November 2020

Available online 30 November 2020

Keywords:

Camptodactyly

Contracture

Flap

Perforator

Digital artery

Surgery

ABSTRACT

Camptodactyly is a condition defined by persistent flexion contracture of the proximal interphalangeal joints of the hand. Surgical treatment requires flaps for the dissection of the skin and the resulting soft tissue defect, soft tissue release, and sometimes reconstruction of the extension mechanism. Z-plasty and transposition flap have been reported as methods used in soft tissue defects. In this case, covering the defects of the digits was necessary for keeping the wound clean; thus, we should select a surgical method that facilitates stable and reliable blood flow of the flap. The digital artery perforator flap is pedicled and its transfer does not require the dissection of neurovascular bundles; therefore, it can be used safely and relatively easily. We considered the digital artery perforator flap to be a useful technique in terms of securing stable and reliable blood flow and not twisting the skin. Thus, we performed a digital artery perforator flap transfer for a volar soft tissue defect due to dissociation from proximal interphalangeal joint contracture in camptodactyly.

© 2020 The Authors. Published by Elsevier Ltd on behalf of British Association of Plastic, Reconstructive and Aesthetic Surgeons. This is an open access article under the CC BY-NC-ND license (<http://creativecommons.org/licenses/by-nc-nd/4.0/>)

* Corresponding author.

E-mail address: cherryblossom_guerlain@yahoo.co.jp (Y. Morimoto).

Background

Camptodactyly is a condition defined by a persistent flexion contracture of the proximal interphalangeal (PIP) joints of the hand and can be treated either conservatively, surgically, or in combination. We performed surgical treatment using digital artery perforator (DAP) flap for volar soft tissue defect due to dissociation from PIP joint contracture in camptodactyly.

Case report

Camptodactyly of the bilateral little fingers was detected in a 4-year-old boy with Coffin-Siris syndrome, growth disorder, and mental retardation at around 3 years. Though he had been undergoing rehabilitation, his little fingers were very small and orthotic treatment was difficult. As flexion contracture gradually progressed and thinning skin was observed on the back of the PIP joint due to protrusion of the proximal phalanx head, it was decided that he would undergo bilateral surgery of the little fingers. Before the procedure, the active and passive extension of the little finger PIP joints on both sides were -110° and -90° , respectively (Fig. 1). For bilateral camptodactyly, we performed volar skin incision of the PIP joint, dissection of the flexor digitorum superficialis (FDS) tendon, release of the volar plate, and dissection of the accessory collateral ligament. As a result of the procedure, passive extension was 0° on both sides. However, the skin defect occurred on the volar side of the PIP joint due to contracture dissection and extension of the PIP joint.

After the PIP joint had been temporarily fixed at 40° flexion using 0.7 mm wire, we transferred the DAP flaps for the skin defect. Preoperatively, the localization of the perforator from the digital artery was confirmed by ultrasound sonography at the proximal of the PIP joint. The DAP flap on the ulnar side of the proximal phalanx was shaped like a spindle with the same size as the soft tissue defect. When elevating the flap, the neurovascular bundle was removed from the proximal fat, and care was taken to remove as little fat as possible from the skin.

The distal part of the flap was the only skin incision made due to perforator inclusion. It was confirmed under microscopy that the flap included the perforator from the digital artery. The flap size was 4 mm wide and 14 mm long at the right side, and 4 mm wide, and 12 mm long at the left side. The flaps were rotated 90° around the perforator and transferred to the defect. Only then was the skin of the flaps sutured and the donor sites were linearly closed (Fig. 2). Because of the boy's mental status, soft casts were wrapped around each hand postoperatively in order to protect the wound and keep it clean. The casts were removed 3 weeks after surgery simultaneously with the wires that had temporarily fixed the PIP joint. Complications such as the skin necrosis or flap contraction were not observed during follow-up.

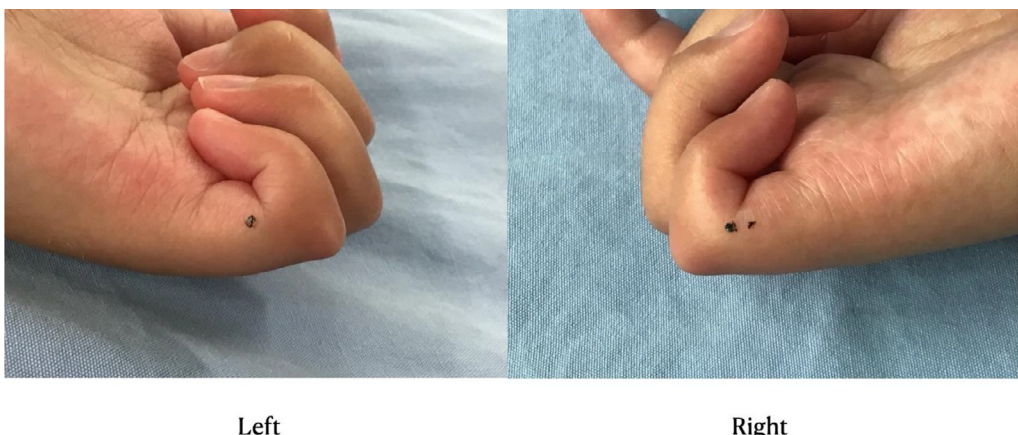


Fig. 1. At preoperative rest position, flexion contractures on bilateral little finger.

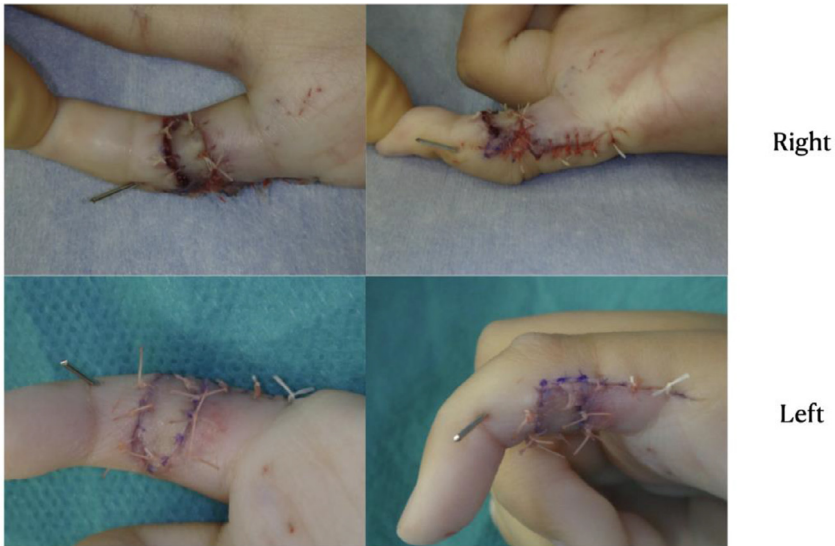

Fig. 2. The PIP joint was temporarily fixed into place and DAP flaps were transferred.

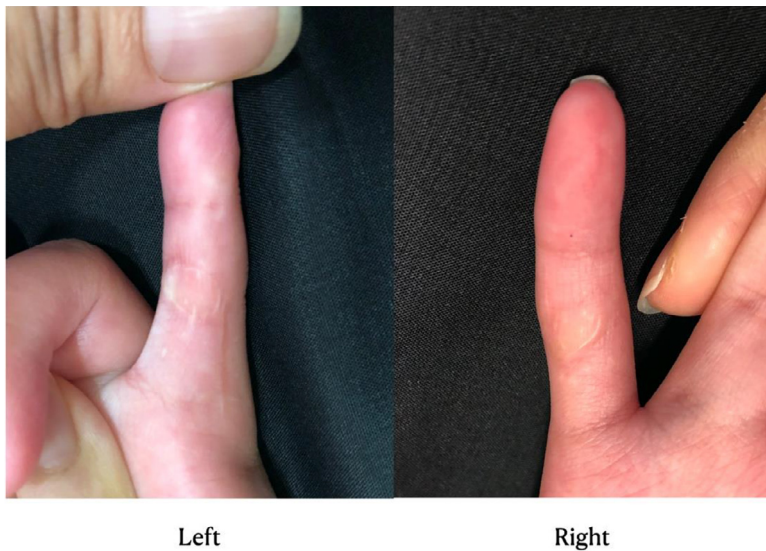

Fig. 3. There was no skin pigmentation or contraction of the flaps.

Recurrence of flexion contracture of the PIP joint was observed on both sides 1 year after surgery, with active and passive extension of the little finger at -50° and -20° , respectively. There was no skin pigmentation or contraction of the flaps, which were pliable and showed good color (Fig. 3).

Discussion

Camptodactyly is an atraumatic flexion deformity of the PIP joint often caused by congenital disease. The PIP joints of the little fingers are most commonly affected.¹

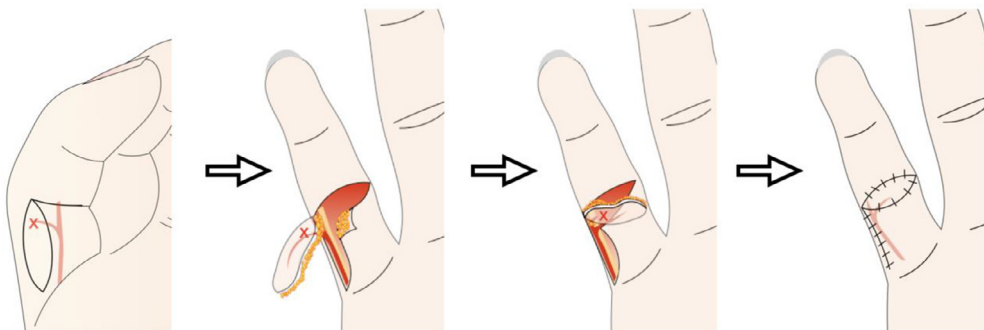


Fig. 4. DAP flap procedure for a volar soft tissue defect after dissociation for the contracture of the proximal interphalangeal joint.

Different authors have suggested various reasons for the primary cause of camptodactyly. Although conservative therapy is effective for camptodactyly with mild contracture, Siegert et al. recommended surgery in cases whereby the contracture is more than 60°.² Surgical treatment requires flaps for the contracture dissection of the skin and resulting soft tissue defect, soft tissue release, and sometimes reconstruction of the extension mechanism.³

There are reported that the skin is 100%, a short FDS tendon and tendon sheath is 67%, and retinaculum cutis is 56% as structures involved in patients with camptodactyly.⁴ Skin contracture dissection and flap transfer are considered to be almost essential in treating such soft tissue defects. There are reports of Z-plasty and transposition flap as methods of flap transfer in such cases.^{5,6}

In this case, covering the defects of the digits was necessary for keeping the wound clean; thus, we should select a surgical method that facilitates stable and reliable blood flow of the flap. Using the DAP flap as a technique for fingertip reconstruction was described by Koshima et al.⁷ Since this is a pedicled flap that does not require the neurovascular bundles to be dissected, surgery can be performed safely and relatively easily. DAP flaps can also be used for back, lateral, and palm lateral skin defects.^{7,8} In this case, the skin defect was on the volar side of the PIP joint and a spindle-shaped flap was created on the ulnar side of the proximal phalanx. Elevated flaps were rotated 90° around the perforator and transferred to the defects. Surgical scarring is unlikely to occur because the incision went along the skin line at the PIP joint. The spindle-shaped flap also closely matched the shape of the soft tissue defect after the contracture dissection (Fig. 4). Although the transposition flap typified by the digitolateral flap has similar skin lines, it takes a random-pattern that moves away from the distal pedicle and causes twisting in this area; thus, the DAP flap is considered to be a useful technique in terms of securing stable and reliable blood flow and not twisting the skin.

In this case, it was necessary to cover the fingers to keep the wound clean postoperatively. The flap was grafted without causing complications such as flap congestion and necrosis, and a favorable course was observed.

To our knowledge, this is the first report of tissue defects on the volar side of the PIP joint due to dissociation from PIP joint contracture in camptodactyly being covered with DAP flaps.

Conclusion

This report describes a case in which DAP flap transfer was used for soft tissue defect on the volar side of the PIP joint due to dissociation from joint contracture in camptodactyly. The postoperative course was favorable, and it should be considered to be a useful surgical method.

Funding

None.

Declaration of Competing Interest

The authors have no financial or other interests to disclose.

References

1. Benson LS, Waters PM, Kamil NI, et al. Camptodactyly: classification and results of nonoperative treatment. *J Pediatr Orthop*. 1994;14:814–819.
2. Sigert JJ, Cooney WP, Cobyns JH. Management of simple camptodactyly. *J Hand Surg Br*. 1990;15:181–189.
3. Foucher G, Lorea P, Khoouri RK. Camptodactyly as a spectrum of congenital deficiencies: a treatment algorithm based on clinical examination. *Plast Reconstr Surg*. 2006;117:1897–1905.
4. Smith PJ, Grobelaar AO. Camptodactyly: a unifying theory and approach to surgical treatment. *J Hand Surg Am*. 1998;23:14–19.
5. Evans BT, Waters PM, Bae DS. Early results of surgical management of camptodactyly. *J Pediatr Orthop*. 2017;37:e317–e320.
6. Hamilton KL, Netscher DT. Evaluation of a stepwise surgical approach to camptodactyly. *Plast Reconstr Surg*. 2015;135:568e–576e.
7. Koshima I, Urushibara K, Fukuda N, et al. Digital artery perforator flaps for fingertip reconstructions. *Plast Reconstr Surg*. 2006;118:1579–1584.
8. Usami S, Inami K, Hirase Y. Coverage of the dorsal surface of a digit based on a pedicled free-style perforator flap concept. *J Plast Reconstr Aesthet Surf*. 2018;71:863–869.