JPRAS Open 39 (2024) 191–197

Contents lists available at ScienceDirect

JPRAS Open

journal homepage: www.elsevier.com/locate/jpra

Case Report

Provisional resection of the nutrient artery in free anterolateral thigh flap debulking surgery ☆

Yuta Izawa*, Hiroko Murakami, Kazuo Sato, Yoshihiko Tsuchida

Department of Orthopaedic Trauma Center, Sapporo Higashi Tokushukai Hospital, Kita 33 Jou Higashi 14 chome 3-1, Higashiku, Sapporo, Hokkaido, Japan

ARTICLE INFO

Article history:
Received 19 November 2023
Accepted 16 December 2023
Available online 23 December 2023

Keywords:
Open fracture
Free anterolateral thigh flap
Debulking surgery
Flap necrosis
Provisional resection

ABSTRACT

Fix and flap surgery is the standard treatment for severe open-limb fractures. In cases of complex injuries, secondary surgeries such as additional osteosynthesis, implant removal, bone grafting, and debulking surgery may be required after the soft tissue condition has stabilized. During secondary surgery, if the nutrient vessels of the flap are resected haphazardly and an additional procedure is performed, flap necrosis may occur owing to insufficient blood flow. Creating a hemodynamic system that can withstand secondary surgery through increasing blood flow surrounding the flap is necessary in preventing necrosis. We report a case in which “provisional resection” of the nutrient artery was performed prior to the debulking surgery of a free anterolateral thigh flap.

A 45-year-old man sustained an extensive degloving injury on the dorsum of the hand during a car accident. On the fifth day after injury, soft tissue reconstruction with a free anterolateral thigh flap was performed. Although the soft tissue condition was stable, debulking surgery was planned 4 months after the injury because of the thickness of the flap. Flap necrosis may occur if the nutrient artery was resected and debulking surgery was performed simultaneously. Therefore, staged surgery using “provisional resection” of the nutrient artery was selected. First, the nutrient artery was resected. After waiting for 1 week, skin graft removal and flap thinning were performed as the second step. No flap necrosis was observed.

☆ This manuscript has not been presented, either partially or in its entirety, at any meeting.

* Corresponding author at: Department of Orthopaedic Trauma Center, Sapporo Higashi Tokushukai Hospital, Kita 33 Jou Higashi 14 chome 3-1, Higashiku, Sapporo, Hokkaido, Japan.

E-mail address: yutaizawa18@gmail.com (Y. Izawa).

https://doi.org/10.1016/j.jpra.2023.12.013

"Provisional resection" changes the hemodynamics of the flap to a random pattern due to the delay phenomenon and can prevent flap necrosis caused by secondary surgeries, such as debulking surgery.

Introduction

Fix and flap surgery for severe open-limb fractures is the standard treatment.[1,2] In cases of complex injuries, secondary surgeries such as additional osteosynthesis, implant removal, bone grafting, and debulking surgery may be required after soft tissue stabilization. In most cases, when performing secondary surgery, the flap is peeled off from the margins. During secondary surgery, if the nutrient vessels of the flap are resected haphazardly and an additional procedure is performed, necrosis may occur owing to insufficient blood flow to the flap. Creating a hemodynamic system that can withstand secondary surgery by increasing surrounding blood flow is necessary in preventing flap necrosis.

We hypothesized that flap necrosis could be prevented by applying the concept of stepwise dissection used for distant flaps and performing "provisional resection" of the nutrient artery. We report a case in which "provisional resection" of the nutrient artery was performed prior to debulking surgery of a free anterolateral thigh (ALT) flap.

Methods

The surgical procedure for "provisional resection" of the nutrient artery is as follows: First, the secondary surgery approach is planned. "Provisional resection" is performed only when an effective operation can be achieved by resecting nutrient artery of the flap. If the operation can be performed effectively even if the nutrient artery is left in place, the artery is not intentionally resected. Before surgery, enhanced computed tomography (CT) is performed to confirm whether the nutrient artery of the flap remained intact. In the first stage of the secondary surgery, the edge of the flap is partially incised to secure the nutrient artery. Blood circulation in the flap is assessed by blocking the nutrient artery using vascular clips. If the flap maintains adequate blood circulation, it can survive with blood flow from the recipient bed and surrounding tissue. In such cases, the nutrient artery is resected, and the wound is roughly closed. However, if the blood circulation of the flap becomes unstable because of interruption by the vascular clip, the clip is reapplied every few days. Blood flow of the flap can be "trained" by gradually increasing the duration of interruption using the vascular clip. This procedure is repeated until the blood circulation of the flap became stable, even when blood flow is restricted. Finally, the nutrient artery of the flap is resected. A 1-week waiting period is set after the resection of the nutrient artery. During this waiting period, blood flow from the surrounding tissue increases and hemodynamics that can withstand secondary surgery are established. In the second stage of secondary surgery, the skin flap is peeled off the margins; additional surgeries such as osteosynthesis, bone grafting, and debulking surgery are performed, and the wound is closed with absorbable sutures.

Case presentation

A 45-year-old man was transported to our hospital after being injured in a car accident. There was an extensive degloving injury to the dorsum of the hand and the extensor tendons were exposed. This was accompanied by a distal phalanx fracture of the thumb and second, fourth, and fifth metacarpal fractures. On the fifth day after the injury, osteosynthesis of the metacarpal fractures and soft tissue reconstruction with a free ALT flap were performed. The radial artery at the snuff box was selected as the recipient and end-to-end anastomosis was performed using the perforator of the de-

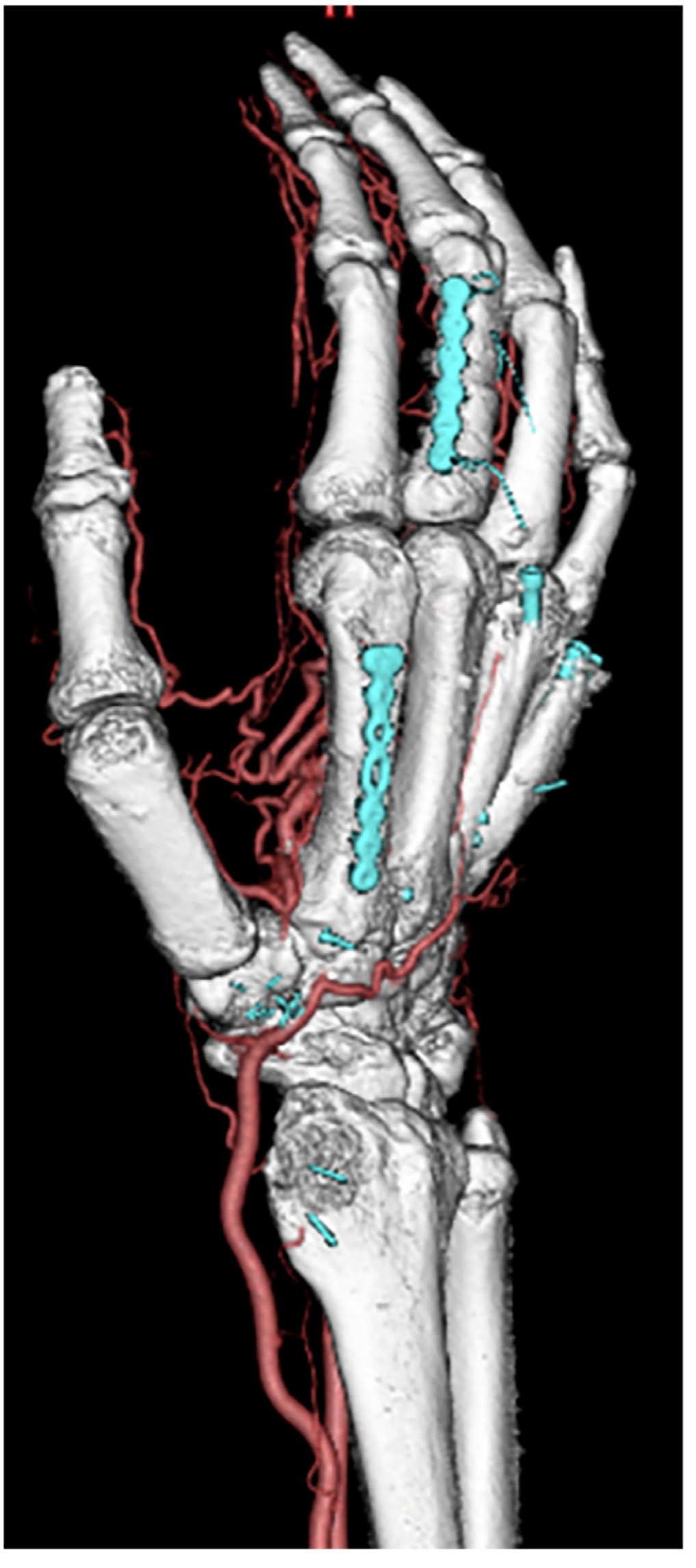

Figure 1. Enhanced CT before secondary surgery. The anastomosed perforator, which was the nutrient artery of the flap, is visible.

scending branch of the lateral circumflex femoral artery. Full-thickness skin grafting was performed on the remaining skin defect on the 25th day after injury. Although the soft tissue condition was stable, debulking surgery was planned 4 months after the injury because of the thickness of the flap. The plan was to completely remove the skin graft area on the dorsal side of the wrist, make the flap as thin as possible the, and close the wound. Peeling off the flap from the proximal and radial margin was thought to be effective. In addition, we determined that thinning of a wider area of the flap could be achieved by resecting the anastomotic perforator. By performing the planned approach, it was predicted that the most of the blood flow of the flap would depend on blood flow from the surrounding tissues on the ulnar and distal sides. Enhanced CT was performed before surgery, and the anastomosed perforator was visualized (Figure 1). Flap necrosis may have occurred if the perforators,

Figure 2. Appearance after "provisional resection" as the first step of the secondary surgery. An incision was made directly above the nutrient artery. Nutrient artery was resected and the wound was roughly closed.

which were the nutrient arteries, were resected, and debulking surgery was performed simultaneously. Therefore, staged surgery using "provisional resection" of the nutrient artery was selected. First, an incision was made directly above the nutrient artery to secure it. Even when the nutrient artery was blocked with a vascular clip, the blood flow of the flap remained stable; therefore, the nutrient artery was resected and the wound was roughly closed (Figure 2). Following surgery, enhanced CT confirmed that the perforator was not visible (Figure 3). After 1 week, skin graft removal and flap thinning were performed as the second step. The skin flap was peeled off from the radial and proximal margin by extending the initial surgical incision. Most areas of the flap were peeled off from the recipient bed, leaving continuity with the surrounding tissue on the ulnar and distal sides. While checking blood circulation, fat was removed to make the flap as thin as possible. After achieving sufficient hemostasis, the wound was closed using absorbable sutures (Figure 4). Flap necrosis or wound complications were not observed.

Discussion

Severe open-limb fractures require covering of the injured area with soft tissue with abundant blood flow. Thin flaps such as the ALT and groin flaps are often used to treat hand injuries. However, the grafted flaps are thicker in obese patients. Primary thinning of the ALT flap has been reported

Figure 3. Enhanced CT after "provisional resection". The nutrient artery of the flap could not be visualized.

to cause vascular complications in 13.4% of the cases and is not recommended, especially in Western patients.[3-5] Therefore, debulking surgery may be necessary from a cosmetic or functional perspective after the soft-tissue condition has stabilized. Resection of the nutrient artery may result in a more effective debulking flap, depending on the arrangement of the flap and blood vessels. However, flap necrosis may occur if the nutrient artery is resected haphazardly. Therefore, evaluating whether the flap can survive is necessary even if the nutrient artery is resected and reducing the possibility of flap necrosis is required.

The transplanted flap receives blood circulation from the recipient bed and surrounding tissue through neovascularization and angiogenesis. Neovascularization describes, de novo formation of blood vessels from endothelial progenitor cells; a process that does not rely on sprouting from existing vessels. Angiogenesis is defined as new blood vessel formation via sprouting from preexisting vessels. Yoon et al. reported that after free flap surgery, neovascularization and angiogenesis occur as early as 6 days, and flap may survive even if the nutrient vessels are ligated 12 days after surgery.[6] However, a case has been reported involving flap necrosis due to nutrient artery injury several months after free-flap transplantation.[7-8] Therefore, evaluating whether the flap can survive

Figure 4. Appearance after debulking surgery as the second step of the secondary surgery. The skin flap was peeled off the from radial and proximal sides, skin graft was removed, and flap was thinned. No flap necrosis or wound complications occurred.

is necessary even if the nutrient artery is resected. In our case, the nutrient artery was blocked with a vascular clip and the artery was resected after confirming that the flap could survive only with blood flow from the recipient bed and surrounding tissue. By waiting for 1 week after "provisional resection", increasing blood flow into flap due to the delay phenomenon was expected. It has been proven that angiogenesis is promoted by the delay phenomenon, resulting in the inflow of blood vessels from the surrounding tissue, expansion of blood vessel diameter, and increase in blood flow velocity.[9,10] As a result, the hemodynamics of the flap change to a random pattern, and necrosis can be prevented even when deep dissection and debulking surgery are performed. Additionally, vascularization of the skin flaps is generally superior to that of muscle flaps. Therefore, the risk of flap necrosis due to resection of nutrient artery is high in muscle flaps. The delay phenomenon obtained by provisional resection may be more effective in debulking muscle flaps. This technique is applicable not only to debulking surgery but also to all secondary surgeries, such as osteosynthesis and bone grafting.

Conclusion

We reported a case in which "provisional resection" of the nutrient artery was performed prior to debulking surgery for free ALT. "Provisional resection" results in a change in the hemodynamics of the flap to a random pattern and can prevent necrosis caused by secondary surgeries such as debulking surgery.

Informed consent

Informed consent was obtained from the patient in this study.

Ethical approval

Not required.

Declaration of competing interest

None.

Funding

This study did not receive any specific grants from funding agencies in the public, commercial, or non-profit sectors.

Acknowledgements

None.

References

1. Godina M. Early microsurgical reconstruction of complex trauma of the extremities. *Plast Reconstr Surg*. 1986;78(3):285–292. doi:10.1097/00006534-198609000-00001.
2. Gopal S, Majumder S, Batchelor AG, Knight SL, De Boer P, Smith RM. Fix and flap: the radical orthopaedic and plastic treatment of severe open fractures of the tibia. *J Bone Joint Surg Br*. 2000;82(7):959–966. doi:10.1302/0301-620x.82b7.10482.
3. Alkureishi LWT, Shaw-Dunn J, Ross GL. Effects of thinning the anterolateral thigh flap on the blood supply to the skin. *Br J Plast Surg*. 2013;56(4):401–408.
4. Sharabi SE, Hatef DA, Koshy JC, Jain A, Cole PD, Hollier Jr LH. Is primary thinning of the anterolateral thigh flap recommended? *Ann Plast Surg*. 2010;65(6):555–559. doi:10.1097/SAP.0b013e3181cbfebc.
5. Agostini T, Lazzeri D, Spinelli G. Anterolateral thigh flap thinning: techniques and complications. *Ann Plast Surg*. 2014;72(2):246–252. doi:10.1097/SAP.0b013e31825b3d3a.
6. Yoon AP, Jones NF. Critical time for neovascularization/angiogenesis to allow free flap survival after delayed postoperative anastomotic compromise without surgical intervention: a review of the literature. *Microsurgery*. 2016;36(7):604–612. doi:10.1002/micr.30082.
7. Fisher J, Wood MB. Late necrosis of a latissimus dorsi free flap. *Plast Reconstr Sur*. 1984;74(2):274–281. doi:10.1097/00006534-198408000-00018.
8. Sadove RC, Kanter MJ. Absent neovascularization in a lower extremity free flap: a case report. *J Reconstr Microsurg*. 1993;9(1):5–9. doi:10.1055/s-2007-1006632.
9. Du Z, Zan T, Li H, Li Q. A study of blood flow dynamics in flap delay using the full-field laser perfusion imager. *Microvasc Res*. 2011;82(3):284–290. doi:10.1016/j.mvr.2011.09.010.
10. Hamilton K, Wolfswinkel EM, Weathers WM, et al. The delay phenomenon: a complication of knowledge across specialties. *Craniomaxillofac Trauma Reconstr*. 2014;7(2):112–118. doi:10.1055/s-0034-1371355.