

***Gordonia bronchialis*–Associated Endophthalmitis, Oregon, USA**

Rene Choi, Luke Strnad, Christina J. Flaxel, Andreas K. Lauer, Eric B. Suhler

Author affiliations: Casey Eye Institute, Portland, Oregon, USA (R. Choi, C.J. Flaxel, A.K. Lauer, E.B. Suhler); Oregon Health and Science University, Portland (L. Strnad); Veterans Administration Portland Health Care System, Portland (E.B. Suhler)

DOI: <https://doi.org/10.3201/eid2505.180340>

Gordonia bronchialis is an aerobic actinomycetes that rarely causes infections in humans. Few reports describe *Gordonia* spp. causing eye-related infections. We report a case of chronic infectious endophthalmitis in Oregon, USA, associated with infection by *G. bronchialis*.

Gordonia bronchialis is an aerobic bacteria that rarely causes infections in humans. We report a case of chronic infectious endophthalmitis caused by infection with *G. bronchialis*.

A 63-year-old woman was referred to a uveitis service in Portland, Oregon, USA, because of a 10-month history of decreased vision in the left eye caused by 3 recurrences of anterior and intermediate uveitis that was refractory to topical corticosteroids. Her ocular history included cataract

surgery with intraocular lens implants placed bilaterally 2.5 years before symptom onset. Her medical history included chronic obstructive pulmonary disease, diabetes mellitus type 2, and hypertension. A complete review of systems, including fevers, chills, night sweats, weight loss, or history of contacts with ill persons, was unremarkable.

Her visual acuity was 20/20, and she had hand motion vision at 2 feet in the right and left eyes. No afferent pupillary defect was appreciated, and intraocular pressures were normal bilaterally. In the left eye, anterior segment examination showed 4+ anterior chamber cell with a hypopyon and a diffuse white granular sheet along the posterior face of the intraocular lens implant. Visualization of the left fundus was precluded by 4+ vitreous cell and haze. B-scan ultrasonography showed extensive vitreous opacities and an attached retina (Figure).

Laboratory test results were negative for rapid plasma reagin, fluorescent treponemal antibody absorption, tuberculosis (Quantiferon-Gold TB; Quest Diagnostics, <https://www.questdiagnostics.com>), angiotensin-converting enzyme, rheumatoid factor, antinuclear antibody, and human leukocyte antigen B27. We obtained standard results for a complete blood count with differential counts, erythrocyte sedimentation rate, complete metabolic panel, and chest radiography.

The patient was given a diagnosis of presumptive chronic infectious endophthalmitis and underwent a pars plana vitrectomy and intraocular lens implant removal of the left eye. A vitreous sample was sent for pan-culture, cytologic analysis, flow cytometry, and broad-range PCR

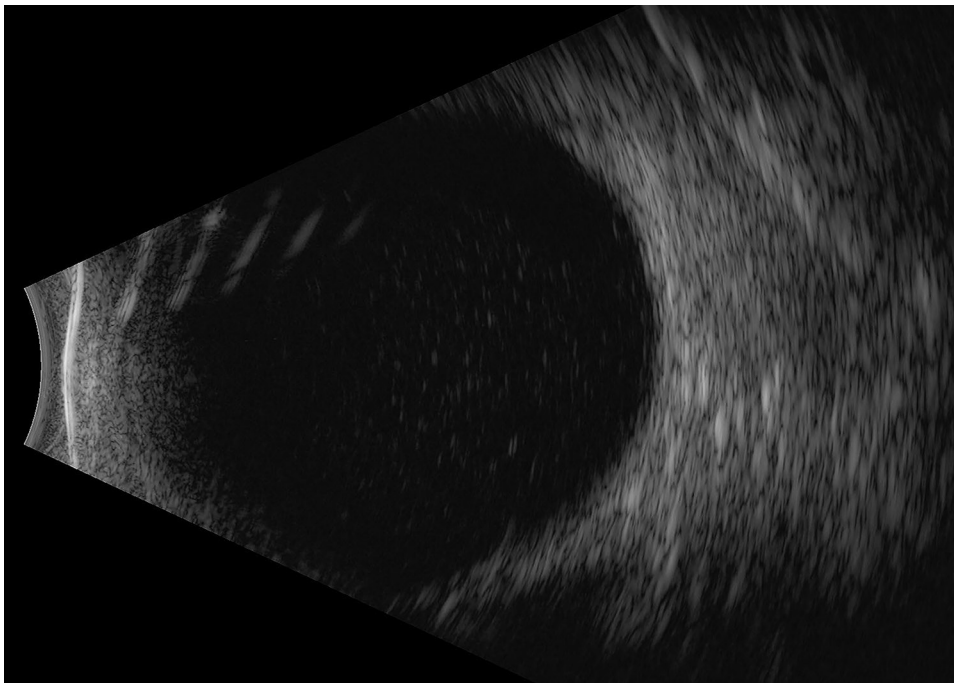


Figure. B-scan ultrasonography of the left eye of a 63-year-old woman with *Gordonia bronchialis*–associated endophthalmitis, Oregon, USA, showing dense opacities in the vitreous space.

analyses with 16S rRNA gene sequencing. Results of cytology analysis and flow cytometry were negative for neoplastic processes. Culture analysis showed gram-positive bacilli but did not identify the species.

The 16S rRNA gene sequencing yielded positive results for *G. bronchialis*. We confirmed the bacterium to be *G. bronchialis* by using matrix-assisted laser desorption/ionization time-of-flight mass spectrometry. Antimicrobial susceptibility testing showed favorable MICs for amikacin, ceftriaxone, amoxicillin/clavulanic acid, and ciprofloxacin. Subsequently, the patient was treated with an intravitreal injection of 400 µg of amikacin to the left eye.

Two weeks after this intervention, visual acuity had improved to 20/100 in the left eye and ocular inflammation had resolved. However, 3 weeks later, the patient returned because of worsening symptoms, hand motion vision, and severe symptomatic recurrent anterior chamber and vitreous inflammation in the left eye. Intravitreal ceftazidime (2.25 mg) was administered to the left eye, and a 21-day course of oral moxifloxacin (400 mg/d) was prescribed. One week after completing her moxifloxacin regimen, her symptoms had improved, her best corrected visual acuity had improved to 20/40 in the left eye, and intraocular inflammation had resolved.

Gordonia spp. are gram-positive, weakly acid-fast aerobic actinomycetes that are ubiquitous in the environment; 29 species have been identified (1). Human infections are rare, although a few case reports of sternal wound infections, bloodstream and intravascular catheter related infections, and skin abscesses have been published (2). Optimal antimicrobial drug treatment for infection with *Gordonia* spp. is unknown. However, the organisms are generally believed to be susceptible to cephalosporins, aminoglycosides, and fluoroquinolones (3).

One previous case of *Gordonia* spp. playing a pathogenic role in an eye-related infection in a case of traumatic endophthalmitis secondary to infection with *G. sputi* has been reported (4). In contrast, the peculiarity of our case was the lack of obvious mode of transmission for *G. bronchialis* into the intraocular space. Seeding of the intraocular lens implant at the time of cataract surgery is possible, but unlikely, given the time lapse of 2.5 years between surgery and onset of symptoms. The patient also had no risk factors or history suggesting seeding from the bloodstream.

The course of our patient was of particular interest because the eye initially improved after vitrectomy and administration of intravitreal amikacin. However, a robust recurrence of inflammation occurred 3 weeks later, probably caused by incomplete treatment during initial therapy.

Although previously accurate identification of *Gordonia* spp. by using traditional culturing techniques has been challenging, advent of molecular biology techniques, such as 16S rRNA sequencing and matrix-assisted laser

desorption/ionization time-of-flight mass spectrometry, has improved identification of aerobic actinomycetes (3–8). Because the organism was partially identified by culture and fully identified by multiple molecular techniques and responded clinically to targeted antimicrobial drugs, we believe this case was a pathogenic infection and not a non-pathogenic contaminant/colonizer.

We report a case of chronic infectious endophthalmitis caused by infection with *G. bronchialis*. Molecular methods have enabled successful identification of this organism, which is generally considered to have low virulence and be highly susceptible to antimicrobial drugs. A combination approach of pars plana vitrectomy and intraocular lens explantation with intravitreal and oral antimicrobial drugs might lead to a successful outcome.

This study was supported by core grant P30 EY010572 (to the Casey Eye Institute) from the National Institutes of Health and an unrestricted grant to the Casey Eye Institute from Research to Prevent Blindness (New York, NY)

About the Author

Dr. Choi is a vitreoretinal surgery fellow at the Casey Eye Institute at Oregon Health and Science University, Portland, OR. His primary research interest is in elucidating the mechanisms that govern infectious and noninfectious causes of uveitis.

References

1. Sukackiene D, Rimsevicius L, Kiveryte S, Marcinkeviciene K, Bratchikov M, Zokaityte D, et al. A case of successfully treated relapsing peritoneal dialysis-associated peritonitis caused by *Gordonia bronchialis* in a farmer. *Nephrol Ther*. 2017.
2. Ramanan P, Deziel PJ, Wengenack NL. *Gordonia* bacteremia. *J Clin Microbiol*. 2013;51:3443–7. <http://dx.doi.org/10.1128/JCM.01449-13>
3. Blaschke AJ, Bender J, Byington CL, Korgenski K, Daly J, Petti CA, et al. *Gordonia* species: emerging pathogens in pediatric patients that are identified by 16S ribosomal RNA gene sequencing. *Clin Infect Dis*. 2007;45:483–6. <http://dx.doi.org/10.1086/520018>
4. Fang W, Li J, Cui HS, Jin X, Zhai J, Dai Y, et al. First identification of *Gordonia sputi* in a post-traumatic endophthalmitis patient: a case report and literatures review. *BMC Ophthalmol*. 2017;17:190. <http://dx.doi.org/10.1186/s12886-017-0573-5>
5. Verma P, Brown JM, Nunez VH, Morey RE, Steigerwalt AG, Pellegrini GJ, et al. Native valve endocarditis due to *Gordonia polyisoprenivorans*: case report and review of literature of bloodstream infections caused by *Gordonia* species. *J Clin Microbiol*. 2006;44:1905–8. <http://dx.doi.org/10.1128/JCM.44.5.1905-1908.2006>
6. Gil-Sande E, Brun-Otero M, Campo-Cerecedo F, Esteban E, Aguilar L, García-de-Lomas J. Etiological misidentification by routine biochemical tests of bacteremia caused by *Gordonia terrae* infection in the course of an episode of acute cholecystitis. *J Clin Microbiol*. 2006;44:2645–7. <http://dx.doi.org/10.1128/JCM.00444-06>
7. Wang T, Kong F, Chen S, Xiao M, Sorrell T, Wang X, et al. Improved identification of *Gordonia*, *Rhodococcus* and *Tsukamurella* species by 5'-end 16S rRNA gene sequencing.

Pathology. 2011;43:58–63. <http://dx.doi.org/10.1097/PAT.0b013e328340e431>

8. Rodríguez-Lozano J, Pérez-Llantada E, Agüero J, Rodríguez-Fernández A, Ruiz de Alegria C, Martínez-Martínez L, et al. Sternal wound infection caused by *Gordonia bronchialis*: identification by MALDI-TOF MS. *JMM Case Rep*. 2016;3:e005067.

Address for correspondence: Rene Choi, Department of Ophthalmology, Casey Eye Institute, Oregon Health and Science University, 3375 SW Terwilliger Blvd, Portland, OR 97239, USA; email: choir@ohsu.edu

Rickettsiales in Ticks Removed from Outdoor Workers, Southwest Georgia and Northwest Florida, USA

Elizabeth R. Gleim,¹ L. Mike Conner, Galina E. Zemtsova, Michael L. Levin, Pamela Wong, Madeleine A. Pfaff, Michael J. Yabsley

Author affiliations: Joseph W. Jones Ecological Research Center at Ichauway, Newton, Georgia, USA (E.R. Gleim, L.M. Conner); Oxford College of Emory University, Oxford, Georgia, USA (E.R. Gleim, P. Wong); University of Georgia, Athens, Georgia, USA (E.R. Gleim, M.A. Pfaff, M.J. Yabsley); Centers for Disease Control and Prevention, Atlanta, Georgia, USA (G.E. Zemtsova, M.L. Levin)

DOI: <https://doi.org/10.3201/eid2505.180438>

We determined the prevalence of selected Rickettsiales in 362 ticks removed from outdoor workers in southwest Georgia and northwest Florida, USA. Persons submitted an average of 1.1 ticks/month. We found *Ehrlichia chaffeensis* in an *Amblyomma maculatum* tick, and Panola Mountain *Ehrlichia* sp. in 2 *A. maculatum* ticks and 1 *Dermacentor variabilis* tick.

The southeastern United States has multiple tick species that can transmit pathogens to humans. The most common tick species, *Amblyomma americanum*, is the vector for the causative agents of human ehrlichioses and southern tick-associated rash illness, among others (1). *Dermacentor*

variabilis ticks can transmit the causative agent of Rocky Mountain spotted fever, and *Ixodes scapularis* ticks can transmit the causative agents of Lyme disease, babesiosis, and human granulocytic anaplasmosis (1). Although less common in the region, *A. maculatum* ticks are dominant in specific habitats and can transmit the causative agent of *Rickettsia parkeri* rickettsiosis (1).

Persons who have occupations that require them to be outside on a regular basis might have a greater risk for acquiring a tickborne disease (2). Although numerous studies have been conducted regarding risks for tickborne diseases among forestry workers in Europe, few studies have been performed in the United States (2,3). The studies that have been conducted in the United States have focused on forestry workers in the northeastern region (2). However, because of variable phenology and densities of ticks, it is useful to evaluate tick activity and pathogen prevalence in various regions and ecosystems.

Burn-tolerant and burn-dependent ecosystems, such as pine (*Pinus* spp.) and mixed pine forests commonly found in the southeastern United States, have unique tick dynamics compared with those of other habitats (4). The objective of this study was to determine the tick bite risk and tickborne pathogen prevalence in ticks removed from forestry workers working in pine and mixed pine forests in southwest Georgia and northwest Florida, USA.

During June 2009–December 2011, forestry workers in southwestern Georgia (7 counties) and northwestern Florida (1 county) submitted ticks crawling on or attached to them. We identified ticks and tested them for selected pathogens (Appendix, <https://wwwnc.cdc.gov/EID/article/25/5/18-0438-App1.pdf>). Immature forms of the same species from the same day and person were pooled (≤ 5 nymphs and ≤ 20 larvae) for testing.

A total of 53 persons submitted 362 ticks (Table). Excluding larvae, the most common tick species submitted was *A. maculatum*, followed by *A. americanum*, *I. scapularis*, and *D. variabilis*. On 4 occasions, 1 person submitted *A. tuberculatum* ticks (3 batches of larvae and 1 batch of nymphs) from a longleaf pine site in Baker County, Georgia. Average submissions per person were 2.6 ticks (median 1 tick), but 1 person submitted 100 ticks. A total of 24 persons submitted ticks more than once, and they submitted an average of 0.08–6.5 ticks/month (overall average submission rate of 1.1 ticks/month). Three ticks were engorged (1 *D. variabilis* adult, 1 *A. americanum* nymph, and 1 *Amblyomma* sp. nymph); only the *Amblyomma* sp. nymph was positive for a pathogen (*R. amblyommatis*).

Rickettsia spp. prevalence was 36.4% in adult, 27.9% in nymphal, and 20% in larval *A. americanum* ticks; *R. amblyommatis* was the only species identified (Table). *Rickettsia* spp. were detected in 23% of *A. maculatum* adults; *R. amblyommatis* was most common (6.0%), followed by

¹Current affiliation: Hollins University, Roanoke, Virginia, USA.