



## Case Report

# Ganglioglioma of the cervicothoracic spinal cord in a patient with neurofibromatosis type 1: A case report

Thainá Zanon Cruz<sup>1</sup>, Pedro Henrique Costa Ferreira-Pinto<sup>1</sup>, Ana Carolina Gonçalves Brito<sup>2</sup>, Leandro Ururahy<sup>1</sup>, Jefferson Trivino Sanchez<sup>1</sup>, Flavio Nigri<sup>1</sup>

<sup>1</sup>Department of Surgical Specialties and Neurosurgery, Neurosurgery Teaching and Assistance Unit, Pedro Ernesto University Hospital, Rio de Janeiro, Brazil, <sup>2</sup>Department of Pathology, Pedro Ernesto University Hospital, Rio de Janeiro, Brazil.

E-mail: \*Thainá Zanon Cruz - thaina.zanoon@hotmail.com; Pedro Henrique Costa Ferreira-Pinto - pedrohcfp@gmail.com; Ana Carolina Gonçalves Brito - anacarolgbrito@gmail.com; Leandro Ururahy - ururahy@gmail.com; Jefferson Trivino Sanchez - jefferson.trivino@gmail.com; Flavio Nigri - flavionigri@gmail.com



### \*Corresponding author:

Thainá Zanon Cruz,  
Department of Surgical  
Specialties, Neurosurgery  
Teaching and Assistance Unit,  
Pedro Ernesto University  
Hospital, Rio de Janeiro, Brazil.  
thaina.zanoon@hotmail.com

Received : 24 February 2021

Accepted : 26 May 2021

Published : 28 June 2021

### DOI

10.25259/SNI\_192\_2021

### Quick Response Code:



## ABSTRACT

**Background:** Gangliogliomas are rare tumors of the central nervous system. They are usually located intracranially and rarely in the spinal cord. There is no clear correlation between this tumor and neurofibromatosis type 1 (NF1) with only four cases described. The aim of this article is to describe one more case and add data to the literature regarding this rare association.

**Case Description:** An 8-year-old boy with NF1 presented progressive asymmetrical paraparesis (Grade 4 medical research council scale on the right leg and Grade 3 on the left leg). The cervicothoracic spinal magnetic resonance imaging demonstrated an intramedullary lesion from C4 to T4 vertebrae. The patient underwent a microsurgical resection. A partial resection was performed due to a drop in the motor evoked potential signal amplitude during dissection. Pathology report revealed a ganglioglioma (World Health Organization Grade I). Postoperatively, the patient evolved with worsening of the paraparesis. A few weeks later, he has improved his preoperative functional neurological state (better strength and gait). Adjuvant radiotherapy was not used. The patient is being followed up at the neurosurgery outpatient clinic.

**Conclusion:** This is another case of spinal ganglioglioma associated with NF1. The tumor must be included in the differential diagnosis of patients with NF1 and spinal lesions. Complete microsurgical resection remains the standard treatment for spinal gangliogliomas, however, in this specific case, it was decided to leave a portion of the tumor to prevent neurological damage. The prognosis and treatment of this condition associated with NF1 remains to be determined.

**Keywords:** Ganglioglioma, Microsurgery, Neurofibromatosis type 1, Spinal tumor

## INTRODUCTION

Gangliogliomas are rare tumors of the central nervous system (CNS), corresponding to 2.7–3.8% of primary CNS tumors, composed of variable proportions of glial and neuronal elements.<sup>[14,21]</sup> The occurrence in the spinal cord is 1.1% of all spinal neoplasms.<sup>[19]</sup> The first complete pathological description of these tumors was made in 1930 by Courville.<sup>[10,19]</sup> They are generally more frequent in children, corresponding to 4% of CNS tumors in the pediatric population.<sup>[8]</sup> Seizure is the most common symptom.<sup>[8]</sup> They can be found anywhere in the CNS, but are most located in the temporal lobe.<sup>[5]</sup> The spinal cord is an uncommon site of occurrence, ranging from 7.6% to 14.3% of total

This is an open-access article distributed under the terms of the Creative Commons Attribution-Non Commercial-Share Alike 4.0 License, which allows others to remix, tweak, and build upon the work non-commercially, as long as the author is credited and the new creations are licensed under the identical terms.

©2021 Published by Scientific Scholar on behalf of Surgical Neurology International

cases.<sup>[21]</sup> Gangliogliomas do not have specific features in imaging examinations. They usually have slow growth, low malignancy rate and are usually amenable to definitive treatment with surgical resection. Adjuvant radiotherapy may be indicated only in cases of lesion malignancy or any contraindication to resect a growing residual lesion.<sup>[16,20]</sup>

Neurofibromatosis type 1 (NF1) corresponds to an autosomal dominant genetic disorder in which mutations in the NF1 gene occur. The NF1 gene is located on the long arm of chromosome 17 (17q11.2).<sup>[2,3]</sup> It is the most common form of neurofibromatosis, accounting for 90% of all cases and is completely penetrating, with phenotypic expression in all cases of mutations.<sup>[7]</sup> Studies show that approximately half of patients have this condition inherited and the other half have sporadic mutations.<sup>[2,11]</sup> The syndrome predisposes the appearance of tumors located in the CNS. The most common tumor associated is the optic pathway glioma.<sup>[5,13,17]</sup> The diagnosis of NF1 is even more suspicious in children who have bilateral optic pathway glioma. These tumors have suggestive features in magnetic resonance imaging (MRI) and can regress without treatment.<sup>[5,13,17]</sup> Other tumors include neurofibromas, schwannomas, meningiomas, and gliomas. Spinal cord tumors in patients with NF1 have been reported as sporadic cases in the literature.<sup>[5,13]</sup>

There are not enough studies in the literature to define whether the association of NF1 and gangliogliomas is incidental or not. After searching in the medical literature analysis and retrieval system online database, it was found four cases described. The first one was a T10-L2 spinal ganglioglioma in a 5-year-old female (Japan, 2011).<sup>[9]</sup> The second case was a C4 to T3 ganglioglioma in a 4-year-old male (Italy, 2013).<sup>[6]</sup> In the third case, the authors followed up a 16-year-old male with a C3-T1 ganglioglioma for 10 years (China, 2015).<sup>[20]</sup> Finally, in the fourth case, the authors described a ganglioglioma of the conus medullaris in a 16-year-old male (India, 2016).<sup>[19]</sup> The present report is the fifth documented case of the association of a spinal ganglioglioma in a patient with NF1 [Table 1]. The aim of this paper is to add data to the literature regarding this rare association.

## CLINICAL PRESENTATION

An 8-year-old male patient was admitted to the pediatric unit complaining of weakness and pain of the lower limbs with occasional falls 1 year ago with significant worsening in the past 2 months. He had NF1 diagnosis since 2 years old with the presence of two of the seven National Institutes of Health criteria. The first criterion was more than six cafe-au-lait spots located on the lateral thoracic region with a diameter above 5 mm in a prepubertal individual. The second criterion was one plexiform neurofibroma in the lumbar region, confirmed after a biopsy performed in 2018. No other family members were diagnosed with NF1.

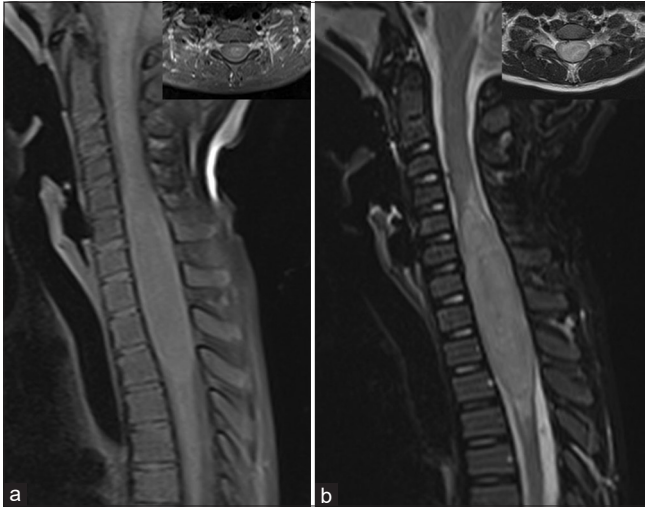
**Table 1:** Case reports demonstrating the association between NF1 and spinal ganglioglioma.

Cases/ authors	Age (year)	Sex	Location	Country/ year
Hayashi <i>et al.</i>	5	Female	T10-L2	Japan, 2011
Giussani <i>et al.</i>	4	Male	C4-T3	Italy, 2013
Tian <i>et al.</i>	16	Male	C3-T1	China, 2015
Sundar <i>et al.</i>	16	Male	Conus medullaris	India, 2016
Cruz <i>et al.</i>	8	Male	C4-T4	Brazil, 2020

NF1: Neurofibromatosis type 1

The physical examination revealed macrocrania, pectus excavatum, and leg length discrepancy. On neurological examination, he presented an asymmetrical paraparesis (Grade 4 medical research council [MRC] scale on the right leg and Grade 3 on the left leg) with spasticity, hyperreflexia, and bilateral Babinski signs. The patient was able to walk, but was unable to stay long due to weakness. The brain and spinal cord MRI were performed. The brain MRI revealed T2 hyperintense signal and T1 hypointense signal lesions, in the dorsal part of the right globus pallidus, cerebellar hemispheres, pons, and white matter. Contrast-enhanced T1-weighted images, with fat suppression technique of the cervicothoracic spinal MRI, demonstrated an intramedullary lesion from the superior endplate of the C4 vertebra to the inferior endplate of the T4 vertebra, with a peripheral isointense signal and an irregular hyperintense central suggesting an intramedullary mass [Figure 1a]. The lesion was hyperintense on short-time inversion recovery and T2-weighted sequences [Figure 1b]. Lesion size on preoperative spine MRI was 7.3 × 1.6 × 1.3 cm (length; depth; and width).

After initial evaluation, it was decided to perform a cervicothoracic tumor resection. The procedure was performed under intravenous general anesthesia. After anesthetic induction, the patient was placed in the prone position with a 3-pin head holder. Antisepsis and asepsis techniques were performed with subsequent placement of sterile drapes. A posterior longitudinal skin incision was made. After identification, through palpation and guided radioscopia of the cervical and thoracic spinous processes, a subperiosteal dissection was performed. The patient underwent a C3-T5 laminotomy. After bone removal, the dura mater was opened and attached with 4-0 polypropylene suture. During inspection, the tumor was intramedullary and situated laterally (left side) in the cervicothoracic spinal cord. The lesion consistency was apparently firm, with a good cleavage plane in the superior aspect of the spinal cord [Figure 2a-d]. As the tumor had a posterior exophytic component, it was not necessary to perform myelotomy. The dissection was initiated at the tumor interface within the posterolateral region of the spinal cord adjacent to the dorsal root entry zone [Figure 2a].

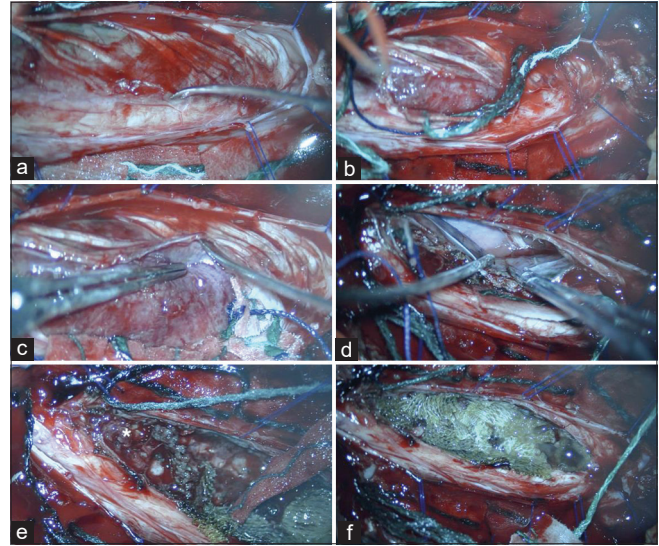


**Figure 1:** Cervicothoracic spinal magnetic resonance imaging. (a) Axial and sagittal views of contrast-enhanced T1-weighted with fat suppression demonstrated an intramedullary lesion from C4 to T4. Note the peripheral isointense signal with an irregular central hyperintense component. (b) The lesion was hyperintense on short-time inversion recovery (sagittal slice) and T2-weighted (axial slice) sequences.

After the initial dissection of the upper pole of the tumor, partial resection of the lesion was performed. In the most caudal portion, the tumor was infiltrating the adjacent neural tissue without a clear cleavage plane. On the basis of a drop of the intraoperative somatosensory and motor evoked potentials (MEPs) during dissection, we choose to leave some tumor. Therefore, a partial resection was achieved [Figure 2e and f]. Finally, the C3-T5 lamina was reintroduced and fixed with titanium plates.

During the procedure, the somatosensory evoked potentials recorded cortical waves P37 and N20, with stable latencies and amplitudes. There was a MEP amplitude decreasing (90%) of the triceps brachii bilaterally and left abductor pollicis brevis after complete removal of the superior tumor pole [Figures 3a-c and 4a-c]. During dissection of the inferior tumor pole, there was 89% decreasing of the left abductor hallucis MEP and the resection was interrupted [Figure 4a-c]. At the end of the procedure, the right triceps brachii muscle MEP amplitude was normalized [Figures 3a-c and 4a-c]. However, 90% of the MEP signal drop in the left triceps brachii and left abductor pollicis brevis was still present.

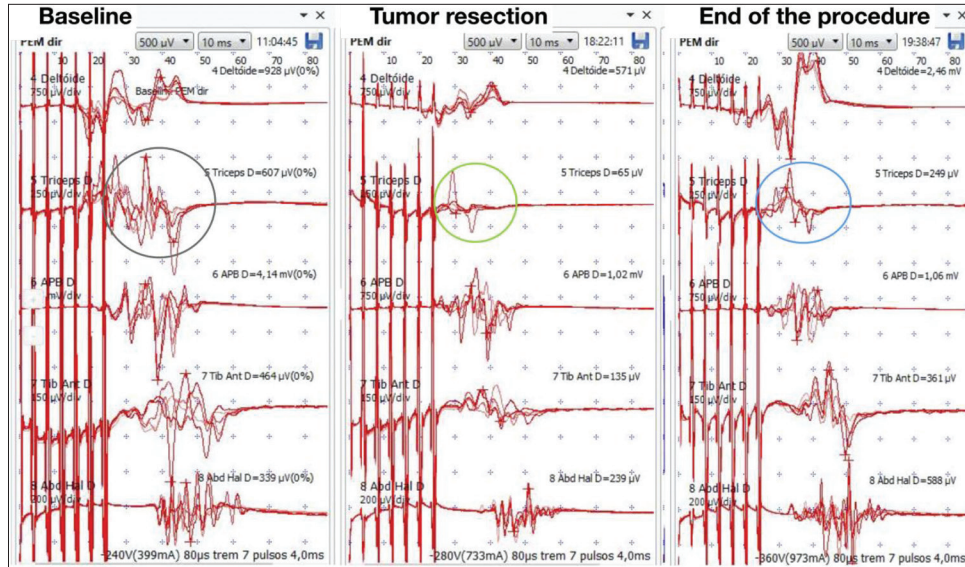
Histopathological examination revealed a relative well-circumscribed neoplasm composed of atypical neurons distributed irregularly. The neurons were mixed with glial proliferation, mild atypia, and a dense fibrillary background with focal desmoplasia. There were eosinophilic granular bodies and rare microcalcification besides vessels with hyalinized wall. These findings supported the diagnosis of ganglioglioma – World Health Organization Grade I [Figure 5a



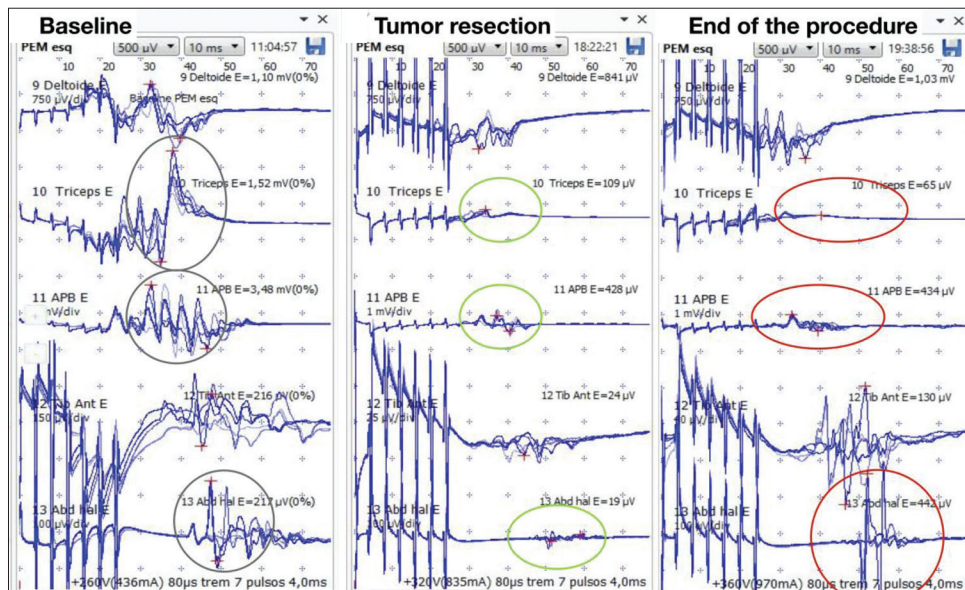
**Figure 2:** Microsurgery resection of the cervicothoracic tumor. (a) The lesion was located laterally (left side) pushing the dorsal cervical nerve roots (arrow head). (b) Some dorsal nerve roots were removed to allow lesion removal. (c) Tumor dissection included the most lateral aspect. (d) Subarachnoid plane after lateral dissection. (e) The most inferior aspect of the tumor was very attached. Traction and dissection of this part of the tumor cause a significant drop of the intraoperative somatosensory and motor evoked potentials. It was decided to leave some tumor (asterisk). (f) Final aspect of the cavity. The tumor bed was filled with absorbent cellulose hemostatics.

and b]. No special stain was performed in the specimen. The diagnosis was based on characteristic morphological criteria and correlation with the neuroradiological findings. No additional techniques were necessary.

In the immediate postoperative period, the patient presented kinesiphobia, refusing to get out of bed in the 1<sup>st</sup> days. Worsening of paraparesis was noted (Grade 3 MRC bilaterally). The patient did not use steroids in the pre- and post-operative period. The residual lesion size measured by the immediate postoperative spine MRI was 1.6 × 1.5 × 1.3 cm (length; depth; and width) representing 80% of tumor resection. The patient was discharged and returned 3 weeks after the procedure. He presented a symmetrical Grade 4 MRC paraparesis with spasticity, hyperreflexia, and bilateral Babinski signs. He improved his preoperative functional neurological state exhibiting a spastic gait without fatigue overtime. He is being followed up for 7 months with serial clinical and radiological examinations. In the last appointment, there was a significant improvement in gait (Grade 5 MRC scale on the right leg and Grade 4+ on the left leg). Postoperative MRI, performed 5 months after surgery, showed no growth of residual lesion [Figure 6a and b]. Therefore, until this moment, the patient did not need a new surgical approach or radiotherapy.



**Figure 3:** Intraoperative neurophysiological monitoring – right side. (a) Demonstration of motor evoked potential (MEP) with stable amplitude and latency at the beginning of the procedure (gray circle). The following muscles were analyzed: deltoid, triceps brachii, abductor pollicis brevis, tibialis anterior, and abductor hallucis. (b) After superior tumor pole removal, there was a MEP drop in the right triceps brachii muscle (green circle). There were no changes in the other muscles MEPs during inferior pole dissection. (c) At the end of the procedure, there was a MEP normalization on the right side (blue circle).

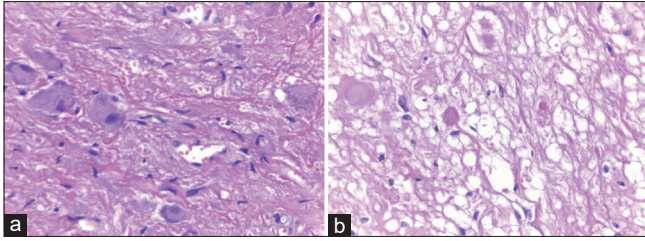


**Figure 4:** Intraoperative neurophysiological monitoring – left side. (a) Demonstration of motor evoked potential (MEP) with stable amplitude and latency at the beginning of the procedure (gray circle). The following muscles were analyzed: deltoid, triceps brachii, abductor pollicis brevis, tibialis anterior, and abductor hallucis. (b) After superior tumor pole removal, there was 90% MEP drop in the left triceps brachii and abductor pollicis brevis (green circle). During inferior resection, there was 89% MEP drop in the left abductor hallucis and the resection was interrupted (green circle). (c) At the end of the procedure, the MEP signal drop in the left triceps brachii and abductor pollicis brevis was maintained (red circle). The left abductor hallucis MEP returned to the baseline (red circle).

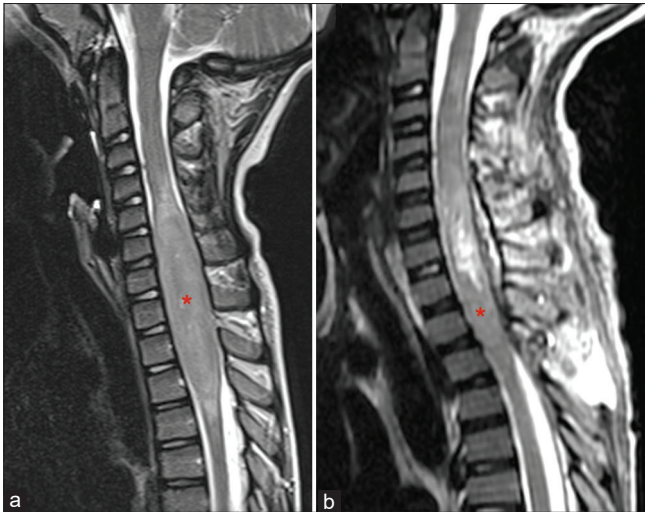
**DISCUSSION**

Spinal cord gangliogliomas are very rare tumors. A study involving 348 children, demonstrated a preference for males

and an average of 10 years old.<sup>[4]</sup> The most common location in the spinal cord is the cervical and the thoracic portions, covering 4–8 vertebral segments.<sup>[10,19]</sup> The mean lag time between onset of symptoms and confirming diagnosis of the



**Figure 5:** Histopathological findings – ganglioglioma. Hematoxylin and eosin stain ( $\times 400$ ). (a) Neoplastic neurons with Nissl substance aggregated under the cell membrane and irregular distribution. (b) Eosinophilic granular bodies in a fibrillary microcystic matrix.



**Figure 6:** Comparison between pre- and post-operative cervicothoracic spine magnetic resonance imaging. (a) Preoperative sagittal view of T2-weighted demonstrating an intramedullary lesion from C4 to T4 (red asterisk). (b) Postoperative sagittal view of T2-weighted demonstrating the hyperintense residual cavity and caudal residual tumor (red asterisk).

tumor is 12 months.<sup>[10,19]</sup> There are no unique radiological features for gangliogliomas, however, MRI is very useful for diagnosis. These tumors are intramedullary and have a primary eccentric location.<sup>[15,19]</sup> They usually have longitudinal extension, lack of edema, mixed T1-weighted signal intensity, and irregular contrast enhancement. Bone erosion and scoliosis can be associated.<sup>[15,19]</sup> Spinal tumor calcification can be observed in the computed tomography, but this is more common in intracranial gangliogliomas.<sup>[15,19]</sup> In most cases, it is possible to perform total resection and adjuvant radiotherapy is rarely necessary.<sup>[10,19]</sup> Worse prognosis is observed in infants and patients with brainstem tumors.<sup>[4]</sup>

Malignant progression of gangliogliomas is a rare event, reported in the literature in 10% of cases. It is considered that the proliferation of the astrocytic component is responsible for this malignant transformation, while the neuronal component does not have a neoplastic nature.<sup>[1,19]</sup> In a study, Lang *et al.* described worse operative morbidity rates

(35% vs. 5%), worse relative 5-year survival rates (78.5% vs. 93%), and worse event-free survival rates (44.5% vs. 95%) for gangliogliomas brainstem/spinal cord when compared to brain tumors. In addition, spinal cord/brainstem tumors had a 3.5 and 5 times higher risk of recurrence in the same study.<sup>[4,12]</sup> The proposed treatment of gangliogliomas is complete microsurgical removal, leading to a better prognosis and disease-free survival.<sup>[1,10,19]</sup> The effect of chemotherapy still remains controversial, and no benefit has been confirmed.<sup>[1,18,21]</sup> There is a tendency toward less use of radiotherapy in recent years, due to the understanding of the benignity of tumors and the harmful effects resulting from this therapy, which should always be considered risk benefit, generally indicated for tumors with anaplastic characteristics or high proliferation rate.<sup>[4,19]</sup>

About 40% of patients with NF1 have spinal cord lesions on MRI. They lead to clinical manifestations in approximately 2% of patients.<sup>[19]</sup> Interestingly, both NF1 and gangliogliomas are disorders of glial cells and neurons. The reason of the appearance of these tumors in the context of hereditary syndromes, such as NF1, neurofibromatosis type 2 (NF2), and von Hippel–Lindau, is still under investigation and needs to be determined.<sup>[22]</sup> The identification of the oncogenic signaling pathways in the development of spinal cord tumors will be crucial for the management of these lesions in the future. In some experimental studies, abnormal proliferation of astrocytes in the brain of rodents with heterozygosity of NF1 has been developed.<sup>[5]</sup> The defective neurofibromin was present in NF1 pilocytic astrocytoma.<sup>[5]</sup> However, so far, it has not been possible to demonstrate its presence in gangliogliomas and further studies are necessary to establish a possible genetic/molecular correlation.<sup>[5]</sup>

Due to the rarity of the association of ganglioglioma and NF1, little is known about the incidence, age of presentation, sex preference, most common location in the spinal cord, best treatment, and prognosis. Despite the total resection of spinal gangliogliomas being the standard treatment, in this case, we were not able to perform a complete resection because the MEP dropped during caudal dissection. The tumor was infiltrating the spinal cord. To preserve neurofunctional status, it was chosen to leave some tumor and follow-up the residual lesion. Its indolent tumor nature, allows an expectant approach. It is important to distinguish gangliogliomas from the other common NF1-associated tumors, especially diffuse astrocytoma, pilocytic astrocytoma, and focal areas of signal intensity.

## CONCLUSION

This report adds to the literature another case of a spinal ganglioglioma in a patient with NF1. The tumor must be included in the differential diagnosis of patients with NF1 and spinal lesions. Despite complete microsurgery resection

being the standard treatment of gangliogliomas, in this case, it was decided to perform a partial resection and follow-up due to the high risk of spinal cord injury. The prognosis and treatment of this condition associated with NF1 remains to be determined.

#### Declaration of patient consent

The authors certify that they have obtained all appropriate patient consent.

#### Financial support and sponsorship

Fundação de Amparo à Pesquisa do Estado do Rio de Janeiro (FAPERJ) and Center of High Complexity Neurosurgery Intern Patients (NIPNAC).

#### Conflicts of interest

There are no conflicts of interest.

#### REFERENCES

1. Araújo JE, Souza MR, Sperlescu A, Balbo RJ. Malignant course of a ganglioglioma: Case report. *Arq Neuropsiquiatr* 1998;56:486-90.
2. Ars E, Kruyer H, Morell M, Pros E, Serra E, Ravella A, *et al.* Recurrent mutations in the NF1 gene are common among neurofibromatosis Type 1 patients. *J Med Genet* 2003;40:e82.
3. Cawthon RM, O'Connell P, Buchberg AM, Viskochil D, Weiss RB, Culver M, *et al.* Identification and characterization of transcripts from the neurofibromatosis 1 region: The sequence and genomic structure of EVI2 and mapping of other transcripts. *Genomics* 1990;7:555-65.
4. Dudley RW, Torok MR, Gallegos DR, Mulcahy-Levy JM, Hoffman LM, Liu AK, *et al.* Pediatric low-grade ganglioglioma: Epidemiology, treatments, and outcome analysis on 348 children from the surveillance, epidemiology, and end results database. *Neurosurgery* 2015;76:313-9.
5. Fedi M, Mitchell LA, Kalnins RM, Gutmann DH, Perry A, Newton M, *et al.* Glioneuronal tumours in neurofibromatosis Type 1: MRI-pathological study. *J Clin Neurosci* 2004;11:745-7.
6. Giussani C, Isimbaldi G, Massimino M, Trezza A, Cianci P, Conocico F, *et al.* Ganglioglioma of the spinal cord in neurofibromatosis Type 1. *Pediatr Neurosurg* 2013;49:50-4.
7. Gorlin RJ, Cohen MM, Levin LS. Hamartoneoplastic syndromes. In: *Syndromes of the Head and Neck*. 3<sup>rd</sup> ed. Oxford: Oxford University Press; 1990. p. 353-416.
8. Gupta K, Orisme W, Harreld JH, Qaddoumi I, Dalton JD, PUNCHIHEWA C, *et al.* Posterior fossa and spinal gangliogliomas form two distinct clinicopathologic and molecular subgroups. *Acta Neuropathol Commun* 2014;2:18.
9. Hayashi Y, Nakada M, Mohri M, Murakami H, Kawahara N, Hamada J. Ganglioglioma of the thoracolumbar spinal cord in a patient with neurofibromatosis Type 1: A case report and literature review. *Pediatr Neurosurg* 2011;47:210-3.
10. Jallo G, Freed D, Epstein F. Spinal cord gangliogliomas: A review of 56 patients. *J Neurooncol* 2004;68:71-7.
11. Junior L, Filho A, Silva D, Geller M. Neurofibromatosis type 1 in childhood: Review of clinical aspects. *Rev Paul Pediatr* 2008;26:176-82.
12. Lang FF, Epstein FJ, Ransohoff J, Allen JC, Wisoff J, Abbott IR, *et al.* Central nervous system gangliogliomas. Part 2: Clinical outcome. *J Neurosurg* 1993;79:867-73.
13. Lee M, Rezai AR, Freed D, Epstein FJ. Intramedullary spinal cord tumors in neurofibromatosis. *Neurosurgery* 1996;38:32-7.
14. Miller DC. Surgical pathology of intramedullary spinal cord neoplasms. *J Neurooncol* 2000;47:189-94.
15. Patel U, Pinto RS, Miller DC, Handler MS, Rorke LB, Epstein FJ, *et al.* MR of spinal cord ganglioglioma. *AJNR Am J Neuroradiol* 1998;19:879-87.
16. Patibandla MR, Ridder T, Dorris K, Torok MR, Liu AK, Handler MH, *et al.* Atypical pediatric ganglioglioma is common and associated with a less favorable clinical course. *J Neurosurg Pediatr* 2016;17:41-8.
17. Rodriguez FJ, Perry A, Gutmann DH, O'Neill BP, Leonard J, Bryant S, *et al.* Gliomas in neurofibromatosis Type 1: A clinicopathologic study of 100 patients. *J Neuropathol Exp Neurol* 2008;67:240-9.
18. Silver JM, Rawlings CE, Rossich E, Zeidman SM, Friedman AH. Ganglioglioma: A clinical study with long-term follow-up. *Surg Neurol* 1991;35:261-6.
19. Sundar IV, Jaiswal M, Purohit D, Mittal RS. Ganglioglioma of conus medullaris in a patient of neurofibromatosis type 1: A novel association? *Asian J Neurosurg* 2016;11:455.
20. Tian R, Liu B, Wang G, Hao S. Natural history of spinal ganglioglioma in neurofibromatosis Type 1: A 10-year follow-up. *Int J Clin Exp Med* 2016;9:4879-83.
21. Truite LV, Hanel RA, Grande CV, Torres LF, Araújo JC. Spinal cord ganglioglioma: Case report. *Arq Neuropsiquiatr* 2001;59:431-4.
22. Zhang M, Iyer RR, Azad TD, Wang Q, Garzon-Muvdi T, Wang J, *et al.* Genomic landscape of intramedullary spinal cord gliomas. *Sci Rep* 2019;9:18722.

**How to cite this article:** Cruz TZ, Ferreira-Pinto PHC, Brito AC, Ururahy L, Sanchez JT, Nigri F. Ganglioglioma of the cervicothoracic spinal cord in a patient with neurofibromatosis type 1: A case report. *Surg Neurol Int* 2021;12:313.