

Available online at www.sciencedirect.com

ScienceDirect

journal homepage: www.elsevier.com/locate/radcr

Case Report

Abdominal pain from ingested bone misdiagnosed as appendicitis: Report of a rare case and literature review ☆☆☆

Hoshman Rahman Asaad, MBChB, K.B.M.S.^{a,b}, Heero Ismael Faraj, MBChB^b, Ahmed Altom, MBChB^c, Syamand Abdulrahman Ahmed, MBChB^a, Bakhtyar Kamal Muhammad, MBChB^{a,d}, Muhammad Jabar Rashid, MBChB^a, Jeza M. Abdul Aziz, Msc.^{a,e,*}, Rebwar Hassan Khdir, Bsc.^a, Nguyen Tien Huy, M.D., Ph.D.^{f,*}

^aBaxshin Research Center, Baxshin Hospital, Sulaimani, Kurdistan Region, Iraq

^bKurdistan Center for Gastroenterology and Hepatology, Sulaimani, Kurdistan, Iraq

^cDepartment of Internal Medicine, Faculty of Medicine, Damascus University, Damascus, Syrian Arab Republic.

^dAnesthesia Department Technical, College of Health, Sulaimani, Polytechnic University, Kurdistan Region, Iraq

^eMedical laboratory science, College of health sciences, University of Human Development, Sulaimani, Kurdistan Region, Iraq

^fSchool of Tropical Medicine and Global Health, Nagasaki University, Nagasaki, 852-8523, Japan

ARTICLE INFO

Article history:

Received 18 July 2022

Revised 26 July 2022

Accepted 31 July 2022

Keywords:

Misdiagnosis

Colonoscopy

Appendicitis

Ingest meat bone

A rare case

Foreign bodies

ABSTRACT

Bones are potential foreign bodies that could be accidentally ingested, leading to several symptoms varying from asymptomatic to perforation of the gastrointestinal tract. However, these cases are rare but may be misdiagnosed with other common diseases such as appendicitis. We present in this case a 25-year-old male who presented with appendicitis symptoms, after appendectomy the patient had the same complaint, But the colonoscopy demonstrated a meat bone in the terminal ileum and was removed with the same device. Finally, he was discharged from the hospital without complications and after decreasing abdominal pain. According to the literature review, this is one of the rare cases of using colonoscopy to treat bone impaction non-operatively.

© 2022 The Authors. Published by Elsevier Inc. on behalf of University of Washington.

This is an open access article under the CC BY-NC-ND license (<http://creativecommons.org/licenses/by-nc-nd/4.0/>)

☆ Competing Interests: None.

☆☆ Funding: This research did not receive any specific grant from funding agencies in the public, commercial, or not-for-profit sectors.

* Corresponding authors.

E-mail addresses: jeza1981@gmail.com (J.M.A. Aziz), tienhuy@nagasaki-u.ac.jp (N.T. Huy).

<https://doi.org/10.1016/j.radcr.2022.07.108>

1930-0433/© 2022 The Authors. Published by Elsevier Inc. on behalf of University of Washington. This is an open access article under the CC BY-NC-ND license (<http://creativecommons.org/licenses/by-nc-nd/4.0/>)

Introduction

Ingestion of foreign bodies is a rare condition that may affect any part of the digestive tract, including the esophagus, stomach, bowel, and even rectum. However, the presentations vary between asymptomatic [1], gastrointestinal hemorrhage [2], acute or chronic abdominal pain [3], obstruction symptoms [4], and many others. That makes the diagnosis a challenging issue for the clinicians, especially in the presence of many other possible and even more common diagnoses. The process will be even harder when the ingested foreign bodies mimic known diseases such as appendicitis and renal colic [5,6]. Additionally, the previous reports indicate that diagnostic tools often miss the correct diagnosis, such as computed tomography (CT), which only diagnoses 15% of cases [7].

On the other hand, foreign bodies include shots, toothpicks, dental prostheses, and other artificial parts. Moreover, biological parts such as bones of chicken, fish, and cattle are also a source for foreign bodies. Though, there are only a few reports about the management of ingestion of meat bone. Considering the previous challenges, the current literature needs more reports about these rare cases to identify the best practice in similar cases. Therefore, we present one of the rare case reports about a patient with appendicitis-like pain due to bone ingestion. This report has been written following the SCARE criteria guidelines for case reports [8].

Case report

A 25-year-old male pharmacist was admitted to the Baxshin hospital with severe right iliac fossa pain and recurrent attacks of vomiting, no fever, and no change in bowel habits. Two weeks before this presentation, he had the same complaints and was diagnosed with acute appendicitis when he was admitted to another hospital. They found that the appendix was normal with no evidence of inflammation during the appendectomy. The patient continued to have the same pain and had been sent by the surgeon to a gastroenterologist for colonoscopy as a case of suspected Crohn's disease. On physical examination, acute right iliac fossa pain, tenderness on palpation, slight abdominal distention, and vital signs were normal. Additionally, all laboratory tests were normal. As a result, the patient prepared for a colonoscopy.

Colonoscopy revealed a normal anal canal, rectum, and all parts of the colon, including the cecum. But there was a foreign body embedded in the mucosa of the terminal ileum obstructing the ileocecal valve, causing severe congestion of surrounding mucosa with ulceration and stenosis of the terminal ileum and ileocecal valve. Upon questioning the patient, he mentioned that before 20 days, he ate (Biryani) which is often prepared by flavoring rice with beef meat and mild spices.

Abdominal and pelvis (CT) with oral and intravenous contrast confirmed the presence of foreign body/bone fragments measuring 21 × 17 mm in size within the lumen of the terminal ileum at the ileocecal junction (Fig. 1). There was also

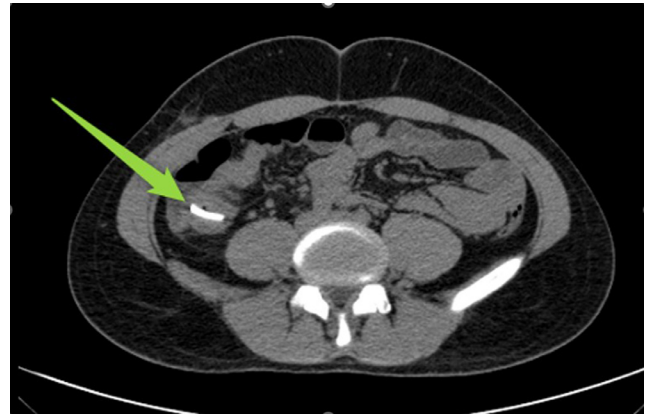


Fig. 1 – Computed tomography (CT) scan showing a foreign body (bone fragment) measuring 21 × 17 mm in size within the lumen of the terminal ileum.



Fig. 2 – Extract sharp animal bone 25 × 19 mm.

a focal edematous mural thickening, hyperemia, mild adjacent fat stranding, and mild free fluid at the pelvis. On the other hand, there was no free intraperitoneal air and no proximal dilatation. Multiple diverticula were seen at the sigmoid colon with no sign of inflammation. Additionally, we found normal liver (size, density, and shape), no focal lesion seen in the portal and hepatic veins, normal intra and extrahepatic biliary tree, normal gallbladder, normal spleen, pancreas, adrenal glands, both kidneys size, shape, density and contrast excretion, no stone or hydronephrosis, no focal mass, normal urinary bladder, no pelvic mass, no bony lesion. Under sedation by colonoscopy the piece of meat bone with sharp edge removed size 25 × 19 mm (Fig. 2) in the ileocecal valve using polypectomy snare and alligator forceps (Fig. 3). There was ulceration in the ileum and ileocecal valve with stenosis; biopsies were taken. There were no immediate signs of perforation. The patient was admitted for 24 hours of observation and discharged without any complication after im-

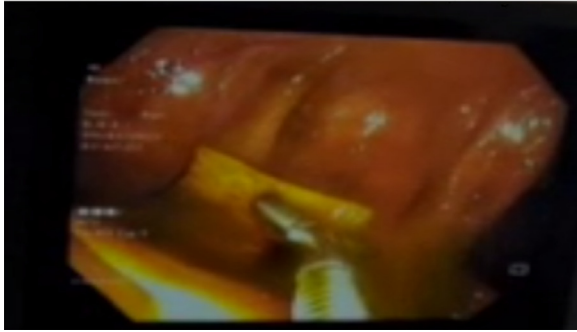


Fig. 3 – Colonoscopy view showing a bone.

proving the abdominal pain. The histopathology results returned later and revealed no features of Crohn's disease in the specimen.

Discussion

Foreign bodies include a wide range of materials, from artificial ones such as shots and batteries to biological materials such as bones. In this rare case, CT was involved in confirming the diagnosis of meat bone, which is unusual in the literature. However, the final management was done using an uneventful and successful colonoscopy.

Most cases of foreign body ingestion happened incidentally and were discovered during laparotomy [9]. Regarding vulnerable groups, prisoners, patients with psychiatric diseases, children, and alcoholics are the most common [10]. That is maybe because those patients are usually less aware of the hard pieces in their food and their bad eating habits, while in our case the patient was a pharmacist.

On the other hand, bones may represent potential foreign bodies that could be ingested accidentally, leading to various complications. Fish, and chicken are the most commonly reported source of ingested bones [11]. Fish is the most frequently reported one, especially in Asian communities, because it is the main dish there, then chicken; however, meat bone cases were rarely reported [11]. Our case is considered one of the rare cases that reported ingested beef meat in the literature.

Several cases reported foreign body ingestion with symptoms similar to appendicitis. Similar to what was reported above, most patients were above 40 years old; only 2 out of 9 were young (23 and 24 years old). Most of the cases were fish bones; however, chicken and sheep bones were also reported. Impaction places include distal duodenum, jejunum, terminal ileum, ileocecal junction, distal sigmoid colon, and Meckel's diverticulum. Additionally, all cases reported negative CT and Ultrasound scans, and the patients were only diagnosed with an ingested foreign bone then suggest laparoscopy and laparotomy [12–21]. Therefore, clinicians should not count very much on the imaging results to exclude the ingestion of foreign bodies despite its rarity. One

can also conclude that the clinical complaints are mostly compatible with the place of the foreign bodies. Most of the bones are located at the ilium or near the ileocecal junction, which same of them may lead to congestion, inflammation, or structure. As a result, that inflammatory process may lead to real appendicitis or appendicitis-like symptoms due to occlusion of the appendix inlet [14,21]. Though, most of the reported cases showed normal appendix without inflammation. Therefore, the appendicitis-like pain may be due to the common innervation of the ileocecal junction, ilium, and appendix.

Regarding treatment, most of these cases were diagnosed and treated operatively with laparoscopy or laparotomy. In previous literature, only a few cases used the non-operative method with colonoscopy or conservative treatment. That includes the removal of a dental needle in the cecum [22], a toothpick in the sigmoid [23], chicken bone in the cecal wall [24], and a small bowel perforation treated non-operatively with antibiotics and monitoring [25]. The remarkable thing is that patients' symptoms were not severe enough to trigger an emergent laparoscopy, and the clinicians considered ingestion of foreign bodies before the operation either by imagining tools or the patient history. Therefore, detailed patient history [26], imagining tools, and enough time before the final decision are critical to operations in those patients. However, these cases were treated successfully and discharged from the hospital without complications. To our best knowledge, this paper reports the treatment of ingested beef meat bone with appendicitis-like symptoms using colonoscopy. That will support the current few pieces of evidence about using colonoscopy as an effective tool to remove foreign bodies in the colon. However, more research is needed to reach a clear indication for colonoscopy compared to the operation method in patients with ingested foreign bodies.

Conclusion

Ingestion of bone meat may mimic acute appendicitis. However, the symptoms could be treated effectively with colonoscopy instead of operative intervention according to the foreign body site and other factors related to diagnosis and patient. Therefore, as a treatment tool, colonoscopy applies to specific conditions that should be defined clearly in future research.

Author contributions

HRA, HIF, MJR, BKM, and SAA contributed to the Diagnosis, and patient management, designed the study, and conducted research. AA, JMA, and NTH make relevant inferences based on the available data and formulated the discussion and conclusions, finally approved the manuscript. RHK performed the literature review and preparation of the draft manuscript. All authors have critically reviewed, edited the manuscript, approved the final draft, and are responsible for the content and similarity index of the manuscript.

Patient consent

I state that written and informed consent was taken from the patient for publication of this case. The patient was informed that no personal details will be revealed in the publishing of this case.

Ethical approval

Ethical approval to report this case was obtained from the Baxshin Hospital Institutional Review Board (BRC260022).

REFERENCES

- [1] Cevallos JM, Molina GA, Aguayo WG, Cacuango LP, Espin DS, Ramos DR, et al. A nail in the appendix, accidental discovery on an asymptomatic patient. *J Surg Case Rep* 2019;2019(1):1–3. doi:10.1093/jscr/rjy335.
- [2] Karnecki K, Pieśniak D, Jankowski Z, Gos T, Kalisz M. Fatal haemorrhage from an aorto-esophageal fistula secondary to button battery ingestion in a 15-month-old child. Case report and literature review. *Leg Med* 2020;45:101707. doi:10.1016/j.legalmed.2020.101707.
- [3] Monsalve P, Lombardo G, Bastardo E. Gastric perforation by fish bone: case report. *Gastroenterol Hepatol Open Access* 2019;10(5):268–70. doi:10.15406/ghoa.2019.10.00394.
- [4] Ye H, Huang S, Zhou Q, Yu J, Xi C, Cao L, et al. Migration of a foreign body to the rectum: a case report and literature review. *Medicine (Baltimore)* 2018;97(28):e11512 Epub 2018/07/12. doi:10.1097/md.00000000000011512.
- [5] Reeves JM, Wade MD, Edwards J. Ingested foreign body mimicking acute appendicitis. *Int J Surg Case Rep* 2018;46:66–8. doi:10.1016/j.ijscr.2018.04.003.
- [6] Rodrigues Gaspar JR, Vieira e Monteiro E, Costa Simões VJ, Durão Salgueiro PS. Renal colic by gastrointestinal perforation: endoscopic approach. *Port J Gastroenterol* 2021;28(3):222–4. doi:10.1159/000510033.
- [7] Li SF, Ender K. Toothpick injury mimicking renal colic: case report and systematic review. *J Emerg Med* 2002;23(1):35–8.
- [8] Agha RA, Franchi T, Sohrabi C, Mathew G, Kerwan A, Thoma A, et al. The SCARE 2020 guideline: updating consensus Surgical CAse REport (SCARE) guidelines. *Int J Surg* 2020;84:226–30. doi:10.1016/j.ijvsu.2020.10.034.
- [9] Rodríguez-Hermosa JI, Codina-Cazador A, Sirvent JM, Martín A, Gironès J, Garsot E. Surgically treated perforations of the gastrointestinal tract caused by ingested foreign bodies. *Colorectal Dis* 2008;10(7):701–7.
- [10] Madrona AP, Hernández JAF, Prats MC, Riquelme JR, Paricio PP. Intestinal perforation by foreign bodies. *Eur J Surg* 2000;166(4):307–9. doi:10.3109/110241500750009140.
- [11] Lai ATY, Chow TL, Lee DTY, Kwok SPY. Risk factors predicting the development of complications after foreign body ingestion. *Br J Surg* 2003;90(12):1531–5.
- [12] Ayoub A, Fagihi M, Abdul-Aal H, Abiri A, Al-Nam A, Khan L. Distal ileal perforation due to accidental ingestion of meat bone mimicking acute appendicitis. *Saudi J Laparosc* 2019;4(1):54–6. doi:10.4103/sjl.Sjl_9_18.
- [13] Joglekar S, Rajput I, Kamat S, Downey S. Sigmoid perforation caused by an ingested chicken bone presenting as right iliac fossa pain mimicking appendicitis: a case report. *J Med Case Rep* 2009;3(1):7385. doi:10.4076/1752-1947-3-7385.
- [14] Ma T, Zheng W, An B, Xia Y, Chen G. Small bowel perforation secondary to foreign body ingestion mimicking acute appendicitis: Case report. *Medicine (Baltimore)* 2019;98(30):e16489–e. doi:10.1097/MD.00000000000016489.
- [15] Almoudaris AM, Chow A, Kaneria S, Jiyad Z, Hadjiminias Dimitri J. Fish bone perforation mimicking acute appendicitis. *J Surg Pak* 2011;2:296–9.
- [16] Yadav AK, Malla G, Deo KB, Giri S, Bhattarai BM, Adhikary S. Jejunal perforation due to ingested buffalo bone mimicking acute appendicitis. *BMC Res Notes* 2016;9:321 Epub 2016/06/28. doi:10.1186/s13104-016-2127-y.
- [17] Chandrasinghe PC, Pathirana CK. Laparoscopically detected and nonsurgically managed ileal perforation by an ingested fish bone: a case report. *J Med Case Rep* 2015;9(1):43. doi:10.1186/s13256-015-0526-7.
- [18] Lim D, Ho C-M. Appendicitis-mimicking presentation in fishbone induced microperforation of the distal duodenum: a case report. *World J Gastrointest Surg* 2020;12(2):77–84. doi:10.4240/wjgs.v12.i2.77.
- [19] Koller J, Abdirahman AM, Khaliq A, Abu-Dayeh A, Sajid S, Mirza S, et al. A case report on fish bone perforating Meckel's diverticulum mimicking appendicitis. *Cureus* 2022;14(2):e22693 Epub 2022/04/05. doi:10.7759/cureus.22693.
- [20] Ngoc NS, Duy NT, Tung VL, Ngoc BHC. Intestinal perforation caused by fishbone in a child with the misdiagnosis of acute appendicitis: a case report. *Clin Case Rep* 2021;9(8):e04584. doi:10.1002/ccr3.4584.
- [21] Marouane Harhar RJ, Tijani El H, Mohammed B. Fishbone-induced appendicitis: a case report. *Cureus* 2021;13(5):e15003. doi:10.7759/cureus.15003.
- [22] Kang GCW, Madhukumar P. Successful management of an iatrogenically-ingested sharp foreign body. *Ann Acad Med Singap* 2008;37(11):980–1.
- [23] Zesos P, Oikonomou A, Souftas V, Gkotsis D, Pitiakoudis M, Kouklakis G. Endoscopic removal of a toothpick perforating the sigmoid colon and causing chronic abdominal pain: a case report. *Cases J* 2009;2:8469. doi:10.4076/1757-1626-2-8469.
- [24] Simunic M, Zaja I, Ardalic Z, Stipic R, Maras-Simunic M. Case report: successful endoscopic treatment of a large bowel perforation caused by chicken bone ingestion. *Medicine (Baltimore)* 2019;98(50):e18111. doi:10.1097/MD.00000000000018111.
- [25] Ward MA, Tews MC. Small bowel perforation secondary to fish bone ingestion managed non-operatively. *J Emerg Med* 2012;43(5):e295–e2e8. doi:10.1016/j.jemermed.2010.05.039.
- [26] Ahmed MM, Tahir KS, Gubari MIM, Rasul RHK, Rashid MJ, Abdul Aziz JM. Large trichobozoar associated with misdiagnosis, a rare case report with a brief literature review. *Int J Surg Case Rep* 2021;88:106551. doi:10.1016/j.ijscr.2021.106551.