

Dynamic stabilization

# Surgical results of dynamic nonfusion stabilization with the Segmental Spinal Correction System for degenerative lumbar spinal diseases with instability: Minimum 2-year follow-up

Hideki Ohta, MD \*, Yoshiyuki Matsumoto, MD, Yuichirou Morishita, MD, PhD, Tsubasa Sakai, MD, George Huang, MD, Hirotaka Kida, MD, and Yoshiharu Takemitsu, MD, PhD

*Oita Orthopedic Hospital, Oita-shi, Japan*

## Abstract

**Background:** When spinal fusion is applied to degenerative lumbar spinal disease with instability, adjacent segment disorder will be an issue in the future. However, decompression alone could cause recurrence of spinal canal stenosis because of increased instability on operated segments and lead to revision surgery. Covering the disadvantages of both procedures, we applied nonfusion stabilization with the Segmental Spinal Correction System (Ulrich Medical, Ulm, Germany) and decompression.

**Methods:** The surgical results of 52 patients (35 men and 17 women) with a minimum 2-year follow-up were analyzed: 10 patients with lumbar spinal canal stenosis, 15 with lumbar canal stenosis with disc herniation, 20 with degenerative spondylolisthesis, 6 with disc herniation, and 1 with lumbar discopathy.

**Results:** The Japanese Orthopaedic Association score was improved, from  $14.4 \pm 5.3$  to  $25.5 \pm 2.8$ . The improvement rate was 76%. Range of motion of the operated segments was significantly decreased, from  $9.6^\circ \pm 4.2^\circ$  to  $2.0^\circ \pm 1.8^\circ$ . Only 1 patient had adjacent segment disease that required revision surgery. There was only 1 screw breakage, but the patient was asymptomatic.

**Conclusions:** Over a minimum 2-year follow-up, the results of nonfusion stabilization with the Segmental Spinal Correction System for unstable degenerative lumbar disease were good. It is necessary to follow up the cases with a focus on adjacent segment disorders in the future.

© 2011 SAS - The International Society for the Advancement of Spine Surgery. Published by Elsevier Inc. All rights reserved.

**Keywords:** Lumbar spinal canal stenosis; Instability; Dynamic stabilization

There has long been a conflict of opinions regarding whether the best treatment for unstable degenerative lumbar disease is spinal fusion or decompression surgery. Despite good results with fusion, adjacent segment disease remains a long-term issue. With decompression surgery, on the other hand, revision surgery may be required in many cases because of recurrence of spinal canal stenosis caused by increased instability on operated segments. We applied nonfusion stabilization with the Segmental Spinal Correction System (SSCS) (Ulrich Medical, Ulm, Germany) and decompression to mitigate the disadvantages of both procedures.

The disadvantages of conventional spinal fusion are the requirement for bone grafting, potential adjacent segment disease (fusion disease), and the relatively invasive approach. Adjacent segment disease is obviously a major issue. To address it, instruments have been actively developed (mainly in Europe), primarily motion-preserving devices whose purpose is to restore physiologic motion and provide prophylaxis for adjacent segment disease while allowing for decompression. Devices for lumbar spine artificial disc replacement are in the review stage, but posterior motion preservation techniques remain in development.

The SSCS was developed by Professor Archibald H. von Stempel in 1989.<sup>1</sup> It is a unique system with a solid rod and a pedicle screw that has mobility in its screw head. The screw controls lateral bending, rotation, and translation completely and allows some motion in flexion and extension (sagittal plane) (Fig. 1). The SSCS was originally used

\* Corresponding author: Hideki Ohta, MD, Oita Orthopedic Hospital, 1-1-41 Iwata-machi, Oita-shi, 870-0936, Japan; Tel: 097-552-5151; Fax: 097-558-8573.

E-mail address: [hideohoh@oct-net.ne.jp](mailto:hideohoh@oct-net.ne.jp)

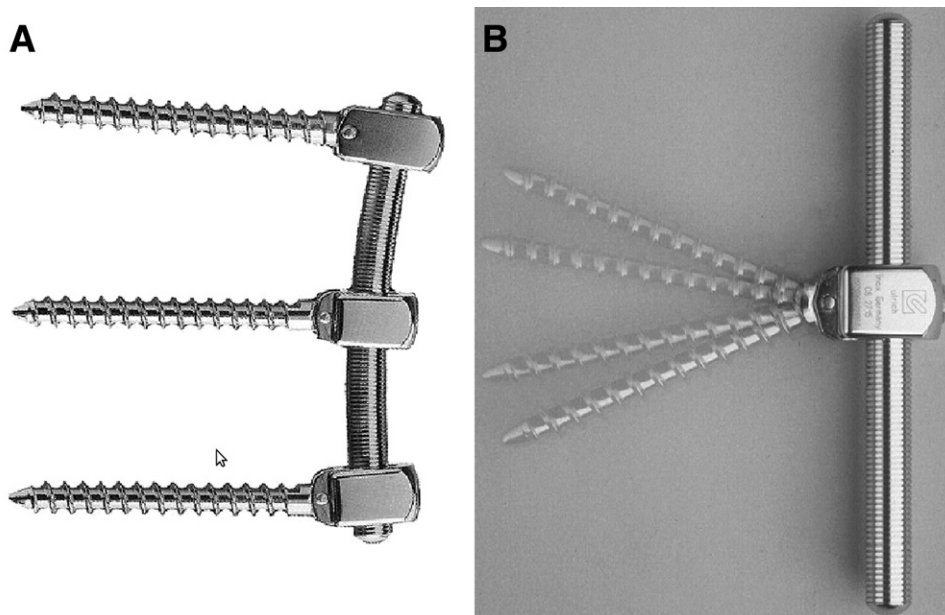


Fig. 1. The SSCS controls rotation and translation and allows flexion and extension. The screw has 20° of mobility in both the cranial and caudal directions. Segmental Spinal Correction System (A). The hinged screw allows motion (B).

together with posterolateral fusion. However, von Stempel realized that patients were asymptomatic and no SSCS implant failure occurred even with occurrence of pseudarthrosis. A multicenter study of nonfusion stabilization without bone grafts was started in 2004 with the concept of motion preservation.<sup>2</sup> The dynamized pedicle screw is available elsewhere under the Cosmic System (Ulrich Medical, Ulm, Germany)<sup>1</sup> with bioactive calcium phosphate coating. (The Japanese Ministry of Health, Labor and Welfare has not approved the bioactive coated screw for use yet in Japan, hence the use of the uncoated screw.) Although hinge breakage is of concern, no failure has been reported.

We used SSCS nonfusion stabilization combined with spinous process splitting laminectomy for unstable degenerative lumbar disease. A less invasive spinous process splitting<sup>3</sup> allows for SSCS implantation (Fig. 2).

The surgical results of SSCS for unstable degenerative lumbar disease with a minimum 2-year follow-up are presented. The purpose of this study was to determine the clinical results and the incidence of adjacent segment disease as well as instrument failure.

## Methods

We performed SSCS nonfusion stabilization in 214 patients from June 2005 to September 2009. We chose 52 patients (35 men and 17 women) with a minimum 2-year follow-up. The mean age was 64.3 years (range, 21–82 years), with a mean follow-up of 35 months (range, 24–46 months). The operative indications were as follows: degenerative spondylolisthesis (20 patients), lumbar spinal canal stenosis (10 patients), disc herniation (6 patients), lumbar canal stenosis with disc herniation (15 patients), and lumbar

discopathy (1 patient). In all cases instability was observed by use of plain radiographs. We defined instability as more than 5° of posterior angulation, more than 3 mm of anterolisthesis, or sagittalization of facet joints. Positioning the patients in the prone position on the 4-point frame maintains the lumbar spine in a neutral or mildly lordotic position. Decompression was achieved by spinous process splitting followed by pedicle screw insertion. The screws were then tightened with rods in situ without correction, followed by split spinous process suturing to complete the procedure. No bone graft was used. Postoperatively, a soft corset was applied to the patients with no activity restriction.

The investigational items are as follows: (1) changes in clinical symptoms based on the Japanese Orthopaedic Association (JOA) score, which correlates to Oswestry Disability Index and Roland-Morris Disability Questionnaire,<sup>4</sup> (2) Cobb angle (maximum flexion-extension) of operated segments preoperatively and at final follow-up, (3) range of motion (ROM) of the operated segments preoperatively and at final follow-up, and (4) occurrence of adjacent segment disorders and instrumentation failure.

## Results

The JOA score was  $14.4 \pm 5.3$  preoperatively, and it improved to  $25.5 \pm 2.8$  postoperatively. The Hirabayashi recovery rate was 76.0%. The preoperative Cobb angle was  $-2.8^\circ \pm 4.8^\circ$  (maximum flexion) and  $6.8^\circ \pm 4.8^\circ$  (maximum extension), and ROM was  $9.6^\circ \pm 4.2^\circ$ . The postoperative Cobb angle was  $3.2^\circ \pm 3.7^\circ$  (maximum flexion) and  $5.1^\circ \pm 3.9^\circ$  (maximum extension), and ROM was  $2.0^\circ \pm 1.8^\circ$ . The posterior angulation (flexion instability) disap-

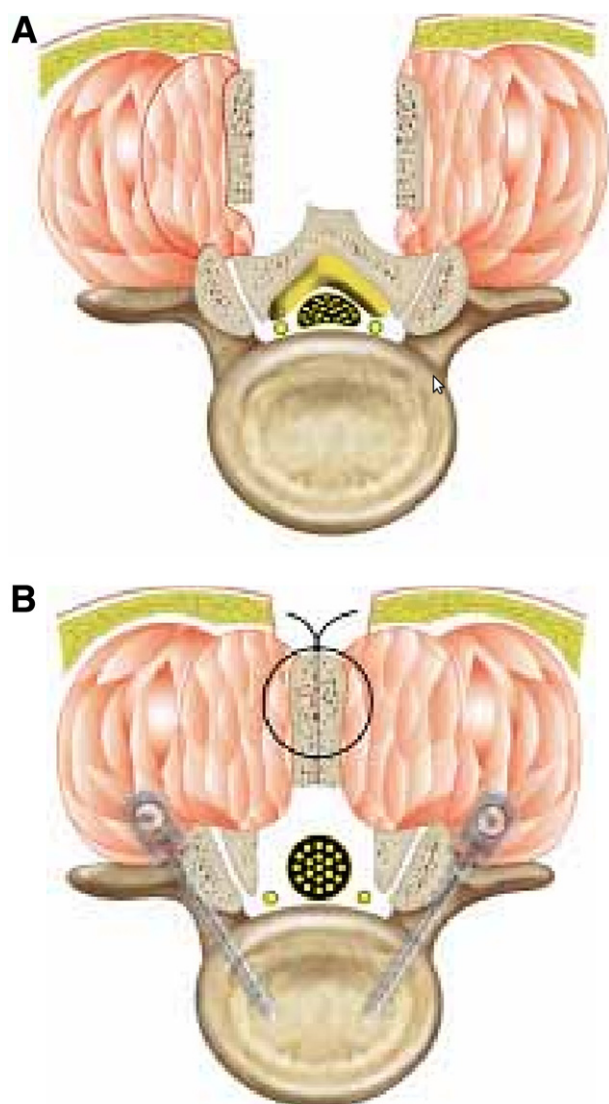


Fig. 2. Spinous process splitting approach. The advantages of the spinous process splitting laminectomy include minimizing damage to the posterior supporting structure, less dead space and less blood loss, and the prevention of muscular atrophy because nerves and vessels on the paraspinal muscle remain undamaged. Split the spinous process longitudinally in the middle (A). Suture the split spinous process after decompression and insertion of the pedicle screw (B).

peared, and the ROM was decreased statistically ( $P < .001$ , paired  $t$  test). Adjacent segment disease appeared in 3 patients (5.7%). One patient had pain in the lower extremity at 1 year after surgery, when falling during a walk. Disc herniation was observed in the upper adjacent segment, and discectomy and posterolateral lumbar fusion were performed because the patient did not agree to undergo conservative treatment. Two other patients had low-grade spinal canal stenosis in both upper and lower adjacent segments after surgery, but they have been followed up closely with conservative treatment because the symptoms were very mild. Loss of disc height at the lower adjacent segment was observed in 2 cases but produced no symptoms. There was 1 implant screw breakage; thus the failure

rate was 0.47% (1 of 214 screws). Screw loosening was observed in a 3-level stabilization asymptomatic patient.

#### Case presentation

A 74-year-old man was diagnosed with lumbar spinal canal stenosis. Symptoms included low-back pain for 2 years, pain and paralysis in the right lower extremity, and intermittent claudication. Stenosis in L4–5 was observed by myelography. A disc angle of  $-8^\circ$  in flexion (posterior angulation) and  $+4^\circ$  in extension was observed on radiographs. Surgery was performed for spinal canal stenosis with instability. The technique used was spinous process splitting laminectomy at L4–5 and stabilization with the SSCS in neutral position. The operation time was 79 minutes. Blood loss was 52 ml. Thirty-four months after surgery,  $2^\circ$  of motion remained in the disc (Fig. 3), and the JOA score had improved from 13 to 28.

#### Discussion

Proponents of spinal fusion and nonfusion have not yet reached consensus regarding degenerative disc disease treatment. Spinal fusion immediately stabilizes diseased segments in terms of pain relief while enhancing nerve recovery. Adjacent segment disease remains a midterm/long-term drawback with conventional spinal fusion. Ghiselli et al<sup>5</sup> reported revision surgery rates of 16.5% (5 years) and 36.1% (10 years) after lumbar posterior fusion (Kaplan-Meier method). Motion preservation technology with the purpose of achieving decompression and physiologic reconstruction with preservation of the physiologic spine motion has received attention.

Spinal motion preservation techniques include intradiscal stabilization by artificial disc and extradiscal stabilization that stabilizes segments outside of the disc. Lumbar artificial discs have been actively used mainly in Europe and the United States, but they are being reviewed because of complications. Extradiscal stabilization can be achieved in 2 ways. One is a flexible rod with a pedicle screw, and the other is an interspinous process spacer. There are many implants available in the European market, but only the Isobar TTL (Alphatec Spine, Carlsbad, California) and the Graf system (SEM, Co., Mountrouge, France) are available for use in Japan. For the Graf system, the revision surgery rate because of adjacent segment disease was 7% at 10-year minimum follow-up, and this system is considered to have less effect on adjacent segments.<sup>6</sup> The Graf system has less control for lateral bending and rotation.<sup>7</sup> Facet joint fusion due to strong posterior compression forces has been reported<sup>7</sup>; therefore it may be a less-than-ideal motion preservation system.

The SSCS differs from the previously mentioned implants. It is a pedicle screw-based system with a rigid rod, but the unique structure of having a hinge in the screw head allows for micromotion.<sup>8</sup> The screw hinges  $20^\circ$  in the sagittal plane and is rigid in the coronal plane and for rotational

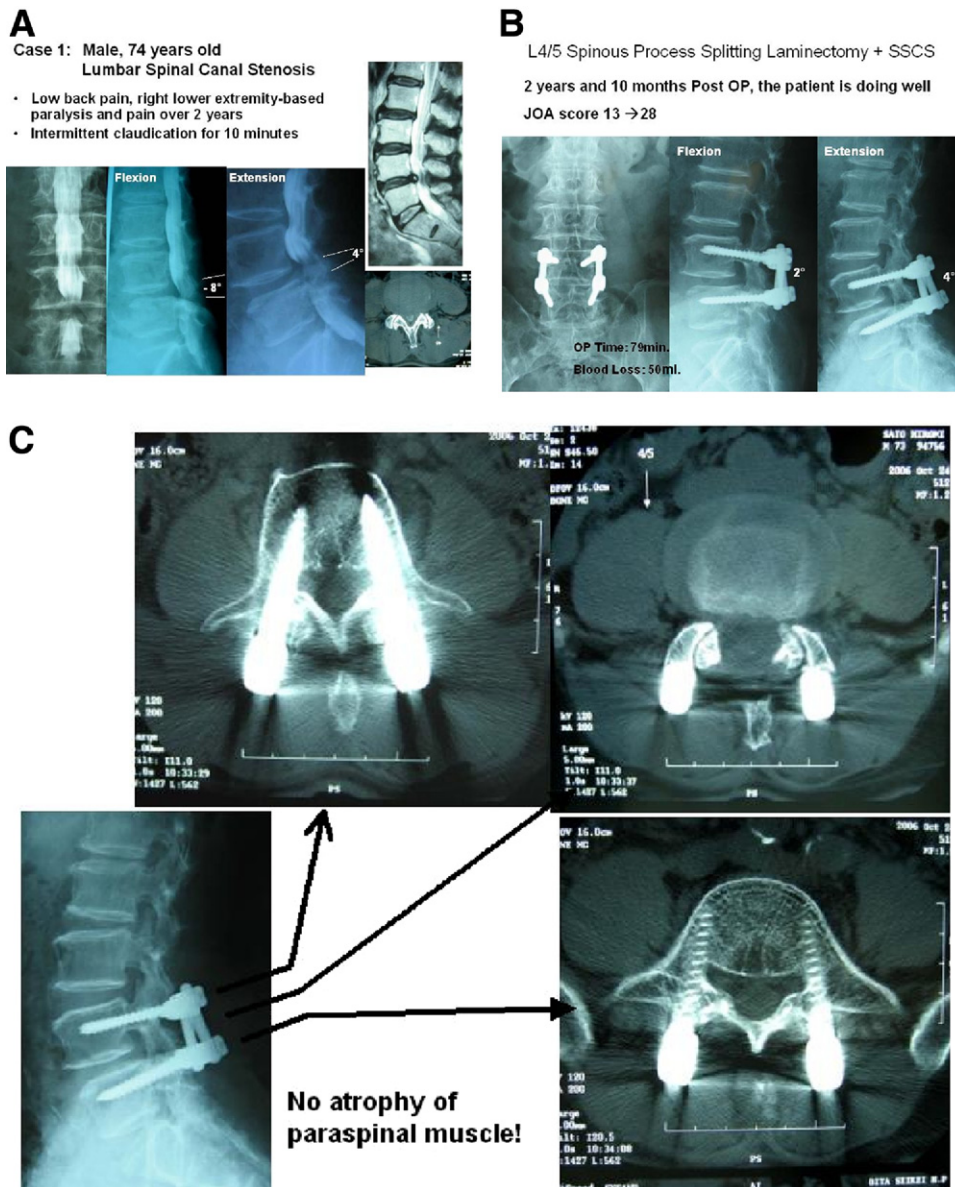


Fig. 3. Case presentation: Preoperative radiograph (A). Postoperative radiograph (B). Postoperative radiograph and computerized tomograph (C). Abbreviations: Post OP, post operation; OP time, operation time; JOA score, Japanese Orthopaedic Association score.

movement and rotational direction. The SSCS does not allow for lateral bending, rotation, or translation except for sagittal plane motion. Dynamic compression testing showed no implant failure after 10 million cycles (a 30-year lifetime)<sup>9</sup>; the screw hinges remained intact, showing no macroscopic signs of wear debris or loosening. Wear debris was not observed during revision surgery for 1 patient. Hinged posterior fixation has been reported to reduce load to the screw and may reduce breakage risk.<sup>8,10</sup> von Stempel et al<sup>2</sup> in a multicenter study reported breakage in 2 of 1,604 screws (0.12%) and 1 of 658 rods (0.15%). We found screw breakage in 1 of 214 screws, or a 0.47% implant failure rate. The implant failure rate was low for this nonfusion stabilization and avoided the morbidity associated with bone grafts. This hinged screw is more physiologic than a rigid

screw and shares load moderately with vertebral motion segments<sup>8,10</sup> while reducing load to the device. The instantaneous axis of rotation<sup>11</sup> of flexion and extension is located in the dorsal half of the disc on the superior vertebral body. With flexion instability, the disc has posterior (kyphotic) angulation centering on the instantaneous axis of rotation in flexion and the facet joint slides greatly. Neutral-position tightening of the SSCS rod and screw head controls facet joint slide and removes flexion instability. Thus flexion instability (instability in the sagittal plane direction) is removed. This allows 2° to 3° of micromotion in the disc through a hinge mechanism. This micromotion function prevents adjacent segment disease (Fig. 4). One root cause for adjacent segment disease is increased intradiscal pressure<sup>12</sup> in adjacent discs of operated segments, which can

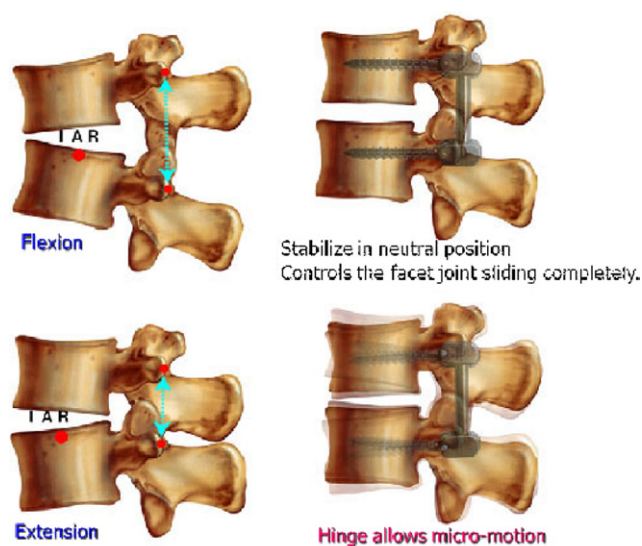


Fig. 4. Mechanism of SSCS stabilization. The instantaneous axis of rotation (IAR) of flexion and extension is located dorsal to the disc on the superior part of the vertebral body. If there is flexion instability, the disc would have posterior angulation centering on the IAR in flexion, with facet joint sliding. With the SSCS, the rod and the screw head are tightened in neutral position. Therefore facet joint sliding is controlled while still allowing micromotion of the disc because of the hinge between the screw head and the screw thread. It is thought that the micromotion works as a shock absorber, like a car suspension, and prevents adjacent segment disorder.

also occur with nonfusion stabilization.<sup>13</sup> Nonfusion stabilization compensates for some ROM in adjacent discs, which may be forced to increase by spinal fusion. In our study ROM in patients' discs was largely reduced, from  $9.6^\circ$  preoperatively to  $2.0^\circ$  postoperatively. Further consideration is necessary to find out whether the mean motion of  $2^\circ$  is enough to prevent adjacent segment disease.

Revision surgery was required in 1 case (1.9%) because of adjacent segment disease at less than 5 years. Although further long-term follow-up is necessary, short-term results are good with maintained stability of the spine. Using spinous process splitting laminectomy for decompression minimized the damage to the paraspinal muscle, which may lead to less lower-back discomfort after surgery.

The indications for the SSCS are (1) mild degenerative spondylolisthesis, (2) preserved anterior column support, (3) posterior angulation in the flexion position (flexion instability), and (4) sagittalization of facet joints. Instability was defined as the presence of more than  $5^\circ$  of posterior angulation, more than 3 mm of anterolisthesis, or sagittalization of facet joints. Further evaluation is necessary to determine the level of instability best managed by the SSCS (maximum instability in this study was  $12^\circ$  posterior angulation and 15 mm of anterolisthesis). We have no experience with the SSCS in patients with severe instability.

The contraindications are severe instability, degenerative scoliosis, foraminal stenosis, isthmic spondylolisthesis, trauma, and infection. Hinge motion is asymmetrically re-

stricted in degenerative scoliosis, increasing the risk of screw breakage. Short disc height with foraminal stenosis restricts SSCS application. In short, the SSCS is not suitable if correction for alignment is required. In case of isthmic spondylolisthesis, there is a risk of breakage because the facet joint is destroyed and the load to the device will be excessive.

Spinal fusion with instrumentation was developed for the purpose of scoliosis correction. In the early 1980s, the technique was applied to degenerative lumbar disease, and the application became frequently used. Is it necessary to correct the malalignment of the lumbar spine excessively? The concept of the motion preservation technology is to provide spinal decompression and stabilize physiologic instability.

Worldwide, companies are competing to develop marketable implants for spinal fusion with the aim of achieving bony fusion in alignment. The SSCS was originally developed to be used in conjunction with bone grafts. However, it was later found that with pseudarthrosis, the implant failure rate was low and patients were asymptomatic. Thus the SSCS has also become a nonfusion stabilization system. Long-term follow-up data are pending. There is room for modification of the SSCS device in that it only allows motion in the sagittal plane. Lumbar artificial disc revision has a potential high risk, given anatomic concerns. On the other hand, motion preservation technology with a posterior approach has expected growth potential because of surgeon familiarity and ease of revision. We expect further development of ideal instrumentation facilitated by advancements in technology.

## Conclusion

The results of SSCS nonfusion stabilization for 52 patients with unstable degenerative lumbar disease with a minimum 2-year follow-up found improved JOA scores and a Hirabayashi recovery rate of 76%. ROM was significantly controlled, from  $9.6^\circ \pm 4.2^\circ$  preoperatively to  $2.0^\circ \pm 1.8^\circ$  postoperatively. There was screw breakage in 1 case, but stability of the spine was maintained. Long-term follow-up focusing on adjacent segment disorder is required.

## References

1. von Stempel A, Stoss C, Moosmann D, Martin A. Non-fusion stabilization of the lumbar spine in the case of degenerative disease with a dynamic pedicle screw rod. *Coluna/Columna* 2006;5:27–34.
2. von Stempel A, Schiavone MA, Ozer F, et al. Non fusion stabilization with a non rigid but stable pedicle screw system—results of a multicentre study, Presented at Spine Arthroplasty Society - 7th Annual Conference, Berlin, Germany, May 1–5, 2007.
3. Watanabe K, Hosoya T, Shiraishi T, Matsumoto M, Chiba K, Toyama Y. Lumbar spinous process-splitting laminectomy for lumbar canal stenosis. Technical note. *J Neurosurg Spine* 2005;3:405–8.
4. Fujiwara A, Kobayashi N, Saiki K, Kitagawa T, Tamai K, Saotome K. Association of the Japanese Orthopaedic Association score with the

- Oswestry Disability Index, Roland-Morris Disability Questionnaire, and short-form 36. *Spine* 2003;28:1601–7.
5. Ghiselli G, Wang JC, Bhatia NN, Hsu WK, Dawson EG. Adjacent segment degeneration in the lumbar spine. *J Bone Joint Surg Am* 2004;86:1497–503.
  6. Kanayama M, Hashimoto T, Shigenobu K, Togawa D, Oha F. A minimum 10-year follow-up of posterior dynamic stabilization using Graf artificial ligament. *Spine* 2007;32:1992–6.
  7. Hadlow SV, Fagan AB, Hillier TM, Fraser RD. The Graf ligamentoplasty procedure. Comparison with posterolateral fusion in the management of low back pain. *Spine* 1998;23:1172–9.
  8. Scifert JL, Sairyo K, Goel VK, Grobler LJ, Grosland NM, Spratt KF, Chessel KD. Stability analysis of an enhanced load sharing posterior fixation device and its equivalent conventional device in a calf spine model. *Spine* 1999;24:2206–13.
  9. von Stempel A, Sukopp C, Basso S. Non-fusion versus fusion technique for the stabilization of the lumbar spine. Presented at Spine Arthroplasty Society - 4th Annual Conference, Vienna, Austria, May 4–7, 2004.
  10. Goel VK, Konz RJ, Grosland NM, et al. Hinged-dynamic posterior device permits greater loads on the graft and similar stability as compared with its equivalent rigid device: a three-dimensional assessment. *JPO* 2001;13:1–6.
  11. White AA III, Panjabi MM. *Clinical Biomechanics of the Spine*. 2nd ed. Philadelphia: Lippincott; 1990:88–9.
  12. Weinhoffer SL, Guyer RD, Herbert M, Griffith SL. Intradiscal pressure measurements above an instrumented fusion. A cadaveric study. *Spine* 2005;20:526–31.
  13. Kitahara K, Takano K, Hara T, et al. Effects of lumbar spinal instrumentation on the adjacent intradiscal pressure [in Japanese]. *J Soc Biomechanisms* 2005;26:121–6.