

Pseudotumor mimicking iliacus muscle abscess following a total hip arthroplasty with metal on metal articulation

A case report

Myung Rae Cho, MD, Chung Mu Jun, MD, Tae Bum Oh, MD, Jae bum Kwon, MD, Won Kee Choi, MD*

Abstract

Rationale: Cases of pseudotumor complicated after THA with metal-on-metal articulation as a bearing surface have been reported. Most of the pseudotumors occurred near or inside the hip joint, and usually have similar features with the infectious condition. We herein report a case of pseudotumor with huge size in the pelvic cavity mimicking features of iliacus muscle abscess.

Patients concerns: A 70-year-old female was referred to our emergency department due to huge mass in her right pelvic area on abdominal CT. She complained of mild febrile sensation, generalized weakness, and pain in her right leg for several months. The patient underwent metal-on-metal bearing THA 11 years ago for treatment of right-sided hip pain due to avascular necrosis.

Diagnosis: Percutaneous catheter drainage was performed for both therapeutic and diagnostic reasons. No microbes were cultured from the drained fluid, and signs of chronic inflammation were shown on pathology slide samples. The patient showed positive allergic reactions to cobalt and captan on allergic patch test, and serum cobalt levels was increased as 46.78 $\mu\text{g/L}$ (normal value, 0.11–0.64 $\mu\text{g/L}$). Biopsy samples of the cyst were consistent with the histological findings of pseudotumor reported by Willert et al.

Intervention: For the treatment of infection, primarily, the patient was surgically treated by irrigation, debridement, and bone bead insertion. Then, after 4 weeks of antibiotic treatment, revision surgery changing the metal-on-metal articulation into poly-on-metal articulation was performed.

Outcomes: CT scan at 1 year after surgery showed no findings of cyst inside the pelvic cavity. Although the patient complained of right sided hip pain (VAS score 2), she was able to perform activities of daily living.

Lessons: In patients who underwent metal-on-metal THA, pseudotumor mimicked the feature of periprosthetic infection may occur not only inside the hip joint but also in the pelvic cavity.

Abbreviations: THA = total hip arthroplasty, CT = computer tomography.

Keywords: metal on metal, pseudotumor, total hip arthroplasty

1. Introduction

In order to reduce wear after total hip arthroplasty (THA), numerous studies have been conducted for several decades.^[1–3] Bearing surfaces to reduce wear are highly crosslinked

polyethylene-on-metal, ceramic-on-ceramic, and metal-on-metal articulations. Pseudotumor is not uncommon complication, and reported in the 1980.^[4–6] This complication can be developed in all bearing surfaces involving metal-on-polyethylene, ceramic-on-polyethylene, ceramic-on-ceramic, and metal-on-metal articulations. Even though this lesion is not neoplastic lesion, it may frequently progress, resulting in the end of implant survival. The incidence of pseudotumor is from 0.27% to 5%, the size is usually less than 10 to 15 cm, and most of the cases arose near or inside the hip joint.^[7,8] Frequently this lesion has been confused as an infectious condition. Importantly, there are limited data on pseudotumor with the huge mass occurring in the pelvic cavity. We herein report a case of pseudotumor with huge mass occurring in the pelvic cavity but not inside the hip, mimicking features of iliacus muscle abscess.

Informed written consent was obtained from the patient for publication of this case report and accompanying images.

2. Case

A 70-year-old female was referred to our emergency department due to pain around the inguinal area. She complained of mild

Editor: N/A.

The authors have no conflicts of interests to disclose.

Department of Orthopaedic Surgery, College of Medicine, Daegu Catholic University, Daegu City, Republic of Korea.

* Correspondence: Won Kee Choi, Department of Orthopaedic Surgery, Daegu Catholic University Hospital, 3056-6, Daemyung-4-dong, Nam-gu, Daegu, Republic of Korea (e-mail: cwk1009@hanmail.net).

Copyright © 2019 the Author(s). Published by Wolters Kluwer Health, Inc. This is an open access article distributed under the terms of the Creative Commons Attribution-Non Commercial-No Derivatives License 4.0 (CCBY-NC-ND), where it is permissible to download and share the work provided it is properly cited. The work cannot be changed in any way or used commercially without permission from the journal.

Medicine (2019) 98:27(e16322)

Received: 17 January 2019 / Received in final form: 4 May 2019 / Accepted: 13 June 2019

<http://dx.doi.org/10.1097/MD.0000000000016322>

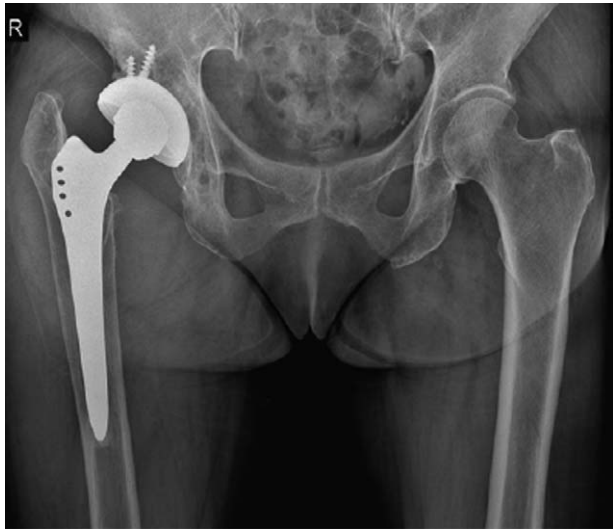

Figure 1. The patient underwent metal-on-metal bearing THA 11 years ago for treatment of right sided hip pain due to avascular necrosis.

febrile sensation, generalized weakness, and limping in her right leg for several months. There was no redness, heatness, and sinus tract. The patient underwent THA for treatment of right-sided hip pain due to avascular necrosis 11 years ago (Fig. 1). Instrument implanted was Zweymüller stem with metal-on-metal bearing surface (Alloclassic-SL; AlloPro AG, Baar, Switzerland). Despite of the operation, the patient suffered from consistent right hip pain of the visual analog scale (VAS) score 5. A huge cystic mass was detected in her right pelvic and hip area on abdominal computed tomography (CT) (Fig. 2). In laboratory findings, WBC count was 13,800 (normal range, 3600–9600) with the 82% neutrophil (normal range, 37%–72%), ESR 82 mm/hour (normal range, 0–20 mm/hour) and CRP 77.1 mg/L (normal range, <5 mg/L). Under the impression of the abscess, percutaneous catheter drainage was inserted into the iliacus cystic

mass for the diagnostic confirmation. Drained fluid was yellow to light orange color, and not turbid. In fluid analysis, glucose level was 74 mg/dl, protein 5.5 g/dl, PH 6.8, RBC 20,000/ μ l, and WBC 15,000/ μ l with 90% neutrophil. No microbes were cultured from the drained fluid, and PCR test for tuberculosis was negative. The patient showed positive allergic reactions to cobalt and captan on allergic patch test, and serum cobalt levels were increased as 46.78 μ g/L (normal value, 0.11–0.64 μ g/L). Even though the size of the mass was decreased, additional surgical management of irrigation and debridement (I&D) was performed for the confirmation on the infectious condition and removal of the remnant mass. Clear fluid was drained intraoperatively, and the neck Zweymüller stem was dented. Dent was located vertically at just beneath the edge of the artificial cobalt-chrome head. It was about 5 mm in length and 1 mm in depth. There was no visible metallic debri around the mass intraoperatively. Intraoperative frozen biopsy showed 10 neutrophils/high power field (HPF) at 1 zone. Not being free from the infectious condition, we inserted an antibiotic-loaded cement beads (Palacos R (zimmer) 40 mg mixed with vancomycin 4 g and tobramycin 80 mg) (Fig. 3). The patient was managed with the intravenous antibiotic treatment (ciprofloxacin + metronidazole) for a month. Intraoperative biopsy samples of the cyst showed fibrinous exudates and surrounding granulation tissues with scattered metallic particles, which were thought to be the consistent with the histological findings of pseudotumor reported by Willert et al (Fig. 4). After 4 weeks of an antibiotic treatment, inflammatory markers showed signs of improvement (WBC, ESR, CRP level). At postoperative 5 weeks revision surgery changing the metal-on-metal articulation into poly-on-metal articulation was performed. Except the well-fixed femoral stem, the acetabular cup, liner, and metal head were all replaced. Both female taper of the metal head and metal taper were grossly damaged (Fig. 5). Intraoperative frozen biopsy showed under 5 neutrophils/HPF, and there were no grossly signs of infection. Pelvic CT scan at 1 year after the revision surgery showed no findings of cysts inside the pelvic cavity. Although the patient complained of right sided hip pain (VAS score 2), she was able to perform activities of daily living.

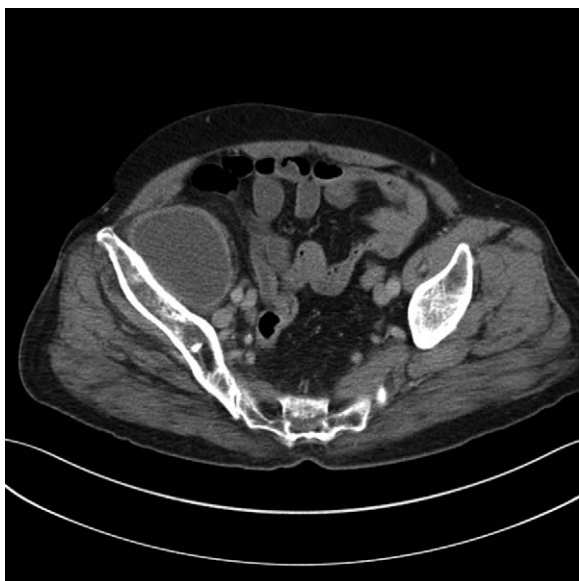

Figure 2. Pelvic CT scan revealed abscess-like cyst in the iliacus muscle.

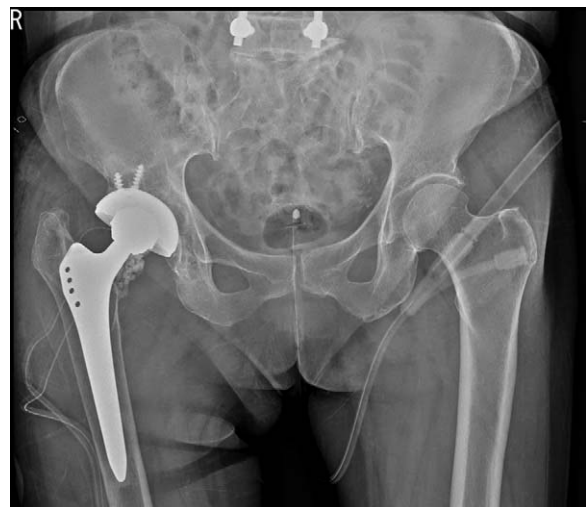

Figure 3. Since intraoperative frozen biopsy showed 10 neutrophils/high power field, antibiotic-loaded cement beads were inserted.

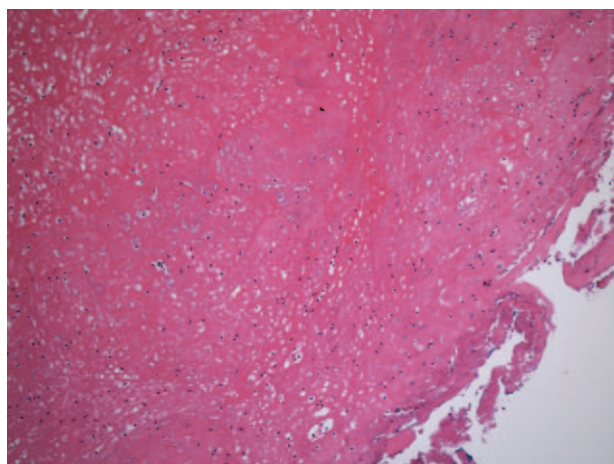


Figure 4. Histological finding showed chronic inflammation with perivascular lymphocytic aggregates.

3. Discussion

Compared to poly-on-metal articulation, metal-on-metal articulation is superior in linear wear rates. However, complications such as pseudotumors, which is thought to be an immunologic delayed hypersensitivity response to the metal particles, have been reported. Metal-on-metal hypersensitivity reactions are considered to be local hypersensitivity Type-IV reactions, also referred to as aseptic lymphocytic vasculitis-associated lesions (ALVAL).^[4] This local tissue reaction, described as an ALVAL was characterized by Willert et al^[9]



Figure 5. The female taper of the metal head showed signs of corrosive wear.

as having histologic features of chronic inflammation. Although clinical features of pseudotumor may show signs of chronic inflammation, it may also show signs of acute infection. However, most of the cases which have been reported showed cystic lesions of inside the hip joint.^[4,7,8] However, this case is a pseudotumor mimicked the features of iliacus muscle abscess. The medical team which treated the patient initially diagnosed case as iliacus intramuscular abscess and transferred the patient to our medical center. Since analysis of the fluid drained from the abscess showed chronic inflammation but not acute infection, we tried to check out the possibility of ALVAL. Also, it was not suitable for the definition of periprosthetic joint infection by Parvizi et al.^[10] After confirming positive allergic reactions to cobalt, checking the elevated serum cobalt level, and by confirming the findings of ALVAL in the biopsy sample, we diagnosed the iliacus intramuscular abscess as a pseudotumor. CT scans revealed no signs of osteolysis near the acetabular cup and the femoral stem. After the signs of infection subsided, revision surgery changing the metal-on-metal articulation into poly-on-metal articulation was performed. During the surgery, we checked the wear in the Morse taper of the femoral stem and the female taper of the metal head female taper. We did not replace the femoral stem, in order to prevent bone loss which may occur during the removal of the well-fixed stem. At 1 year after revision surgery, the patient did not show antalgic gait during ambulation, and showed improvement in her right hip pain (VAS score 5 -> 2). Also, follow-up CT scans did not show findings of any cyst-like lesions.

We experienced a case of pseudotumor mimicked the feature of iliacus muscle abscess. In patients who underwent metal-on-metal THA, pseudotumor mimicked the feature of periprosthetic infection may occur not only inside the hip joint but also in the pelvic cavity.

Once again, we emphasize that pseudotumor mimicked periprosthetic infection may occur not only inside the hip joint but also in the pelvic cavity.

Author contributions

Conceptualization: Myung Rae Cho, won Kee Choi.

Investigation: Tae Bum Oh.

Visualization: Chung Mu Jun.

Writing – original draft: Myung Rae Cho, Chung Mu Jun, Won Kee Choi.

Writing – review & editing: Myung Rae Cho, Tae Bum Oh, Jae Bum Kwon, Won Kee Choi.

References

- [1] Bozic KJ, Kurtz S, Lau E, et al. The epidemiology of bearing surface usage in total hip arthroplasty in the United States. *J Bone Joint Surg Am* 2009;91:1614–20.
- [2] Lee JM. The current concepts of total hip arthroplasty. *Hip Pelvis* 2016;28:191–200.
- [3] Yoon PW, Yoo JJ, Kim YJ, et al. The epidemiology and national trends of bearing surface usage in primary total hip arthroplasty in Korea. *Clin Orthop Surg* 2016;8:29–37.
- [4] Mikhael MM, Hanssen AD, Sierra RJ. Failure of metal-on-metal total hip arthroplasty mimicking hip infection. A report of two cases. *J Bone Joint Surg Am* 2009;91:443–6.
- [5] Jacobs JJ, Hallab NJ. Loosening and osteolysis associated with metal-on-metal bearings: a local effect of metal hypersensitivity? *J Bone Joint Surg Am* 2006;88:1171–2.
- [6] Griffiths HJ, Burke J, Bonfiglio TA. Granulomatous pseudotumors in total joint replacement. *Skelet Radiol* 1987;16:146–52.

- [7] Watters TS, Eward WC, Hallows RK, et al. Pseudotumor with superimposed periprosthetic infection following metal-on-metal total hip arthroplasty: a case report. *J Bone Joint Surg Am* 2010;92:1666–9.
- [8] Judd KT, Noiseux N. Concomitant infection and local metal reaction in patients undergoing revision of metal on metal total hip arthroplasty. *Iowa Orthop J* 2011;31:59–63.
- [9] Willert HG, Buchhorn GH, Fayyazi A, et al. Metal-on-metal bearings and hypersensitivity in patients with artificial hip joints. A clinical and histomorphological study. *J Bone Joint Surg Am* 2005;87:28–36.
- [10] Parvizi J, Zmistowski B, Berbari EF, et al. New definition for periprosthetic joint infection: from the Workgroup of the Musculoskeletal Infection Society. *Clin Orthop Relat Res* 2011;469:2992–4.