



Contents lists available at ScienceDirect

## Trauma Case Reports

journal homepage: <http://www.journals.elsevier.com/trauma-case-reports/>

## Case Report

Traumatic rupture of a solitary splenic hydatid cyst:  
A case report☆Moustafa Lakis<sup>a,c</sup>, Edith Hanna<sup>a</sup>, Michael G. Noujaim<sup>b</sup>, George Abi Saad<sup>a,c,\*</sup><sup>a</sup> American University of Beirut Medical School, Beirut, Lebanon<sup>b</sup> The University of Massachusetts Medical School, Worcester, MA, USA<sup>c</sup> Division of General Surgery, American University of Beirut Medical Center, Beirut, Lebanon

## ARTICLE INFO

## Article history:

Accepted 16 February 2015

Available online 23 April 2015

## Keywords:

*Echinococcus*  
Hydatid  
Trauma  
Splenectomy  
Cysts  
Surgery

## SUMMARY

The rupture of an *Echinococcus granulosus* hydatid cyst in the spleen due to trauma is a rare event. In this case report we describe the case of a 39-year-old Lebanese male victim of a motor vehicle accident with a ruptured solitary splenic hydatid cyst discovered by CT scan and excised during exploratory laparotomy.

Echinococcosis or hydatid disease is a parasitic infestation by the *Echinococcus* genus of tapeworm. The eggs of *E. granulosus*, a species of *Echinococcus*, are fecal-orally transmitted to human hosts, most often from dog feces, and manifest as cystic lesions termed hydatid. *E. granulosus* most commonly affects the liver (75%), lungs (15%), and rarely the spleen (2–5%) [1,2]. *E. granulosus* is particularly endemic to cattle rearing areas of the Middle East. Infected patients most commonly present with vague abdominal pain, as a result of mass effect or spontaneous rupture of the cyst. Nevertheless, patient presentation may be due to traumatic rupture of a hydatid cyst; however, this is very rare. Herein we report a case of traumatic rupture of a solitary splenic hydatid cyst in a 39-year-old male following a motor vehicle crash, managed following the Advanced Trauma Life Support (ATLS) protocol.

© 2015 The Authors. Published by Elsevier Ltd. This is an open access article under the CC BY-NC-ND license (<http://creativecommons.org/licenses/by-nc-nd/4.0/>).

☆ The authors of this case report have no conflicts of interest to disclose.

\* Corresponding author at: Abdel Aziz, Blue Bldg, 4th floor, American, University of Beirut Medical Center, Beirut, Lebanon. Tel.: +961 1350000x5680.

E-mail address: [ga17@aub.edu.lb](mailto:ga17@aub.edu.lb) (G.A. Saad).

## Case report

A previously healthy 39-year-old male presented to the emergency department 30 min after being involved in a motor vehicle collision. The patient was well appearing, hemodynamically stable, and alert with a Glasgow coma scale of 15. On physical examination, the patient's abdomen was distended with left upper quadrant tenderness and bilateral flank pain. There were no signs of rebound tenderness, peritoneal irritation or left shoulder pain. An IV contrast enhanced computed tomography (CT) scan of the abdomen and pelvis revealed a  $10.5 \times 10 \times 11$  cm cystic lesion in the spleen with heterogeneously increased central intensity indicative of active hemorrhage (Fig. 1). Additionally, a 7.5 cm laceration on the superior aspect of the spleen was noted with a subcapsular splenic hematoma involving more than 50% of the splenic surface suggesting a grade III splenic injury. CT scan also revealed hyperdense fluid in the left paracolic gutter indicating an intraperitoneal bleed. Shortly after the completion of the CT scans, the patient became hypotensive and was promptly treated with and responded to 2 L LR fluid-challenge resuscitation. This was the only time that the patient's condition became unstable. An exploratory laparotomy was performed 30 min after the time of admission and revealed a large hemoperitoneum and a ruptured splenic cyst with a structure resembling hydatid cystic membranes (Fig. 2). No other injuries were noted or sustained by the patient. A total splenectomy was performed and the peritoneal cavity was irrigated with cetrimide for 10 min. Thorough exploration of the abdomen revealed no other pathology. Post-operative pathological examination of the spleen confirmed the presence of a solitary cyst consistent with hydatid disease. Furthermore, scoleces of *E. granulosus* were noted in the splenic parenchyma immediately adjacent to the cyst. An indirect hemagglutination test for hydatid disease was negative ( $<1:32$ ). As long-term management, the patient was started on Albendazole 400 mg twice daily and he was followed for a period of 6 months. The patient made a full recovery.

## Discussion

Splenic hydatid cysts often present with non-specific symptoms such as dull abdominal pain, dyspepsia or constipation. Alternatively, they may be asymptomatic in 30% of patients. Nonetheless, these cysts can have serious complications, including fistula of the colon or perforation into the diaphragm or bronchial tree [3,4]. Most often, hydatid cysts rupture spontaneously. Rupture of a hydatid cyst secondary to trauma is very rare, especially so in the spleen, which is the organ least affected in patients with *E. granulosus* infestation.

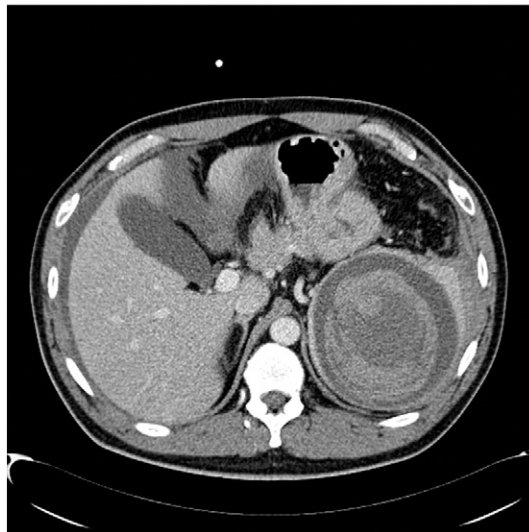
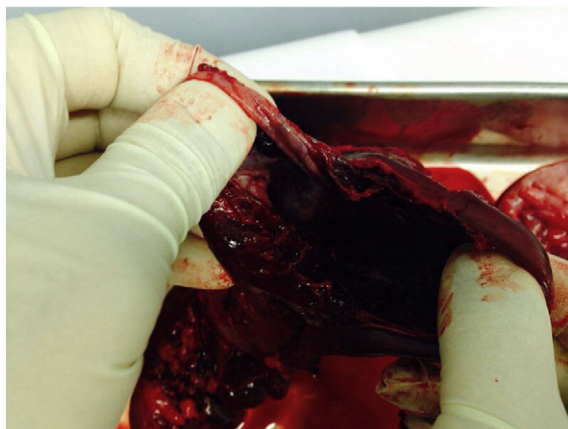


Fig. 1. Abdominopelvic computed tomography scan reveals a large cystic mass originating from the spleen. Increased central intensity is noted that is indicative of active hemorrhage into a pre-existing splenic cyst or a large pseudoaneurysm.



**Fig. 2.** Intra-operative image of the ruptured solitary splenic cyst.

CT scan is an important modality in the detection of hydatid cysts with 95% sensitivity [5]. CT findings normally include: calcified cyst wall, daughter cysts, and membrane detachment [6,7]. Interestingly, none of these findings were observed in our patient; thus, leading to a pre-operative differential diagnosis of simple splenic cysts, pseudoaneurysm of the splenic artery, cystic hemangioma or lymphangioma. Post-operative pathological examination of the excised spleen confirmed the diagnosis of a solitary hydatid cyst due to a parasitic infection by *E. granulosus*, a tapeworm endemic to the region.

Total splenectomy is the primary modality for managing splenic hydatid cysts; nevertheless, partial splenectomies may be considered as a treatment option that prevents post-splenectomy opportunistic infections [8]. The non-operative treatment of blunt trauma to solid organs, namely the spleen and liver, is currently the state-of-the-art modality of treatment in low-grade injuries and patients who are hemodynamically stable. However, in similar injuries, special caution should be taken and patients should be explored to avoid the immediate and long-term complications of ruptured hydatid cysts, such as anaphylactic shock and development of abdominal hydatidosis. In our patient's case, hemorrhaging and hemodynamic instability as a result of the ruptured cyst made a total splenectomy the more favorable treatment option. The patient was also empirically treated with cetrimide to prevent hydatidosis.

In conclusion, we describe a rare case of traumatic rupture of a solitary splenic hydatid cyst at the American University of Beirut Medical Center. Hydatid cysts due to echinococcosis must be considered in the differential diagnosis of cystic lesions of the spleen in endemic areas. We consider these findings to be key features for the diagnosis and treatment of ruptured splenic hydatid cysts.

## References

- [1] H. Singh, M.S. Arora, Primary hydatid cyst of the spleen, *Med. J. Armed Force India* 59 (2003) 169–170.
- [2] A. Mazumdar, G. Singh, N.M. Gupta, Primary splenic hydatid in adults, *Trop. Gastroenterol.* 21 (2) (Apr–Jun 2000) 78–79.
- [3] R.E. Ratyck, Tumours, cysts and abscesses of spleen, in: J.L. Cameron (Ed.), *Current Surgical Therapy*, 4th ed. Mosby, St Louis, 1992, pp. 518–521.
- [4] I. Alfageme, M. Martin, J. Hernandez, et al., Rupture of a long-standing splenic hydatid cyst into the bronchial tree, *Clin. Infect. Dis.* 19 (5) (Nov 1994) 992–994.
- [5] P. Polat, M. Kantarci, F. Alper, et al., Review hydatid disease from head to toe, *Radiographics* 23 (2) (Mar–Apr 2003) 475–494 (quiz 536–7).
- [6] I. Pedrosa, A. Saiz, J. Arrazola, et al., Review hydatid disease: radiologic and pathologic features and complications, *Radiographics* 20 (3) (May–Jun 2000) 795–817.
- [7] V. Durgun, S. Kapan, M. Kapan, et al., Primary splenic hydatidosis, *Dig. Surg.* 20 (1) (2003) 38–41.
- [8] A.H. Bhandarwar, A.N. Katara, G.D. Bakhshi, et al., A review of literature – Splenic Hydatidosis, *BHJ* 44 (2008) 4.