

# A Prospective Randomized Comparative Clinical trial of Hysteroscopic Septal Resection Using Conventional Resectoscope Versus Mini-resectoscope

Kallol Kumar Roy, S. M. Anusha, Rakhi Rai, Anamika Das, Rinchen Zangmo, Seema Singhal

Department of Obstetrics and Gynaecology, AIIMS, New Delhi, India

ABSTRACT

**Context:** Hysteroscopic metroplasty (HM) is the gold standard treatment for women with septate uterus with recurrent pregnancy loss. Miniresectoscope requires less cervical dilatation as compared to conventional resectoscope. Very few studies are available in the literature on use of miniresectoscope for operative purpose. **Aim of the Study:** This study aimed to compare operative and postoperative outcome parameters using conventional versus mini resectoscope (MR) for hysteroscopic septal resection (HSR). **Study Settings and Design:** This was a prospective randomized controlled trial conducted in the Department of Obstetrics and Gynaecology from July 2017 to May 2019. **Materials and Methods:** Forty patients fulfilling the inclusion criteria were recruited and randomized into two groups. In Group A (20 patients), HSR was done using conventional resectoscope (CR) and in Group B (20 patients), MR was used. The various parameters recorded were cervical dilatation time, operating time, intraoperative complications, postoperative pain, and hospital stay and reproductive outcome post surgery in both groups. **Results:** Data analysis was carried out using SPSS IBM software version 20.0. The mean operating time was comparable but cervical dilatation time was significantly more in Group A. The duration of hospital stay was significantly less in Group B. There were no differences in adequacy of vision in both the groups but area of field was less in MR group. Four out of nine patients with infertility conceived after surgery. 65% in Group A and 70% in Group B conceived during follow up. **Conclusion:** Our study showed that hysteroscopic metroplasty with MR, has comparable efficacy to CR in terms of good vision and septal resectability with added advantages of shorter cervical dilatation time, ease of entry of resectoscope, shorter operative time and significantly reduced postoperative morbidity in terms of less pain. However, the field of vision is less and resection time is more, hence more expertise is required. Further larger randomized trials are required.

**KEYWORDS:** Hysteroscopy, mini resectoscope, monopolar, resectoscope, septal resection

## INTRODUCTION

Failure of resorption of tissue connecting two Mullerian ducts leads to the formation of septate uterus.<sup>[1]</sup> The prevalence of uterine anomalies is 5.5% in general population, 13.3% in women with previous miscarriages, 8% in infertile women, and 24.5% in

women with miscarriage and infertility.<sup>[2]</sup> Septate uterus is classified as class V according to the American

**Address for correspondence:** Dr. Rakhi Rai, Fellow Minimally Invasive Gynaecological Surgery, Teaching Block, 3<sup>rd</sup> Floor, Department of Obstetrics and Gynecology, AIIMS, New Delhi - 110 029, India. E-mail: drrakhi81@yahoo.co.in

Received: 06-02-2020

Revised: 04-06-2020

Accepted: 14-01-2021

Published: 30-03-2021

### Access this article online

Quick Response Code:



**Website:**  
www.jhrsonline.org

**DOI:**  
10.4103/jhrs.JHRS\_12\_20

This is an open access journal, and articles are distributed under the terms of the Creative Commons Attribution-NonCommercial-ShareAlike 4.0 License, which allows others to remix, tweak, and build upon the work non-commercially, as long as appropriate credit is given and the new creations are licensed under the identical terms.

**For reprints contact:** WKHLRPMedknow\_reprints@wolterskluwer.com

**How to cite this article:** Roy KK, Anusha SM, Rai R, Das A, Zangmo R, Singhal S. A prospective randomized comparative clinical trial of hysteroscopic septal resection using conventional resectoscope versus mini-resectoscope. J Hum Reprod Sci 2021;14:61-7.

Fertility Society (AFS).<sup>[3]</sup> Patients with septate uterus may remain asymptomatic or may present as first or second trimester abortions or obstetric complications such as preterm delivery, malpresentation, and increased cesarean section.<sup>[4-7]</sup> It may be an incidental finding<sup>[8]</sup> or diagnosed on imaging such as hysterosalpingography, saline infusion sonogram, three-dimensional ultrasound, and magnetic resonance imaging (MRI).<sup>[9]</sup> Hysteroscopic metroplasty (HM) is the gold standard treatment for women with septate uterus with recurrent pregnancy loss. Due to its simplicity, reproducibility, and low morbidity, it can also be considered in women more than 35 years, unexplained infertility and planned for assisted reproductive technology.<sup>[10]</sup>

Conventional resectoscope (CR) using 9 mm working element with 4 mm telescope is widely used for hysteroscopic septal resection (HSR). It requires cervical dilatation up to 9 mm. Cervical dilatation may lead complications such as cervical lacerations, cervical incompetence with increased operating time.<sup>[11]</sup> Mini-resectoscope (MR) with outer sheath of 5 mm using 2.9 mm telescope needs cervical dilatation only up to 5 mm, thereby reducing the complications and hence intraoperative and postoperative morbidity.<sup>[12]</sup>

Very few studies are available in the literature on use of MR for operative procedures.<sup>[13-15]</sup> Mini-resectoscope has not been compared with CR for HSR so far. Therefore, there was a need to study mini resectoscope with 2.9 mm telescope for HSR for its feasibility and to compare with conventional one in terms of difficulty in dilatation, operative time, intraoperative complications, postoperative morbidity, menstrual and reproductive outcome.

## MATERIALS AND METHODS

This was a prospective randomized controlled trial conducted in the Department of Obstetrics and Gynaecology from July 2017 to May 2019 after taking ethical clearance from Institute's Ethics Committee. Uterine septum was defined by AFS (depth of external fundal indentation was <1 cm and internal fundal indentation was >1.5 cm). The indentations were measured after obtaining a coronal view with visible intramural parts of both the Fallopian tubes. Written informed consent was taken from all the patients. A total of 40 patients with uterine septum who fulfilled the inclusion criteria were recruited and further randomized into two groups. The inclusion criteria were uterine septum diagnosed on USG, MRI, or hysteroscopy with recurrent abortions or preterm deliveries <30 weeks and infertility). On hysteroscopy, septum was diagnosed by deep seated ostia with a septum dividing uterus

into two uterine cavities. Randomization was done by computer-generated random numbers. Patients were blinded to the study groups. The single observer who noted the parameters such as cervical dilatation time, operating time, fluid deficit, intraoperative complications, postoperative pain, and hospital stay was blinded to the instrument used and study groups. There was allocation concealment. In Group A (20 patients), HSR was done using CR [Figure 1] and in Group B (20 patients), MR [Figure 2] was used for septal resection. Patients with myoma, active genital tuberculosis, abnormal semen analysis or any other cause of recurrent pregnancy loss (APLA, Diabetes mellitus, Thyroid disorders, abnormal karyotype) were excluded [Figure 3]. HM was done in proliferative phase under general anesthesia by a single surgeon. In Group A (conventional, Karl Storz, Germany), cervix was dilated with Hegar's dilator up to 9 mm. A 9 mm working element along with sheath and 4 mm 30-° telescope equipped with a monopolar Collin's knife was introduced into the uterine cavity using 1.5% glycine with an inflow pressure of 75–100 mmHg and cutting current of 60–80 watt. In Group B (MR, Karl Storz, Germany), cervix was dilated up to 5 mm. A 5 mm working element with a sheath and 2.9 mm telescope with monopolar Collin's knife was used. The septum was divided in a cephalad direction until hysteroscope could be moved from one cornua to another without any obstruction and both tubal ostia were visualized simultaneously.

Input/output was strictly monitored. The procedure was stopped whenever fluid deficit reached 1000 ml. Serum electrolytes were checked preoperatively and postoperatively in all the patients. The various parameters including time required for cervical dilatation, operating time, intraoperative complications such as cervical injuries, bleeding, uterine perforation and fluid absorption, postoperative morbidity like postoperative pain and



**Figure 1:** Conventional resectoscope with accessories

hospital stay were recorded by a single observer who was blinded with respect to the instrument used or study groups. Pain was assessed by 10-point visual analogue scale score. Long-term consequences like cervical incompetence were studied. Postoperatively, tablet estradiol valerate 4 mg a day was given for 6 weeks to prevent intrauterine adhesions. Relook hysteroscopy was done after 6 weeks in all patients to assess for any remnant uterine septum or adhesions and second

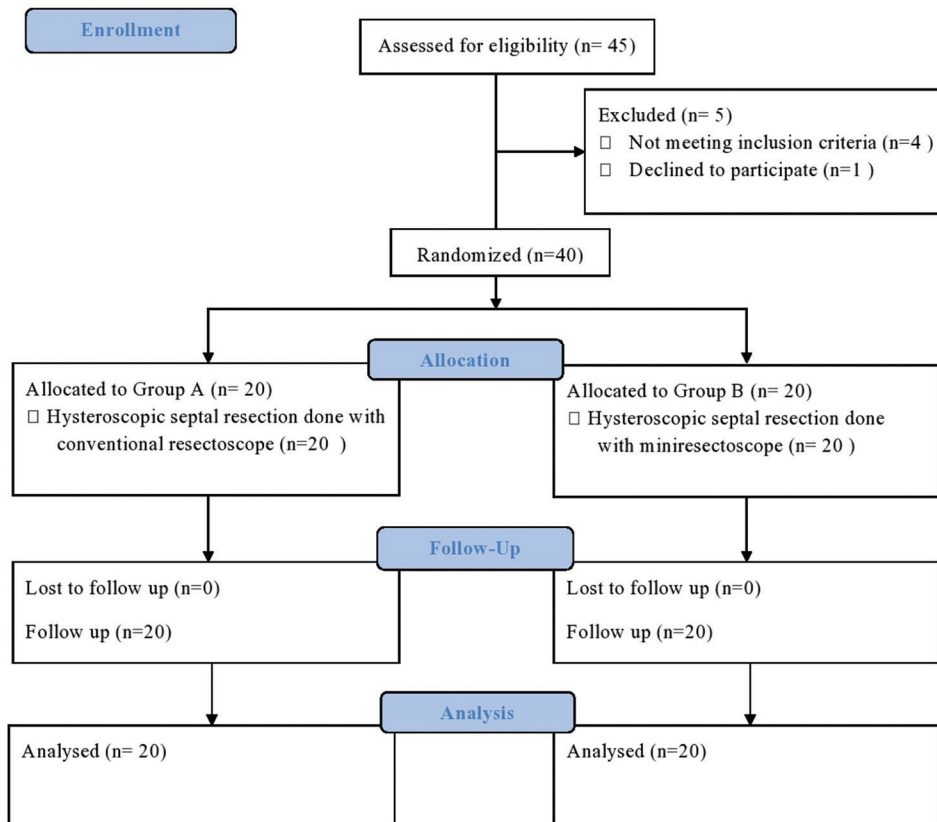
surgery (repeat HSR or adhesiolysis) was performed accordingly. Patients were advised to plan conception 2 months after primary or second surgery. Patients were followed for minimum 6 months every 2 months. The various variables studied were menstrual calendar, number of conceptions, outcome of pregnancy, and postoperative adhesion formation. All the patients who conceived post septal resection were followed up till the final outcome of the pregnancy (delivery or abortion). Cervical length monitoring was done in patients who conceived and history or ultrasound indicated cervical cerclage was inserted accordingly. The primary outcome measures were to compare conventional versus mini-resectoscope for HSR in terms of difficulty in cervical dilatation, cervical dilatation time, operative time, visual acuity, and intraoperative complications. The secondary outcome measures included comparison of conventional versus mini-resectoscope for HSR in terms of postoperative pain, hospital stay, and menstrual outcome.

**Statistical analysis**

An earlier study by Colacurci *et al.*<sup>[16]</sup> had demonstrated that the operating time ( $23.4 \pm 5.7$ ) using unipolar knife was significantly higher compared to 5 mm diameter hysteroscope ( $16.9 \pm 4.7$  mm). Presuming that similar finding will be obtained for the present study, an



**Figure 2:** Mini-resectoscope with accessories



**Figure 3:** Consort flow diagram depicting patient participation and follow-up

adequate sample of 30 in each group will have 80% power at 5% level of significance in detecting statistical significance. However, due to time constraints and availability of patients based on inclusion and exclusion criteria, It was proposed to have 20 patients in each group. Data analysis was carried out using SPSS IBM software version 20.0. Frequency distributions were computed for all categorical variables and Chi-square/Fisher's exact test as appropriate was applied for comparing frequency data of cross categories. For continuous variables, descriptive statistics such as mean, median, standard deviation, and range values were calculated. To test the significance difference between mean of two groups, Student's *t* independent test was applied. For biochemical parameters changes in values between pre and post was compared within each group using Student's *t* paired test. For all statistical tests,  $P < 0.05$  was considered as statistically significant.

## RESULTS

This study was conducted to compare HSR using CR (Group A, 20 cases) versus MR (Group B, 20 cases) in terms of operative and postoperative outcome. None of the patients had to be shifted from Group A to Group B due to difficulty in cervical dilatation. There is no significant cost difference between two groups.

The mean age, clinical presentation, menstrual pattern were comparable in two groups [Table 1]. 22.5% patients presented with infertility (12.5% with primary infertility and 10% with secondary infertility). There were two patients with complete septum in Group A and rest 18 patients had partial septum. In Group B, none of the patients had complete septum.

The mean operating time was comparable in both groups ( $11.2 \pm 1.31$  min in Group A vs.  $10.9 \pm 3.04$  min in Group B,  $P = 0.789$ ) but cervical dilatation time was

**Table 1: Demographic and preoperative profile of patients**

	Group A	Group B	P
Mean age $\pm$ SD	27.6 $\pm$ 3.53	27.7 $\pm$ 2.34	0.916
	Number of patients, n (%)	Number of patients, n (%)	P
Clinical presentation			
Bad obstetric history	15 (75)	16 (80)	0.99
Secondary infertility	2 (10)	2 (10)	0.99
Primary infertility	3 (15)	2 (10)	0.99
Menstrual cycle			
Normal	19 (95)	19 (95)	0.999
Oligomenorrhea	1 (5)	1 (5)	
Previous obstetric history			
Abortions	11 (64.7)	13 (72.2)	0.725
Preterm deliveries	6 (35.3)	3 (16.7)	0.264
Extent of septum			
Partial	18 (90)	20 (100)	0.487
Complete	2 (10)	0	0.487

SD=Standard deviation

**Table 2: Preoperative, operative, and postoperative parameters in two groups**

Parameter	Group A	Group B	P
Mean operating time (min $\pm$ SD)	11.2 $\pm$ 1.31	10.9 $\pm$ 3.04	0.789
Cervical Dilatation time (min $\pm$ SD)	3.08 $\pm$ 0.62	1.69 $\pm$ 0.33	<0.001
Duration of hospital stay (h)	6.02 $\pm$ 0.97	4.67 $\pm$ 0.63	<0.001
Postoperative pain score at 2 h postsurgery	6.05 $\pm$ 0.68	4.05 $\pm$ 0.68	0.049
Fluid deficit (ml)	320.0 $\pm$ 59.5	350.0 $\pm$ 58.6	0.894
Mean preoperative sodium level (mEq/ml)	136.85 $\pm$ 1.75	136.70 $\pm$ 2.08	0.877
Mean postoperative sodium level (mEq/ml)	138.45 $\pm$ 1.95	138.55 $\pm$ 2.08	0.877
Conception rate (%)	65	70	0.480

SD=Standard deviation

**Table 3: Comparison of reproductive outcome before and after metroplasty**

Variables	Before metroplasty (%)	After metroplasty (%)	P
Number of patients with miscarriages	24 (68.6) ( $\geq 2$ miscarriages)	5 (18.5)	<0.001
Number of term deliveries	4 (11.4)	21 (77.8)	<0.001

significantly more in Group A ( $3.08 \pm 0.62$  min in Group A vs.  $1.69 \pm 0.33$  min in Group B,  $P < 0.001$ ) but time for septal resection was more in Group B. The duration of hospital stay was significantly less in Group B ( $6.02 \pm 0.97$  h in Group A vs.  $4.67 \pm 0.63$  h in Group B,  $P < 0.001$ ) [Table 2] but the additional 1 h of postoperative stay in conventional Group A has no major practical concern.

There were no differences in adequacy of vision in both the groups but the field of vision was less in MR group. There were no intraoperative and postoperative complications in both the groups.

Second look hysteroscopy was done after 6 weeks in all patients. No postoperative adhesions were found in either group. Three (15%) patients had remnant septum  $>1$  cm in either group. All these 6 patients underwent repeat HSR. Normal cavity with no remnant septum or adhesions was found in these 6 patients on repeat second look hysteroscopy after 6–8 weeks of second surgery.

Patients were followed up over the time for menstrual and pregnancy outcome. Both the patients with oligomenorrhea (one from each group) continued to have oligomenorrhea after surgery. One patient from Group A developed menorrhagia after surgery.

Out of total 9 patients with infertility, 4 patients conceived and delivered at term. None of these patients had abortion or ectopic pregnancy.

There was significant reduction in abortion rate from 68.6% to 18.5% ( $P < 0.001$ ) and significant increase in term delivery rate (11.4% to 77.8%,  $P < 0.001$ ) [Table 3].

Thirteen patients (65%) in Group A and 14 (70%) in Group B conceived during follow-up. 92.3% patients in Group A and 64.3% in Group B had term delivery after surgery. A total of 5 patients had abortion [Table 4]. All pregnant patients were booked in our antenatal clinic. Cervical length monitoring was done by ultrasound. Two patients in Group A had short cervical length ( $<2.5$  cm) and underwent cervical cerclage during pregnancy and none of the patients in Group B required cerclage.

## DISCUSSION

Septate uterus is the most common congenital uterine anomaly in high risk population.<sup>[1,2]</sup> HM is the treatment

of choice. To date, there is limited literature available comparing the larger diameter CR to the smaller hysteroscope versapoint device,<sup>[16,17]</sup> but no comparative study comparing conventional versus MR for HSR has been reported so far.

In the recent years' introduction of mini-hysteroscope revolutionized the field of hysteroscopic surgery.<sup>[13-15]</sup> Reducing the size of hysteroscope is of greater importance in reducing the pain and cervical injuries. There is lack of literature comparing conventional and MR for HM.

It has been shown that surgeon experience with mini-hysteroscopy is not much important for the acceptability and success of the procedure.<sup>[18,19]</sup> They suggested the usage of MR by the surgeons with less experience and where difficult dilatation is expected.<sup>[18]</sup> In a study conducted by Angelis, it was found that pain and failure rate were less with mini hysteroscope and the image quality was as high as conventional one.<sup>[15]</sup> This can be explained by brightness and high quality of lens used in mini-hysteroscope in this study. Brightness and field and angle of view are comparable or better than the conventional telescopes. Broader angle of view permits better visualization of the cavity with lesser handling of the instrument.<sup>[20]</sup> Another explanation is higher washing capacity of uterine cavity. Small size permits water to flow more easily through the cervical canal than large-sized hysteroscopes which seal the canal. More efficient cleaning of uterine cavity could occur with larger quantity of water flowing into the cavity. This shows that mini resectoscopes provide satisfactory washing of uterine cavity without an outflow channel.<sup>[21]</sup>

Similarly, in our study, the clarity of vision was comparable in both conventional and mini resectoscope group but on the contrary, we found that the area of the field is less with MR, hence a little more experience is required for resection.

Colacurci *et al.*<sup>[16]</sup> compared HSR using 26F resectoscope with monopolar knife and 5 mm diameter hysteroscope with versapoint device. They found that operative time was significantly greater in CR group than in small diameter hysteroscope group ( $23.4 \pm 5.7$  vs.  $16.9 \pm 4.7$  min respectively). Youssef<sup>[17]</sup> compared monopolar resectoscopy with unipolar knife with mini-hysteroscopy with bipotrode 5 Fr bipolar electrode and found that operative time was more with CR ( $25.4 \pm 3.2$  vs.  $15.6 \pm 2.2$  min). Similar results were found in our study, i.e., shorter operating time ( $10.9 \pm 3.04$  min vs.  $11.2 \pm 1.31$  min) in MR group although the Difference was statistically not significant. The probable explanation for this is lesser cervical

**Table 4: Posttreatment pregnancy outcome in both the groups**

Group	Group A (%)	Group B (%)	Total (%)	P
Abortion	1 (7.7)	4 (28.6)	5 (18.5)	0.326
Term deliveries	12 (92.3)	9 (64.3)	21 (77.8)	0.165
Preterm deliveries	0	1 (7.1)	1 (3.7)	0.99
Total number of pregnancies	13	14	27	

dilatation time ( $1.69 \pm 0.33$  min vs.  $3.08 \pm 0.62$  min) with mini resectoscope in Group B. The operating time is the time from cervical dilatation to completion of resection of uterine septum. Although the operating time is slightly more in Group A but the resection time (time from start of uterine septum resection to completion of resection) is less in CR group as the tip of CR is larger than tip of MR.

Five patients out of 80 in conventional group required hospitalization but none in smaller diameter resectoscope group required hospitalization in a study by Colacurci *et al.*<sup>[16]</sup> However, the mean length of stay postsurgery was not statistically significantly different amongst the two groups ( $7.0 \pm 3.5$  h in Group A and  $6.3 \pm 2.2$  h in Group B). In our study, duration of hospital stay was significantly more in group A ( $6.02 \pm 0.97$  h) than Group B ( $4.67 \pm 0.63$  h) due to more postoperative pain.

Roy *et al.*<sup>[21]</sup> compared hysteroscopic adhesiolysis with conventional and MR and found that cervical dilatation time and postoperative pain score were significantly less in MR group. Various studies have reported lower pain score with mini-hysteroscope as compared to the conventional hysteroscope<sup>[13,14,22]</sup> as seen in our study also (postoperative pain score at 2h  $4.05 \pm 0.68$  in MR vs  $6.02 \pm 0.97$  in CR group). Reduction in the hysteroscope diameter by 1–2 mm, decreases its size by 50% and 75%, respectively, leading to a considerable difference in the ease of insertion and also reduces the pain of the procedure significantly.<sup>[20]</sup> Lower pain scores after the procedure were probably due to lesser cervical dilatation required in mini-resectoscope group. Thus, mini-resectoscope provides similar vision with lesser pain as compared to CR.

Low rate of complications had been reported in MR group.<sup>[23]</sup> The volume of fluid used for distension was much less with smaller hysteroscope in a study by Youssef<sup>[17]</sup> ( $710 \pm 120.4$  vs.  $1103 \pm 350.5$  ml,  $P < 0.001$ ). However, in our study, fluid deficit in Group A was not statistically significantly different from Group B ( $320.0 \pm 59.5$  ml in Group A vs.  $350.0 \pm 58.6$  ml in Group B). Although *per se* uterine septum resection took less time in Group A due to larger CR tip, so fluid absorption and deficit should be more with MR group. However, probably due to experience of the operating surgeon, procedures took less time in both the groups. Hence, fluid deficit although was more in MR group but it was statistically significantly not different from conventional resectoscope. No major and minor complications were encountered in both the groups. This could be due to the relatively shorter duration of procedure in both the groups.

HM improves the reproductive outcome in patients with bad obstetric history.<sup>[24]</sup> Similar results were found in our study, i.e., significant reduction in abortion rate (80.2 to 15.2%), and increase in term deliveries (4.2 to 36.1%).

Pabuccu *et al.*<sup>[25]</sup> and Colacurci<sup>[26]</sup> in their study reported five preterm deliveries in women after HSR done for unexplained infertility (one in women with cervical cerclage and remaining four in women without cerclage). In our study, there was one preterm vaginal delivery. Two patients from Group A needed ultrasound indicated cervical cerclage during pregnancy. This cervical incompetence could be because of more cervical dilatation (up to 10 mm) required during septal resection in CR group.

Only few studies are available comparing reproductive outcome of HSR using conventional versus MR.

Colacurci *et al.*<sup>[16]</sup> studied HM in 160 patients using 26F resectoscope (10 mm resectoscope, Group A) versus small diameter hysteroscope (5 mm versapoint device, Group B). No significant differences were reported between the two groups in terms of conception rate (70% Group A and 76.9% in Group B), live birth rate (81.6% in Group A; 84% in Group B), and abortion rate (18.4% in Group A; 16% in Group B). Youssef<sup>[17]</sup> also found comparable reproductive outcome in two groups. In our study, it was found that the conception rate was 65% in Group A and 80% in Group B, abortion rate was 7.7% in Group A and 20% in Group B and live birth rate was 30.8% in Group A and 35.0% in Group B.

The strength of the study is that it was a randomized clinical trial. The weakness of the study is that it involved small number of patients; larger studies are required for more definitive evidence. The duration of study was short to compare the reproductive outcomes.

### Implications for research and practice

Further, larger randomized studies with high quality data comparing CR and MR are required for more definitive evidence.

Mini-resectoscope can be used for HSR as it has comparable outcome as CR with added advantages of lesser cervical dilatation required, shorter operative time and significantly reduced postoperative pain but needs more expertise due to reduced field of vision and prolonged resection time.

### CONCLUSION

Our study showed that HM with MR, has comparable efficacy to CR in terms of good vision and septal resectability outcome with added advantages of shorter

cervical dilatation time, ease of entry of resectoscope, shorter operative time and significantly reduced postoperative morbidity in terms of less pain. However, at the same time, reduced field of vision and prolonged resection time required with MR needs more expertise. Further, larger randomized studies with high quality data comparing CR and MR are required for more definitive evidence.

### Financial support and sponsorship

Nil.

### Conflicts of interest

There are no conflicts of interest.

### REFERENCES

- Pfeifer S, Butts S, Dumesic D, Gracia C, Vernon M, Fossum G, *et al.* Uterine septum: A guideline. *Fertil Steril* 2016;106:530-40.
- Chan YY, Jayaprakasan K, Zamora J, Thornton JG, Raine-Fenning N, Coomarasamy A. The prevalence of congenital uterine anomalies in unselected and high-risk populations: A systematic review. *Hum Reprod Update* 2011;17:761-71.
- The American Fertility Society classifications of adnexal adhesions, distal tubal occlusion, tubal occlusion secondary to tubal ligation, tubal pregnancies, Müllerian anomalies and intrauterine adhesions. *Fertil Steril* 1988;49:944-55.
- Buttram VC, Gibbons WE. Müllerian anomalies: A proposed classification. (An analysis of 144 cases). *Fertil Steril* 1979;32:40-6.
- Selvaraj P, Selvaraj K. Reproductive outcome of septate uterus following hysteroscopic septum resection. *J Hum Reprod Sci* 2010;3:143.
- Grimbizis G, Camus M, Clasen K, Tournaye H, De Munck L, Devroey P. Hysteroscopic septum resection in patients with recurrent abortions or infertility. *Hum Reprod* 1998;13:1188-93.
- Venetis CA, Papadopoulos SP, Campo R, Gordts S, Tarlatzis BC, Grimbizis GF. Clinical implications of congenital uterine anomalies: A meta-analysis of comparative studies. *Reprod Biomed Online* 2014;29:665-83.
- Li Y, Phelps A, Zapala MA, MacKenzie JD, MacKenzie TC, Courtier J. Magnetic resonance imaging of Müllerian duct anomalies in children. *Pediatr Radiol* 2016;46:796-805.
- Olpin JD, Moeni A, Willmore RJ, Heilbrun ME. MR Imaging of Müllerian fusion anomalies. *Magn Reson Imaging Clin N Am* 2017;25:563-75.
- Lourdelle E, Cabry-Goubet R, Merviel P, Grenier N, Oliéric MF, Gondry J. Septate uterus: Role of hysteroscopic metroplasty. *Gynecol Obstet Fertil* 2007;35:811-8.
- Litta P, Spiller E, Saccardi C, Ambrosini G, Caserta D, Cosmi E. Resectoscope or versapoint for hysteroscopic metroplasty. *Int J Gynecol Obstet* 2008;101:39-42.
- Litta P, Cosmi E, Saccardi C, Esposito C, Rui R, Ambrosini G. Outpatient operative polypectomy using a 5 mm-hysteroscope without anaesthesia and/or analgesia: Advantages and limits. *Eur J Obstet Gynecol Reprod Biol* 2008;139:210-4.
- Cicinelli E, Parisi C, Galantino P, Pinto V, Barba B, Schonauer S. Reliability, feasibility, and safety of minihysteroscopy with a vaginoscopic approach: Experience with 6,000 cases. *Fertil Steril* 2003;80:199-202.
- Papalampros P, Gambadauro P, Papadopoulos N, Polyzos D, Chapman L, Magos A. The mini-resectoscope: A new instrument for office hysteroscopic surgery. *Acta Obstet Gynecol Scand* 2009;88:227-30.
- De Angelis C, Santoro G, Re ME, Nofroni I. Office hysteroscopy and compliance: Mini-hysteroscopy versus traditional hysteroscopy in a randomized trial. *Hum Reprod Oxf Engl* 2003;18:2441-5.
- Colacurci N, De Francis P, Mollo A, Litta P, Perino A, Cobellis L, *et al.* Small-diameter hysteroscopy with versapoint versus resectoscopy with a unipolar knife for the treatment of septate uterus: A prospective randomized study. *J Minim Invasive Gynecol* 2007;14:622-7.
- Youssef HM. Uterine septum dissection using mini-hysteroscopy with bipotrode 5 Fr bipolar electrode versus monopolar resectoscopy with a unipolar knife: A randomized controlled study. *Fertil Steril* 2013;100:S394.
- Tonguc EA, Var T, Yilmaz N, Batioglu S. Intrauterine device or estrogen treatment after hysteroscopic uterine septum resection. *Int J Gynaecol Obstet* 2010;109:226-9.
- Thubert T, Dussaux C, Demoulin G, Rivain AL, Trichot C, Deffieux X. Influence of auto-cross-linked hyaluronic acid gel on pregnancy rate and hysteroscopic outcomes following surgical removal of intra-uterine adhesions. *Eur J Obstet Gynecol Reprod Biol* 2015;193:65-9.
- Cicinelli E. Diagnostic minihysteroscopy with vaginoscopic approach: Rationale and advantages. *J Minim Invasive Gynecol* 2005;12:396-400.
- Roy KK, Lingampally A, Kansal Y, Bharti J, Kumar S, Vanamail P, *et al.* A pilot study comparing hysteroscopic adhesiolysis by conventional resectoscope versus mini-resectoscope. *Oman Med J* 2017;32:492-8.
- Cicinelli E. Hysteroscopy without anesthesia: Review of recent literature. *J Minim Invasive Gynecol* 2010;17:703-8.
- Pansky M, Feingold M, Bahar R, Neeman O, Asiag O, Herman A, *et al.* Improved patient compliance using pediatric cystoscope during office hysteroscopy. *J Am Assoc Gynecol Laparosc* 2004;11:262-4.
- Saygili-Yilmaz E, Yildiz S, Erman-Akar M, Akyuz G, Yilmaz Z. Reproductive outcome of septate uterus after hysteroscopic metroplasty. *Arch Gynecol Obstet* 2003;268:289-92.
- Pabuçcu R, Gomel V. Reproductive outcome after hysteroscopic metroplasty in women with septate uterus and otherwise unexplained infertility. *Fertil Steril* 2004;81:1675-8.
- Colacurci N, De Placido G, Mollo A, Carravetta C, De Francis P. Reproductive outcome after hysteroscopic metroplasty. *Eur J Obstet Gynecol Reprod Biol* 1996;66:147-50.