

Aortoiliac reconstruction in the setting of in-stent restenosis

**H. S. Natraj Setty,
T. R. Raghu,
B. C. Srinivas,
C. M. Nagesh,
Babu Reddy,
Jayashree Kharge,
B. K. Geetha,
B. N. Krishnamurthy,
Shivanand Patil,
C. N. Manjunath**

Department of Cardiology, Sri Jayadeva Institute of Cardiovascular Sciences and Research, Bengaluru, Karnataka, India

Address for correspondence:

Dr. H. S. Natraj Setty, #493, 4th Cross, 7th Main, J. P. Nagar, 3rd Phase, Bengaluru - 560 069, Karnataka, India. E-mail: drnatrajsetty75@gmail.com

Abstract

Complex iliac artery obstructions, particularly bilateral stenosis or total iliac artery occlusions, are usually treated with aortofemoral or aortobifemoral graft surgery. However, surgical treatment is associated with 3% mortality rate and significant morbidity such as intestinal ischemia, spinal cord injury, and ureteral damage. Percutaneous interventions of aortic bifurcation offer a promising alternative to surgery with potentially lower morbidity and mortality risk. We report a case of peripheral artery disease who had underwent right transfemoral iliac angioplasty with femoropopliteal bypass presented again with bilateral lower limb ischemia, who was successfully treated with stent implantation with the kissing balloon technique.

Key words: Angioplasty, aortobifemoral graft surgery, iliac artery stenosis, in-stent restenosis

INTRODUCTION

Surgical treatment of aortoiliac occlusive disease is associated with excellent long-term results with a mortality rate of 3% and morbidity rate of 5–8%. Percutaneous interventions is a less invasive alternative to surgery with a good success rate. Risks of contralateral embolism or contralateral iliac artery occlusion due to dislodgement of atherosclerotic or thrombotic material from aortic bifurcation during unilateral percutaneous transluminal angioplasty (PTA) are high. Kissing balloon technique wherein balloons are positioned simultaneously across both limbs of aortic bifurcation and inflated in unison prevents such a complication to develop. Although several series have reported good procedural and clinical success, the complication of dissection, thrombosis or significant residual stenosis remain up to 9%.

CASE REPORT

A 45-year-old male patient presented with a history of intermittent claudication pain for the last 3 months and blackish discoloration of the right toe for 15 days. The patient is a known case of peripheral arterial disease, previously underwent right transfemoral iliac angioplasty with femoropopliteal bypass 1 year ago for similar complaints. He is also a smoker and diabetic, no family history of ischemic heart disease and peripheral vascular disease. Coronary angiogram revealed normal coronaries. On examination, blackish discoloration of the right middle toe, absent pulse in bilateral lower limbs. Computed tomography (CT) peripheral angiogram was revealed diffuse internal thickening with wall calcification noted in aorta causing 40% diameter stenosis, right common iliac artery (CIA) in-stent restenosis of 90% at proximal and distal edges of the stent [Figure 1a], right femoropopliteal graft is thrombosed and left CIA shows multifocal areas of narrowing and occlusion of 90% [Figure 1b]. The patient was subjected for PTA, left CIA approached from the left brachial artery with 0.035 Terumo wire and exteriorized through left femoral artery [Figure 2a]. The right femoral arterial approach was used for deploying CIA stent. Serial predilatation was done using 8 mm × 55 mm peripheral balloon [Figure 2b]. A 8 mm × 120 mm medtronic self-expanding stent was deployed in the right CIA and 7 mm × 150 mm medtronic self-expanding stent deployed in left CIA. A postdilatation with simultaneous kissing at aortoiliac junction was done using 8 mm × 55 mm balloon in right CIA and 7 mm × 40 mm balloon in left CIA. Postprocedure showed good distal flow [Figure 3]. CT peripheral angiogram was done after 1 week which showed patent stent seen in relation to distal aorta, left CIA, external, right CIA [Figure 4].

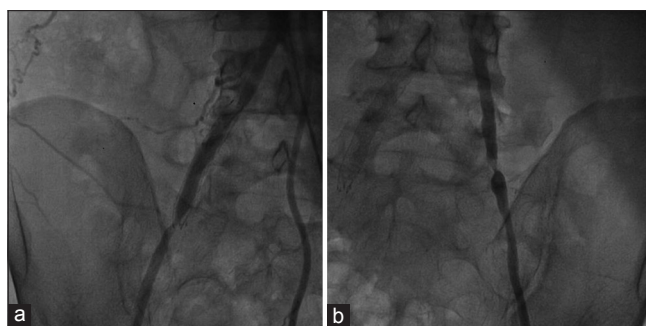


Figure 1: Peripheral angiogram shows right common iliac artery stenosis of 90% at proximal and distal edges of the stent (a), right femoropopliteal graft is thrombosed, left common iliac artery shows multifocal areas of narrowing and occlusion of 90% (b)

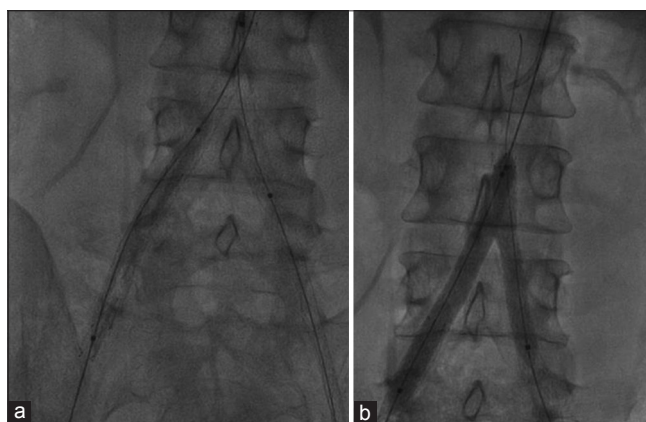


Figure 2: Terumo wire (0.035) and exteriorized through left femoral artery (a). Right femoral artery approach was used for deploying right common iliac artery stent. 8 mm × 55 mm peripheral balloon was used and serial predilatation done (b)

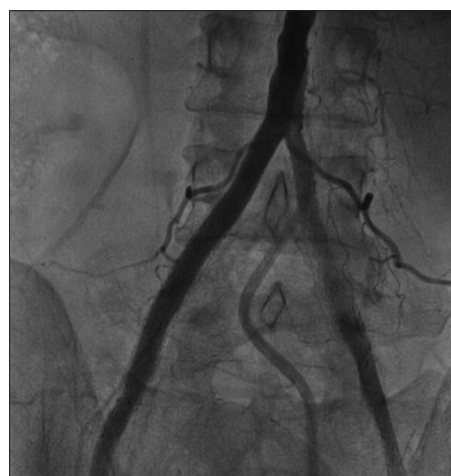

Figure 3: 8 mm × 120 mm medtronic self-expanding stent was deployed in the right common iliac artery and 7 mm × 150 mm medtronic self-expanding stent deployed in the left common iliac artery. Postdilatation with simultaneous kissing at aortoiliac junction was done using 8 mm × 55 mm balloon in right common iliac artery and 7 mm × 40 mm balloon in left common iliac artery. Postprocedure showed good distal flow

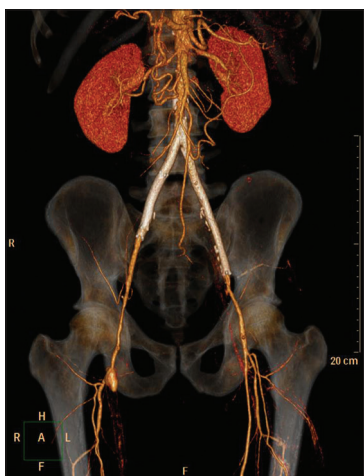


Figure 4: Computed tomography peripheral angiogram shows patent stent seen in relation to distal aorta, left common iliac artery, external right common iliac artery

DISCUSSION

Aortoiliac occlusive disease has been traditionally treated with open aortobifemoral bypass which is burdened with perioperative mortality of 3–5% and morbidity of 10%.^[1] Percutaneous interventions offer a less invasive alternative to surgery with a high technical success rates and comparable long-term results especially in low-grade TransAtlantic Inter-Society Consensus lesions.^[2]

Aortic bifurcation stenting was first described by Palmaz *et al.* in a study of seven patients with an alternative percutaneous approach in which they delivered one iliac stent at a time.^[3] Kissing stent insertion in the aortic bifurcation can be achieved with excellent clinical success with minimal short and intermediate-term complications. Those with lesions localized to the aortic bifurcation may be best suited for the kissing stent technique even though patients with more extensive involvement of the aorta or external iliacs can be successfully treated with additional stents.

Early series of percutaneous recanalization procedures for chronic iliac artery occlusions demonstrated poor results and excessively high complication rates of up to 20%.^[4,5] Vorwerk *et al.* demonstrated that endovascular stents significantly contribute to an improvement in long-term results.^[6] A meta-analysis study of iliac artery intervention, stent placement was found to reduce the risk of long-term failure by 39% when compared with PTA alone, and the 4-year success rate for iliac angioplasty was approximately 44 to 65%.^[7]

According to Ballard *et al.*, factors such as female sex, superficial femoral artery occlusion, perioperative vascular complications, and hypercholesterolemia proved to be risk factors for lower patency rates in iliac artery stents.^[8]

In the present case, the patient underwent balloon angioplasty, followed by primary stent implantation with the kissing balloon technique. All stents were placed, with successful restoration of the vessel patency both CIAs. The patient showed prompt recovery on follow-up at 6 months.

CONCLUSION

Endovascular treatment of aortoiliac disease with kissing stent is a promising method to restore circulation with low morbidity and mortality and good patency rates even in the setting of in-stent restenosis and a good alternative to surgery.

Financial support and sponsorship

Nil.

Conflicts of interest

There are no conflicts of interest.

REFERENCES

- de Vries SO, Hunink MG. Results of aortic bifurcation grafts for aortoiliac occlusive disease: A meta-analysis. *J Vasc Surg* 1997;26:558-69.
- Dormandy JA, Rutherford RB. Management of peripheral arterial disease (PAD). TASC Working Group. TransAtlantic Inter-Society Consensus (TASC). *J Vasc Surg* 2000;31 (1 Pt 2):S1-296.
- Palmaz JC, Encarnacion CE, Garcia OJ, Schatz RA, Rivera FJ, Laborde JC, *et al.* Aortic bifurcation stenosis: Treatment with intravascular stents. *J Vasc Interv Radiol* 1991;2:319-23.
- Johnston KW. Iliac arteries: Reanalysis of results of balloon angioplasty. *Radiology* 1993;186:207-12.
- Colapinto RF, Stronell RD, Johnston WK. Transluminal angioplasty of complete iliac obstructions. *AJR Am J Roentgenol* 1986;146:859-62.
- Vorwerk D, Guenther RW, Schürmann K, Wendt G, Peters I. Primary stent placement for chronic iliac artery occlusions: Follow-up results in 103 patients. *Radiology* 1995;194:745-9.
- Bosch JL, Hunink MG. Meta-analysis of the results of percutaneous transluminal angioplasty and stent placement for aortoiliac occlusive disease. *Radiology* 1997;204:87-96.
- Ballard JL, Bergan JJ, Singh P, Yonemoto H, Killeen JD. Aortoiliac stent deployment versus surgical reconstruction: Analysis of outcome and cost. *J Vasc Surg* 1998;28:94-101.

This is an open access article distributed under the terms of the Creative Commons Attribution-NonCommercial-ShareAlike 3.0 License, which allows others to remix, tweak, and build upon the work non-commercially, as long as the author is credited and the new creations are licensed under the identical terms.

For reprints contact: reprints@medknow.com

Access this article online	
Quick Response Code:	Website: www.jnsbm.org
	DOI: 10.4103/0976-9668.198347

How to cite this article: Natraj Setty HS, Raghu TR, Srinivas BC, Nagesh CM, Reddy B, Kharge J, *et al.* Aortoiliac reconstruction in the setting of in-stent restenosis. *J Nat Sc Biol Med* 2017;8:133-5.