

Corneal endothelium after deep anterior lamellar keratoplasty and penetrating keratoplasty for keratoconus: A four-year comparative study

Anil Kubaloglu, Arif Koytak¹, Esin Sogutlu Sari, Sibel Akyol², Ekrem Kurnaz, Yusuf Ozerturk

Purpose: To compare the status of corneal endothelium and central corneal thickness within the first four postoperative years after deep anterior lamellar keratoplasty (DALK) and penetrating keratoplasty (PK) in patients with keratoconus. **Materials and Methods:** Thirty-nine eyes (Group A) which had PK and 44 eyes (Group B) which had DALK for the treatment of keratoconus were included in this retrospective study. The endothelial cell density (ECD), the mean endothelial cell area and the coefficient of variation of cell area were assessed with a non-contact specular microscope, and the central corneal thickness (CCT) was measured with an ultrasound pachymeter. **Results:** Mean ECD loss rate at two years was 36.24% in Group A and 18.12% in Group B ($P<0.001$). Mean ECD loss rate at four years was 47.82% in Group A and 21.62% in Group B ($P<0.001$). Mean annual ECD loss rate was calculated 14.12% per year in Group A and 5.78% per year in Group B. In the PK group, increase in mean CCT was 15.60% in two years and 15.03% in four years, while in the DALK group, mean CCT increased by 8.05% in two years and 9.31% in four years. **Conclusions:** As the majority of ectatic disorders such as keratoconus occur in young people, long-term endothelial cell survival following treatment with keratoplasty is essential for the long-term visual ability. Our finding that corneal endothelial cell loss in the DALK group occurs at a slower rate than in the PK group suggests DALK as a safer alternative to PK in these selected patients.

Key words: Deep anterior lamellar keratoplasty, endothelial cell density, keratoconus, penetrating keratoplasty

Functional status of the corneal endothelial cells is one of the major criteria determining long-term outcomes of corneal transplant surgery. The annual rate of endothelial cell loss after penetrating keratoplasty is found to be at a higher rate than the physiologic rate (0.6% per year), and cumulative cell loss within the first ten years after penetrating keratoplasty (PK) is reported as 50% or more.^[1-3] Besides the initial surgical trauma, this chronic cell loss is explained by continuing compromise of the donor endothelium in the host ocular environment by several mechanisms (peripheral migration of donor endothelial cells, clinical or subclinical chronic immunologic processes between the donor and recipient tissues, normal or accelerated cellular aging, or secondary glaucoma).^[4-6]

Although penetrating keratoplasty is still considered the standard treatment of advanced keratoconus, in the last decade, deep anterior lamellar keratoplasty (DALK) is proposed as an alternative surgical treatment.^[7,8] The main advantage of DALK is that the patient's own endothelium is retained, which reduces the risk of graft failure and immunologic reactions. Therefore, cell survival after DALK may be expected to be better when compared with that following PK.^[9]

As the patients with keratoconus are relatively younger and as they undergo keratoplasty at earlier ages, long-term survival and function of the corneal endothelium after keratoplasty

is critical for their lifelong visual abilities, more than any other group of patients requiring keratoplasty. In this study, we compared the status of corneal endothelium and central corneal thickness within the first four postoperative years after uncomplicated DALK and PK in patients with keratoconus.

Materials and Methods

The cohort consisted of 55 consecutive patients who had PK and 76 consecutive patients for whom a DALK was planned for the treatment of keratoconus between January 2003 and January 2005. Eyes were grouped on the basis of the keratoplasty technique performed. Group A consisted of patients having PK, while Group B consisted of patients having DALK.

PK was planned in keratoconic eyes with advanced axial or paraxial protrusion of the cornea, scarring at deep stroma or at the level of Descemet's membrane (DM), or a tear in DM. Availability of preoperative specular microscopic evaluation of the donor cornea and a minimum donor endothelial cell density (ECD) of 2000 cells/mm² were accepted as inclusion criteria for Group A cases. Eyes which had combined procedures such as keratoplasty with simultaneous cataract extraction were not included in the study groups. Inclusion criteria for Group B were availability of preoperative specular microscopic examination of the host cornea and a minimum recipient ECD of 1500 cells/mm². All patients were required to have completed a minimum follow-up of 24 months. Patients who missed control visits before 24 months were excluded from the study. In the DALK group, 14 cases which had single or multiple microperforations of DM during the procedure and nine cases which required conversion from DALK to PK intraoperatively were excluded from the study. Eleven patients from Group A and eight patients from Group B were excluded

Access this article online

Website:

www.ijo.in

DOI:

10.4103/0301-4738.90490

Quick Response Code:



Kartal Training and Research Hospital, Istanbul, ¹Faculty of Medicine, Bezmialem Vakif University, Istanbul, ²Diyarbakir State Hospital, Diyarbakir, Turkey

Correspondence to: Dr. Arif Koytak, Faculty of Medicine, Bezmialem Vakif University, Fatih, Istanbul, Turkey. E-mail: akoytak@yahoo.com

Manuscript received: 20.10.10; **Revision accepted:** 05.06.11

from the study because they did not complete a postoperative follow-up of minimum 24 months. Four eyes in Group A and one eye in Group B were excluded from the study as they required repeated grafts because of graft failure within the first 24 months. Also, one eye in Group A which had glaucoma unresponsive to topical treatment was excluded. Among eyes with a fellow eye which also had keratoplasty, the one that was operated earlier was included in the study. Thirty-nine eyes in Group A and 44 eyes in Group B were left available for analysis. Each patient signed an informed consent as part of the institutional review board-approved study.

All surgeries were performed by a single experienced surgeon (A.K.). Donor corneas were obtained from our institutional eye bank and transported in Optisol GS (Bausch and Lomb, Rochester, New York, USA).

As part of the standard PK procedure, the donor buttons were cut using a 7.50–8.50-mm (mean, 7.73 mm) Barron punch trephine from their endothelial sides. The recipient bed was prepared with the suction trephine at a diameter 0.25 mm smaller than the donor button. Corneal scissors were used to complete the excision of the recipient corneal button. In all cases, a single continuous 24-bite 10-0 nylon suture was placed for wound closure. Postoperative treatment regimen included topical antibiotics and topical steroid therapy. Treatment with topical antibiotics was discontinued within a month while steroid therapy continued for at least six months and was gradually tapered off according to the clinical response.

The DALK procedure was accomplished with the big-bubble technique described by Anwar *et al.* In brief, a 70–80% thickness (about 400 μm) trephination to the recipient bed was performed with a suction trephine.^[8] A 30-gauge bent needle was introduced to the deep stroma starting at the bottom of the trephination groove and advanced towards the center of the cornea. Air was injected slowly into the stroma, aiming to achieve the formation of a large air bubble between the stroma and DM. Following a peripheral paracentesis and a superficial keratectomy, residual stroma was removed with blunt-tipped scissors, exposing the DM. The donor cornea was punched out from the endothelial side using a Barron punch trephine at a diameter 0.25 mm larger than the recipient bed. DM and endothelium of the donor cornea was stripped off with a dry Weck-Cel sponge. The button was sutured into the recipient bed using a single continuous 24-bite 10-0 nylon suture. Postoperative medication included topical antibiotics for a month and topical steroids for at least four months.

When performing DALK, if the big-bubble was not achieved despite repeated air injections, conversion to PK was preferred without any attempt for manual dissection of the stroma. Also, in case of a macroperforation necessitating conversion to PK, the host corneal stroma and endothelium was removed with corneal scissors and the procedure was completed with the standard PK technique. In both cases, the subject was excluded from the study group.

In both groups, sutures were retained until 12 months after surgery and then removed under slit-lamp biomicroscopy. Earlier suture removal was needed in cases of loosening of the sutures and/or vascularization of the host cornea.

The ECD and the coefficient of variation of the cell area of donor corneas were assessed by a specular microscope before

storage in Optisol medium (Bausch and Lomb, Rochester, New York, USA). The endothelium was photographed and evaluated using a Topcon SP 2000p noncontact specular microscope (Topcon Corp., Tokyo, Japan). Images of the central corneal window were reviewed by the same observer (S.A.) and manual correction of the cell borders was performed before final analysis of the endothelium. Twenty endothelial cells were marked for each analysis. Central corneal thickness (CCT) was measured with an ultrasound pachymeter (Optikon Pacline, Optikon Corp., Roma, Italy). For each examination, three measurements of ECD, mean endothelial cell area, coefficient of variation of cell area, and CCT were averaged.

All data were entered into a spreadsheet and statistical analyses were performed using the SPSS for Windows software (Version 11.5, SPSS Inc., Chicago, IL). Data were presented descriptively using means for continuous variables and using proportions for categorical variables. Differences in ECD, coefficient of variation of cell area, and CCT were compared between groups by using a paired t test (when data were normally distributed) or a Wilcoxon signed-rank test (when data were not distributed normally). A two-tailed probability of 5% or less was considered statistically significant.

Results

Twenty-four patients in the PK group (61.5% of 39 patients), and 26 patients in the DALK group (59.1% of 44 patients) were male. The mean patient age at keratoplasty was 36.24 (range, 16-49) in Group A, and 34.54 (range, 17-46) in Group B ($P=0.532$). The mean age of donors for the PK group was 49.36 (range, 19-69). All patients in both groups completed the minimum follow-up of 24 months. Thirty-six patients from Group A and 41 patients from Group B had a follow-up of three years, while 33 Group A patients and 39 Group B patients had a follow-up of four years.

Preoperative mean ECD of the donor corneas used for the PK group (Group A) was 2761 ± 538 cells/ mm^2 , while preoperative corneal ECD of the recipient eyes in Group B was 2836 ± 440 cells/ mm^2 ($P=0.485$). In Group A, the mean ECD at the sixth month was found to be 2282 ± 692 cells/ mm^2 ($n=39$). Meanwhile, the mean ECD of Group B was 2422 ± 503 cells/ mm^2 and the difference between two groups was not statistically significant ($P=0.291$).

Mean ECDs of the PK and DALK groups at two years were 1780 ± 547 cells/ mm^2 and 2325 ± 515 cells/ mm^2 respectively ($P<0.001$). Mean rates of EC loss of the two groups at the second year differed significantly (36.24% in Group A versus 18.12% in Group B, $P<0.001$). ECDs of Groups A and B at four years averaged 1476 ± 527 cells/ mm^2 and 2250 ± 529 cells/ mm^2 respectively ($P<0.001$). EC loss rates at the fourth year were 47.82% in the PK group and 21.62% in the DALK group ($P<0.001$). The mean annual EC loss rate was calculated 14.21% per year in Group A and 5.78% per year in Group B, and the difference was found to be statistically significant ($P<0.001$). The EC loss rates of both groups were highest in the first year (25.71% in Group A and 14.90% in Group B, $P<0.001$) and lower thereafter (10.35% per year in Group A and 2.93% per year in Group B, $P<0.001$) [Table 1, Fig. 1].

The mean coefficient of variation of cell area had increased from 0.19 ± 0.02 preoperatively to 0.27 ± 0.04 (mean rate of increase, 41.57%) at four years in Group A, and from 0.20 ± 0.02

Table 1: Changes in endothelial cell density after penetrating keratoplasty and deep anterior lamellar keratoplasty (means \pm standard deviation)

	Penetrating keratoplasty			Deep anterior lamellar keratoplasty			P value
	n	EC density (cells/mm ²)	EC loss (%)	n	EC density (cells/mm ²)	EC loss (%)	
Preoperative	39	2761 \pm 538	-	44	2836 \pm 440	-	0.485*
6 months	39	2282 \pm 692	18.92	44	2422 \pm 503	14.66	0.225**
1 year	39	2085 \pm 645	25.71	44	2416 \pm 514	14.90	<0.001**
2 years	39	1780 \pm 547	36.24	44	2325 \pm 515	18.12	<0.001**
3 years	36	1525 \pm 542	46.05	41	2282 \pm 525	19.89	<0.001**
4 years	33	1476 \pm 527	47.82	39	2250 \pm 529	21.62	<0.001**

*For EC densities, **For EC loss rates, EC: endothelial cell

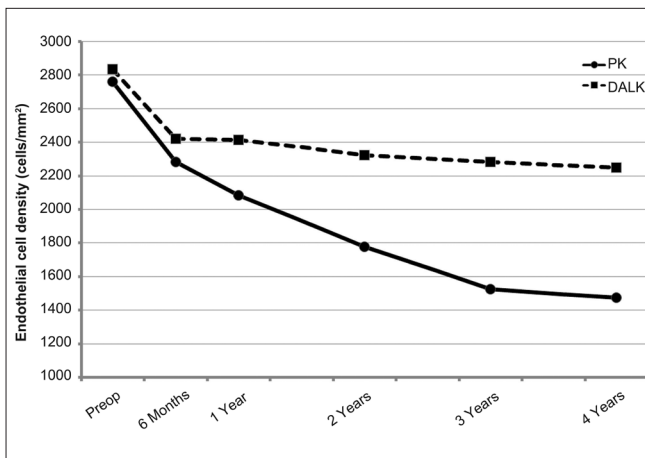


Figure 1: Endothelial cell density after penetrating keratoplasty and deep anterior lamellar keratoplasty (PK: penetrating keratoplasty, DALK: deep anterior lamellar keratoplasty)

preoperatively to 0.24 ± 0.05 (mean rate of increase, 20.56%) at four years in Group B ($P < 0.001$) [Table 2].

The preoperative mean CCT was 468 ± 33 microns in Group A and 490 ± 39 microns in Group B ($P = 0.002$). In Group A, the increase in mean CCT was 15.60% in two years and 15.03% in four years, while in Group B, mean CCT increased by 8.05% in two years and 9.31% in four years. Differences in the rate of increase of CCT in the two groups were statistically significant both at the second ($P = 0.002$) and the fourth years ($P < 0.040$) [Table 3].

Eight eyes (18%) in the PK group had graft rejection episodes. Among them, seven eyes had endothelial rejections and one eye had an epithelial rejection. Three eyes which had endothelial rejections failed to respond to medical treatment and required repeated grafts. In the DALK group, two eyes (4%) had stromal rejection episodes, all of which resolved with medical treatment. In addition, primary graft failure was observed in a case in the PK group and a graft failure related to microbial keratitis with corneal ulceration occurred in the DALK group.

Four patients in the PK group and two patients in the DALK group developed post-keratoplasty glaucoma manageable with topical treatment. The difference between the two groups with

respect to the development of post-keratoplasty glaucoma was not statistically significant ($P = 0.316$). In addition, one eye in the PK group had glaucoma unresponsive to topical treatment and required filtering surgery. This patient was excluded from the study. The mean duration of topical steroid use was 11.92 ± 4.89 months in Group A and 7.84 ± 4.25 months in Group B ($P < 0.001$).

Discussion

Corneal endothelial cell function is essential for long-term graft survival and functional success of any type of keratoplasty. Although it is a well-known phenomenon that the ECD declines with age in the normal cornea, previous studies have demonstrated that PK causes an accelerated rate of cell loss up to 20 years after surgery.^[4,5] The rate of endothelial cell loss following PK is reported to be about 33% within the first two years, about 54% for the first three years and between 59% and 70% at the end of the fifth year.^[2,10-13] These rates are significantly higher than the normal physiologic rate of endothelial cell loss which is about 0.6% per year.^[1] Chronic endothelial cell loss observed in eyes with PK may be the result of a combination of several factors including the initial surgical trauma, cellular interactions between the donor and recipient, immune reactions, accelerated cellular aging, secondary glaucoma as well as donor status and donor preservation conditions.^[4-6] In contrast with PK, the recipient DM and endothelium are left in place in DALK and only the anterior cornea is replaced. Therefore, it is reasonable to believe that a successful and uncomplicated DALK causes less damage to the endothelium and fewer immunologic reactions, resulting in a lower rate of postoperative endothelial cell loss.

In the current study, ECDs, mean endothelial cell areas, coefficients of variation of cell area and CCTs of keratoconic eyes having undergone PK were measured during the first four postoperative years and compared to those of keratoconic eyes having undergone DALK. Only eyes with keratoconus were included in this comparative study in order to minimize the possible biases of different corneal pathologies and coexisting eye diseases.

The surgical techniques of PK and DALK differ in many aspects. PK is an open-sky procedure in which a full-thickness donor button is transplanted and more prominent inflammatory and immune reactions are imminent in the immediate postoperative period. DALK, however, is a less invasive surgery with the recipient endothelium kept in place and the anterior chamber maintained during the procedure.

Table 2: Changes in coefficient of variation of cell area after penetrating keratoplasty and deep anterior lamellar keratoplasty (means \pm standard deviation)

	Penetrating keratoplasty			Deep anterior lamellar keratoplasty			P value
	n	COV of EC area	Increase (%)	n	COV of EC area	Increase (%)	
Preoperative	39	0.19 \pm 0.02	-	44	0.20 \pm 0.02	-	0.003*
6 months	39	0.22 \pm 0.04	13.27	44	0.23 \pm 0.04	12.92	<0.602**
1 year	39	0.23 \pm 0.05	19.67	44	0.23 \pm 0.05	11.54	<0.024**
2 years	39	0.25 \pm 0.05	31.20	44	0.23 \pm 0.05	14.17	<0.001**
3 years	36	0.26 \pm 0.05	34.92	41	0.23 \pm 0.05	15.37	<0.001**
4 years	33	0.27 \pm 0.04	41.57	39	0.24 \pm 0.05	20.56	<0.001**

*For COV of EC areas, **For COV of EC area increase rates, COV: coefficient of variation, EC: endothelial cell

Table 3: Changes in central corneal thickness after penetrating keratoplasty and deep anterior lamellar keratoplasty (means \pm standard deviation)

	Penetrating keratoplasty			Deep anterior lamellar keratoplasty			P value
	n	CCT (microns)	Increase (%)	n	CCT (microns)	Increase (%)	
Preoperative	39	468 \pm 33	-	44	490 \pm 39	-	0.002*
6 months	39	533 \pm 36	14.82	44	533 \pm 20	9.34	0.085**
1 year	39	535 \pm 32	15.31	44	528 \pm 18	8.49	0.008**
2 years	39	536 \pm 36	15.60	44	527 \pm 25	8.05	0.002**
3 years	36	539 \pm 31	15.97	41	529 \pm 21	8.65	0.003**
4 years	33	537 \pm 34	15.03	39	532 \pm 32	9.31	0.040**

*For CCTs, **For CCT increase rates, EC: endothelial cell

Assuming that these major differences could make the comparison of preoperative and immediate postoperative measures of endothelial function biased, we preferred to neglect measurements before the third postoperative month.

In Group A (PK), the endothelial cell loss rate was significantly higher during the entire follow-up period. At the end of the fourth year, the cumulative rate of endothelial cell loss was 47.82% in the PK group and 21.62% in the DALK group. This difference could be explained by several factors such as more prominent immune reactions, weaker wound repair processes, accelerated peripheral migration of endothelial cells and longer topical steroid therapy in the PK group. Several *in vitro* and *in vivo* studies showed negative effects of corticosteroids on the corneal endothelium and endothelial healing process.^[14-17] In our study, the mean duration of steroid use was significantly higher in the PK group. This difference could in part explain the higher endothelial cell loss rate in the PK group when compared to the DALK group. On the other hand, there are also studies reporting that longer use of steroids improved graft survival.^[18] A possible explanation for this contradiction is that, beside their negative impact on the endothelium, the use of steroids suppresses the more prominent inflammation-mediated harm to the endothelium and reduces the overall rate of endothelial cell loss.

Increased intraocular pressure is another risk factor for an accelerated rate of endothelial cell loss following keratoplasty.^[19-21] In our study, more eyes in the PK group developed post-keratoplasty glaucoma (four in 39 eyes in the

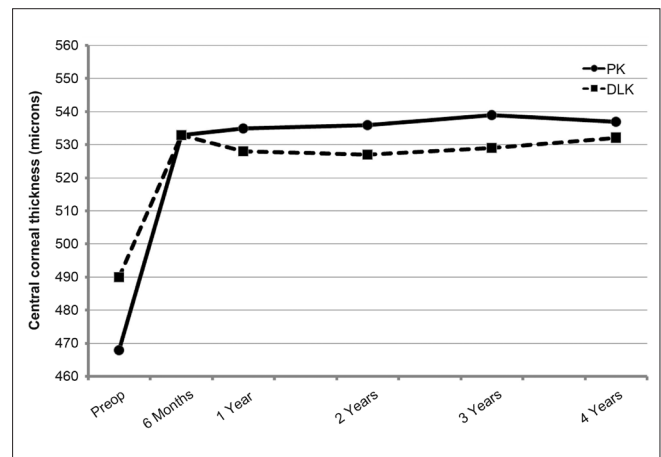


Figure 2: Central corneal thickness after penetrating keratoplasty and deep anterior lamellar keratoplasty (PK: penetrating keratoplasty, DALK: deep anterior lamellar keratoplasty)

PK group vs. two in 44 eyes in the DALK group). Although it was not statistically significant, this difference could be the result of more prominent immune reactions and longer use of steroids in the PK group. We have ground to believe that post-keratoplasty glaucoma could contribute to a higher rate of endothelial cell loss in the PK group.

Following DALK, the bulged DM of a keratoconic eye gains back its normal curvature and its surface area decreases. This

could bring about a notable postoperative increase in ECD. However, this was not the case in our study and further studies are needed to clarify the relationship between ECD and corneal curvature before and after DALK.

In previous publications, cumulative rates of endothelial cell loss after PK were reported as 31–45% at the first year,^[1,11,22] 33% at the second year,^[10] 54% at the third year,^[12] and between 59% and 70% at the fifth year.^[12,13] Although the diagnosis and mean age of our study population were different from previous studies, endothelial cell loss rates were found comparable. Among a few reports on endothelial cell loss rates following DALK, Van Dooren *et al.*, have found a cumulative endothelial cell loss rate of 10.95% at the first year and 12.29% at the second year,^[23] while Vabres *et al.*, have found a rate of 13.5% at the end of the first year.^[22] Our study revealed cumulative ECD loss rates of 14.90% at the first year, 18.12% at the second year and 21.62% at the fourth year. These findings are comparable to the rates in Van Dooren's and Vabres' studies.

Central corneal thickness could be accepted as an indirect measure of endothelial cell function. In the current study, ultrasonic measurements of CCT were obtained in each control visit. In contrast to ECDs, following a sharper increase in the first six months, the CCTs of the two groups had a relatively steady course throughout the follow-up period. The yearly increase rate of mean CCT was found to be significantly higher in Group A (14.82% in Group A vs. 8.49% in Group B), but this difference was related to the rapid increase in the first six months [Fig. 2]. Although the mean ECD in Group A was reduced more than in Group B, there was no statistically significant difference between the mean CCTs of the two groups at the end of the fourth year. This finding proves that even if ECDs decrease significantly, as long as an acceptable density is kept, the remaining cells compensate the loss well and corneal thickness remains normal.^[24] However, longer follow-up of eyes having PK or DALK might reveal a critical time period after which the risk of endothelial decompensation is higher. Our findings, similar to previous publications, suggest that such a risk might be much lower after DALK surgery.^[25,26]

Specular microscopic measurements require a clear central cornea. Therefore, we needed to exclude a total of five cases within the first two years and an additional three cases after the second year, which required repeated grafts because of graft failure. This is one of the limitations of our study, which could overlook the effect of graft rejection episodes on the endothelium. Also, when comparing two different keratoplasty techniques, we in fact compared two different groups of endothelia. The endothelium we used in a PK case belonged to the donor tissue which was presumably undiseased, more aged and stored in a transport medium. On the other hand, the endothelium we followed up in a DALK case belonged to the patient's own keratoconic eye, possibly younger and untouched. Thus, we have to keep in mind that this study is far from revealing how and how much exactly the two techniques act on the corneal endothelium. Instead, the aim of our study is to evaluate the overall long-term behavior of the corneal endothelium following two different keratoplasty techniques.

Although there are several publications on long-term endothelial cell loss following PK and DALK, our study is the first one to compare endothelial cell status and function within four years following penetrating and deep anterior

lamellar keratoplasties in similar patient groups with a unique diagnosis.

As the majority of ectatic disorders such as keratoconus occur in young people, long-term endothelial cell survival following treatment with keratoplasty is essential for the long-term visual ability of these patients. Our finding that corneal endothelial cell loss in the DALK group occurs at a slower rate than in the PK group suggests that in the long term DALK, although technically more challenging, could be a safer alternative to PK surgery for these selected patients.

References

1. Bourne WM, Hodge DO, Nelson LR. Corneal endothelium five years after transplantation. *Am J Ophthalmol* 1994;118:185-96.
2. Ing JJ, Ing HH, Nelson LR, Hodge DO, Bourne WM. Ten-year postoperative results of penetrating keratoplasty. *Ophthalmology* 1998;105:1855-65.
3. Patel SV, Hodge DO, Bourne WM. Corneal endothelium and postoperative outcomes 15 years after penetrating keratoplasty. *Trans Am Ophthalmol Soc* 2004;102:57-66.
4. Bourne WM. Cellular changes in transplanted human corneas: Castroviejo lecture. *Cornea* 2001;20:560-9.
5. Böhringer D, Reinhard T, Spelsberg H, Sundmacher R. Influencing factors on chronic endothelial cell loss characterised in a homogeneous group of patients. *Br J Ophthalmol* 2002;86:35-8.
6. Watson SL, Tuft SJ, Dart JK. Patterns of rejection after deep lamellar keratoplasty. *Ophthalmology* 2006;113:556-60.
7. Al-Torbak AA, Al-Motowa S, Al-Assiri A, Al-Kharashi S, Al-Shahwan S, Al-Mezaine H, *et al.* Deep anterior lamellar keratoplasty for keratoconus. *Cornea* 2006;25:408-12.
8. Anwar M, Teichmann KD. Big-bubble technique to bare Descemet's membrane in anterior lamellar keratoplasty. *J Cataract Refract Surg* 2002;28:398-403.
9. Trimarchi F, Poppi E, Klersy C, Piacentini C. Deep lamellar keratoplasty. *Ophthalmologica* 2001;215:389-93.
10. Panda A, Bageshwar LM, Ray M, Singh JP, Kumar A. Deep lamellar keratoplasty versus penetrating keratoplasty for corneal lesions. *Cornea* 1999;18:172-5.
11. Culbertson WW, Abbott RL, Forster RK. Endothelial cell loss in penetrating keratoplasty. *Ophthalmology* 1982;89:600-4.
12. Bertelmann E, Pleyer U, Rieck P. Risk factors for endothelial cell loss after penetrating keratoplasty. *Acta Ophthalmol Scand* 2006;84:766-70.
13. Cornea Donor Study Investigator Group, Lass JH, Gal RL, Dontchev M, Beck RW, Kollman C, *et al.* Donor age and corneal endothelial cell loss 5 years after successful corneal transplantation: Specular microscopy ancillary study results. *Ophthalmology* 2008;115:627-32.
14. Samples JR, Nayak SK, Gualtieri C, Binder PS. Effect of hydrocortisone on corneal endothelial cells *in vitro*. *Exp Eye Res* 1985;41:487-95.
15. Singh G. Corticosteroids in corneal endothelial wound healing. *Ann Ophthalmol* 1985;17:238-43.
16. Solomon A, Solberg Y, Belkin M, Landshman N. Effect of corticosteroids on healing of the corneal endothelium in cats. *Graefes Arch Clin Exp Ophthalmol* 1997;235:325-9.
17. Chen WL, Lin CT, Yao CC, Huang YH, Chou YB, Yin HS, *et al.* In-vitro effects of dexamethasone on cellular proliferation, apoptosis and Na⁺-K⁺-ATPase activity of bovine corneal endothelial cells. *Ocul Immunol Inflamm* 2006;14:215-23.
18. Nguyen NX, Seitz B, Martus P, Langenbacher A, Cursiefen C. Long-term topical steroid treatment improves graft survival

- following normal-risk penetrating keratoplasty. *Am J Ophthalmol* 2007;144:318-9.
19. Gagnon MM, Boisjoly HM, Brunette I, Charest M, Amyot M. Corneal endothelial cell density in glaucoma. *Cornea* 1997;16:314-8.
 20. Reinhard T, Böhringer D, Sundmacher R. Accelerated chronic endothelial cell loss after penetrating keratoplasty in glaucoma eyes. *J Glaucoma* 2001;10:446-51.
 21. Bertelmann E, Pleyer U, Rieck P. Risk factors for endothelial cell loss post-keratoplasty. *Acta Ophthalmol Scand* 2006;84:766-70.
 22. Vabres B, Bosnjakowski M, Bekri L, Weber M, Pechereau A. Deep lamellar keratoplasty versus penetrating keratoplasty for keratoconus. *J Fr Ophtalmol* 2006;29:361-71.
 23. Van Dooren BT, Mulder PG, Nieuwendaal CP, Beekhuis WH, Melles GR. Endothelial cell density after deep anterior lamellar keratoplasty (Melles technique). *Am J Ophthalmol* 2004;137:397-400.
 24. Kus MM, Seitz B, Langenbacher A, Naumann GO. Endothelium and pachymetry of clear corneal grafts 15 to 33 years after penetrating keratoplasty. *Am J Ophthalmol* 1999;127:600-2.
 25. Morris E, Kirwan JF, Sujatha S, Rostron CK. Corneal endothelial specular microscopy following deep lamellar keratoplasty with lyophilised tissue. *Eye* 1998;12:619-22.
 26. Shimazaki J, Shimmura S, Ishioka M, Tsubota K. Randomized clinical trial of deep lamellar keratoplasty vs penetrating keratoplasty. *Am J Ophthalmol* 2002;134:159-65.

Cite this article as: Kubaloglu A, Koytak A, Sari ES, Akyol S, Kurnaz E, Ozerturk Y. Corneal endothelium after deep anterior lamellar keratoplasty and penetrating keratoplasty for keratoconus: A four-year comparative study. *Indian J Ophthalmol* 2012;60:35-40.

Source of Support: Nil. **Conflict of Interest:** None declared.