

Goldilocks Procedure without a Vertical Incision and a Comprehensive Literature Review

Hilton Becker, MD
Oscar Adrian Vazquez, MD, MS
Jacob Komberg, BS

Background: The Goldilocks technique is a postmastectomy breast reconstruction procedure adopted in 2012, which is performed by preserving and de-epithelializing the residual mastectomy flap to create an autologous tissue breast mound using an anchor, inverted T, or lateral incision. It is utilized in select patients along with the addition of a free nipple graft, fat grafting, and/or tattoo. A novel technique using the Goldilocks procedure offers promising postoperative results as a more aesthetic alternative. The purpose of this study was to perform a literature review on the healing outcomes and patient satisfaction of the Goldilocks procedure along with presenting our approach using a horizontal inframammary incision without a vertical incision.

Methods: A retrospective chart review of patients presenting to a single surgeon for breast reconstruction surgery using the Goldilocks procedure without a vertical incision from March of 2018 to October of 2020 was performed. A narrative literature review on surgical techniques and outcomes was also conducted.

Results: Three cases of breast reduction using the Goldilocks procedure without a vertical incision are described. From the literature search, 13 articles inclusive of 222 patients were identified.

Conclusions: The Goldilocks procedure without a vertical incision can be performed in patients with large breasts for breast reconstruction postmastectomy. It is possible to utilize the superior flap in conjunction with the de-epithelialized inferior flap of the breast and obtain good projection with this method. Furthermore, avoidance of the vertical incision reduces breakdown at the T-junction and is aesthetically beneficial. (*Plast Reconstr Surg Glob Open* 2021;9:e3786; doi: 10.1097/GOX.0000000000003786; Published online 23 August 2021.)

INTRODUCTION

Breast cancer, by far the most common invasive cancer found in women, makes up around 25% of cancer cases and 14% of cancer deaths in women, where it affects one in seven women worldwide.¹ Treatment approaches are usually multifactorial, based on the cancer stage and patient age, comorbidities, and preference. Treatment can include chemotherapy, radiation therapy, hormonal therapy, monoclonal antibodies, and surgery. Surgical approaches can include lumpectomy and mastectomy, which can be partial or total.² The “Goldilocks mastectomy” was first described in 2012 and was designed for postmastectomy breast reconstruction by preserving and

de-epithelializing the residual mastectomy flap to create an autologous tissue breast mound. As opposed to being too flat (traditional mastectomy) or too complex (micro-surgical or implant-based), this option is meant to be just right for selected patients.³ This technique has been described in case series and case reports in patients who were poor candidates for implant-based reconstruction, simply did not want implants, or did not want to undergo major surgery, although there has been one published article using the procedure in conjunction with a lateral intercostal perforator flap on 14 women with good results.⁴⁻¹² Ideal candidates for Goldilocks procedures include patients with medical comorbidities (diabetes or obesity) presenting with macromastia or severe breast ptosis, as these patients typically have excess skin and adipose tissue remaining after the mastectomy that can be used to recreate a breast mound, improve contour and/or shape, and enhance the overall aesthetic appearance.¹³

The degree of total mastectomy is again based on cancer stage and patient age, comorbidities, and preference.

From the Charles E. Schmidt College of Medicine, Florida Atlantic University, Boca Raton, Fla.

Received for publication April 17, 2021; accepted June 29, 2021.

Copyright © 2021 The Authors. Published by Wolters Kluwer Health, Inc. on behalf of The American Society of Plastic Surgeons. This is an open-access article distributed under the terms of the [Creative Commons Attribution-Non Commercial-No Derivatives License 4.0 \(CCBY-NC-ND\)](#), where it is permissible to download and share the work provided it is properly cited. The work cannot be changed in any way or used commercially without permission from the journal.

DOI: 10.1097/GOX.0000000000003786

Disclosure: Dr. Becker is a consultant for Marina Medical and Mentor Worldwide, LLC., and Scientific Advisor for Surgical Innovation Associates. The other authors have no financial interest to declare.

This can include simple mastectomy (total mastectomy), modified radical mastectomy (Patey’s mastectomy), radical mastectomy (Halsted’s mastectomy), skin-sparing mastectomy, nipple-sparing/subcutaneous mastectomy, extended radical mastectomy, and prophylactic mastectomy.¹⁴ An incisional approach can vary and includes the hidden incision category (inframammary fold incision and scarless circumareola incision), vertical incision category (vertical incision, circumvertical incision, circumvertical incision with skin excision, and wise pattern), and transverse incision category (lateral incision, circumlateral incision, and transverse incision).¹⁵ The Goldilocks technique has evolved in use in that it can be used for salvage after implant-based reconstruction or can also be used in conjunction with nipple reconstruction.^{16,17} This technique will provide a breast mound with variable degrees of projection depending upon the amount of tissue present in the native breast and the type of incision used. This approach is not a complete substitute for formal breast reconstruction but is an alternative to near-total mastectomy in patients who may be poor candidates for traditional reconstruction or those patients who prefer a one-stage reconstruction without the time commitment and potential morbidities of traditional multistage reconstruction.¹³

All the articles from 2012 to 2020 on this procedure use either the anchor, inverted T, or even a lateral circumareolar incision; however, no studies have been published performing the procedure without a vertical incision in conjunction with the inframammary incision. The aim of this article is to emphasize the potential benefits of the Goldilocks procedure without a vertical incision utilizing a case series of three patients, and to review the literature on surgical techniques and outcomes compared to our patients.

METHODS

A retrospective chart review of patients presenting for postmastectomy breast reconstruction surgery was performed. All patients were seen by a single surgeon and underwent the Goldilocks procedure without a vertical incision from March 2018 to October 2020. Informed consent was obtained and information regarding patient demographics, medical history, surgical materials and technique, and postoperative outcomes was abstracted from provider notes along with narrative literature review described in detail in the discussion section.

A total of three cases of the Goldilocks procedure without a vertical incision are described. One patient had a long-term absorbable mesh placed. Patients were 79, 69, and 54 years of age at the time of surgery. Patients had body mass indices (BMIs) of 30.2, 36.0, and 40.8. Medical history, medications, and smoking history are further detailed (Table 1). This institutional review board-exempt study adheres to the ethical principles stated in the 2013 Declaration of Helsinki which were strictly followed.

Surgical Technique

In the preoperative area with the patients in the upright position, measurements were verified, and markings for the skin incisions outlining the upper flap extending laterally from the midaxillary line, medially to the sternal border, and down to the upper areola were made along with inferior markings outlining the inferior flap for de-epithelialization and removal of the nipple areolar complex by the breast surgeon (Fig. 1). The patients were prepared and draped in the routine sterile fashion in the supine position under general anesthesia. After the breast surgeon completed the bilateral mastectomies with removal of the nipple areolar complex, the mastectomy

Table 1. Patients Undergoing Goldilocks Procedure without a Vertical Incision

Patient ID	Age at Surgery	Height (in.), Weight (lb), BMI	Comorbidities
1	79	61, 160, 30.2	Bilateral breast cancer, hypertension
2	69	64, 210, 36.0	Bilateral breast cancer, obesity, HTN, CAD, HLD, IBS, diabetes
3	54	65, 245, 40.8	Right breast cancer, obesity, sleep apnea, GERD
Allergies		Smoking History	Surgical History
Morphine NKDA NKDA		No Marijuana Marijuana	Left breast lumpectomy Back, right hand, bilateral knees Hysterectomy
Medications			
Lisinopril, amlodipine, anastrozole Paroxetine, percocet, folate, pantoprazole, insulin, metformin, aspirin, atorvastatin, lisinopril None			
Year of Procedure	Follow-Up Time (mo)	Complications	Miscellaneous
2018	10	Seroma	Postradiation. Mesh used
2020	16	Left breast scar	Left scar revision with bilateral fat grafting seven months postoperative. Nipple tattoos
2020	8	None	N/A

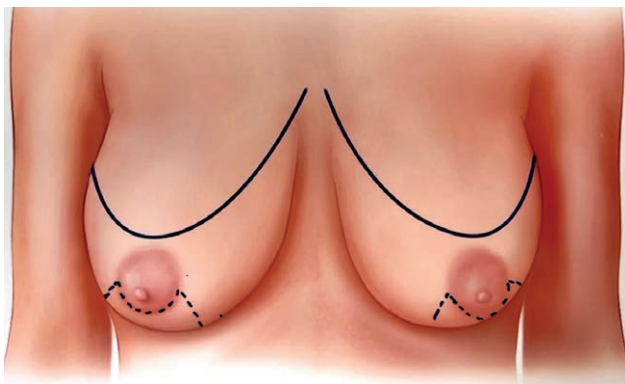


Fig. 1. Preoperative markings used for all patients. Superior flap indicated by solid blue line and inferior flap with blue dotted line.

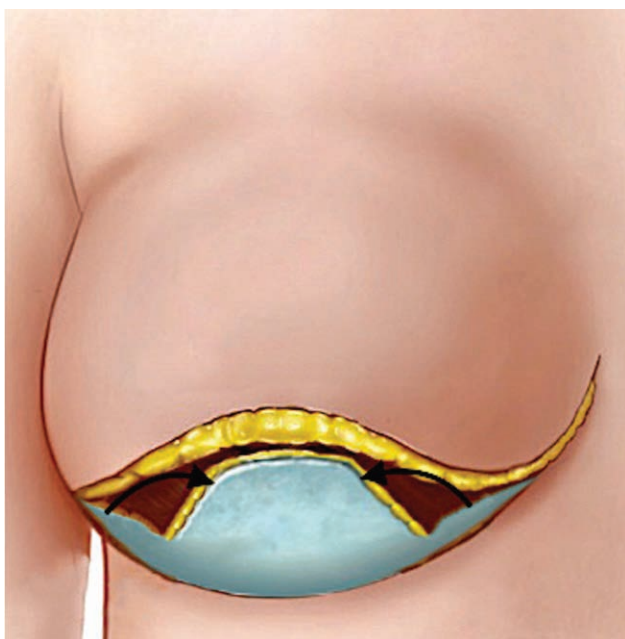


Fig. 2. Lateral and medial flap tucked under inferior flap (black arrows).

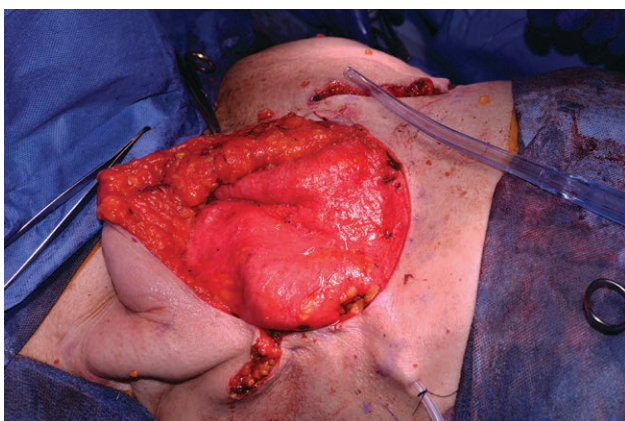


Fig. 3. Intraoperative view of lateral and medial flap folded under inferior flap.

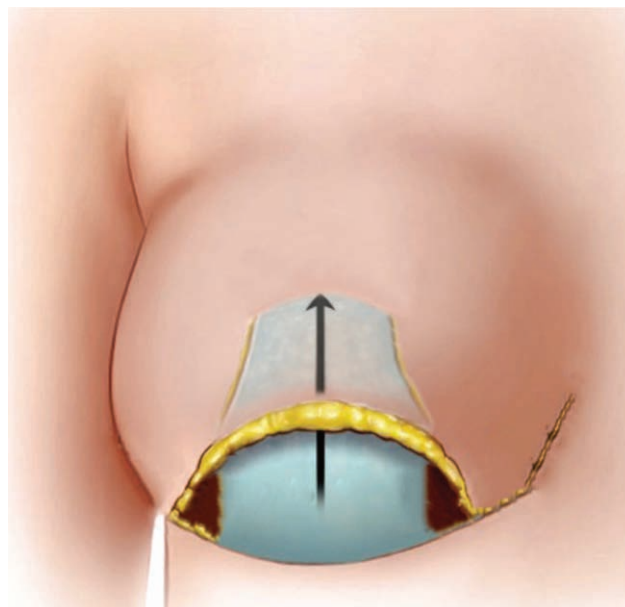


Fig. 4. Inferior flap advanced superiorly and sutured to the chest wall (black arrow).

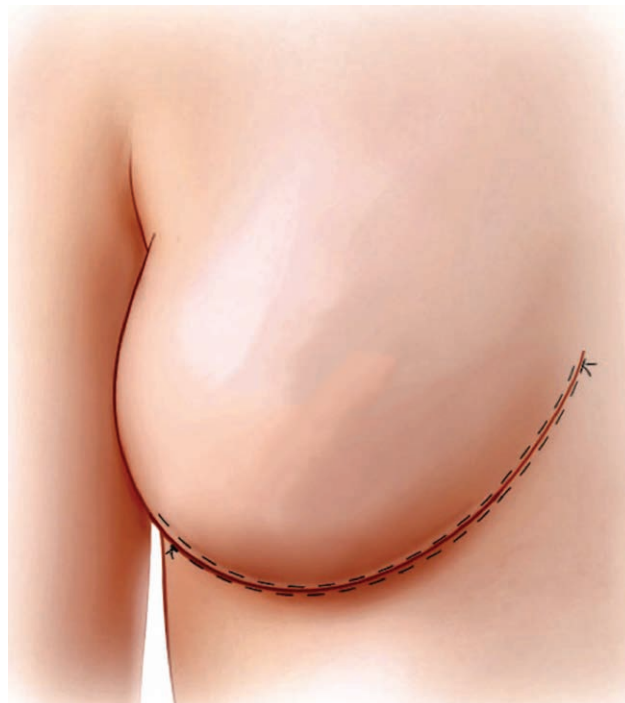

Fig. 5. Final closure with incision at the inframammary fold.

sites were irrigated with antibiotic solution and hemostasis was obtained. The superior flap was maintained and further elevated superiorly, if necessary. The inferior flap and the medial and lateral extensions were de-epithelialized. The de-epithelialized medial and lateral extensions were folded beneath the central portion of the flap to give extra projection (Figs. 2 and 3). Two Jackson–Pratt drains were placed into each pocket and sutured to the

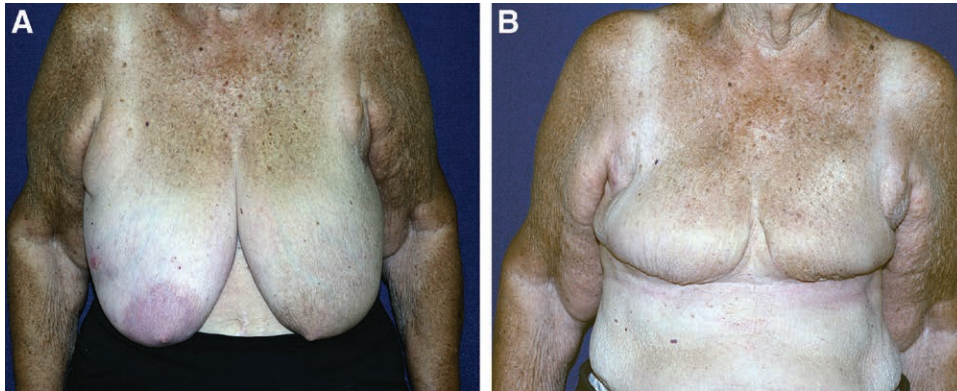


Fig. 6. Front view photographs of a 79-year-old female patient with a BMI of 30.2. A, Preoperative. B, Postoperative at 10 months.

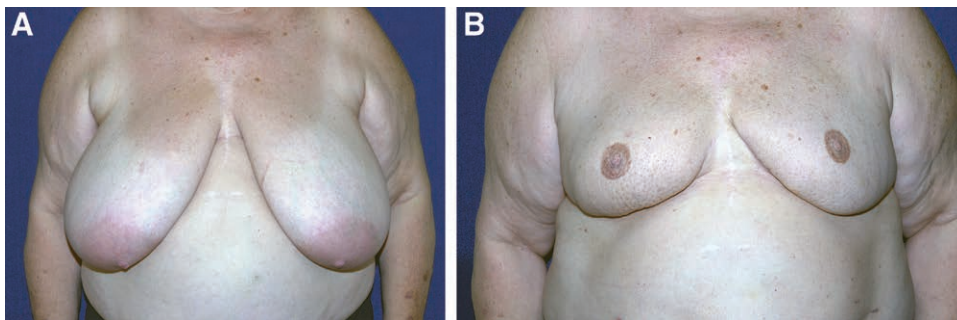


Fig. 7. Patient photographs of a 69-year-old woman with a BMI of 36.0. A, Preoperative. B, Postoperative at 8 months.

skin. The inferior flap was then advanced superiorly and anchored to the pectoralis major muscle with 2-0 interrupted Vicryl sutures (Fig. 4). This can be further supported with a long-term absorbable synthetic mesh. The superior flap was then advanced inferiorly and anchored to the inframammary fold with 2-0 interrupted Vicryl sutures. The flap was closed with two rows of #1 Stratafix sutures, one from medial to lateral, and the other from lateral to medial, creating further central projection followed by 3-0 running subcuticular Monocryl suture. The final result creates one incision at the inframammary fold (Fig. 5).

RESULTS

Outcomes

Postoperative follow-up time ranged from 8 to 16 months (average of 11.3 mo) immediately following breast reconstruction with the Goldilocks procedure without a vertical incision. During this time, we did not note any complications of infection, hematomas, or breakdown of the incisions, but did have a seroma requiring drainage in patient 1 and an OR take back for left breast scar revision in patient 2. Patient 2 also had bilateral nipple tattooing with subsequent fat grafting to further increase the breast volume. Preoperative and postoperative images for

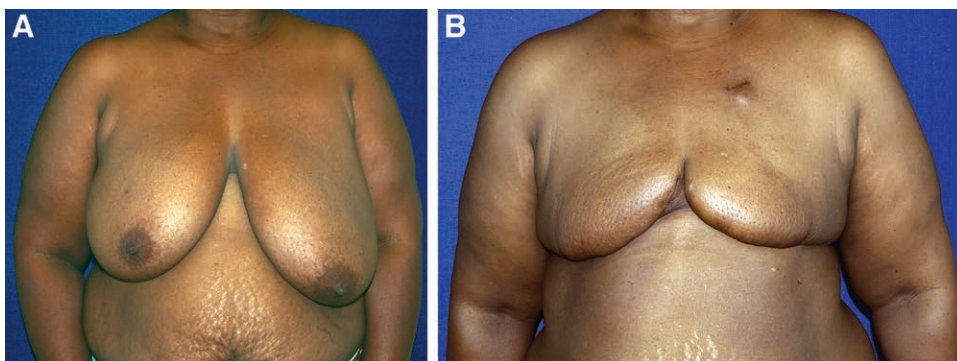


Fig. 8. Patient photographs of a 54-year-old woman with a BMI of 40.8. A, Preoperative. B, Postoperative at 3 months.

Table 2. Review of Literature on Surgical Techniques and Outcomes for Goldilocks Procedure

Author, Year, Country	Study Design (N)	Average Age (Range)	Average BMI (Range)	Procedure	Incision Type	Complications	Patient Satisfaction
Zingaretti et al, 2020, Italy ¹⁷	Retrospective cohort (7 patients, 9 breasts)	N/A	N/A	Goldilocks mastectomy with nipple reconstruction	Inverted T	0	The treatment left an inconspicuous scar and was much appreciated by all patients (and often by their partners)
Zavala et al, 2019, South Korea ¹⁶	Case study (1 patient, 1 breast)	74	N/A	Right-sided explantation with free nipple graft, left-sided reduction mammoplasty	Inverted T	0	Cosmetic outcome of the procedure was satisfactory
Chaudhry et al 2019, USA ¹³	Retrospective cohort (53 patients, 96 breasts)	55.8 (33–77)	33.7 (19.2–54.6)	Goldilocks mastectomy	Inverted T (R), anchor (L)	Out of 96, 3 wound dehiscence, 2 seroma, 2 cellulitis, 1 hematoma, and 1 OR take-back	Our future studies will also need to assess patient satisfaction using a validated scoring system such as BREAST-Q
Schwartz, 2019, USA ¹²	Retrospective cohort (14 patients, 28 breasts)	N/A	33.5 (24.4–44)	Simultaneous Goldilocks mastectomy and LICAP flap reconstruction with free nipple graft	Anchor with bilateral LICAP donor sites	Out of 28, 2 donor sites required postoperative wound care, 6 breasts suffered complications from the Wise pattern closure, and 4 had areas of fat necrosis, none of which required intervention and healed with conservative measures	N/A
Oliver et al, 2018, USA ¹¹	Retrospective cohort (95 patients, 172 breasts)	55.8 (33–77)	33.7 (19.2–54.6)	Goldilocks mastectomy with adjuvant fat grafting or staged mastopexy	Inverted T	0	Our future studies analyzing our outcomes data with Goldilocks breast reconstruction will assess patient satisfaction using a validated scoring system such as BREAST-Q
Richardson and Aronowitz, 2018, USA ¹⁰	Case study (1 patient, 2 breasts)	57	Obese	Right Goldilocks mastectomy with sentinel node biopsy and prophylactic left Goldilocks mastectomy with bilateral nipple preservation	Anchor	0	N/A
Schwartz, 2017, USA ⁹	Retrospective cohort (10 patients, 20 breasts)	N/A	45 (37–50)	Bilateral Goldilocks mastectomy with free nipple grafts	Anchor	Two patients had wound healing complications, but were completely healed within 8 wks	N/A
Schwartz and Skowronski, 2017, USA ⁸	Case study (1 patient, 2 breasts)	66	N/A	Two-stage bilateral Goldilocks mastectomy and lymph node evaluation with free nipple grafts and fat grafting	Anchor	0	N/A
Ter Louw et al, 2017, USA ⁷	Case study (1 patient, 1 breast)	21	N/A	Right-sided removal of fibroadenoma with Goldilocks mastectomy and free nipple graft	Anchor	0	The patient was ecstatic with her outcome
Schwartz and Skowronski, 2016, USA ⁶	Case study (1 patient, 2 breasts)	50	N/A	Bilateral Goldilocks mastectomy with free nipple grafts	Anchor	0	N/A

(Continued)

Table 2. (Continued)

Author, Year, Country	Study Design (N)	Average Age (Range)	Average BMI (Range)	Procedure	Incision Type	Complications	Patient Satisfaction
Ogawa, 2015, Japan ⁵	Retrospective cohort (5 patients, 6 breasts)	72 (67–76)	29.32 (25.1–39)	Goldilocks mastectomy	Inverted T	Two patients had delayed wound healing.	Of the two patients who were considered to have had a good cosmetic result, the bilateral case was very much satisfied with the cosmetic result. However, satisfaction of the severely obese patient was not high, as she thought that she had received breast reconstruction. By contrast, three patients with poor cosmetic results were thought to have received mastectomy, and they did not complain about the cosmetic result. Healthy and aesthetically appealing appearance
Krishnan et al, 2015, USA ⁴	Case study (1 patient, 2 breasts)	35	N/A	Bilateral nipple-sparing Goldilocks mastectomy with lateral circumareolar mastopexy	Lateral circumareolar	0	Patients report high levels of satisfaction with their results and an IRB study comparing patient satisfaction with the Goldilocks mastectomy versus formal reconstruction is currently underway
Richardson and Ma, 2012, USA ³	Retrospective cohort (32 patients, 50 breasts)	61.5 (41–94)	30.3 (18–51.9)	Goldilocks mastectomy	Inverted T	Out of 50, 3 developed cellulitis, prolonged seroma formation requiring JP drainage.	

N/A, not applicable.

patients 1, 2, and 3 are shown in [Figures 6–8](#), respectively. All patients were pleased with their results and healing outcomes according to clinical notes from all postoperative appointments.

DISCUSSION

Literature Review

The search was performed using keywords “Goldilocks mastectomy” in PubMed and Google Scholar. Manual searches were also performed by reviewing the references of identified articles and relevant review articles. With these parameters, a total of 15 articles were identified. Thirteen articles were included as they were those that contained primary data on the above-named procedure consisting of local tissue recruitment for breast reconstruction postmastectomy and one using a perforator flap. Two articles were excluded since they did not include the procedure or did not include information on surgical techniques and/or outcomes. Extracted information from these studies included general demographic information, characteristics of the study sample, surgical technique, patient- and/or physician-reported outcomes, complication types and rates, and satisfaction rates. From the literature search, there were seven retrospective cohort studies and six case studies. Of the retrospective cohort studies, two appear to pertain to the same cohort of patients. A total of 222 patients participated in these studies, with 391 Goldilocks mastectomies, both unilateral and bilateral, performed. Six retrospective cohort studies, inclusive of 121 patients and 209 procedures, reported complications with rates ranging from 0% to 43%, an overall rate of 13%, and with only one reported case of a patient needing a subsequent unintended surgery. One retrospective cohort study, inclusive of 95 patients and 172 procedures, did not include any complication rates. All six case studies, inclusive of six patients and 10 procedures, did not report any significant complications. Patient satisfaction was not fully quantified by any of the studies; however, some of the studies vaguely suggested that the patients were “overall satisfied by the cosmetic results.” A list of these studies is provided in [Table 2](#).

In this study, we offer a review of our preliminary but potentially promising approach performing a Goldilocks mastectomy using a horizontal inframammary incision without a vertical incision. Prior studies of the Goldilocks procedure have not documented the omission of a vertical incision, and there remains a need for an expanded description of this procedure along with the use of nipple tattooing and/or mesh. A variety of factors motivated the senior author to consider using a horizontal inframammary incision without a vertical incision. The most pertinent was incision breakdown and overall patient satisfaction and cosmetic appearance. Our study population was roughly similar, in terms of age and BMI, to those described by previous studies on Goldilocks mastectomies. Complications associated with Goldilocks mastectomy, such as infection and hematoma, were not observed in our patients; however, seroma requiring drainage and an OR take back for scar revision was encountered. The three

patients were followed at 3, 8, and 10 months. Based on our review of the literature on Goldilocks mastectomies, complication rates span a wide range.

Our review of the literature discussing surgical technique and outcomes for the Goldilocks procedure in breast reconstruction reveals a need for further study in this field as more surgeons adopt the procedure. Almost one-half of identified studies were single-patient case studies. Apart from these, the other studies were retrospective cohort studies published in the last eight years following the first article establishing this relatively new technique. Prior studies involved the use of the anchor or inverted T incisions with one study using the lateral circumareolar incision. Six studies used a free nipple graft, two studies had nipple preservation, two studies performed augmentation with fat grafting, one study reconstructed the nipple, and one used the procedure in conjunction with a lateral intercostal perforator flap with additional donor site complications.¹² None of the studies discussed the use of an inframammary incision with no vertical incision.

CONCLUSION

There are several limitations of this case series. First, the sample size is small, and the same lead surgeon was responsible for all cases. Second, the duration of follow-up is short, and a longer duration of follow-up would be preferable to capture and account for longer-term outcomes, including overall satisfaction with aesthetic appearance, scar features, cancer recurrence, and/or subsequent procedures. Finally, our review of the literature focused on the limited prior studies that included information regarding surgical planning, technique, or outcomes. As a result, studies documenting relevant pre-surgical considerations such as chemotherapy and/or radiation are not included here. However, the advantages of a horizontal inframammary incision that can be concealed in the inframammary fold without a vertical incision are worthy of presenting.

The Goldilocks procedure presented in this study allows for reconstruction of the breast using a horizontal incision and avoids the use of the vertical incision. This limits scar formation to optimize the aesthetic outcome and avoids complications from wound dehiscence at the T-junction. This technique can also be used to obtain good projection by using the inferior flap and suturing it into the upper pole with possible reinforcement with mesh and can be further enhanced with fat grafting. As breast reconstruction with the Goldilocks procedure becomes more common, additional research regarding surgical techniques and outcomes are warranted.

Hilton Becker, MD
670 Glades Rd, STE 220
Boca Raton, Florida, 33431
E-mail: Hilton@beckerMD.com

REFERENCES

1. Momenimovahed Z, Salehiniya H. Epidemiological characteristics of and risk factors for breast cancer in the world. *Breast Cancer (Dove Med Press)*. 2019;11:151–164.
2. Moo TA, Sanford R, Dang C, et al. Overview of breast cancer therapy. *PET Clin*. 2018;13:339–354.
3. Richardson H, Ma G. The Goldilocks mastectomy. *Int J Surg*. 2012;10:522–526.
4. Krishnan NM, Bamba R, Willey SC, et al. Explantation following nipple-sparing mastectomy: the Goldilocks approach to traditional breast reconstruction. *Plast Reconstr Surg*. 2015;135:795e–796e.
5. Ogawa T. Goldilocks mastectomy for obese Japanese females with breast ptosis. *Asian J Surg*. 2015;38:232–235.
6. Schwartz JC, Skowronski PP. Case report of a definitive autologous reconstruction in a patient requiring immediate postoperative anticoagulation and reduced operative time. *Int J Surg Case Rep*. 2016;25:86–88.
7. Ter Louw RP, Bruce SB, Nahabedian MY. Partial breast reconstruction with Goldilocks technique after excision of giant fibroadenoma: a case report. *Plast Reconstr Surg Glob Open*. 2017;5:e1200.
8. Schwartz JD, Skowronski PP. Extending the indications for autologous breast reconstruction using a two-stage modified goldilocks procedure: a case report. *Breast J*. 2017;23:344–347.
9. Schwartz JC. Goldilocks mastectomy: a safe bridge to implant-based breast reconstruction in the morbidly obese. *Plast Reconstr Surg Glob Open*. 2017;5:e1398.
10. Richardson H, Aronowitz JA. Goldilocks mastectomy with bilateral in situ nipple preservation via dermal pedicle. *Plast Reconstr Surg Glob Open*. 2018;6:e1748.
11. Oliver JD, Chaudhry A, Vyas KS, et al. Aesthetic Goldilocks mastectomy and breast reconstruction: promoting its use in the ideal candidate. *Gland Surg*. 2018;7:493–495.
12. Schwartz JD. Toward a more definitive goldilocks mastectomy: simultaneous addition of the lateral intercostal perforator flap. *Plast Reconstr Surg Glob Open*. 2019;7:e2132.
13. Chaudhry A, Oliver JD, Vyas KS, et al. Outcomes analysis of Goldilocks mastectomy and breast reconstruction: a single institution experience of 96 cases. *J Surg Oncol*. 2019;119:1047–1052.
14. Lazaraviciute G, Chaturvedi S. Mastectomy—A critical review. *Open J Clin Diagnost*. 2017;07:58–66.
15. Lotan AM, Tongson KC, Police AM, et al. Mastectomy incision design to optimize aesthetic outcomes in breast reconstruction. *Plast Reconstr Surg Glob Open*. 2020;8:e3086.
16. Zavala KJ, Kwon JG, Han HH, et al. The Goldilocks technique: an alternative method to construct a breast mound after prosthetic breast reconstruction failure. *Arch Plast Surg*. 2019;46:475–479.
17. Zingaretti N, Guarneri GF, Francesco F, et al. Optimizing aesthetic outcomes after Goldilocks mastectomy: a new method of nipple reconstruction. *Arch Plast Surg*. 2020;47:629–630.