CASE REPORT – OPEN ACCESS

International Journal of Surgery Case Reports 31 (2017) 145–149

Contents lists available at ScienceDirect

International Journal of Surgery Case Reports

journal homepage: www.casereports.com

Traumatic tension pneumocephalus: Two case reports

Abubaker Al-Aieb[a], Ruben Peralta[a], Mohammad Ellabib[a], Ayman El-Menyar[b,c,*], Hassan Al-Thani[a]

[a] Department of Surgery, Trauma Surgery, Hamad General Hospital, Doha, Qatar
[b] Department of Surgery, Trauma Surgery, Clinical Research, Hamad General Hospital, Doha, Qatar
[c] Clinical Medicine, Weill Cornell Medical College, Doha, Qatar

ARTICLE INFO

Article history:
Received 3 November 2016
Received in revised form 16 January 2017
Accepted 16 January 2017
Available online 18 January 2017

Keywords:
Head trauma
Tension pneumocephalus
Cerebrospinal fluid leak
Rhinorrhea

ABSTRACT

INTRODUCTION: Traumatic pneumocephalus rarely evolves into tension pneumocephalus. It can be devastating if not recognized and treated promptly.

CASE PRESENTATION: We presented two cases of post-traumatic tension pneumocephalus. A 30- year old male pedestrian hit by a car presented with right frontal bone fracture extending to right frontal sinuses. He developed pneumocephalus involving all ventricles and subdural space and extending down to foramen magnum with tight basal cistern. The patient was managed conservatively. During the hospital course, he developed cerebrospinal fluid leak from the facial fractures and meningitis. After complete recovery, the patient was discharged home in a good health condition. The second case was a 43- year old lady driver who involved in a motor vehicle crash and presented with comminuted fracture of the right frontal bone, right parietal extra-axial hemorrhage. She developed pnemocephalus involving the bilateral frontal lobes, mainly on the left side with extension to the left lateral ventricle. Pneumocephalus was also noted in the pre-pontine cistern. The patient had rhinorrhea during the hospital course. The patient underwent wound debridement, intracranial pressure monitoring, and repair of her globe and advancement flap for right facial injury.

CONCLUSIONS: These are two rare cases with posttraumatic tension pneumocephalus treated conservatively with a favorable outcome. Early diagnosis of tension pneumocephalus is a crucial step to facilitate early recovery; however, the associated injuries need attention as they could influence the hospital course.

1. Introduction

Pneumocephalus is known as intracerebral aerocele or pneumatocele due to a collection of air in the cranial cavity [1–5]. It could complicate head trauma in 3.9–9.7% of cases and it commonly occurs after supratentorial craniotomy as well [6–9]. The accumulation of intracranial air can be acute (<72 h) or delayed (≥72 h) [10–12]. As a rule, intracranial collection of air is benign and asymptomatic condition. Tension pneumocephalus occurs when intracranial air causes intracranial hypertension and then it causes a mass-effect with neurological deterioration. However, transformation of pneumocephalus into tension pneumocephalus is a rare event [13–15].

The presence of intracranial air indicates the presence of an open communication and should be considered as a form of cerebrospinal fluid (CSF) fistula. Air enters the intracranial space after dura tears even without direct brain laceration. This air flows "upstream" along the normal CSF pathways [16–21]. It is a serious complication and a neurosurgical emergency may be required especially when associated with clinical deterioration. Pneumocephalus could increase the risk of developing meningitis [22–25]. We report two cases of significant tension pneumocephalus following traumatic head injury. This work has been reported in line with the consensus-based surgical case report (SCARE) guidelines [26].

2. Case presentation

Case 1: A 30-year old male pedestrian hit by a car presented to the trauma resuscitation unit (TRU) with a Glasgow Coma Scale (GCS) score of 15, stable vital signs, multiple facial lacerations, tenderness over the chest wall, abdominal wall ecchymosis and right upper limb weakness.

Computerized tomography (CT) imaging of head showed right frontal and occipital lobe hemorrhagic contusions with surrounding mild edema causing effacement of the overlying cortical sulci. Right frontal bone fracture was extending to right frontal sinuses.

* Corresponding author at: Department Of Surgery, Trauma Surgery, Hamad General Hospital, P.O. Box 3050, Doha, Qatar.
E-mail addresses: Aymanco65@yahoo.com, elmenyar@yahoo.com (A. El-Menyar).

http://dx.doi.org/10.1016/j.ijscr.2017.01.038
2210-2612/

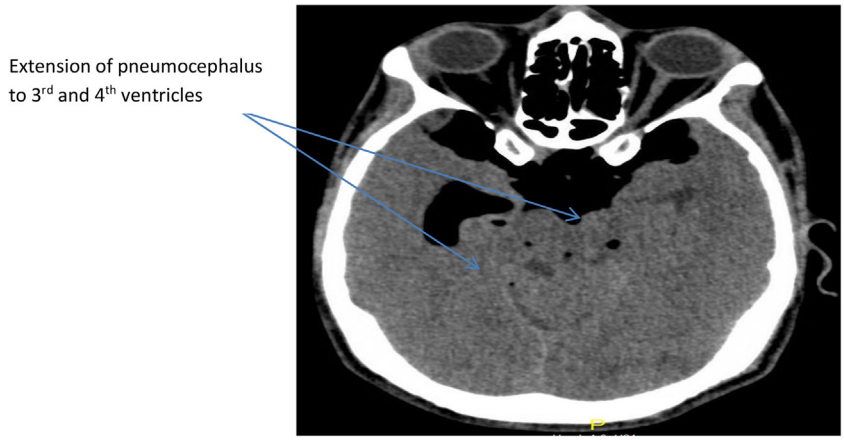

Fig. 1. Extension of pneumocephalus to 3rd and 4th ventricles (case 1).

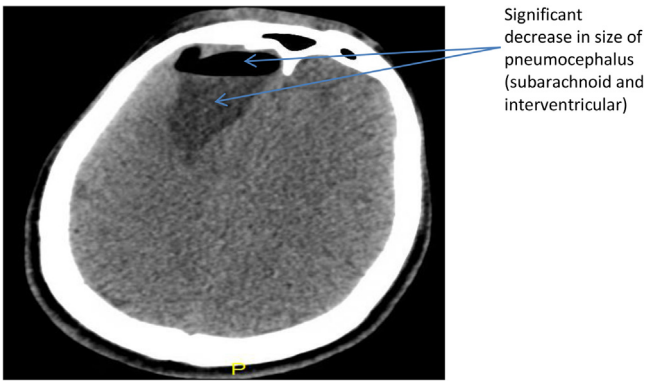

Fig. 2. Significant decrease in size of pneumocephalus (subarachnoid and interventricular) (case 1).

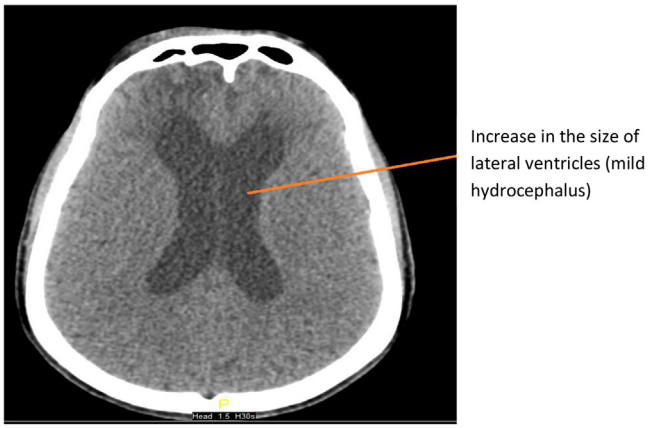

Fig. 3. Increase in the size of lateral ventricles (mild hydrocephalus) (case 1).

Multiple facial bone fractures were characterized by bilateral orbital roof fracture, comminuted fracture of the left maxillary sinus with almost complete fluid opacification and associated air loculi in maxillary, ethmoid, and sphenoid sinuses, mastoid air cells, left temporal bone fracture extending to skull base, and nasal bone fracture. Asymmetry between the atlanto-odontoid joint spaces was noted denoting joint spine instability (Figs. 1 and 2).

Cervical spine and shoulder Magnetic resonance imaging (MRI) showed atlantoaxial sublaxation, multilevel cervical disc protrusion with spinal cord indentation and contusions as well as right brachial plexuses injury. Fracture of right 8–10 ribs, fracture of left 7th rib, grade III hepatic injury, right adrenal hematoma and right ulnar fracture were also noted. Patient was managed conservatively by a multidisciplinary team including experts from trauma, neurosurgery, maxillofacial, orthopedic and plastic surgery.

Follow up CT scan on the 3rd and 6th day to evaluate the intracranial injury showed no significant changes compared to admission CT scan of head except for the regression of hyper dense brain hemorrhagic contusions.

On 1 day 13, the patient was transferred to rehabilitation unit in a good health condition for weakness of right upper limb. On day 18, he developed severe headache along with neck pain and vomiting. Physical examination showed that the patient was vitally stable and was afebrile. Urgent CT head showed newly developed extensive pneumocephalus dissecting its way to the extra axial CSF spaces with right frontal air loculus averaging 4.6 × 3.9 cm maximal dimensions. Pneumocephalus involved all ventricles and subdural space and was extending down to foramen magnum with tight basal cistern. Frontal air sinus might be the site of CSF leakage, development of pneumocephalus and air within the ventricular system and slight midline shift to the left side.

Patient was admitted to trauma intensive care unit (TICU) as an emergency case of tension pneumocephalus. He was kept in flat position with 100% oxygen supplement via oxygen mask for four days. On the 2nd and 4th days, follow up head CT scans showed significant decrease in the size of pneumocephalus. Repeat CT scan of the head showed an increase in the size of the ventricles (Fig. 3) with a slight hypo-density in the right frontal area.

A lumbar puncture was done with an initial reading of 27 mmHg, followed by an improvement in the clinical condition. Broad-spectrum antibiotics were commenced for a total duration of 28 days for meningitis. Lumbar puncture was repeated with a low opening pressure. The patient dramatically improved after completing the antibiotic course.

A repeated head CT scan before discharge showed no increase in the ventricles size compared to the previous CT scans. The patient was completely asymptomatic and discharged home in a good general health condition.

Case 2: A 43-years old lady driver involved in a motor vehicle collision causing severe head and facial injuries. She had right forehead open fracture with a globe rupture. The GCS was low (4–8) and the patient was intubated.

Imaging studies showed comminuted fractures of the right frontal bone with multiple bone fragments reaching the right ventricle. Fracture lines extended to the left frontal and right parietal bone. Subarachnoid hemorrhage was noted along the sulci of the both cerebral hemisphere. Blood density was noted in the fourth ventricle with an evidence of right parietal extra-axial

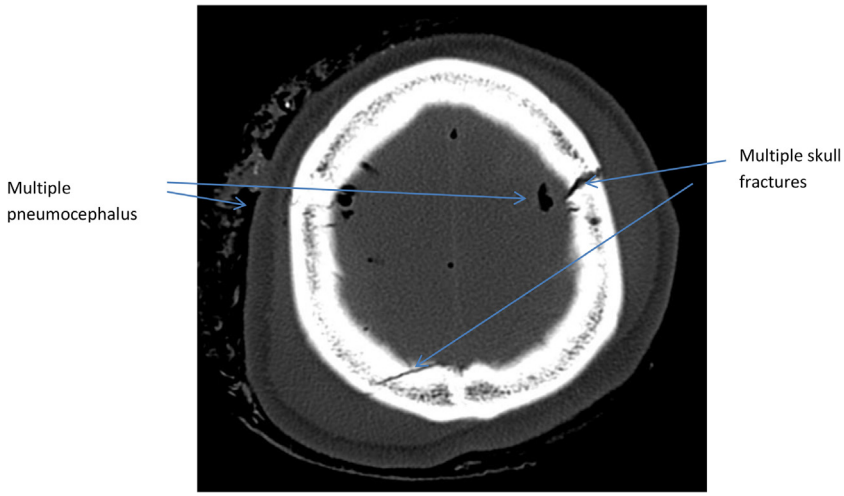

Fig. 4. CT scan shows multiple skull fractures and pneumocephalus (Case 2).

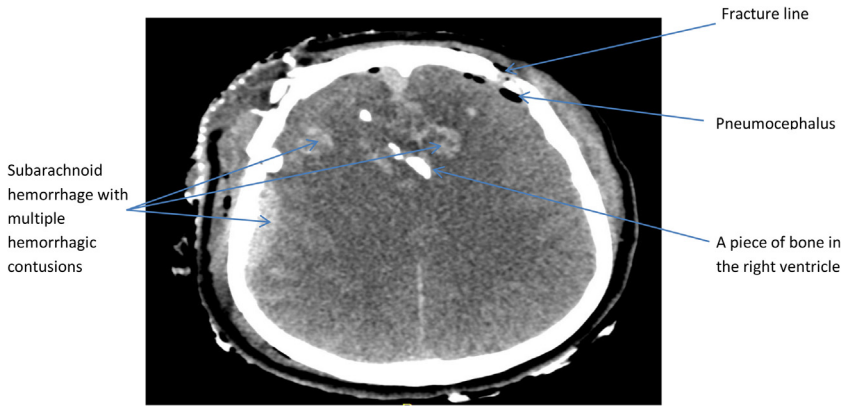

Fig. 5. CT scan shows Subarachnoid hemorrhage with multiple hemorrhagic contusions and Pneumocephalus (Case 2).

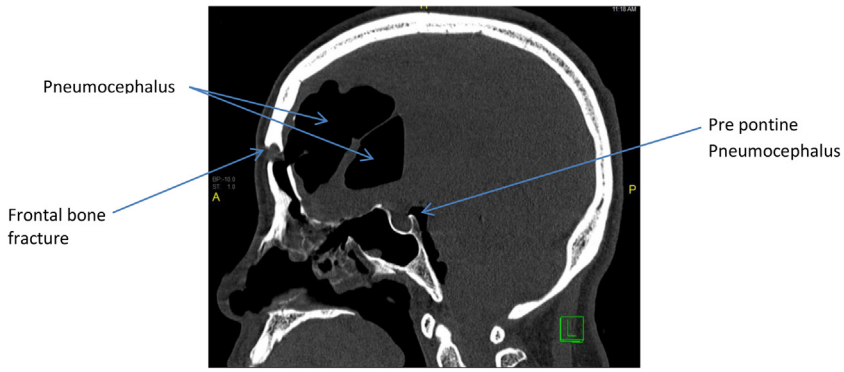

Fig. 6. Frontal bone fracture and pneumocephalus (Case 2).

hemorrhage measuring 10 mm in depth with multiple locules of pneumocephalus. There was a subgaleal hematoma in the left temporoparietal and right occipital regions. Comminuted fracture of the medial wall and floor of the right orbit with rupture of the right eye globe and multiple bony fragments were noted. Fractures of the anterior wall of the right maxillary sinus and bony nasal septum were evident. Also, fracture of the medial wall of the sphenoid sinus with blood noted in sphenoid, ethmoid right and left maxillary sinuses (Figs. 4–6). The patient underwent wound debridement cleaning, intracranial pressure monitor (ICP) insertion and repair of her globe and advancement flap for the right facial injury.

The patient was treated conservatively by a multidisplinary team. On the 12th day, repeated head CT showed evolving multi compartment hemorrhage with multiple comminuted calvarial and maxillofacial fractures. There was an improvement in the secondary mass effect and decrease in cerebral sulcal effacement and midline shift to the left side. On the 16th day, patient was extubated and her GCS score was improved (13). She was then managed by physical, occupational and speech therapy. She lost her right eye due to rupture globe and the face looked asymmetrical. Rehabilitation team started training program to improve her motivation, participation cognitive functions and ambulation. In rehabilitation

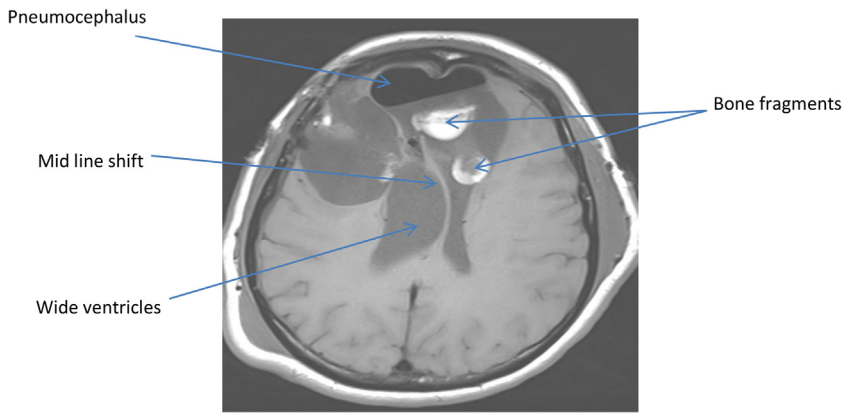

Fig. 7. Midline shift and pneumocephalus (Case 2).

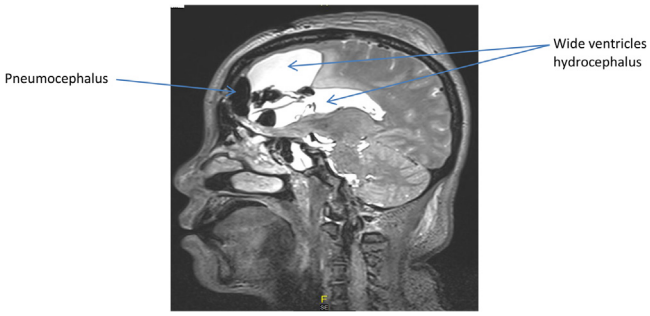

Fig. 8. MRI: bi-frontal large Cerebrospinal fluid collection with hemorrhagic contents (Case 2).

center, the patient had flu cough, fever, and watery leak from her nose.

Urgent CT head showed newly developed large pneumocephalus involving the bilateral frontal lobes, mainly on the left side with possible extension to the left lateral ventricle. It was associated with significant shift of midline structures to the right side measuring about 15 mm. Pneumocephalus was also noted in the pre-pontine cistern (Figs. 7 and 8).

Upon receiving the patient in the TICU, she was confused and afebrile and was kept in flat position with complete bed rest, oxygen therapy on nonrebreather mask (15 L/min),cefepime 2 gm IV q8 hourly and was advised to avoid or minimize straining and coughing. The patient developed rhinorrhea (CSF leak). Her repeated head CT scan showed significant decrease in the previously noted pneumocephalus with small residual air loculi seen within the right frontal lobe extending to the frontal sinus. There was significant decrease in the previously noted midline shift from 15 mm to about 3 mm, along with a decrease in the ventricular size.

On the 6th day, patient transferred to neurosurgical ward in good general condition with a plan for reconstructive surgery.

3. Discussion

We are reporting a very rare condtion of pneumocephuls after traffic-related injuries that was tense enough to cause clinical deterioration and was successfully treated symptomatically in two cases. The incidence of pneumocephalus is less than 1% in patients with head trauma, but it could reach 8% when fractures of either the paranasal sinus or the skull base presents [1–3]. Tension pneumocephalus may develop if the intracranial air creates a mass effect on the brain, resulting in a possibly life-threatening neurosurgical emergency.

Two mechanisms have been postulated to account for the entrance of air into the cranial vault. The “ball-valve mechanism” was previously described as a causative agent when a fistula allows ambient air at a pressure above the ICP to force itself into the intracranial space [4]. This process continues until the ICP overcomes the ambient pressure and the brain and dura mater are forced over the fistula. The process may repeat itself multiple times until the higher-pressure ambient air no longer overcomes the ICP. A second mechanism postulates that when a continuous CSF leak from an enclosed space is present, the loss of CSF creates a void space and relative negative pressure, allowing air to bubble in and fill the void [5–10]. This scenario is called the “Coke-bottle mechanism.” This fluid-gas exchange may continue until no additional loss of CSF is possible [11–15]. In our cases, tension pneumocephalus was not manifested initially and it took more than two weeks post trauma to develop. Both cases were treated symptomatically for tension pneumocephalus, however, the development of CSF leak, meningitis and associated injuries were issues during the hospital course that prolonged the hospital length of stay.

4. Conclusions

These are two rare cases with posttraumatic pneumocephalus treated conservatively with a favorable outcome. Early diagnosis of tension pneumocephalus is a crucial step to facilitate early recovery; however, the associated injuries may influence the hospital course.

Conflict of interest

None.

Financial issues to disclose

None.

Ethical approval

This case report was approved by the Medical Research Center, Hamad Medical Corporation (IRB #16327/16). As the data was retrieved from the chart review anonymously, a waiver of informed consent was grant by the Medical Research Center.

Consent

Data were collected retrospectively from the chart review and no direct contact with the 2 cases were there, therefore a waiver of

consent was granted and approved by the Medical Research Center, Hamad Medical Corporation (IRB #16327/16).

Author contribution

Abubaker Al-Aieb contributed in study concept or design, data collection, data interpretation, and writing the paper.

Ruben Peralta contributed in study concept or design, data collection, data interpretation, and writing the paper.

Mohammad Ellabib contributed in study concept or design, data collection, data interpretation, and writing the paper.

Ayman El-Menyar contributed in study concept or design, data collection, data interpretation, and writing the paper.

Hassan Al-Thani contributed in study concept or design, data collection, data interpretation, and writing the paper.

Guarantor

Abubaker Al-Aieb.
Ayman El-Menyar.

References

[1] E.O. Komolafe, E. Faniran, Tension pneumocephalus – a rare but treatable cause of rapid neurological deterioration in traumatic brain injury. A case report, Afr. J. Neursci. 2 (2010) 9, http://dx.doi.org/10.4314/ajns.v9i2.70412.
[2] V.O. Solomiichuk, V.O. Lebed, K.I. Drizhdov, Posttraumatic delayed subdural tension pneumocephalus, Surg. Neurol. Int. 4 (March) (2013) 37, http://dx.doi.org/10.4103/2152-7806.109537.
[3] T.H. Chandran, N. Prepageran, R. Philip, K. Gopala, A.L. Zubaidi, M.A. Jalaludin, Delayed spontaneous traumatic pneumocephalus, Med. J. Malaysia 62 (2007) 411–442.
[4] H.L. Cho, Y.M. Han, Y.K. Hong, Tension pneumocephalus after transsphenoidal surgery: report of two cases, J. Korean Neurosurg. Soc. 35 (2004) 536–538.
[5] W.E. Dandy, Pneumocephalus (intracranial pneumatocele or aerocele), Arch. Surg. 12 (1926) 949–982.
[6] W.J. Hong, C.J. Yoo, C.W. Park, S.G. Lee, Two cases of delayed tension pneumocephalus, J.Korean Neurosurg. Soc. 37 (2005) 59–62.
[7] M. Horowitz, Intracranial pneumocele: an unusual complication following mastoid surgery, J. Laryngol. Otol. 78 (1964) 128–134.
[8] N. Kiymaz, O. Demir, N. Yilmaz, Posttraumatic delayed tension pneumocephalus: case report, Inonu Universitesi Tip Fakultesi Dergisi 12 (2005) 189–192.
[9] E.O. Komolafe, Tension pneumocephalus: a rare but treatable cause of rapid neurological deterioration in traumatic brain injury: a case report, Afr. J. Med. Sci. 29 (2010) 88–91.
[10] T. Kon, H. Hondo, M. Kohno, K. Kasahara, Severe tension pneumocephalus caused by opening of the frontal sinus by head injury 7 years after initial craniotomy: case report, Neurol. Med. Chir. (Tokyo) 43 (2003) 242–245.
[11] A. Kuncz, A. Roos, L. Lujber, D. Haas, M. Al Refai, Traumatic prepontine tension pneumocephalus: case report, Ideggyogy Sz 57 (2004) 313–315.
[12] S.H. Lee, J.S. Koh, J.S. Bang, M.C. Kim, Extensive tension pneumocephalus caused by spinal tapping in patient with basal skull fracture and pneumothorax, J. Korean Neurosurg. Soc. 45 (2009) 318–321.
[13] K.M. Leong, A. Vijayananthan, S.F. Sia, V. Waran, Pneumocephalus: an uncommon finding in trauma, Med. J. Malaysia 63 (2008) 256–258.
[14] S.J. Michel, The Mount Fuji sign, Radiology 232 (2004) 449–450.
[15] P.K. Nayak, A.K. Mahapatra, Tension pneumocephalus in lateral position following posterior fossa surgery, Pan Arab J. Neurosurg. 15 (2011) 76–78.
[16] K. Oge, G. Akpinar, V. Bertan, Traumatic subdural pneumocephalus causing rise in intracranial pressure in the early phase of head trauma: report of two cases, Acta Neurochir. Wien. 140 (1998) 655–658.
[17] U.A. Pandit, B.J. Mudge, T.S. Keller, S.K. Samra, P. Kilaru, S.K. Pandit, et al., Pneumocephalus after posterior fossa exploration in the sitting position, Anaesthesia 37 (1982) 996–1001.
[18] P. Pillai, R. Sharma, L. MacKenzie, E.F. Reilly, P.R. Beery 2nd, T.J. Papadimos, et al., Traumatic tension pneumocephalus: Two cases and comprehensive review of literature, OPUS 12 Sci. 4 (2010) 6–11.
[19] H. Pruss, R. Klingebiel, M. Endres, Tension pneumocephalus with diplegia and deterioration of consciousness, Case Rep. Neurol. 3 (2011) 48–49.
[20] G.C. Satapathy, H.H. Dash, Tension pneumocephalus after neurosurgery in the supine position, Br. J. Anaesth. 84 (2000) 115–117.
[21] C.M. Schirmer, C.B. Heilman, A. Bhardwaj, Pneumocephalus: case illustrations and review, Neurocrit. Care 13 (2010) 152–158.
[22] N. Shaikh, I. Masood, Y. Hanssens, A. Louon, A. Hafiz, Tension pneumocephalus as complication of burr-hole drainage of chronic subdural hematoma: a case report, Surg. Neurol. Int. 1 (2010) 27.
[23] A. Thapa, D. Agrawal, Mount Fuji sign in tension pneumocephalus, Indian J. Neurotrauma 6 (2009) 161–163.
[24] A. Vikram, A.K. Deb, Tension pneumocephalus secondary to a dural tear, Appl. Radiol. 40 (2011) 37–38.
[25] A.M. Vitali, A.A. le Roux, Tension pneumocephalus as a complication of intracranial pressure monitoring: a case report, Indian J. Neurotrauma 4 (2007) 115–118.
[26] R.A. Agha, A.J. Fowler, A. Saeta, I. Barai, S. Rajmohan, D.P. Orgill, SCARE Group, The SCARE statement: consensus-based surgical case report guidelines, Int. J. Surg. 34 (2016) 180–186, http://dx.doi.org/10.1016/j.ijsu.2016.08.014.