

Inferior vena cava reconstruction with tubularized bovine pericardium

J. Hunter Mehaffey, MD, Robert Jason Perry, MD, Nicolas H. Pope, MD, and Gilbert R. Upchurch Jr, MD, Charlottesville, Va

A 32-year-old man presented with a large, locally advanced sarcomatoid right renal cell carcinoma invading the duodenum and inferior vena cava (IVC). Because of persistent symptomatic gastrointestinal bleeding requiring repeated blood transfusion and the inability to use appropriate systemic chemotherapy, the patient was taken for palliative resection. En bloc pancreaticoduodenectomy, right nephrectomy, and IVC resection were performed with reconstruction of the IVC with tubularized bovine pericardium. Widespread availability, ease and speed of tubularized graft creation, lack of morbidity to the patient, and its inherent resistance to infection in contaminated fields make bovine pericardium an expedient reconstructive option in these challenging cases. (*J Vasc Surg Cases* 2016;2:28-30.)

Major oncologic operations necessitating resection of the inferior vena cava (IVC) pose a serious reconstructive challenge. Interposition graft options include composite saphenous vein, femoral vein, and synthetic and cryopreserved vein or artery grafts for these reconstructions.^{1,2} In the case of autologous grafts, graft harvest incurs additional morbidity to the patient and adds time to an often already protracted operation.

Bovine pericardium (BP) is used ubiquitously in vascular surgery, typically as a patch for arterial angioplasty, with excellent long-term results.³ BP can be used in contaminated fields with excellent results and is frequently used for patch repair of major venous defects.⁴ Here, the use of tubularized BP as venous conduit is described for an interposition graft of the IVC after en bloc tumor resection. Whereas tubularized pericardium was first described and patented in 1985 by Woodroof and Yang, it has seen limited clinical use in the literature.⁵ There are only a few reports of its use as a tubularized graft for major venous reconstructions.⁵⁻⁷

The purpose of this case report is to describe the use of tubularized BP as a conduit for reconstruction of the IVC. Particularly, this case highlights the safety and practicality of this method. Tubularized BP should be considered an expedient and low-morbidity option for major venous reconstruction requiring an interposition graft. With the consent of the patient's guardian, we present a case report

describing the use of tubularized BP for interposition graft of the IVC after oncologic resection.

CASE REPORT

A 32-year-old man presented with scrotal swelling and right flank pain beginning approximately 3 months before presentation. Axial imaging demonstrated a large retroperitoneal mass circumferentially invading the IVC (*Fig 1*) with multiple pulmonary metastases. Fine-needle aspiration of the mass revealed a sarcomatoid renal cell carcinoma. Medical management for possible downstaging was attempted, but the patient developed significant gastrointestinal bleeding requiring multiple blood transfusions. After extensive discussions with the patient, family, and multiple surgical services, the patient was scheduled for right nephrectomy, pancreaticoduodenectomy, partial hepatectomy, and IVC resection with reconstruction.

He was taken to the operating room by the surgical oncology team for midline laparotomy and abdominal exploration, which revealed a massive tumor occupying the right hemiabdomen. The tumor was mobilized, a Whipple resection was performed, and the tumor was fully resected en bloc with all associated structures with the exception of the midportion of the IVC. At this point, the vascular surgery team completed the resection and reconstructed the IVC. The option of using longitudinally composited cryopreserved saphenous vein was entertained, but there was a significant size mismatch between the graft and the patient's IVC. Ultimately, a large graft of BP was tubularized over a 20-mL syringe with an endovascular tri-stapler. An end-to-end IVC to tubularized pericardium anastomosis was then performed with triangulated running 4-0 Prolene suture, leaving a small gap in the anastomosis for deairing later. The graft was then cut to length and an end-to-end graft to terminal IVC anastomosis was completed, again with triangulated 4-0 Prolene suture. Because of slight size mismatch between the graft and the terminal IVC, the right iliac vein was opened to accommodate the size mismatch and incorporated into the distal anastomosis. Once the distal anastomosis was completed, the patient was placed in Trendelenburg position, and flow was allowed to resume from the lower extremities to flush any air out of the newly reconstructed IVC. The proximal anastomosis was then completed with good hemostasis

From the Department of Vascular Surgery, University of Virginia.

Author conflict of interest: none.

Correspondence: J. Hunter Mehaffey, MD, Division of Vascular and Endovascular Surgery, University of Virginia, Box 800679, Charlottesville, VA 22903 (e-mail: jhm9t@virginia.edu).

The editors and reviewers of this article have no relevant financial relationships to disclose per the Journal policy that requires reviewers to decline review of any manuscript for which they may have a conflict of interest.

2352-667X

Copyright © 2016 The Authors. Published by Elsevier Inc. on behalf of the Society for Vascular Surgery. This is an open access article under the CC BY-NC-ND license (<http://creativecommons.org/licenses/by-nc-nd/4.0/>).

<http://dx.doi.org/10.1016/j.jvsc.2016.01.002>

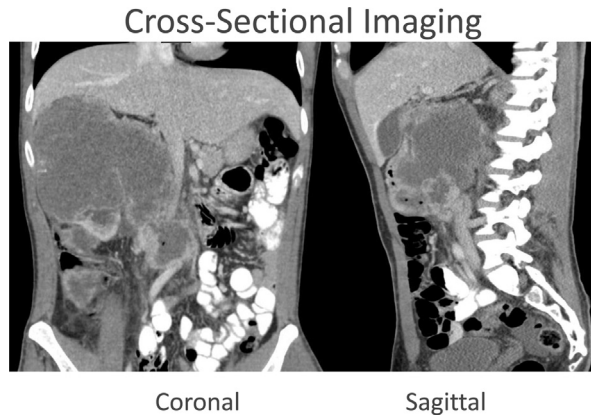


Fig 1. Sagittal and coronal computed tomography images of the patient's tumor preoperatively. As illustrated here, there is circumferential involvement of the inferior vena cava (IVC) and abutment to the aorta.

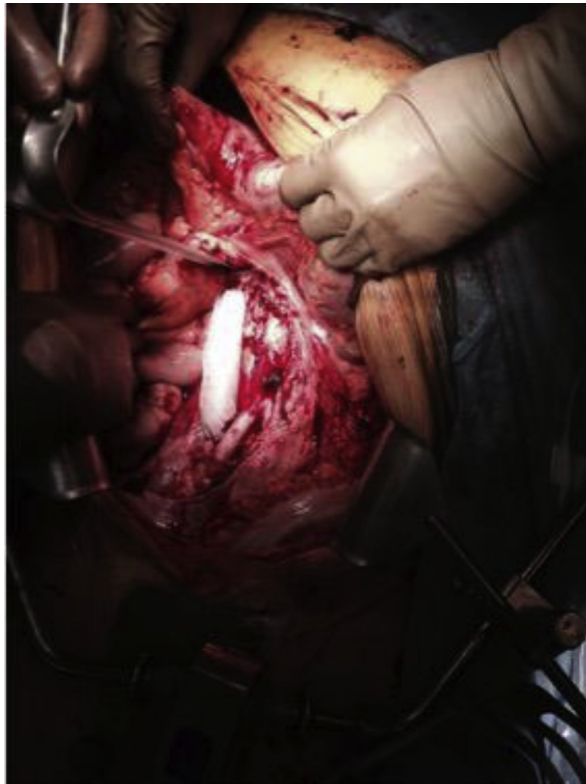

Fig 2. An intraoperative photograph taken after reconstruction of the inferior vena cava (IVC) with tubularized bovine pericardium (BP).

(Fig 2). At this point, the hepaticojejunostomy, pancreaticojejunostomy, and gastrojejunostomy were performed by the surgical oncology team.

Final pathologic evaluation revealed a 19-cm sarcomatoid renal cell carcinoma with extensive pericaval involvement. The patient's postoperative course was complicated by a

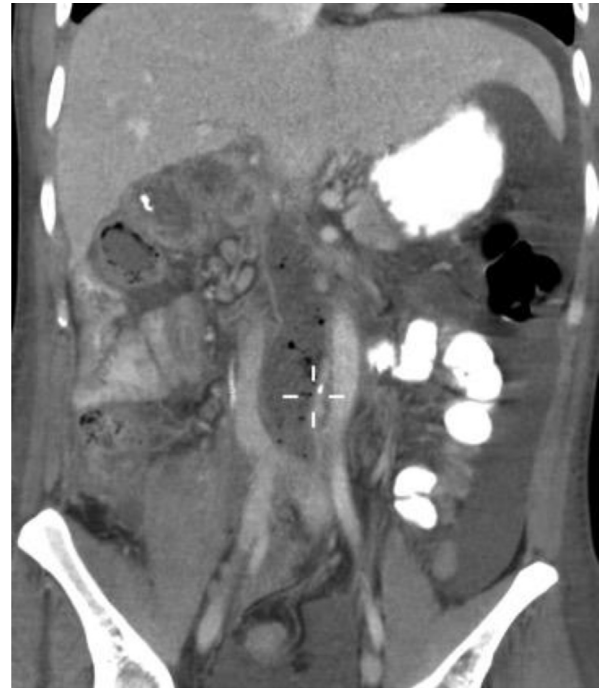

Fig 3. A coronal computed tomography scan of the reconstruction 30 days after the operation. As demonstrated here, the inferior vena cava (IVC) is patent, and the patient is doing well.

culture-negative intra-abdominal fluid collection requiring percutaneous drainage. He was discharged home on postoperative day 12 on 325 mg of aspirin. He was doing well with a patent graft at 1 month (Fig 3) and with no leg swelling at 2 months postoperatively.

Ultimately, the patient suffered progression of his disease and expired 8 months later. Therefore, consent for this report was obtained from his wife.

DISCUSSION

This case report describes the use of tubularized BP in the reconstruction of a large IVC defect in a young patient after oncologic resection. Tubularized BP has several potential advantages over other graft materials: it is readily available, is expeditiously fashioned to fit the patient's anatomy, has excellent long-term results in other vascular applications, is durable for arterial reconstructions even in the setting of gross infection, is relatively cheap, and presents no morbidity risk to the patient.^{3,4} The cost of BP is a fraction of cryopreserved vessel, even with the additional cost of a vascular tri-stapler; an interposition graft can be fashioned quickly and more cost-effectively than any comparable options.

A small case series of 15 patients presented by Ciccone et al demonstrated excellent outcomes of superior vena cava reconstruction with tubularized BP in the chest with mean follow-up of 46 months.⁸ The same institution reported the use of tubularized BP for left femoral vein in

the trauma setting with no stenosis, calcification, or degradation at 2-year follow-up.⁶ We found one other case report in the literature detailing the use of tubularized BP as an IVC interposition graft.⁹ All three of these reports describe a similar technique of BP tubularization over a syringe with either a vascular stapler or running Prolene suture.

In our case, a 32-year-old man with a large, locally advanced sarcomatoid right renal cell carcinoma underwent resection of the tumor, IVC, and infrarenal aorta with tubularized BP IVC reconstruction. In addition to use in oncologic reconstructions, tubularized BP potentially could be used to repair major vascular traumatic injuries where abdominal soilage demands a conduit resistant to infection and the patient's condition precludes a protracted operation. This may find particular application in military or other austere medical environments where tubularized BP's ease of storage and customizability make it an attractive option to more traditional graft materials.

CONCLUSIONS

Tubularized BP represents an excellent alternative for venous reconstruction with interposition graft in most situations encountered in vascular, oncologic, and trauma surgery. Clearly, further study of these applications is warranted.

REFERENCES

1. Nayyar R, Panda S, Saini A, Seth A, Chaudhary SK. Leiomyosarcoma of inferior vena cava involving bilateral renal veins: surgical challenges and reconstruction with upfront saphenous vein interposition graft for left renal vein outflow. *Indian J Urol* 2010;26:438-40.
2. Chervenkov V, Kirilova K, Tschirkov AL. Venous reconstruction of the inferior vena cava bifurcation for retroperitoneal rhabdomyosarcoma in a child. Case report. *J Cardiovasc Surg (Torino)* 2005;46:47-9.
3. Papakostas JC, Avgos S, Arnaoutoglou E, Nassis C, Papadopoulos G, Matsagkas MI, et al. Use of the Vasco-Guard bovine pericardium patch for arteriotomy closure in carotid endarterectomy. Early and long-term results. *Ann Vasc Surg* 2014;28:1213-8.
4. McMillan WD, Leville CD, Hile CN. Bovine pericardial patch repair in infected fields. *J Vasc Surg* 2012;55:1712-5.
5. Woodroof EA, Yang PS. Tubular prostheses prepared from pericardial tissue. US Patent 4502159 A. March 5, 1985.
6. Del Campo C, Fonseca A. Replacement of the left common iliac vein with a custom-made bovine pericardium tubular graft. *Tex Heart Inst J* 2001;28:39-41.
7. Coleman S, Kerr H, Krishnamurthi V, Wee A, Gong M, Ghoneim I, et al. The use of bovine pericardium for complex urologic venous reconstruction. *Urology* 2014;83:495-7.
8. Ciccone AM, Venuta F, D'Andrilli A, Andreotti C, Ibrahim M, Rendina EA, et al. Long-term patency of the stapled bovine pericardial conduit for replacement of the superior vena cava. *Eur J Cardiothorac Surg* 2011;40:1487-91.
9. Anaya-Ayala JE, Cheema ZF, Davies MG, Lumsden AB, Reardon MJ. Concomitant reconstruction of infrarenal aorta and inferior vena cava after en bloc resection of retroperitoneal rhabdomyosarcoma. *Vasc Endovascular Surg* 2011;45:769-72.

Submitted Oct 24, 2015; accepted Jan 19, 2016.