



## CASE REPORT

# Mediastinitis: parotid abscess complication<sup>☆</sup>

## Mediastinite: complicação de abscesso parotídeo

Thiago Pires Brito\*, Alexandre Caixeta Guimarães, Mariana Mari Oshima, Carlos Takahiro Chone

Faculty of Medical Sciences, Universidade Estadual de Campinas (UNICAMP), Campinas, SP, Brazil

Received 24 November 2012; accepted 29 March 2013

### Introdução

Deep cervical abscesses are severe conditions with multiple origins, among those the most common are odontogenic and peritonsillar. After the advent of antibiotics, suppurative parotitis which gives as a source of cervical abscess became uncommon.<sup>1</sup> Such a purulent collection spreading to other cervical or thoracic spaces can lead to extremely severe clinical features and high mortality, especially if it culminates in mediastinitis.

We are reporting a rare case of parotid abscess with dissection into mediastinum, a rare complication of salivary gland infection.

### Case presentation

A 38-year female presented at the Emergency Department with a one-week history of fever and pain located at the left parotid gland. The last three days, she had been experiencing dyspnea, painful swallowing, and worsening of her health status. She did not have a history of trauma, dental treatment or cervicofacial conditions.

At physical examination, she had clinical signs of sepsis and a firm bulge over the left parotid gland and ipsilateral IB, IIA, and III cervical levels. Examination of the oral cavity showed moderate trismus with no throat changes.

Axial computed tomography (Fig. 1) showed a collection consistent with an abscess affecting superficial and deep lobes of the parotid gland, extending into left masticator and parapharyngeal spaces. Coronal and sagittal views showed a large cervical collection extending inferiorly into the medias-

tinum through the vascular visceral space. The thoracic axial view showed that the collection involved the anterior mediastinum and documented bilateral pleural effusion.

The patient was admitted to the ICU and underwent a left lateral cervicotomy, mediastinoscopy, and posterior thoracotomy to drain the purulent collections. After the procedure, intravenous antibiotic (ampicillin + sulbactam) and corticosteroid therapy were administered. The abscess culture was positive for *Streptococcus constellatus*. The patient's in-hospital stay lasted 26 days, and the course occurred with improvement.

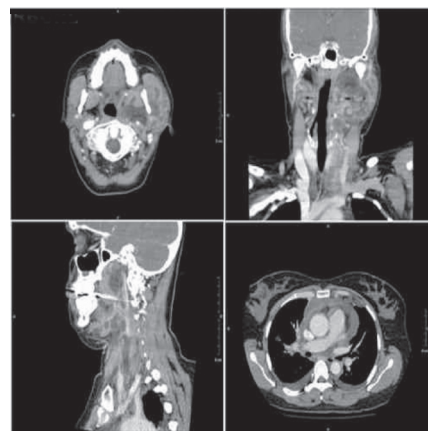


Figure 1 Computed tomography showing large abscess affecting multiple cervical spaces and extending into the anterior mediastinum.

<sup>☆</sup>Please cite this article as: Brito TP, Guimarães AC, Oshima MM, Chone CT. Mediastinitis: parotid abscess complication. Braz J Otorhinolaryngol. 2014;80:268-9.

\* Corresponding author.

E-mail: E-mail: thpbrito@gmail.com (T.P. Brito).

## Discussion

Although parotitis is the most common salivary gland infection, parotid abscess is rare.<sup>1</sup> Left untreated, the infection can organize and spread throughout deep cervical spaces, thus elevating its morbidity and mortality. It usually affects people with an impaired health, such as those carrying systemic diseases and immunosuppressed individuals. The main risk factor is dehydration due to reduced salivation and increased bacterial growth.

*Staphylococcus aureus* is the most common agent of parotid suppurative infections, as high as 80% of cases.<sup>2</sup> Infection by multiple organisms is also frequent and causes infection enhancement.<sup>3</sup> The organism in this case was *Streptococcus constellatus*, usually a part of oral cavity flora.

Infectious invasion of deep cervical spaces can disseminate through cervical fasciae and give rise to abscesses potentially extending into the mediastinum. The descending necrotizing mediastinitis is rare, but it is one of the most life-threatening forms of mediastinitis. The condition is clinically characterized by toxemic signs and thoracic symptoms, such as dyspnea or thoracic pain in a patient with a cervical infection, with an estimated mortality of 40%.<sup>3,4</sup>

The mediastinitis secondary to a parotid abscess is a rare event. A scientific literature review was conducted (MEDLINE and LILACS) and only one case report of necrotizing mediastinitis secondary to an acute suppurative parotitis was found in a general hospital in Toronto, Canada.<sup>5</sup>

In the current clinical case, the infectious involvement of the deep parotid lobe was likely to extend through the stylo-mandibular tunnel to the parapharyngeal space. From this space, which is confluent with several cervical spaces, the infection reached the carotid sheath and spread inferiorly to the superior mediastinum.

The classical treatment for descending necrotizing mediastinitis is based on wide surgical drainage associated with broad-spectrum antibiotic therapy.

## Final comments

Although parotid abscess is not common, the possibility that this infection can spread into the mediastinum increases the need of early diagnosis and treatment.

## Conflicts of interest

The authors declare no conflicts of interest.

## Referências

1. Ganesh R, Leese T. Parotid abscess in Singapore. *Singapore Med J.* 2005;46:553-6.
2. Krippaehne WW, Hunt TK, Dunphy JE. Acute suppurative parotitis: a study of 161 cases. *Ann Surg.* 1962;156:251-7.
3. Macedo JLS, Netto MX. Tratamento conservador de mediastinite necrotizante descendente. *J Pneumol.* 1998;24:167-70.
4. Estrera AS, Landay MJ, Grisham JM, Sinn DP, Platt MR. Descending necrotizing mediastinitis. *Surg Gynecol Obstet.* 1983;157:545-52.
5. Guardia SN, Cameron R, Phillips A. Fatal necrotizing mediastinitis secondary to acute suppurative parotitis. *J Otolaryngol.* 1991;20:54-6.