

# Emergency Intraoperative Onlay Mesh Repair of Incarcerated Spigelian Hernia

M. S. Subramanya, MBBS, MRCS, J. Chakraborty, MBBS,  
B. Memon, RGN, LLB, PGCEd, M. A. Memon, MBBS, FRACS

## ABSTRACT

**Background and Objectives:** Spigelian hernia is a rare cause of incarcerated ventral abdominal hernia that may pose a diagnostic dilemma. However, with the increasing utilization of double contrast computed tomography (CT) for undiagnosed small bowel obstruction in a virgin abdomen, more such cases are being diagnosed with increasing confidence. Furthermore, with the rapid expansion of the indications for minimal access surgery in emergency situations, these rare emergencies are increasingly tackled using a laparoscopic approach leading to swift patient recovery and discharge.

**Methods:** We present the case of an emergency intraperitoneal onlay mesh (IPOM) repair of Spigelian hernia, causing acute small bowel obstruction in a 55-year-old man with liver disease and ascites that was diagnosed using a CT scan. We conducted a search of Medline, Embase, Science Citation Index, Current Contents, PubMed, and the Cochrane Database to review the history of laparoscopic repair of Spigelian hernia and its various advancements, which are briefly presented here.

**Results:** The hernia was successfully reduced using laparoscopy, revealing a moderate-size defect in the linea semilunaris. The hernial defect was repaired with a composite mesh that was tacked into position. The patient was discharged from the hospital on the second postoperative day.

**Conclusions:** Spigelian hernia in an emergency setting can be easily and swiftly repaired using the IPOM method utilizing a composite mesh.

**Key Words:** Spigelian hernia, Laparoscopic repair, surgical techniques

Department of Surgery, Ipswich Hospital, Ipswich, Queensland, Australia (Subramanya, Chakraborty, Memon); Department of Surgery, University of Queensland, Herston, Queensland, Australia; Bond University, Gold Coast, Queensland, Australia (Memon).

Address correspondence to: M. A. Memon, FRACS, Ipswich Hospital, Chelmsford Avenue, Ipswich, Queensland 4305, Australia. Telephone: +61 7 38101140, Fax: +61 7 38101592, E-mail: mmemon@yahoo.com

DOI: 10.4293/108680810X12785289144683

© 2010 by JSLS, *Journal of the Society of Laparoendoscopic Surgeons*. Published by the Society of Laparoendoscopic Surgeons, Inc.

## INTRODUCTION

With the rapid expansion of the indications for minimal access surgery in emergency situations,<sup>1</sup> Spigelian hernias, which are rare emergencies, are increasingly tackled using a laparoscopic approach leading to swift patient recovery and discharge. Diagnosis of a Spigelian hernia requires a high index of suspicion, because the presenting symptoms are vague and nonspecific, and the patient often lacks clinical signs. Since the first case report of the laparoscopic repair of a Spigelian hernia in 1992 by Carter,<sup>2</sup> repair has evolved immensely with the advent of new techniques and types of mesh. We present the case of an incarcerated Spigelian hernia with small bowel obstruction complicated by liver disease and ascites, which was repaired using a laparoscopic approach and composite mesh.

## CASE REPORT

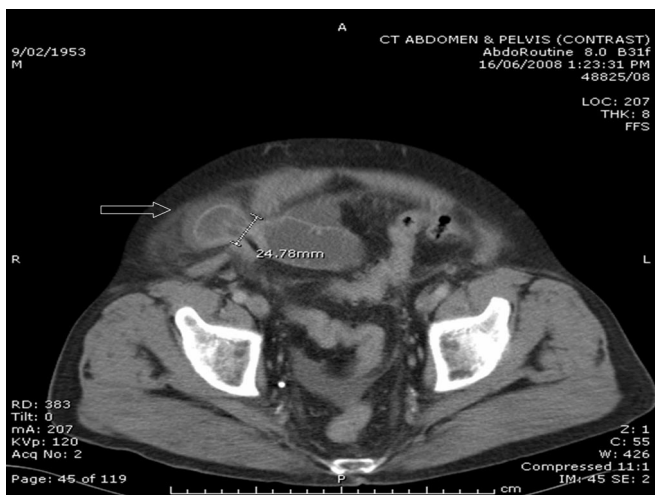
A 55-year-old gentleman presented to the emergency department with a 1-day history of central, constant abdominal pain associated with nausea, vomiting, constipation, and abdominal distension. He had been losing weight gradually for the previous 6 months. He was also being treated for chronic liver failure secondary to alcohol abuse. He had recently undergone an upper gastrointestinal endoscopy and colonoscopy as part of his investigation for anemia and weight loss, which revealed esophageal varices and a cecal polyp. He had no previous abdominal surgery.

On admission, his general physical examination revealed pallor and spider nevi. All his vital parameters however were within normal limits. Abdominal examination revealed a distended but soft abdomen with tenderness in the right lower quadrant of the abdomen and the suprapubic region associated with high-pitched bowel sounds. However, no isolated swelling was felt on his abdomen. He was found to have shifting dullness on abdominal examination suggestive of ascites. Digital rectal examination revealed an empty rectum.

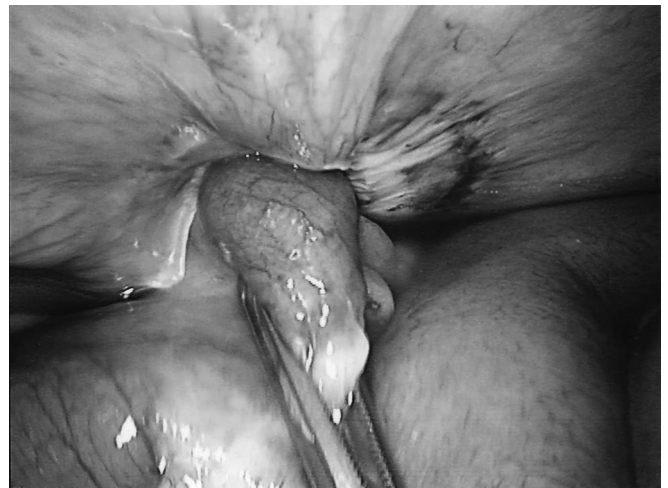Routine blood investigations revealed slightly deranged liver function tests (Bilirubin 5 (<20), ALP 136, (56-119) GGT 134 (<50), AST 30 (<35), and ALT 22 (<45), but his

full blood count, urea, and electrolytes were within normal limits. Urine analysis did not reveal any abnormality either. Plain abdominal films showed dilated loops of small bowel with multiple air fluid levels consistent with small bowel obstruction. He was therefore initially treated conservatively with intravenous fluids and nasogastric aspiration, and an urgent double contrast computerized tomography (CT) was arranged to investigate the cause of this small bowel obstruction in a virgin abdomen. The CT scan of his abdomen revealed a low right incarcerated Spigelian hernia in a typical site containing a loop of small bowel with proximal dilated small bowel and abdominal ascites (**Figure 1**).

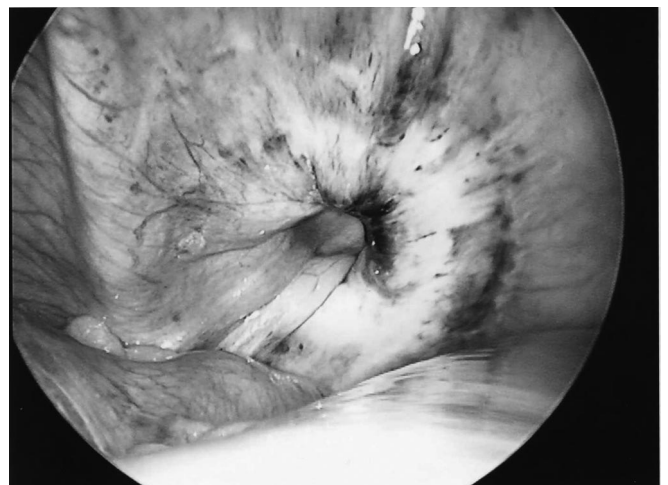
Based on the CT scan results, the patient was transferred to the surgical theater for an urgent diagnostic laparoscopy. This revealed an incarcerated Spigelian hernia in the right iliac fossa over the linea semilunaris, containing a loop of small bowel with grossly dilated loops of bowel upstream and collapsed bowel downstream (**Figure 2**). Furthermore, a reasonable amount of ascitic fluid was also present in the abdominal cavity, which was aspirated. Once the cause of small bowel obstruction was identified, 2 further 5-mm ports were inserted on the left lateral side of the abdomen, and the patient was tilted head down and towards the left on the operating table. The hernia was successfully reduced with gentle traction revealing a moderate defect in the linea semilunaris (**Figure 3**). The incarcerated bowel was viable and pink on reduction. The hernial defect was repaired with an 8-cm Bard Ventralex Hernia Patch (Bard Limited, Crawley, UK), a type of com-



**Figure 1.** Double contrast CT scan of the abdomen showing the Spigelian hernia location (white arrow) with distended small bowel.



**Figure 2.** Laparoscopic view of the fully incarcerated Spigelian hernia containing the loop of small bowel.



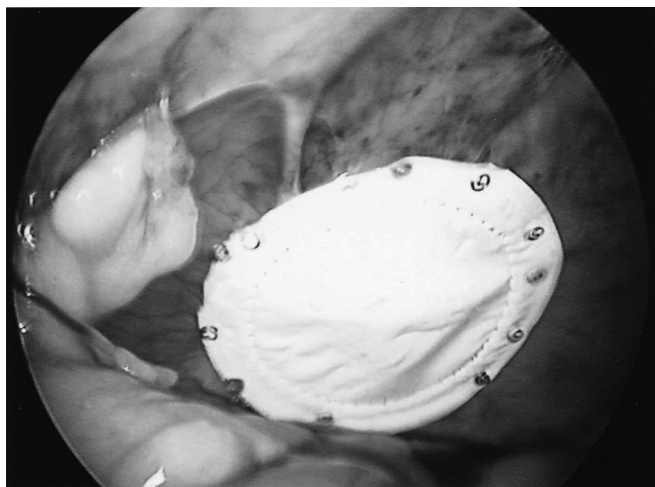**Figure 3.** Laparoscopic view of the Spigelian hernial defect with small bowel completely reduced into the abdominal cavity.

posite mesh, which was tacked in position with the Pro-Tack (Auto Suture, United States Surgical, Norwalk, CT, USA) (**Figure 4**). This entire procedure took around 40 minutes.

The patient made a good recovery from the operation and started eating and drinking the very next day. He was discharged from the hospital on the second postoperative day and was seen 6 months and a year following his surgery with no recurrence of his hernia.

## DISCUSSION

Spigelian hernia is a rare condition that requires a high degree of suspicion to diagnose because of the overlying



**Figure 4.** IPOM repair of the Spigelian hernia defect using Bard Ventraliex Hernia Patch secured with Protack.

intact external oblique and vague presenting symptoms. It accounts for 2% of all the emergency surgeries with a high incarceration and strangulation rate.<sup>3</sup> In the largest series of 81 repairs in 79 patients reported from the Mayo Clinic, the incarceration rate was as high as 17%.<sup>3</sup> In yet another large study of 28 patients, 33% of the patients who presented as emergencies had incarceration.<sup>4</sup>

Named after a Belgian anatomist Adriaan Van Den Spieghel, it was first described by Henri Francois Le Dran in 1742. Until 1992, the main stay of repair for Spigelian hernias was open mesh repair, when for the first time it was repaired laparoscopically.<sup>2</sup> Since then, various laparoscopic suture or mesh repairs utilizing a range of techniques like transabdominal preperitoneal repair (TAPP),<sup>5</sup> totally extraperitoneal repair (TEP),<sup>6</sup> and scroll technique<sup>7</sup> have been described. A variety of meshes have also been used, such as polypropylene,<sup>8</sup> polytetrafluoroethylene (PTFE),<sup>9</sup> and composite.<sup>10</sup> Many surgeons nowadays prefer composite mesh because it has a lesser propensity to cause adhesions and obstructions, unlike polypropylene. In our case, we utilized the intraperitoneal onlay mesh (IPOM) method using a composite mesh with PTFE on the exposed side and polypropylene on the abdominal wall side.

The laparoscopic method has the advantage of less physiological insult, because it avoids a large abdominal incision. Furthermore, it accurately and quickly localizes the obstruction site, which sometimes is a challenge in an open repair of this type of hernia, especially in an obese individual. Also according to the literature, laparoscopic repair has lower recurrence rates, is associated with a

quicker recovery, and has a shorter hospital stay compared with open techniques. This is true even in the elderly patients undergoing laparoscopic repair of Spigelian hernias.<sup>11</sup> In the only prospective study comparing the open versus laparoscopic repair of Spigelian hernia in 22 patients, the laparoscopic group compared with the open group had significantly lower morbidity (4 vs 0,  $P < 0.05$ ) and hospital stay (median of 5.2 vs 1.4 days,  $P < 0.001$ ).<sup>12</sup> TEP has been the method of choice in elective cases, whereas TAPP has been the preferred method in emergency settings, mainly because of small bowel incarceration and distension in emergency presentation.<sup>12</sup> In our case, we elected to use IPOM repair with the composite mesh.

The initial diagnostic laparoscopy allowed us not only to quickly locate the site of hernia but also to reduce and examine the incarcerated bowel before proceeding to repair the defect. Unlike other cases, which have been previously reported, our patient not only had gross abdominal distension secondary to small bowel obstruction, but also had associated ascites, making the repair challenging. However, once the hernia was reduced, the repair was extremely straightforward and quick.

## CONCLUSION

We feel that Spigelian hernias, in an emergency setting, can be easily and swiftly repaired using the IPOM method with a composite mesh. This leads to a speedy recovery and earlier hospital discharge.

## References:

1. Memon MA, Fitzgibbons RJ Jr. The role of minimal access surgery in the acute abdomen. *Surg Clin North Am.* 1997;77:1333-1353.
2. Carter JE, Mizes C. Laparoscopic diagnosis and repair of spigelian hernia: report of a case and technique. *Am J Obstet Gynecol.* 1992;167:77-78.
3. Larson DW, Farley DR. Spigelian hernias: repair and outcome for 81 patients. *World J Surg.* 2002;26:1277-1281.
4. Moreno-Egea A, Flores B, Girela E, Martín JG, Aguayo JL, Canteras M. Spigelian hernia: bibliographical study and presentation of a series of 28 patients. *Hernia.* 2002;6:167-170.
5. Saber AA, Elgamal MH, Rao AJ, Osmer RL, Itawi EA. Laparoscopic spigelian hernia repair: the scroll technique. *Am Surg.* 2008;74:108-112.
6. Moreno-Egea A, Aguayo JL, Girela E. Treatment of spigelian hernia using totally extraperitoneal laparoscopy ambulatory surgery. *Surg Endosc.* 2002;16:1806-1810.

7. Palanivelu C, Vijaykumar M, Jani KV, Rajan PS, Maheshkumaar GS, Rajapandian S. Laparoscopic transabdominal preperitoneal repair of spigelian hernia. *JLS*. 2006;10:193-198.
8. Tarnoff M, Rosen M, Brody F. Planned totally extraperitoneal laparoscopic spigelian hernia repair. *Surg Endosc*. 2002;16:359.
9. Appeltans BM, Zeebregts CJ, Cate Hoedemaker HO. Laparoscopic repair of a Spigelian hernia using an expanded polytetrafluoroethylene (ePTFE) mesh. *Surg Endosc*. 2000;14:1189.
10. Barie PS, Thompson WA, Mack CA. Planned laparoscopic repair of a spigelian hernia using a composite prosthesis. *J Laparoendosc Surg*. 1994;4:359-363.
11. Novell F, Sanchez G, Sentis J, Visa J, Novell J, Novell C. Laparoscopic management of spigelian hernia. *Surg Endosc*. 2000;14:1189.
12. Moreno-Egea A, Carrasco L, Girela E, Martín JG, Aguayo JL, Canteras M. Open vs laparoscopic repair of spigelian hernia: a prospective randomized trial. *Arch Surg*. 2002;137:1266-1268.