



Research article

Transcranial brain parenchyma sonographic findings in patients with myotonic dystrophy type 1 and 2

Milija Mijajlovic^{a,1}, Ivo Bozovic^{b,1}, Aleksandra Pavlovic^{a,c},
 Vidosava Rakocevic-Stojanovic^a, Sanja Gluscevic^d, Amalija Stojanovic^e,
 Ivana Basta^a, Giovanni Meola^{f,g}, Stojan Peric^{a,*}

^a Neurology Clinic, University Clinical Center of Serbia, Faculty of Medicine, University of Belgrade, Belgrade, Serbia

^b Neurology Clinic, University Clinical Center of Serbia, Belgrade, Serbia

^c Faculty of Special Education and Rehabilitation, University of Belgrade, Belgrade, Serbia

^d Neurology Clinic, Clinical Center of Montenegro, Podgorica, Montenegro

^e Faculty of Medicine, University of Belgrade, Belgrade, Serbia

^f Department of Biomedical Sciences for Health, University of Milan, Milan, Italy

^g Department of Neurorehabilitation Sciences, Casa Di Cura del Policlinico, Milan, Italy

ARTICLE INFO

Keywords:

Myotonic dystrophy type 1
 Myotonic dystrophy type 2
 Transcranial sonography
 Substantia nigra
 Nucleus raphe

ABSTRACT

Introduction: Myotonic dystrophy type 1 (DM1) and 2 (DM2) are genetically determined progressive muscular disorders with multisystemic affection, including brain involvement. Transcranial sonography (TCS) is a reliable diagnostic tool for the investigation of deep brain structures. We sought to evaluate TCS findings in genetically confirmed DM1 and DM2 patients, and further correlate these results with patients' clinical features.

Methods: This cross-sectional study included 163 patients (102 DM1, 61 DM2). Echogenicity of the brainstem raphe (BR) and substantia nigra (SN) as well as the diameter of the third ventricle (DTV) were assessed by TCS. Patients were evaluated using the Hamilton Depression Rating Scale, Fatigue Severity Scale and Daytime Sleepiness Scale.

Results: SN hyperechogenicity was observed in 40% of DM1 and 34% of DM2 patients. SN hypoechogenicity was detected in 17% of DM1 and 7% of DM2 patients. BR hypoechogenicity was found in 36% of DM1 and 47% of DM2 subjects. Enlarged DTV was noted in 19% of DM1 and 15% of DM2 patients. Older, weaker, depressive, and fatigued DM1 patients were more likely to have BR hypoechogenicity ($p < 0.05$). DTV correlated with age and disease duration in DM1 ($p < 0.01$). In DM2 patients SN hyperechogenicity correlated with fatigue. Excessive daytime sleepiness was associated with hypoechogenic BR ($p < 0.05$) and enlarged DTV ($p < 0.01$) in DM2 patients.

Conclusions: TCS is an easy applicable and sensitive neuroimaging technique that could offer new information regarding several brainstem structures in DM1 and DM2. This may lead to better understanding of the pathogenesis of the brain involvement in DM with possible clinical implications.

* Corresponding author. Neurology Clinic, University Clinical Center of Serbia 6, Dr. Subotic Street 11 000, Belgrade, Serbia.

E-mail address: stojanperic@gmail.com (S. Peric).

¹ These two authors equally contributed to the paper.

1. Introduction

Myotonic dystrophies (DM) are autosomal dominant, progressive muscular disorders with diverse clinical presentations. Based on their clinical and molecular features, two DM subtypes are myotonic dystrophy type 1 (DM1) and a generally milder form named myotonic dystrophy type 2 (DM2) [1]. Besides the predominant muscle affection, both types of DM have various multisystemic involvements, including the central nervous system affection [2]. Indeed, neuropsychological dysfunction has been described as a consistent part of the DM phenotype, with impairment severity ranging from subtle cognitive decline to severe intellectual disability [3,4]. Further confirmations of these findings were obtained after a *postmortem* histopathological analysis of DM brain samples, where neurofibrillary tangles without amyloid plaque occurrence were observed in different areas of the cerebral hemispheres [5–7]. Indeed, several histopathology analyses of *postmortem* DM1 brain samples have already proven the presence of different neurofibrillary tangles (NFTs), RNA foci and *Marinesco* bodies in substantia nigra (SN), and the loss of serotonergic neurons in the brainstem raphe (BR), leading to both neuronal and glial alterations [8,9]. On the other hand, limited histopathological data about DM2 have shown the presence of NFTs and neuropil threads in the hippocampi, entorhinal, prefrontal areas, and upper cervical cord while ubiquitin positive *Marinesco* bodies have been found in SN [3]. Various neuroradiological techniques were used to-date in order to investigate different morphological and functional brain changes in patients with DM [1]. Several magnetic resonance (MR) imaging brain studies have revealed both white and gray matter involvement in these patients [10–16], while positron emission tomography (PET) studies demonstrated the presence of frontal and/or temporal hypometabolism, all consistent with the observed cognitive and behavioral dysfunction in these patients [17].

Transcranial sonography (TCS) is an ultrasound-based technique used for non-invasive visualization of deep brain structures such as basal ganglia and substantia nigra (SN), the structures with a proven pathophysiological and diagnostic role in different neurodegenerative and psychiatric diseases [18]. More importantly, these brain regions can be less precisely evaluated with other neuroradiological techniques, such as MR and PET imaging, when compared to TCS [8,18,19]. As extrapyramidal symptomatology and cognitive impairment occasionally comprise the clinical spectrum of DM [20–24], a precise evaluation of these brain structures might be crucial in these patients. In to-date literature, only several smaller studies (including two from Serbia) have separately analyzed different TCS characteristics in both DM1 and DM2 patients. Our previous research of different TCS characteristics in DM patients was conducted on significantly smaller cohorts, including 66 DM1 and 38 DM2 patients [8,9].

Thus, our aim was to characterize and compare different TCS changes and their clinical relevance between two large cohorts of genetically confirmed DM1 and DM2 patients.

2. Material and methods

This was a retrospective cross-sectional study which comprised 102 genetically confirmed DM1 and 62 DM2 adult patients, admitted to the Inpatient Unit or Day Hospital of the Neurology Clinic, University Clinical Center of Serbia, from 2010 to 2018. This study was approved by the local Ethics Committee of the Neurology Clinic and conducted in accordance with the Declaration of Helsinki. Informed consent was obtained from all patients before blood sampling, ultrasonography examination and testing patients with different scales used in the research.

Using triplet repeat primed polymerase chain reaction (TR-PCR) we genetically confirmed the diagnosis in all tested patients. Main sociodemographic, clinical, and diagnostic data were collected from patients' medical records. The sole exclusion criterion was a nontransparent ultrasound bone window. Only six patients, out of the initial number of 169 DM patients, met this exclusion criteria and were not included in the study, making the final number of 163 analyzed patients. Severity of DM1 was assessed using the Muscular Impairment Rating Scale (MIRS) [25]. Severity of both DM1 and DM2 was analyzed by Medical Research Council Sum Score (MRC-SS) like in our previous paper [26].

Transcranial sonography was performed through the pre-auricular temporal bone window in all DM patients, using a color-coded ultrasound system with a 2.5 MHz transcranial phased-array transducer (Aloka Prosound Alpha 10, Aloka, Japan). The examination was conducted in concordance with the current guidelines (including a 16-cm insonation depth and a dynamic range of 50–55 Db), and evaluated by an independent TCS expert, agnostic to patients' clinical data [19]. Individualized image contrast and brightness corrections were applied to obtain the best image quality in B-mode. Echogenicity of the BR, SN, and the diameter of the third ventricle (DTV) were assessed by TCS [8]. The echogenicity of BR was evaluated using a two-level grading system, where grade 0 represented a hypoechogenic, discontinuous/interrupted or missing BR, while grade 1 defined a typical, highly echogenic, and continuous BR (in physiological conditions, the echogenicity of BR corresponds to the echogenicity of the surrounding basal cisterns or red nucleus) [19]. Using an axial TCS, SN hyperechogenic region was assessed, manually encircled (respecting the outer SN borders) and evaluated using the current numeric criteria for our ultrasound laboratory and ultrasound system applied (values with size below 0.19 cm² were interpreted as normal echogenicity, while values greater than 0.19 cm² were defined as hyperechogenic [27]. In accordance with the previous data, SN hypoechogenicity was defined as the summation of bilateral SN echogenic sizes below 1 standard deviation of the mean for the general population (<0.21 cm²) [25]. The DTV was concluded as normal if the minimum transverse diameter on axial TCS scan was below 7 mm [28].

The Daytime Sleepiness Scale (DSS) was used to evaluate the presence of excessive daytime sleepiness (defined as score above 7) in all DM patients [29]. The Hamilton Rating Scale for Depression (Ham-D) was applied to all our patients to evaluate symptoms of depression, where a score equal to or above 15 was consistent with depression [30]. Krupp's Fatigue Severity Scale (FSS) was used to evaluate the burden of fatigue. A score equal to or above 36 was interpreted as significant fatigue [31].

2.1. Statistical analysis

The data were analyzed using both parametric and non-parametric statistical methods. To determine the statistical significance between the observed variations, the Pearson's χ^2 -test and Fisher's test were applied for non-continuous variables. Mann-Whitney *U* test and Student's *t*-test were used to analyze the differences of continuous variables. Pearson's coefficient was applied to determine correlation between different parameters. The values of *p* below 0.05 were considered statistically significant. The IBM Statistical Package for Social Sciences, version 20 (IBM SPSS, Chicago, IL, USA), was used for statistical analyses. The results are graphically presented in Tables and as a Figure.

3. Results

3.1. Main sociodemographic and clinical features of DM patients

Main sociodemographic data of DM1 and DM2 patients are listed in Table 1. The study was conducted on 102 patients with DM1, with the mean age of 40.1 ± 10.7 years, and 61 DM2 patients with the mean age of 51.9 ± 10.6 years at testing. When different sociodemographic data between DM1 and DM2 patients were compared, DM2 patients were older and with a higher female prevalence. In addition, the disease onset was at a later age in DM2 patients compared to DM1 patients ($p < 0.01$), while the disease duration was longer in DM1 patients ($p < 0.05$).

Depression was present in up to 15% of DM1 patients, while the FSS scale revealed significant fatigue in almost half of them (Table 1). Excessive daytime sleepiness (EDS) was noted in over 45% of our DM1 patients. On the other hand, depression was present in only 4% of DM2 patients. Significant fatigue was present in over 50%, while EDS was recorded in more than a fifth of DM2 patients. When comparing all neuropsychiatric characteristics of both cohorts, it was noted that EDS occurred more often in patients with DM1.

3.2. Main TCS findings in DM patients

The main results of TCS examination in DM patients are shown in Table 2. SN hyperechogenicity was observed in 40 (39.6%) DM1 patients, while hypoechogenicity was noted in only 17 (16.8%) patients. The mean right SN echogenic area was 0.14 ± 0.06 cm², and it was 0.15 ± 0.06 cm² on the left. In patients with DM2, SN hyperechogenicity was observed in 21 (34.4%) patients, whereas SN hypoechogenicity was registered in only 4 (6.6%) subjects. The mean right SN echogenic area was 0.16 ± 0.07 cm² and the left was 0.16 ± 0.06 cm². No differences were recorded when comparing DM1 and DM2 patients ($p > 0.05$).

Frequency of pathological BR echogenicity (grade 0) was similar in both patient groups (35.6% in DM1 vs. 47.5% in DM2, $p > 0.05$). The average DVT was 6.1 ± 1.7 mm in DM1 patients, and in almost one fifth of them it was greater than 7 mm. The mean DVT noted in DM2 patients was 5.7 ± 1.7 mm, and it was greater than 7 mm in 15% of patients. Enlarged DVT appeared in similar frequency in both types of DM ($p > 0.05$).

Examples of hypoechogenicity of substantia nigra and missing brainstem raphe (Fig. 1-A) and hyperechogenicity of substantia nigra and normal brainstem raphe (Fig. 1-B) of our patients are combinedly presented in Fig. 1.

Table 1
Main sociodemographic and clinical characteristics of DM1 and DM2 patients.

Features	DM1 (n = 102)	DM2 (n = 61)
Male patients (n (%))	59 (57.8) ^a	17 (27.9) ^a
Age (mean \pm SD, years)	40.1 ± 10.7^a	51.9 ± 10.6^a
Age at onset (mean \pm SD, years)	23.3 ± 10.9^a	39.5 ± 12.1^a
Disease duration (mean \pm SD, years)	$16.9 \pm 9.3^{**}$	$12.6 \pm 12.1^{**}$
MIRS (n (%))	2 (2.0)	–
0	14 (14.7)	
1	25 (24.5)	
2	52 (51.0)	
3	8 (7.8)	
4		
MRC-SS	16.7 ± 2.3^a	18.0 ± 2.1^a
Ham-D score (mean \pm SD)	11.4 ± 9.3	9.0 ± 5.9
Depression (n (%))	9 (14.8)	2 (4.4)
FSS score (mean \pm SD)	35.4 ± 14.8	37.0 ± 16.4
Severe fatigue (n (%))	39 (51.3)	20 (47.6)
DSS score (mean \pm SD)	$6.8 \pm 4.3^{***}$	$5.4 \pm 2.6^{***}$
Excessive daytime sleepiness (n (%))	33 (45.2) ^{**}	10 (23.8) ^{**}

DM1 – myotonic dystrophy type 1, DM2 – myotonic dystrophy type 2, MIRS – Muscular Impairment Rating Scale, MRC-SS – Medical Research Council sum-score, FSS – Fatigue Severity Scale, Ham-D – Hamilton Rating Scale for Depression, DSS – Daytime Sleepiness Scale.

^a $p < 0.01$, ^{**} $p < 0.05$, ^{***} $p = 0.05$.

Table 2

Transcranial sonography (TSC) findings in patients with DM1 and DM2 (none result reached statistical significance).

TCS findings	DM1 (n = 102)	DM2 (n = 61)
SN right (mean ± SD, cm ²)	0.14 ± 0.06	0.16 ± 0.07
SN left (mean ± SD, cm ²)	0.15 ± 0.06	0.14 ± 0.06
SN hypoechogenicity (n (%))	17 (16.8)	4 (6.6)
SN normal (n (%))	44 (43.6)	36 (59.0)
SN hyperechogenicity (n (%))	40 (39.6)	21 (34.4)
BR disruption (n (%))	36 (35.6)	29 (47.5)
BR right (n (%))	14 (14.1)	7 (11.5)
BR left (n (%))	12 (12.1)	6 (9.8)
DTV (mean ± SD, mm)	6.1 ± 1.7	5.7 ± 1.7
DTV >7 mm (n (%))	19 (18.6)	9 (15.3)

BR - brainstem raphe, DM1-myotonic dystrophy type 1, DM2 - myotonic dystrophy type 2, DTV - diameter of the third ventricle, NL - nucleus lentiformis, SN - substantia nigra.

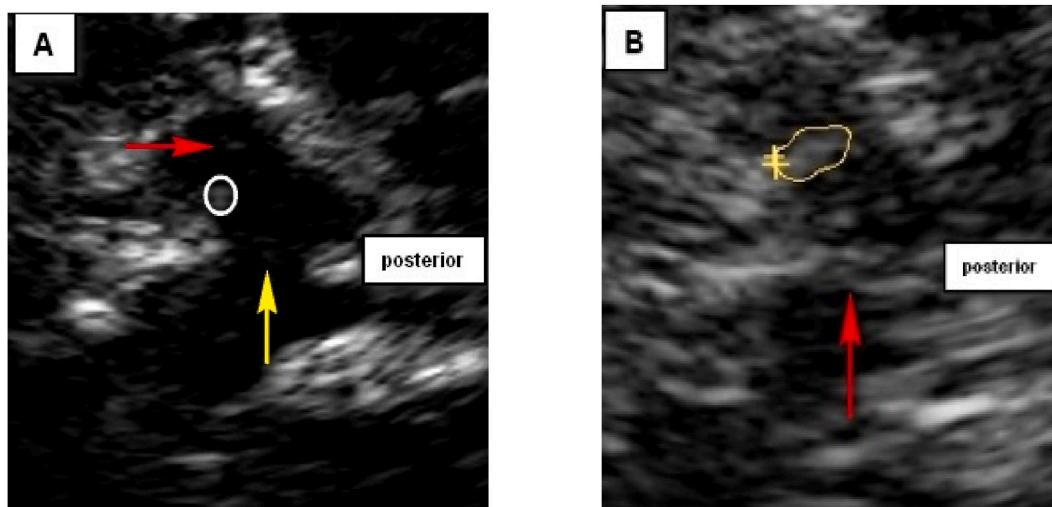


Fig. 1. Examples of different echogenicity of substantia nigra and brainstem raphe in our DM patients

A. Hypoechogenic “butterfly” shaped mesencephalic brainstem showing hypoechogenic substantia nigra (red arrow) and missing brainstem raphe line-grade 0 (yellow arrow); red nucleus is encircled.

B. Outer circumference of the hyperechogenic substantia nigra is encircled; normal echogenicity of the brainstem raphe-grade 1 depicted as hyperechogenic continuous line (red arrow) (same echogenicity as the basal cisterns that surround hypoechogenic “butterfly” shaped mesencephalic brainstem). (For interpretation of the references to color in this figure legend, the reader is referred to the Web version of this article.)

Table 3

The association between different brain transcranial echosonography findings and sociodemographic/clinical data in DM1 patients^a.

Sociodemographic/clinical features	BR hypoechogenicity	Normal BR echogenicity
Age (n (%))	36 (35.3)	66 (64.7)
MRC-SS (mean ± SD)	16.1 ± 2.5	17.0 ± 2.1
Ham-D score (mean ± SD)	14.9 ± 12.5	9.2 ± 5.5
FSS score (mean ± SD)	40.0 ± 14.3	33.0 ± 14.6
Sociodemographic/clinical features	Increased DVT	Normal DVT
Age (n (%))	19 (18.6)	83 (81.4)
Age in DVT subgroups (mean ± SD, years)	45.9 ± 10.4	38.8 ± 10.4
Disease duration (mean ± SD, years)	20.7 ± 8.4	16.0 ± 9.4
Sociodemographic/clinical features	SN hyperechogenicity	Normal SN echogenicity
Age (n (%))	40 (39.6)	44 (43.6)

BR - brainstem raphe, DM1 - myotonic dystrophy type 1, DSS - Daytime Sleepiness Scale, DTV - diameter of the third ventricle, FSS - Fatigue Severity Scale, Ham-D - Hamilton Rating Scale for Depression, MRC-SS - Medical Research Council sum-score, SN - substantia nigra.

^a Only statistically significant data is shown in the table.

3.3. Correlation of the TCS findings with different sociodemographic and neuropsychiatric features in DM patients

DM1 patients with pathological BR echogenicity (grade 0 on TCS) were older (42.6 ± 10.6 vs. 38.2 ± 10.1 years, $p < 0.05$) and had more severe muscle weakness as measure with MRC-SS (16.1 ± 2.5 vs. 17.0 ± 2.1 , $p < 0.05$). BR grade 0 was more common in depressed vs. non-depressed DM1 patients (77.8% vs. 32.7%, $p < 0.05$). Also, patients with pathologic echogenicity of BR had higher Ham-D score (14.9 ± 12.5 vs. 9.2 ± 5.5 , $p < 0.05$). FSS score was borderline higher in patients with BR pathological echogenicity (40.0 ± 14.3 vs. 33.0 ± 14.6 , $p = 0.05$). Patients with increased DVT were older (45.9 ± 10.4 vs. 38.8 ± 10.4 years, $p < 0.01$) and they had longer disease duration (20.7 ± 8.4 vs. 16.0 ± 9.4 years, $p < 0.05$). No statistically significant associations were observed between other TCS findings and additional sociodemographic (including patients' age) and neuropsychiatric features of DM1 patients.

SN hyperechogenicity was more common in DM2 patients with fatigue (60.0% vs. 18.8%, $p < 0.05$). DM2 patients with EDS more often had pathologic echogenicity of BR (80.0% vs. 43.8%, $p < 0.05$). Also, DSS was higher in patients with hypoechogenic (grade 0) BR (6.1 ± 2.8 vs. 4.5 ± 2.1 , $p < 0.05$). Pathologically increased DTV was more common in DM2 patients with EDS (40.0% vs. 3.1%, $p < 0.01$). DSS was higher in patients with enlarged third ventricle (7.6 ± 3.2 vs. 5.2 ± 2.31 , $p < 0.05$). Statistically meaningful associations between different brain transcranial echosonography findings and sociodemographic/clinical data in DM1 and DM2 patients are summarized in Tables 3 and 4. No other statistically significant relationships were found between TCS findings and additional sociodemographic (including patients' age) and neuropsychiatric features among DM2 patients.

4. Discussion

To the best of our knowledge, this is the first study where TCS data were assessed and directly compared between two large cohorts of DM1 and DM2 patients.

An increased frequency of SN hyperechogenicity was noted in 40% of our DM1 patients, which was in accordance with the data from both German and previous Serbian cohorts which all pointed out a significant presence of SN hyperechogenicity in these patients [9,28]. Similarly, SN hyperechogenicity was found in about one third of our DM2 patients, which is also in accordance with previous literature data [8,28]. Moreover, TCS findings of SN hyperechogenicity were more common in both our cohorts compared to the data from the general population, where SN hyperechogenicity can be observed in around 10% of healthy individuals [8,24]. While interpreting these data, one must have in mind the fact that the frequency of SN hyperechogenicity increases with age even in healthy adults [32]. Potential pathophysiological mechanisms behind the SN hyperechogenicity occurrence in healthy adults need further clarifications, but it could be an ultrasonographic reflection of the presence of iron accumulation and/or a subclinical dopaminergic system dysfunction. However, these findings did not correlate with patients' age in our study.

On the other hand, it is already known that SN hyperechogenicity on TCS is a characteristic of neurodegenerative disorders such as Parkinson's disease (PD) and other types of parkinsonism and is interpreted to be probably caused by increased iron deposition in specific brain regions [33,34]. Indeed, a more recent MR study of Ates et al. showed the presence of significant iron accumulation in the putamen and *nucleus accumbens* in both DM1 and DM2 patients, with the accumulation being more diffuse in DM1 patients including the SN [35]. It might be speculated that different types of autopsy-confirmed brain accumulations already described in patients with myotonic dystrophies, could lead to impaired iron metabolism. Nevertheless, these data are consistent with our findings where SN hyperechogenicity was noted in at least one third of both DM cohorts. From a clinical perspective, not only can SN hyperechogenicity be detected in about 90% of PD patients, but several motor and non-motor prodromal PD signs have also been noted in healthy individuals with SN hyperechogenicity [8]. On the other hand, as previously reported, cardinal parkinsonism signs (such as tremor and bradykinesia) were found in our DM2 subjects but none of them fulfilled the criteria of PD or other established forms of parkinsonism [8]. However, no extrapyramidal symptom was found to correlate with SN hyperechogenicity in this study.

Another interesting finding is the presence of SN hypoechogenicity in 17% of our DM1 patients, which is somehow higher compared to general population data (around 10%). Although these data are similar to our previous reports on SN hypoechogenicity in DM1 patients [9], the previous sample size was significantly smaller. Additionally, compared to other neurodegenerative disorders, SN hypoechogenicity was traditionally reported in patients with restless leg syndrome (RLS) [36,37], and this finding was explained by the presence of regional brain iron deficiency [9,38,39]. Clinically speaking, RLS symptoms were rarely noted in our cohort of DM1

Table 4

The association between different brain transcranial echosonography findings and sociodemographic/clinical data in DM2 patients^a.

Sociodemographic/clinical features	BR hypoechogenicity	Normal BR echogenicity
Age (n (%))	29 (47.5)	32 (52.5)
DSS (mean \pm SD)	6.1 ± 2.8	4.5 ± 2.1
Sociodemographic/clinical features	Increased DVT	Normal DVT
Age (n (%))	9 (14.7)	52 (85.3)
EDS (%)	40.0	3.1
DSS (mean \pm SD)	7.6 ± 3.2	5.2 ± 2.3
Sociodemographic/clinical features	SN hyperechogenicity	Normal SN echogenicity
Age (n (%))	21 (34.4)	36 (59.0)

BR - brainstem raphe, DM2 - myotonic dystrophy type 2, DSS - Daytime Sleepiness Scale, DTV - diameter of the third ventricle, EDS - excessive daytime sleepiness, SN - substantia nigra.

^a Only statistically significant data is shown in the table.

patients, but further evaluations are needed. Still, as recently underlined by Beliveau et al. contradictory findings about iron deficiency exclusively in SN in RLS patients could be found across current literature data. According to their meta-analysis, there is still no clear evidence for decreased iron content in SN in patients with RLS [40]. Thus, there is still no clear explanation of the observed SN hypoechogenicity in RLS, or in DM1 patients, and this finding could not be solely explained by iron deficiency, so further studies are urgently needed to clarify these interesting findings. Finally, we have found no statistically significant association between any type of SN echogenicity and patients' age.

We have identified pathological BR echogenicity (grade 0) to be a frequent finding in both cohorts of DM patients (36% in DM1 and 48% in DM2). Our findings are in accordance with previous Serbian data where BR hypoechogenicity/discontinuation was observed in both DM1 and DM2 patients [17,24], but also with German data, where pathological BR echogenicity was observed in almost half of DM1 patients [28]. Although still speculative, several studies have reported a correlation between this TCS finding and different brain MR signal alterations in patients with depression, suggesting that BR pathological echogenicity (grade 0) might represent a structural serotonergic fiber tract disruption of the dorsal nucleus raphe [41–45]. Moreover, previous histopathology analyses of postmortem brain tissue of DM1 patients have underlined the loss of serotonergic neurons in the BR [8,9], typically coexisting with different neurofibrillary accumulations and neuronal and glial alterations. Granting all this, in the current study we showed that BR hypoechogenicity was more frequently observed in depressed DM1 patients. It is of note that symptoms of depression are more common in elderly, with its prevalence rising with age [46]. In addition, BR hypoechogenicity was more commonly observed in our older DM1 patients with more pronounced muscle weakness. These findings may justify serotonin reuptake inhibitors treatment (SSRI) in these patients. It is reasonable to consider that TCS examination could be an adjuvant diagnostic method in supporting the diagnosis of depression or susceptibility to depression in these patients. Besides, TCS may even serve as a biomarker of antidepressant treatment response (particularly with SSRI). Finally, BR pathological echogenicity was also more frequently noted in fatigued DM1 patients. While the presence of significant fatigue might be a result of CNS dysfunction (especially the cortical projections of the brainstem reticular activating system), the influence of comorbid depression in these patients should not be underestimated [9,16].

Our findings showed that SN hyperechogenicity was more common in DM2 patients with fatigue. It seems that fatigue is quite prevalent in neurological disorders and is often characterized with a significantly reduced energy level or an increased perception of effort disproportionate to attempted activities [47]. It is well known that fatigue is one of the main disabling non-motor symptoms of PD, where the nigrostriatal dopaminergic neuron degeneration in the SN is a core histopathological feature. Moreover, it is suggested that main pathophysiological mechanisms of fatigue in neurodegenerative diseases include abnormal frontal loops (between basal ganglia and cortex), and an imbalance between different neurotransmitters (e.g., dopamine and serotonin) [48]. Since DM2 and PD share different clinical and even pathophysiological features, it might be speculated that fatigue might be the result of similar intracerebral dysfunctions in patients with DM2, but further investigations are still needed.

Several previous studies have suggested the association between BR hypoechogenicity and excessive daytime sleepiness in neuropsychiatric disorders, where dysfunction of the central serotonergic system in BR might modulate the pathophysiological processes of hypersomnia [8,49,50]. It is already known that EDS is not an unusual non-muscular symptom in patients with DM [51,52]. In the current study, EDS was more frequently present in DM2 patients with pathologic BR echogenicity clearly supporting previous data and underlining sleep disturbances as prominent features in DM2 patients [8,28].

Pathological enlargement of DTV was observed in the older DM1 patient group and was found to correlate with longer disease duration. It may be assumed that the increase in DTV is at least partially the result of a slowly progressive pathological brain atrophy specific for DM1, combined with the normal process of brain aging [9,53]. An even more interesting finding was the correlation between pathologically enlarged DTV and EDS in DM2, indicating that a wider affection of neural networks involved in the pathophysiology of hypersomnia might be present in DM patients. However, future imaging and histopathology studies are necessary to support this hypothesis.

5. Limitations

The main limitations of this research are its cross-sectional design, the lack of a longitudinal approach and a comparable healthy control (HC) group. On the other hand, this study might be seen as a continuation of our previous publications about TCS findings in DM [8,9], where individual comparisons of both DM1 and DM2 vs. HC were made. However, to the best of our knowledge, this is the first study in which TCS findings were directly compared in two large groups of DM1 and DM2 patients.

6. Conclusions

SN hyperechogenicity was commonly found in both DM1 and DM2 patients. BR hypoechogenicity/discontinuation was frequently found in both cohorts. Older, depressive and DM1 patients with significant fatigue were more likely to have pathological BR echogenicity. EDS in DM2 patients correlated with hypoechogenic BR (grade 0), hyperechogenic SN and enlarged DTV. TCS seems to be an easily applicable and sensitive neuroimaging technique that offers additional information regarding particular brainstem structures in DM patients. This may lead to better understanding of the pathogenesis of the brain involvement in DM with possible future therapeutic implications.

Ethics approval and consent to participate

This research was approved by the Ethical Board of the Neurology Clinic, University Clinical Center of Serbia.

Consent for publication

Each author has read and approved the final manuscript version for submission.

Data availability statements

The data that support the findings of this study are available on request from the corresponding author. The data are not publicly available due to privacy or ethical restrictions.

Funding

This study was supported by the Ministry of Education and Science of the Republic of Serbia (Fundings No. 200110 and 175083).

Additional information

No additional information is available for this paper.

CRediT authorship contribution statement

Milija Mijajlovic: Writing – review & editing, Supervision, Investigation, Formal analysis, Data curation, Conceptualization. **Ivo Bozovic:** Writing – original draft, Investigation, Formal analysis, Data curation. **Aleksandra Pavlovic:** Investigation, Data curation. **Vidosava Rakocevic-Stojanovic:** Investigation, Data curation. **Sanja Glucevic:** Writing – original draft, Formal analysis. **Amalija Stojanovic:** Writing – original draft, Investigation, Formal analysis, Data curation. **Ivana Basta:** Writing – review & editing. **Giovanni Meola:** Writing – review & editing, Supervision. **Stojan Peric:** Writing – review & editing, Supervision, Formal analysis, Conceptualization.

Declaration of competing interest

The authors declare the following financial interests/personal relationships which may be considered as potential competing interests: Milija Mijajlovic reports a relationship with Heliyon that includes: board membership.

References

- [1] M. Minnerop, C. Gliem, C. Kornblum, Current progress in CNS imaging of myotonic dystrophy, *Front. Neurol.* 9 (2018) 646.
- [2] D.T. Franc, R.L. Muetzel, P.R. Robinson, C.P. Rodriguez, J.C. Dalton, C.E. Naughton, et al., Cerebral and muscle MRI abnormalities in myotonic dystrophy, *Neuromuscul. Disord.: NMD.* 22 (6) (2012) 483–491.
- [3] S. Peric, V. Rakocevic-Stojanovic, G. Meola, Cerebral involvement and related aspects in myotonic dystrophy type 2, *Neuromuscul. Disord.* 31 (8) (2021 Aug) 681–694, <https://doi.org/10.1016/j.nmd.2021.06.002>. Epub 2021 Jun 9. PMID: 34244019.
- [4] S. Peric, V. Rakocevic-Stojanovic, G. Mandic Stojmenovic, V. Ilic, M. Kovacevic, A. Parojcic, J. Pesovic, M. Mijajlovic, D. Savic-Pavicevic, G. Meola, Clusters of cognitive impairment among different phenotypes of myotonic dystrophy type 1 and type 2, *Neurol. Sci.* 38 (3) (2017 Mar) 415–423.
- [5] C.A. Thornton, Myotonic Dystrophy. *Neurol Clin.* 32 (3) (2014) 705–719.
- [6] C.A. Maurage, B. Udd, M.M. Ruchoux, P. Vermersch, H. Kalimo, R. Krahe, et al., Similar brain tau pathology in DM2/PROMM and DM1/Steinert disease, *Neurology* 65 (2005) 1636–1638.
- [7] R. Weijs, K. Okkersen, B. van Engelen, B. Küsters, M. Lammens, E. Aronica, J. Raaphorst, A.M. van Cappellen van Walsum, Human brain pathology in myotonic dystrophy type 1: a systematic review, *Neuropathology* 41 (1) (2021 Feb) 3–20, <https://doi.org/10.1111/neup>.
- [8] V. Rakocevic-Stojanovic, S. Peric, D. Savic-Pavicevic, J. Pesovic, S. Mesaros, D. Lavrnica, et al., Brain sonography insight into the midbrain in myotonic dystrophy type 2, *Muscle Nerve* 53 (5) (2016) 700–704, <https://doi.org/10.1002/mus.24927>.
- [9] S. Peric, A. Pavlovic, V. Ralic, V. Dobricic, I. Basta, D. Lavrnica, et al., Transcranial sonography in patients with myotonic dystrophy type 1, *Muscle Nerve* 50 (2) (2014) 278–282.
- [10] R. Conforti, M. de Cristofaro, A. Cristofano, B. Brogna, A. Sardaro, G. Tedeschi, et al., Brain MRI abnormalities in the adult form of myotonic dystrophy type 1: a longitudinal case series study, *Neuroradiol. J.* 29 (1) (2016) 36–45.
- [11] T. Hashimoto, M. Tayama, M. Miyazaki, K. Murakawa, H. Kawai, H. Nishitani, et al., Neuroimaging study of myotonic dystrophy. I. Magnetic resonance imaging of the brain, *Brain Dev.* 17 (1) (1995) 24–27.
- [12] G. Antonini, C. Mainero, A. Romano, F. Giubilei, V. Ceschin, F. Gragnani, et al., Cerebral atrophy in myotonic dystrophy: a voxel based morphometric study, *J. Neurol. Neurosurg. Psychiatry* 75 (2004) 1611–1613.
- [13] H. Fukuda, J. Horiguchi, C. Ono, T. Ohshita, J. Takaba, K. Ito, Diffusion tensor imaging of cerebral white matter in patients with myotonic dystrophy, *Acta Radiol* 46 (2005) 104–109.
- [14] Y.G. Weber, R. Roebbing, J. Kassubek, S. Hoffmann, A. Rosenbohm, M. Wolf, et al., Comparative analysis of brain structure, metabolism, and cognition in myotonic dystrophy 1 and 2, *Neurology* 74 (2010) 1108–1117.
- [15] F. Caso, F. Agosta, S. Peric, V. Rakocevic-Stojanovic, M. Copetti, V.S. Kostic, M. Filippi, Cognitive impairment in myotonic dystrophy type 1 is associated with white matter damage, *PLoS One* 9 (8) (2014 Aug 12) e104697, <https://doi.org/10.1371/journal.pone.0104697>. PMID: 25115999.
- [16] M. Minnerop, B. Weber, J.C. Schoene-Bake, S. Roeske, S. Mirbach, C. Anspach, et al., The brain in myotonic dystrophy 1 and 2: evidence for a predominant white matter disease, *Brain* 134 (2011) 3530–3546.
- [17] S. Peric, L. Brajkovic, B. Belanovic, V. Ilic, B. Salak-Djokic, I. Basta, et al., Brain positron emission tomography in patients with myotonic dystrophy type 1 and type 2, *J. Neurol. Sci.* 378 (2017 15) 187–192.
- [18] U. Walter, M. Kanowski, J. Kaufmann, A. Grossmann, R. Benecke, L. Niehaus, Contemporary ultrasound systems allow high-resolution transcranial imaging of small echogenic deep intracranial structures similarly as MRI: a phantom study, *Neuroimage* 40 (2) (2008) 551–558, 1.
- [19] D. Berg, J. Godau, U. Walter, Transcranial sonography in movement disorders, *Lancet Neurol.* 7 (2008) 1044–1055.
- [20] S. Winblad, et al., Cerebrospinal fluid tau and amyloid beta42 protein in patients with myotonic dystrophy type 1, *Eur. J. Neurol.* 15 (9) (2008) 947–952.

- [21] S. Winblad, et al., Cognition in myotonic dystrophy type 1: a 5-year follow-up study, *Eur. J. Neurol.* 23 (9) (2016) 1471–1476.
- [22] V. Romeo, et al., Brain involvement in myotonic dystrophies: neuroimaging and neuropsychological comparative study in DM1 and DM2, *J. Neurol.* 257 (8) (2010) 1246.
- [23] S. Peric, G. Mandic-Stojmenovic, I. Markovic, E. Stefanova, V. Ilic, A. Parojcic, S. Misirlic-Dencic, M. Ostojic, V. Rakocevic-Stojanovic, V. Kostic, Cerebrospinal fluid biomarkers of neurodegeneration in patients with juvenile and classic myotonic dystrophy type 1, *Eur. J. Neurol.* 21 (2) (2014 Feb) 231–237, <https://doi.org/10.1111/ene.12237>.
- [24] I. Bozovic, S. Peric, J. Pesovic, B. Bjelica, M. Brkusanic, I. Basta, M. Bozic, I. Sencanic, A. Marjanovic, M. Brankovic, D. Savic-Pavicevic, V. Rakocevic-Stojanovic, Myotonic dystrophy type 2 - data from the Serbian registry, *J. Neuromuscul. Dis.* 5 (4) (2018) 461–469, <https://doi.org/10.3223/JND-180328>.
- [25] J. Mathieu, H. Boivin, D. Meunier, M. Gaudreault, P. Bégin, Assessment of a disease-specific muscular impairment rating scale in myotonic dystrophy, *Neurology* 56 (3) (2001) 336–340, <https://doi.org/10.1212/wnl.56.3.336>.
- [26] S. Peric, R. Maksimovic, B. Banko, M. Durdic, B. Bjelica, I. Bozovic, Y. Balcic, J. Pesovic, D. Savic-Pavicevic, V. Rakocevic-Stojanovic, Magnetic resonance imaging of leg muscles in patients with myotonic dystrophies, *J. Neurol.* 264 (9) (2017 Sep) 1899–1908, <https://doi.org/10.1007/s00415-017-8574-0>.
- [27] J. Godau, K.J. Schweitzer, I. Liepelt, C. Gerloff, D. Berg, Substantia nigra hypoechoogenicity: definition and findings in restless legs syndrome, *Mov. Disord.* 22 (2007) 187–192.
- [28] C. Krogias, B. Bellenberg, C. Pohn, R. Schneider, S.H. Meves, R. Gold, et al., Evaluation of CNS involvement in myotonic dystrophy type 1 and type 2 by transcranial sonography, *J. Neurol.* 262 (2) (2015) 365–374.
- [29] L. Laberge, C. Gagnon, S. Jean, J. Mathieu, Fatigue and daytime sleepiness rating scales in myotonic dystrophy: a study of reliability, *J. Neurol. Neurosurg. Psychiatry* 76 (21) (2005) 1403–1405.
- [30] M. Hamilton, A rating scale for depression, *J. Neurol. Neurosurg. Psychiatry* 23 (1960) 56–62.
- [31] L.B. Krupp, N.G. LaRocca, J. Muir-Nash, A.D. Steinberg, The fatigue severity scale. Application to patients with multiple sclerosis and systemic lupus erythematosus, *Arch. Neurol.* 46 (1989) 1121–1123.
- [32] S. Behnke, K.L. Double, S. Duma, G.A. Broe, V. Guenther, G. Becker, G.M. Halliday, Substantia nigra echomorphology in the healthy very old: correlation with motor slowing, *Neuroimage* 34 (3) (2007 Feb 1) 1054–1059, <https://doi.org/10.1016/j.neuroimage.2006.10.010>.
- [33] D. Berg, W. Roggendorf, U. Schröder, et al., Echogenicity of the substantia nigra: association with increased iron content and marker for susceptibility to nigrostriatal injury, *Arch. Neurol.* 59 (6) (2002) 999–1005, <https://doi.org/10.1001/archneur.59.6.999>.
- [34] S. Zhu, Y. Wang, Y. Jiang, R. Gu, M. Zhong, X. Jiang, B. Shen, J. Zhu, J. Yan, Y. Pan, L. Zhang, Clinical features in Parkinson's disease patients with hyperchogenicity in substantia nigra: a cross-sectional study, *Neuropsychiatric Dis. Treat.* 18 (2022) 1593–1601.
- [35] S. Ates, A. Deistung, R. Schneider, C. Pohn, C. Lukas, J.R. Reichenbach, C. Schneider-Gold, B. Bellenberg, Characterization of iron accumulation in deep gray matter in myotonic dystrophy type 1 and 2 using quantitative susceptibility mapping and R2* relaxometry: a magnetic resonance imaging study at 3 tesla, *Front. Neurol.* 10 (2019 Dec 13) 1320, <https://doi.org/10.3389/fneur.2019.01320>.
- [36] J.L. Pedroso, et al., Severity of restless legs syndrome is inversely correlated with echogenicity of the substantia nigra in different neurodegenerative movement disorders. A preliminary observation, *J. Neurol. Sci.* 319 (2012) 59–62, <https://doi.org/10.1016/j.jns.2012.05.015>.
- [37] C. Schmidauer, et al., Transcranial ultrasound shows nigral hypoechoogenicity in restless legs syndrome, *Ann. Neurol.* 58 (2005) 630–634.
- [38] X. Li, R.P. Allen, C.J. Earley, H. Liu, T.E. Cruz, R.A.E. Edden, P.B. Barker, P.C.M. van Zijl, Brain iron deficiency in idiopathic restless legs syndrome measured by quantitative magnetic susceptibility at 7 tesla, *Sleep Med.* 22 (2016 Jun) 75–82, <https://doi.org/10.1016/j.sleep.2016.05.001>.
- [39] J. Godau, U. Klose, A. Di Santo, K. Schweitzer, D. Berg, Multiregional brain iron deficiency in restless legs syndrome, *Mov. Disord.* 23 (2008) 1184–1187.
- [40] V. Beliveau, A. Stefani, C. Birkl, C. Kremser, E.R. Gizewski, B. Högl, C. Scherfler, Revisiting brain iron deficiency in restless legs syndrome using magnetic resonance imaging, *Neuroimage Clin* 34 (2022) 103024, <https://doi.org/10.1016/j.nicl.2022.103024>.
- [41] G. Becker, D. Berg, K.P. Lesch, et al., Basal limbic system alteration in major depression: a hypothesis supported by transcranial sonography and MRI findings, *Int. J. Neuropsychopharmacol.* 4 (2001) 21–31.
- [42] U. Walter, L. Prudente-Morrissey, S.C. Herpertz, et al., Relationship of brainstem raphe echogenicity and clinical findings in depressive states, *Psychiatry Res* 155 (2007) 67–73.
- [43] C. Krogias, U. Walter, Transcranial sonography findings in depression in association with psychiatric and neurologic diseases: a review, *J. Neuroimaging* 26 (3) (2016 May) 257–263, <https://doi.org/10.1111/jon.12328>.
- [44] J. Godau, D. Berg, Role of transcranial ultrasound in the diagnosis of movement disorders, *Neuroimaging Clin N Am* 20 (1) (2010) 87–101.
- [45] M. Mijajlovic, G. Tsvigoulis, N. Sternic, Transcranial brain parenchymal sonography in neurodegenerative and psychiatric diseases, *J. Ultrasound Med.* 33 (12) (2014) 2061–2068.
- [46] R.M. Kok, C.F. Reynolds 3rd, Management of depression in older adults: a review, *JAMA* 317 (20) (2017) 2114–2122, <https://doi.org/10.1001/jama.2017.5706>.
- [47] M. Siciliano, L. Trojano, G. Santangelo, R. De Micco, G. Tedeschi, A. Tessitore, Fatigue in Parkinson's disease: a systematic review and meta-analysis, *Mov. Disord.* 33 (11) (2018 Nov) 1712–1723, <https://doi.org/10.1002/mds.27461>.
- [48] V.S. Kostić, A. Tomić, M. Ječmenica-Lukić, The pathophysiology of fatigue in Parkinson's disease and its pragmatic management, *Mov Disord Clin Pract* 3 (4) (2016 Mar 11) 323–330, <https://doi.org/10.1002/mdc3.12343>.
- [49] J.D. Steele, M.E. Bastin, J.M. Wardlaw, et al., Possible structural abnormality of the brainstem in unipolar depressive illness: a transcranial ultrasound and diffusion tensor magnetic resonance imaging study, *J. Neurol. Neurosurg. Psychiatry* 75 (2005) 1510–1515.
- [50] S. Ono, K. Takahashi, K. Jimnai, et al., Loss of serotonin-containing neurons in the raphe of patients with myotonic dystrophy: a quantitative immunohistochemical study and relation to hypersomnia, *Neurology* 50 (1998) 535–538.
- [51] L. Laberge, P. Bégin, Y. Dauvilliers, et al., A polysomnographic study of daytime sleepiness in myotonic dystrophy type 1, *J. Neurol. Neurosurg. Psychiatry* 80 (2009) 642–646.
- [52] L. Laberge, C. Gagnon, Y. Dauvilliers, Daytime sleepiness and myotonic dystrophy, *Curr. Neurol. Neurosci. Rep.* 13 (4) (2013 Apr) 340, <https://doi.org/10.1007/s11910-013-0340-9>. PMID: 23430686.
- [53] F.A. Wollenweber, R. Schomburg, M. Probst, V. Schneider, T. Hiry, A. Ochsenfeld, M. Mueller, U. Dillmann, K. Fassbender, S. Behnke, Width of the third ventricle assessed by transcranial sonography can monitor brain atrophy in a time- and cost-effective manner—results from a longitudinal study on 500 subjects, *Psychiatry Res* 191 (3) (2011) 212–216, <https://doi.org/10.1016/j.psychres.2010.09.010>.