

Public health concerns regarding sporadic Creutzfeldt–Jakob disease in China: a case series

Journal of International Medical Research

2019, Vol. 47(8) 3972–3977

© The Author(s) 2019

Article reuse guidelines:

sagepub.com/journals-permissions

DOI: 10.1177/0300060519862067

journals.sagepub.com/home/imr



Ru-Yi Zhou^{1,*}, Yinzhu Zhou^{2,*}, Heng Zhang^{2,*},
Qingqing Hu³, Jinjie Zhu⁴, Jin Zhao²,
Shuilian Chen², Ruchun Liu², Weihong Hu²,
Xixing Zhang², Xianfa Xuan⁵, Yuxue Liao⁶ and
Tianmu Chen⁴ 

Abstract

In this study, we report three cases of sporadic Creutzfeldt–Jakob disease in China, two confirmed cases and one probable case. The aim of this study was to enrich the data regarding clinical and epidemiological features of this disease and to provide reference for the diagnosis, control, and prevention of sporadic Creutzfeldt–Jakob disease.

Keywords

Sporadic Creutzfeldt–Jakob disease, surveillance, epidemiological features, case report, diagnosis, prevention

Date received: 2 November 2018; accepted: 17 June 2019

¹Xixiang Preventive Health Care Center of Baoan District, Shenzhen, Guangdong Province, People's Republic of China

²Office of Infectious Disease Control, Changsha Center for Disease Control and Prevention, Changsha, Hunan, People's Republic of China

³Division of Public Health, School of Medicine, University of Utah, 201 Presidents Circle, Salt Lake City, UT, USA

⁴State Key Laboratory of Molecular Vaccinology and Molecular Diagnostics, School of Public Health, Xiamen University, Xiamen, Fujian Province, People's Republic of China

⁵Department of Nephrology, the Second Affiliated Hospital of Xiamen Medical College, Xiamen, Fujian, China

⁶Shenzhen Center for Disease Control and Prevention, Shenzhen, Guangdong Province, People's Republic of China

*These authors contributed equally to this work.

Corresponding author:

Tianmu Chen, State Key Laboratory of Molecular Vaccinology and Molecular Diagnostics, School of Public Health, Xiamen University, 4221-117 South Xiang'an Road, Xiang'an District, Xiamen, Fujian Province, People's Republic of China.

Email: 13698665@qq.com



Introduction

Creutzfeldt–Jakob disease (CJD) was identified in the 1920s by two German neuroscientists,¹ and since then, four types have been described: sporadic (sCJD), familial or genetic (gCJD), iatrogenic or accidental, and variant. According to open data published in Disease Surveillance in China,^{2–12} there were 1464 cases of CJD and 1302 cases of sCJD reported from 2006 to 2017 in China. In addition, the reported incidence of both diseases has increased each year (Figure 1). However, among the 1302 sCJD cases, only four cases have been

confirmed. In this study, we report three cases of sCJD, two confirmed cases and one probable case. The aim of this study was to enrich the data regarding the clinical and epidemiological features of this disease and to provide a reference for the diagnosis, control, and prevention of sCJD.

Case A

On 28 January 2018, a 61-year-old man began to experience symptoms of dizziness (Table 1). His symptoms subsequently increased and he developed stumbling and decreased cognitive function.

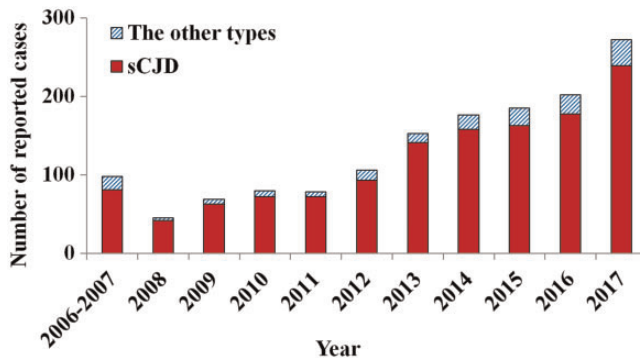


Figure 1. Reported cases of Creutzfeldt–Jakob disease in China, 2006 to 2017.

Table 1. Basic information and epidemiological characteristics of three cases of sporadic Creutzfeldt–Jakob disease.

	Case A	Case B	Case C
Sex	Male	Female	Female
Age (years)	61	51	61
Occupation	Retiree	Farmer	Farmer
Onset date	28 January 2018	31 March 2018	July 2017
Date sample collected	11 April 2018	3 May 2018	21 March 2018
Date confirmed	8 May 2018	16 May 2018	27 June 2018
History of contacting a source of infection	No	No	No
Symptoms at onset	Dizziness	Dizziness	Memory loss
Number of hospitals visited	2	1	1
Protein 14-3-3 in CSF	Positive	Positive	Positive
PrPSc protein in living brain tissue	Positive	NA	Positive
Classification of case	Confirmed	Clinically diagnosed	Confirmed

NA, not available; CSF, cerebrospinal fluid.

On 18 February, he visited the inpatient department of a local hospital (Hospital A) in Xiangtan City, Hunan Province, China. The results of magnetic resonance imaging (MRI), diffusion-weighted MRI (DWI), and magnetic resonance angiography (MRA) showed the following. Abnormal signal range in the left temporal and occipital cortex and subcortical layer, such that cerebral infarction (subacute to chronic stage) and encephalitis were considered. No abnormalities were detected on MRA; no strengthening signal was observed in brain tissue (intracerebral) and meninges on brain MRI. Using intracranial computed tomography angiography, a few calcifications were detected in the left carotid siphon. There were no positive results in routine laboratory testing, biochemical testing, complete viral testing, histologic staining, or testing for the presence of immunoglobulin G (IgG), IgA, and IgM in cerebrospinal fluid (CSF). The diagnosis of cerebral infarction was considered in Hospital A, according to the patient's symptoms and the results of laboratory tests. He received medical treatment to improve neurologic function, memory, and circulation as well as platelet aggregation inhibitors, lipid regulators, and plaque stabilizers. The patients' symptoms of dizziness resolved but his symptoms of stumbling and decreased cognitive function persisted.

On 20 March, the patient suddenly felt increased dizziness and his cognitive abilities and memory declined rapidly. He could remember his name but he could not recall his home address or age and did not recognize his family members. He could not walk by himself and had a low voice and hypologia. He had occasional myoclonic spasm, which lasted 1 or 2 s, with no visual rotation, headache, or vomiting. He was sent to the department of cerebrovascular disease in a hospital (Hospital B) in Changsha City, Hunan Province. The patient had a normal body temperature, respiration rate,

and pulse, but high blood pressure was detected. Results of physical examination showed the following. Normal physical growth; active position; chronic disease aspect; normal skin and mucosa; no rash or lymph gland swelling; normal head appearance with no wound; and normal appearance of the eyes, ears, nose, neck, chest, abdomen, spine, arms and legs, anal orifice, and penis. The patient appeared clinically sane, emotion normal, and disoriented; he had no delusions but had experienced several visual hallucinations. The patient demonstrated a lack of insight and a substantial reduction in calculative ability and both short- and long-term memory as well as poor understanding. He exhibited no signs of meningeal irritation; decreased response to pain and touch over most of the body surface; no or decreased deep reflexes, and no pathological reflexes. Results were negative or normal for routine blood, urine, and stool tests; stool occult blood; liver and renal function; myocardial enzyme levels; blood lipids; coagulation function; routine CSF tests including Gram staining and testing for the presence of antibody in the CSF; JC virus nucleic acid test; and neuronal antigen spectrum antibody IgG. The patient tested positive for Epstein-Barr virus and cytomegalovirus DNA. Biochemical detection of CSF showed increased glucose and lactic dehydrogenase and decreased ceruloplasmin.

On 24 March, the patient underwent MRI, which showed increased T2 signal intensity within the bilateral caudate nucleus and increased signal intensity in FLAIR sequences, especially on the right side. The remaining brain tissue showed no abnormal signal or enhanced range; the boundary of gray matter was clear; normal size and form were observed in the sulci, fissures, cisterns, and ventricles. There was no shift of midline structures, and no abnormal signal range was observed on DWI. Susceptibility weighted imaging showed no low signal

range in brain tissue and no abnormalities were detected in the vein distribution. “Dovetail syndrome” was observed in the bilateral substantia nigra. Increased middle wave amplitude 5-7 c/s θ and 3-4 c/s δ , and scattered 7-9 c/s α were detected in each lead on an electroencephalogram (EEG), with symmetrical slow waves. Scattered low wave amplitude 14-23 c/s β was detected in each lead on the EEG. Single triphasic sharp waves (middle wave amplitude) were occasionally detected in each lead. In accordance with the typical findings in clinical features, EEG, and neuroimaging examinations (MRI, DWI, and MRA), we suspected CJD.

On 28 March, according to his clinical features and examination results, the patient was diagnosed with suspected CJD, after consulting with specialists in Hospital B. The case was reported to the local Center for Disease Control and Prevention (CDC), and CSF specimens were collected and sent to the China CDC on the same day. The results of western blotting on 2 May were positive for protein 14-3-3. On 11 April, with the consent of a family member, living brain tissue (about 8 mm³) was collected from the patient and a specimen sent to the China CDC on 25 April. The specimen tested positive for PrP^{Sc} protein by western blotting on 8 May. The case was confirmed as sCJD according to the “Diagnosis for Creutzfeldt–Jakob disease (WS/T 562-2017)”, of the National Health Commission of the People’s Republic of China. According to WS/T 562-2017, the diagnostic standard of sCJD is as below.

1. History of disease and epidemiology
 - A. Progressive dementia symptoms.
 - B. Clinical course less than 2 years.
 - C. Routine testing excludes other diseases.
 - D. No clear history of iatrogenic contact.
2. Clinical manifestations
 - A. Myoclonus.

- B. Visual impairment or cerebellar ataxia.
 - C. Dysfunction of pyramidal/extrapyr- amidal system.
 - D. Inactive silence.
3. Clinical examination
 - A. Periodic three-phase waves appear on EEG during the course of the disease.
 - B. Abnormally high signal intensity in the putamen/caudate nucleus can be seen on cranial MRI, or the symmet- rical “ribbon” sign of gray matter can be seen on DWI.
4. Laboratory testing
 - A. Positive for 14-3-3 protein in the CSF.
 - B. Histopathological examination of the brain shows typical/standard neuro- pathological changes, i.e., spongi- form degeneration.
 - C. Protease resistance PrPSc deposited in brain tissue by immunohistochemistry.
 - D. Protease resistance PrPSc detected by western blotting.
5. Diagnostic classification
 - A. Suspicious case: history of disease and epidemiology plus any two clini- cal manifestations.
 - B. Clinically diagnosed case: on the basis of suspected cases plus clinical examination or result 4A.
 - C. Confirmed case: on the basis of sus- pected diagnosis, together with any of results 4B–4D.

The patient had no history of blood transfusion, travel or work abroad, contact with bovines, or eating imported beef or beef products. One month before the illness onset date, the patient had been in Shenzhen City, Guangdong Province for a week, but his history is unclear regarding contact with bovines, imported beef or beef products in that city.

Case B

On 31 March 2018, a 51-year-old female experienced symptoms of dizziness (Table 1). On 28 April, she visited Hospital B and was diagnosed with CJD. She had no history of blood transfusion, traveling or working abroad, contact with bovines, or eating imported beef or beef products. On 3 May, a CSF specimen was collected by Hunan provincial CDC and was sent to China CDC. On 16 May, the result of western blot testing was positive for protein 14-3-3. Therefore, the patient was diagnosed with probable sCJD according to WS/T 562-2017. The patient died on 19 May.

Case C

In July 2017, a 61-year old female experienced symptoms of memory loss (Table 1). She had no history of blood transfusion, travel or work abroad, or contact with bovines; however, she reported occasionally eating beef or beef products. On 21 March 2018, she visited a hospital (Hospital C) in Changsha City and was diagnosed with suspected CJD. A sample of the patient's living brain tissue was collected and sent to the China CDC. On 27 June, the results of western blotting were positive for PrP^{Sc} protein. The case was therefore confirmed as sCJD according to WS/T 562-2017.

Discussion

According to data of the above cases, all three patients had sCJD, two of them being confirmed cases and one a probable case. Two patients were female and one was male, and all three patients were older than 50 years. The transmission mode, route of infection, and pathogenesis of sCJD remain unclear. However, self-replication of the mutant protein (PrP^{Sc} protein in the brain and blood) has been confirmed; this protein is considered infectious. There is no clear

evidence to show that diet, surgery, blood transfusion, or occupational or non-occupational exposure to animals are risk factors in sCJD.¹³ We could not rule out the possibility of exposure to other unknown factors that could result in transmission of sCJD. To date, we have not determined the causes and infection routes in these three cases. A key point is enhancement of nosocomial infection control during the entire case period, including isolation of the patient and disinfection.

Among the reported cases of sCJD from 2006 to 2017 in China,²⁻¹² only 0.31% (4/1302) were confirmed cases. However, two confirmed sCJD cases were reported in Hunan Province within a 2-month period in 2018, which alerts us to sCJD being a public health concern that requires greater attention. A sensitive specialized surveillance system should be developed to detect cases of sCJD, to control and prevent this disease in China.

According to the Diagnosis for Creutzfeldt-Jakob disease (WS/T 562-2017) of China, our cases could be diagnosed as sCJD. However, mutation of the prion protein gene (*PRNP*), which is the most frequent mutation in CJD, was not tested in these three patients. As has been published in Europe, more than 50% of gCJD cases are not familial.¹⁴ Therefore, greater genetic evidence from future research is required to distinguish between sCJD and gCJD.

Acknowledgements

The authors thank all study participants for providing the data and field investigators for collecting the data.

Authors' contributions

TC, RZ, and YZ designed the research. YZ, HZ, JZ, SC, RL, WH, and XZ collected the data. TC, RZ, JZ, XX, and YL analyzed the data. TC and QH wrote the article. The final version was approved by all authors.

Declaration of conflicting interest

The authors declare that there is no conflict of interest.

Ethics

This study was approved by the Medical Ethics Committee of Changsha Center for Disease Control and Prevention. The data were obtained from a field epidemiological survey. Written informed consent was given by participants (or their guardian) regarding use of their clinical information. All analyzed data were anonymized.

Funding

This work was partly supported by the Open Research Fund of State Key Laboratory of Molecular Vaccinology and Molecular Diagnostics (SKLVD2018KF001 and SKLVD2018KF002), the Guiding Project of Fujian Science and Technology Plan Project (2018D0009).

ORCID iD

Tianmu Chen  <https://orcid.org/0000-0003-0710-5086>

References

1. Prusiner SB. Prions. *Proc Natl Acad Sci U S A* 1998; 95: 13363–13383.
2. Shi Q, Gao C, Zhou W, et al. Surveillance for Creutzfeldt-Jakob disease in China from 2006 to 2007. *BMC Public Health* 2008; 8: 360. doi: 10.1186/1471-2458-8-360.
3. Tian C, Gao C, Shi Q, et al. Study on the characteristics of patients with Creutzfeldt-Jakob disease under 2008 surveillance data in China. *Zhonghua Liu Xing Bing Xue Za Zhi* 2009; 30: 713–715 [in Chinese].
4. Shi Q, Gao C, Chen C, et al. Study on the characteristics of the surveilled Creutzfeldt-Jakob disease patients in 2009 in China. *Dis Surveill* 2010; 25: 766–769 [in Chinese].
5. Chen C, Shi Q, Zhou W, et al. Surveillance of Creutzfeldt-Jakob disease in China, 2010. *Dis Surveill* 2011; 26: 844–847 [in Chinese].
6. Shi Q, Chen C, Zhou W, et al. Surveillance of Creutzfeldt-Jakob disease in China, 2011. *Dis Surveill* 2012; 27: 928–931 [in Chinese].
7. Zhang XM, Zhou W, Zhang BY, et al. Characteristics of patients with Creutzfeldt-Jakob disease in China, 2013. *Dis Surveill* 2013; 29: 271–275 [in Chinese].
8. Wang JC, Chen C, Zhou W, et al. Surveillance of Creutzfeldt-Jakob disease cases in China, 2012. *Dis Surveill* 2014; 29: 9–13 [in Chinese].
9. Chen C, Zhou W, Zhang BY, et al. Surveillance for Creutzfeldt-Jakob disease in China, 2015. *Dis Surveill* 2016; 31: 365–369 [in Chinese].
10. Xiao K, Zhou W, Zhang BY, et al. Characteristics of Creutzfeldt-Jakob disease cases in China, 2014. *Dis Surveill* 2016; 31: 18–23 [in Chinese].
11. Xiao K, Zhou W, Wang Y, et al. Surveillance for Creutzfeldt-Jakob disease in China, 2016. *Dis Surveill* 2019; 34: 106–111 [in Chinese].
12. Wang J, Zhou W, Xiao K, et al. Surveillance for Creutzfeldt-Jakob disease in China, 2017. *Dis Surveill* 2019; 34: 226–231 [in Chinese].
13. Lopez FJG, Ruiz-Tovar M, Almazan-Isla J, et al. Risk of transmission of sporadic Creutzfeldt-Jakob disease by surgical procedures: systematic reviews and quality of evidence. *Euro Surveill* 2017; 22:1–14. doi: 10.2807/1560-7917.ES.2017.22.43.16-00806.
14. Feketeova E, Jarcuskova D, Janakova A, et al. Creutzfeldt-Jakob disease surveillance in Eastern Slovakia from 2004 to 2016. *Cent Eur J Public Health* 2018; 26: S37–S41. doi: 10.21101/cejph.a5277.