

Coexisting filum terminale arteriovenous fistula and filum terminale lipoma treated with single-stage surgery: illustrative case

Hiroki Yamazaki, MD,^{1,2} Tomohiko Ozaki, MD, PhD,¹ Tomoki Kidani, MD,¹ Yosuke Fujimi, MD,¹ Masahiro Nonaka, MD, PhD,³ Masao Umegaki, MD, PhD,² Chisato Yokota, MD, PhD,² and Toshiyuki Fujinaka, MD, PhD¹

¹Department of Neurosurgery, National Hospital Organization, Osaka National Hospital, Chuo-ku, Osaka, Japan; ²Department of Neurosurgery, Suita Municipal Hospital, Suita, Japan; and ³Department of Neurosurgery, Kansai Medical University, Hirakata, Japan

BACKGROUND Both filum terminale arteriovenous fistulas (FTAVFs) and filum terminale lipomas (FTLs) are rare. Because of this rarity, there is a paucity of data regarding concomitant FTAVF and FTL, and the optimal treatment remains to be defined. The authors describe a patient with coexisting FTAVF and FTL treated with single-stage surgery.

OBSERVATIONS A man in his 70s was referred to the authors' department because of a suspected spinal vascular malformation seen on magnetic resonance imaging that was performed to investigate lower limb weakness, intermittent claudication, and urinary incontinence. Previous imaging had shown a terminal lipoma with an internal flow void. Computed tomography angiography and digital subtraction angiography revealed an FTAVF, the feeder being a lateral sacral artery. The patient was treated surgically with curative intent. The FTL and tethered cord that had been identified by imaging were treated in the same procedure. Postoperative digital subtraction angiography showed absence of the abnormal vessels. The patient was discharged home on the 19th postoperative day.

LESSONS When considering treatment, it is important to determine whether symptoms are attributable mainly to FTL, tethered cord, or FTAVF. One-stage treatment is useful because it eliminates both the FTAVF and the factors that led to its development.

<https://thejns.org/doi/abs/10.3171/CASE22474>

KEYWORDS filum terminale; arteriovenous fistula; filum terminale lipoma; single-stage surgery

Filum terminale arteriovenous fistula (FTAVF) is a type of spinal vascular malformation. It has been reported that the filum terminale artery, a branch of the anterior spinal artery (ASA), or the lateral sacral artery (LSA) directly connects with the filum terminale vein (FTV).¹

FTAVFs are a disease accounting for approximately 5% of spinal vascular malformations.^{1,2} They are more common in middle-aged to older men, with the reported incidence being 0.234 per 100,000 person-years.³

In contrast, filum terminale lipomas (FTLs) are a type of spinal lipoma that develops as a result of spinal canal dysplasia and invasion of subcutaneous fat into the spinal canal during fetal life. Spinal lipomas mainly cause a tethered cord, which can result in sphincter dysfunction and neurological symptoms.⁴ The incidence of

FTLs on magnetic resonance imaging (MRI) ranges from 0.24% to 4%.^{5–8} Because of the rarity of both conditions, there is a paucity of data on their simultaneous occurrence, and the optimal treatment for this combination remains to be clarified. In this report, we describe a patient with an FTAVF concomitant with FTL cured by single-stage surgery.

Illustrative Case

A man in his 70s had had bilateral leg weakness for about 6 months and intermittent claudication for about 4 months before visiting our department. At the time of admission, intermittent claudication was confirmed, and he needed a cane to walk more than 10 m. He subsequently developed urinary incontinence, and his gait disturbance worsened by the day. Spinal cord MRI arranged by a previous

ABBREVIATIONS ASA = anterior spinal artery; AVF = arteriovenous fistula; DAVF = dural arteriovenous fistula; FTAVF = filum terminale arteriovenous fistula; FTL = filum terminale lipoma; FTV = filum terminale vein; LSA = lateral sacral artery; MRI = magnetic resonance imaging.

INCLUDE WHEN CITING Published January 16, 2023; DOI: 10.3171/CASE22474.

SUBMITTED November 3, 2022. **ACCEPTED** November 29, 2022.

© 2023 The authors, CC BY-NC-ND 4.0 (<http://creativecommons.org/licenses/by-nc-nd/4.0/>).

physician showed a T2-high signal area in the spinal cord below the T8 level and a flow void in the dorsal spinal cord that was suspected to denote a spinal vascular malformation (Fig. 1A and B). There was also a terminal lipoma with abnormal blood vessels, and the spinal cord was tethered to the lipoma/filum complex (Fig. 1D).

His manual muscle testing results were 4-/4- in the iliopsoas, quadriceps, and hamstring muscles and 4/4 for lateral dorsiflexion and plantar flexion. There was bilateral sensory disturbance beyond L2. No sacral dysplasia or lumbosacral skin abnormalities were observed.

Despite the absence of abnormal vessels on spinal angiography, computed tomography angiography revealed shunt disease, the feeder being an LSA. Digital subtraction angiography was therefore performed, during which selective angiography of the right LSA showed an arteriovenous fistula (AVF) draining into the FTV. There were no other feeders (Fig. 1C, E, and F).

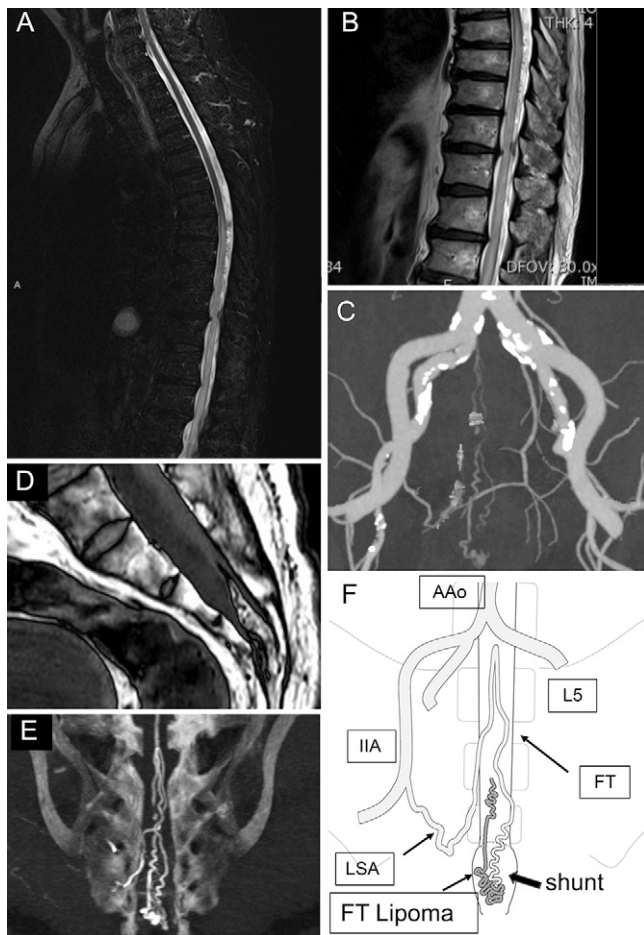


FIG. 1. Preoperative images and pathological schema. T2 short tau inversion recovery MRI showing spinal cord edema below T8 (A). T2-weighted MRI showing a flow void in the dorsal spinal cord (B). Computed tomography angiography showing shunt disease with the lateral sacral artery as the feeder (C). T1-weighted MRI showing a lipoma with a flow void inside it (D). Reconstructed coronal image from three-dimensional rotational angiography obtained by digital subtraction angiography (E). Schema of the relevant anatomy (F). AAo = abdominal aorta; FT = filum terminale.

Surgery was performed with the patient in the prone position under general anesthesia with intraoperative electromyography and bulbocavernosus reflex monitoring to maximize preservation of nerve function. The skin was incised, and 2.5×5 cm of the sacrum was drilled out to expose the dura mater. The dura was incised, revealing an FTL.

MRI showed that the lipoma was continuous with the skin on the caudal side of the operative field. A red (arterialized) vein, which was considered to be an FTV, was noted on the ventral side of the lipoma (Fig. 2A). Intraoperative electromyography responses indicated that there were no problems during dissection of the AVF and removal of the lipoma. Because there was a feeder within the lipoma that bled vigorously, coagulation and cauterization were performed while the lipoma was removed (Fig. 2B–D).

The aforementioned red vein was collapsed and reverted to a venous color. In addition, a venous pattern was observed by vascular Doppler scan. Digital subtraction angiography 17 days after surgery showed that the AVF was no longer present. MRI showed that the high signal areas in the spinal cord had also improved (Fig. 3). The patient's muscle weakness gradually improved, and he was discharged on the 19th postoperative day with a modified Rankin

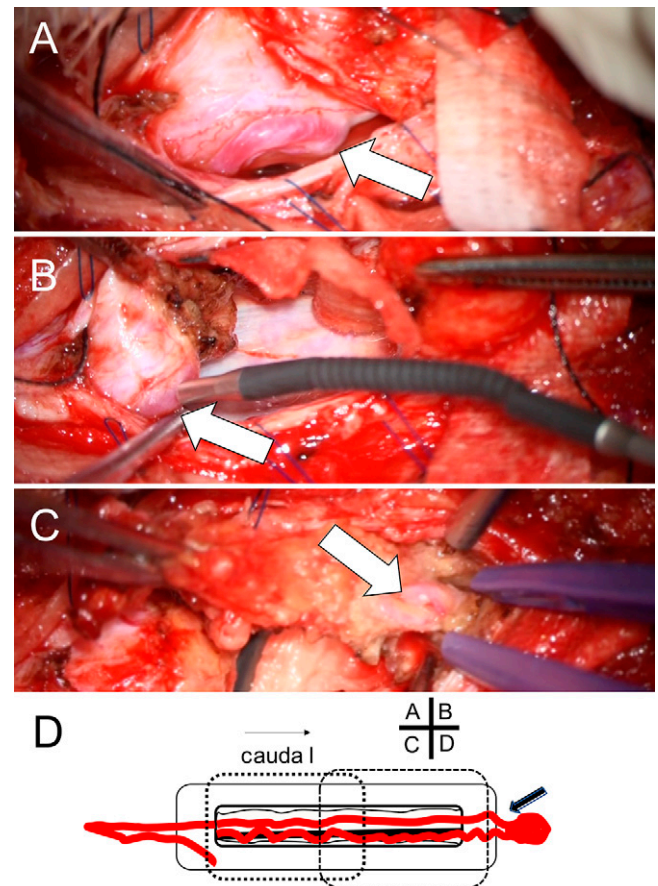


FIG. 2. Intraoperative photograph showing a red vein (white arrows) ventral to the FTL (A). Intraoperative photograph showing a feeder within the lipoma on the caudal side; this was cauterized and amputated (B). Intraoperative photograph showing the red vein disappeared after removal of the FTL (C). Schema of relevant anatomy during surgery (D). The left dotted outlined area shows A and C. The right dotted outlined area shows B. Arrow shows fistulous point.

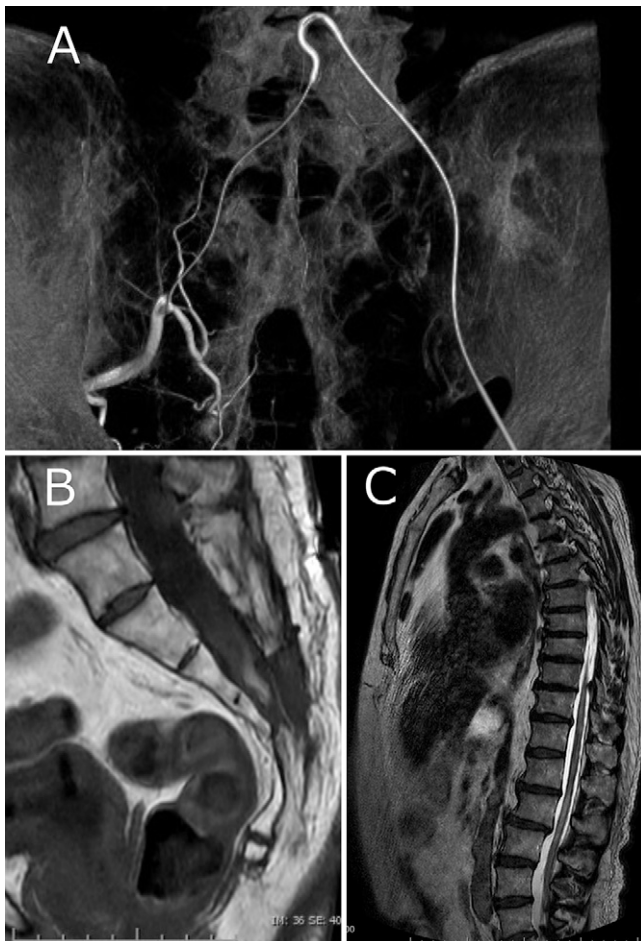


FIG. 3. Postoperative digital subtraction angiography showed disappearance of abnormal vessels (A). T2-weighted MRI showing improvement in spinal cord edema (B). MRI showing absence of the FTL (C).

Scale score 2. By 4 months after surgery, he was able to walk about 300 m by himself, and his dysuria had improved.

Discussion

Observations

FTAVFs occur more commonly in older individuals, and the incidence is three times greater in men than in women.¹ The most common symptom is loss of motor function, reported in 80% of cases, followed by sensory disturbance in 77%, back pain in 72%, bladder and bowel disturbances in 67%, and sexual dysfunction in 10%.¹ Some cases with slow progression are misdiagnosed and even treated surgically as spinal degenerative disease.^{9,10} Increased venous pressure is one of the causes of the disorders resulting from FTAVF. This elevated venous pressure is transmitted to the spinal cord, causing congestive myelopathy. In addition, AVFs can result in blood theft and spinal cord ischemia and dysfunction.¹ Aminoff et al.¹¹ recommended surgical intervention for spinal dural arteriovenous fistula (DAVF) because of the high risk (approximately 50%) of developing walking disability within 3 years.

Manifestations of FTL include sphincter dysfunction in 43%–59% of cases, neurological and orthopedic disorders in 24%–50%, and sensory disturbance in 16%–32%.⁴ The manifestations of FTL may

be attributable to direct compression of nerve tissue by the FTL or microscopic damage to the spinal cord or circulatory disturbance caused by repeated bending of the spinal cord back and forth while it is still engaged.¹²

The exact causative mechanism of FTAVF development has yet to be clarified. Venous hypertension and angiogenic factors have been shown to be strongly involved in the development of DAVF.^{13,14}

Li et al.¹³ have suggested that venous hypertension of the spine caused by venous compression by a lipoma can be associated with development of an FTAVF. In addition, lipomas can release angiogenic factors such as fibroblast growth factor 2 and vascular endothelial growth factor, which can produce angiogenesis within lipomas.^{15,16} Platelet-derived growth factor-B may also be involved in angiogenesis and venous hypertension (Fig. 4).¹⁷ It is involved in adipose tissue expansion and angiogenesis within adipose tissue. The increase in adipose tissue increases proinflammatory M1 macrophages and releases large amounts of platelet-derived growth factor-B, which in turn stimulates angiogenesis.¹⁸ Considering the above, lipomas are presumably associated with AVFs via two mechanisms: venous hypertension and vascular growth factors.

FTAVFs have also been reported as complications of other diseases. In cases of FTAVF combined with scoliosis, it has been suggested that adjacent severe scoliosis may have caused venous hypertension, which in turn may have caused formation of an AVF.¹⁹ In one reported case, a lumbar hernia was complicated by FTAVF, and the associated severe spinal canal stenosis caused venous hypertension. There is also an association between fistula location and stenosis.²⁰ The pathology of tethered cord syndrome caused by a lipoma is considered to be impaired blood flow and inadequate oxygen supply as a result of stretching of the spinal cord vessels.²¹ Thus, multiple factors can promote venous hypertension and angiogenesis.

Takai et al.²² reported a case of AVF associated with FTL with tethered cord that resolved with endovascular therapy alone

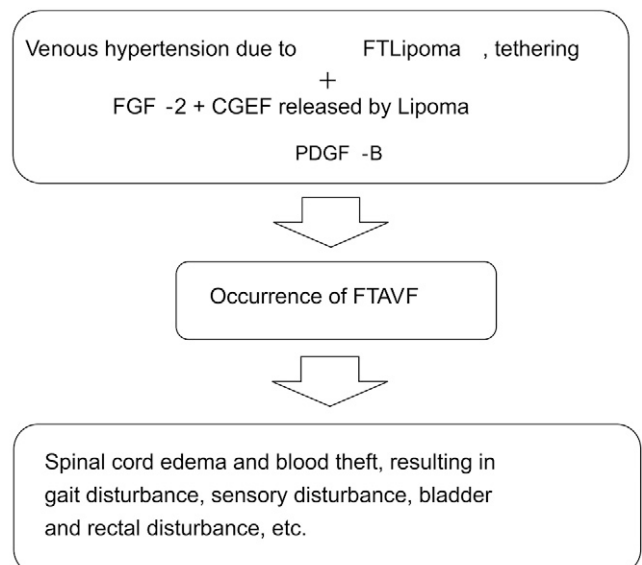
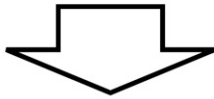


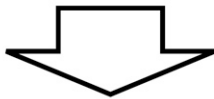
FIG. 4. Flowchart showing development of an AVF and resultant manifestations. FGF-2 = fibroblast growth factor 2; PDGF-B = platelet-derived growth factor-B.

FT lipoma ? tethering ? FTAVF ?



Typical for FTAVF and atypical for lipoma.

Blood flow impairment due to FTAVF



Possibility that AVF may be caused by FT lipoma or tethering, and may be better to remove them at the same time.

Treat FTAVF as the cause of the symptoms and any FT lipoma or tethering that may have caused FTAVF at the same time.

FIG. 5. Causes of manifestations and treatment strategies. FT = filum terminale.

without dissection, suggesting that the manifestations of FTAVF are not caused by tethering of the spinal cord. Talenti et al.²³ reported that treatment of an AVF that was noticed on MRI after treatment of a lipoma resulted in an improvement in symptoms. Their patient's advanced age, onset of lower limb movement disorder, weekly progression of symptoms, and absence of spinal deformity or postural variation are not typical of lipoma or tethered cord syndrome. Thus, disturbance of blood flow caused by the FTAVF was the most likely cause.

There are currently two forms of treatment for FTAVF: endovascular treatment and direct surgery. Endovascular treatment of spinal cord vascular malformations is less invasive than direct surgery but has the disadvantage that the vessels to the shunt are characteristically narrow, tortuous, and long. In particular, embolization from the ASA has been reported to cause complications consequent to thrombosis, vasospasm, and intrusion of embolizing material.^{1,24} Therefore, in cases where the ASA is the main feeder, endovascular treatment carries a high risk of ischemic complications, making direct surgery preferable in some cases.²⁵ Our patient had a single feeder from the LSA, with the resultant low risk of straying into the ASA making it highly possible that endovascular treatment would have been curative. However, endovascular treatment of FTAVFs is inferior to direct surgery in terms of cure. Giordan et al.¹ reported treating 10 of 39 patients with FTAVF with endovascular therapy; the complete occlusion rate was only 76%, and two patients eventually required direct surgery. In contrast, the success rate of direct surgery for FTAVFs is close to 100%, with a complication rate of less than 5%.^{1,26,27} A total of five unsuccessful endovascular embolization procedures were reported in three of six similar cases of combined DAVF and lipoma in the sacral region.²⁸ For the above reasons, we chose to perform a straight-through surgery with curative intent because the lipoma could safely be dissected during the same procedure. From the point of view of resolution of symptoms,

simultaneous resection of the lipoma may have been unnecessary. However, considering the possibility of recurrence of an AVF or lipoma, we believe that resection was indicated (Fig. 5).

Lessons

We report a case of FTAVF associated with FTL treated with single-stage surgery. Treatment of FTAVF presumably led to improvement in neurological symptoms. However, simultaneous surgical treatment of the FTL might be preferable regarding prevention of recurrence of the FTAVF.

Acknowledgments

Funding provided to Tomohiko Ozaki by Japan Society for the Promotion of Science (JSPS; grant no. 18K16582).

References

1. Giordan E, Brinjikji W, Ciceri E, Lanzino G. Arteriovenous fistulae of the filum terminale. *J Neurointerv Surg*. 2018;10(2):191–197.
2. Rodesch G, Hurth M, Alvarez H, Tadié M, Lasjaunias P. Classification of spinal cord arteriovenous shunts: proposal for a reappraisal – the Bicêtre experience with 155 consecutive patients treated between 1981 and 1999. *Neurosurgery*. 2002;51(2):374–380.
3. Hiramatsu M, Ishibashi R, Suzuki E, et al. Incidence and clinical characteristics of spinal arteriovenous shunts: hospital-based surveillance in Okayama, Japan. *J Neurosurg Spine*. 2021;36(4):670–677.
4. Pierre-Kahn A, Zerah M, Renier D, et al. Congenital lumbosacral lipomas. *Childs Nerv Syst*. 1997;13(6):298–335.
5. Al-Omari MH, Eloqayli HM, Qudseih HM, Al-Shinag MK. Isolated lipoma of filum terminale in adults: MRI findings and clinical correlation. *J Med Imaging Radiat Oncol*. 2011;55(3):286–290.
6. Brown E, Matthes JC, Bazan C 3rd, Jinkins JR. Prevalence of incidental intraspinal lipoma of the lumbosacral spine as determined by MRI. *Spine (Phila Pa 1976)*. 1994;19(7):833–836.

7. Uchino A, Mori T, Ohno M. Thickened fatty filum terminale: MR imaging. *Neuroradiology*. 1991;33(4):331–333.
8. Cools MJ, Al-Holou WN, Stetler WR Jr, et al. Filum terminale lipomas: imaging prevalence, natural history, and conus position. *J Neurosurg Pediatr*. 2014;13(5):559–567.
9. Lakhdar F, Benzagmout M, Chakour K, Chaoui MEF. Spinal arteriovenous fistulas of the filum terminale: case report and literature review. *Asian J Neurosurg*. 2019;14(4):1277–1282.
10. Sharma P, Ranjan A, Lath R. Arteriovenous fistula of the filum terminale misdiagnosed and previously operated as lower lumbar degenerative disease. *Asian Spine J*. 2014;8(3):365–370.
11. Aminoff MJ, Logue V. The prognosis of patients with spinal vascular malformations. *Brain*. 1974;97(1):211–218.
12. Pang D, Wilberger JE Jr. Tethered cord syndrome in adults. *J Neurosurg*. 1982;57(1):32–47.
13. Li Q, Zhang Q, Huang QH, et al. A pivotal role of the vascular endothelial growth factor signaling pathway in the formation of venous hypertension-induced dural arteriovenous fistulas. *Mol Med Rep*. 2014;9(5):1551–1558.
14. Uranishi R, Nakase H, Sakaki T. Expression of angiogenic growth factors in dural arteriovenous fistula. *J Neurosurg*. 1999;91(5):781–786.
15. Lucarelli E, Sangiorgi L, Benassi S, et al. Angiogenesis in lipoma: an experimental study in the chick embryo chorioallantoic membrane. *Int J Mol Med*. 1999;4(6):593–596.
16. Horiuchi Y, Iwanami A, Akiyama T, et al. Spinal arteriovenous fistula coexisting within a spinal lipoma: report of two cases. *Spinal Cord Ser Cases*. 2017;3:17079.
17. Uhl E, Rösken F, Sirsjö A, Messmer K. Influence of platelet-derived growth factor on microcirculation during normal and impaired wound healing. *Wound Repair Regen*. 2003;11(5):361–367.
18. Onogi Y, Wada T, Kamiya C, et al. PDGFR β regulates adipose tissue expansion and glucose metabolism via vascular remodeling in diet-induced obesity. *Diabetes*. 2017;66(4):1008–1021.
19. Iampreechakul P, Tirakotai W, Wangtanaphat K, Lertbutsayanukul P, Siriwiwonmas S. Filum terminale arteriovenous fistula in association with degenerative lumbosacral spinal canal stenosis: report of 3 cases and review of the literature. *World Neurosurg*. 2020;138:231–241.
20. Iampreechakul P, Jitpun E, Wangtanaphat K, Lertbutsayanukul P, Khunvutthidee S, Siriwiwonmas S. Filum terminale arteriovenous fistula coexisting with a large L2-L3 disc sequestration and associated diffuse lumbar arachnoiditis. *Asian J Neurosurg*. 2021;16(2):412–417.
21. Hayashi T. Tethered cord syndrome. Article in Japanese. *Spinal Surg*. 2022;36:24–30.
22. Takai K, Komori T, Taniguchi M. Angioarchitecture of filum terminale arteriovenous fistulas: relationship with a tethered spinal cord. *World Neurosurg*. 2019;122:e795–e804.
23. Talenti G, Vitale G, Cester G, Della Puppa A, Faggin R, Causin F. Rare association between spinal dural arteriovenous fistulas and dysraphisms: report of two cases and review of the literature with a focus on pitfalls in diagnosis and treatment. *Interv Neuroradiol*. 2017;23(5):458–464.
24. Chanthanaphak E, Pongpech S, Jiarakongmun P, Kobkitsuksakul C, Chi CT, Terbrugge KG. Filum terminale arteriovenous fistulas: the role of endovascular treatment. *J Neurosurg Spine*. 2013;19(1):49–56.
25. Kumar A, Deopujari CE, Mhatre M. Misdiagnosis in a case of non-compressive myelopathy due to a lumbar spinal intradural fistula supplied by the artery of Adamkiewicz. *Surg Neurol Int*. 2011;2:12.
26. Trinh VT, Duckworth EA. Surgical excision of filum terminale arteriovenous fistulae after lumbar fusion: value of indocyanine green and theory on origins (a technical note and report of two cases). *Surg Neurol Int*. 2011;2:63.
27. Djindjian M, Ribeiro A, Ortega E, Gaston A, Poirier J. The normal vascularization of the intradural filum terminale in man. *Surg Radiol Anat*. 1988;10(3):201–209.
28. Przepiórka Ł, Kunert P, Juszyńska P, et al. Coincidence of tethered cord, filum terminale lipoma, and sacral dural arteriovenous fistula: report of two cases and a literature review. *Front Neurol*. 2018;9:807.

Disclosures

The authors report no conflict of interest concerning the materials or methods used in this study or the findings specified in this paper.

Author Contributions

Conception and design: Ozaki, Yamazaki. Acquisition of data: Ozaki, Yamazaki, Fujimi, Nonaka. Analysis and interpretation of data: Ozaki, Yamazaki. Drafting the article: Yamazaki, Yokota. Critically revising the article: Ozaki, Kidani, Nonaka, Umegaki. Reviewed submitted version of manuscript: Ozaki, Nonaka, Umegaki, Fujinaka. Approved the final version of the manuscript on behalf of all authors: Ozaki. Statistical analysis: Ozaki. Administrative/technical/material support: Ozaki, Yokota. Study supervision: Ozaki, Fujinaka.

Correspondence

Tomohiko Ozaki: National Hospital Organization, Osaka National Hospital, Osaka, Japan. tomohikoozaki@gmail.com.