

## Case Report

## Surgical treatment of focal symptomatic refractory status epilepticus with and without invasive EEG



Carolina Cuello-Oderiz <sup>a,\*</sup>, Marina Aberastury <sup>b</sup>, Ana Gabriela Besocke <sup>a</sup>, Jorge Sinner <sup>c</sup>,  
Betiana Comas-Guerrero <sup>b</sup>, Carlos Alberto Ciraolo <sup>d</sup>, Maria Concepción Pasteris <sup>e</sup>,  
Walter Horacio Silva <sup>b</sup>, María del Carmen García <sup>a</sup>

<sup>a</sup> Department of Adult Neurology, Epilepsy Section, Italian Hospital of Buenos Aires, Argentina

<sup>b</sup> Department of Child Neurology, Epilepsy Section, Italian Hospital of Buenos Aires, Argentina

<sup>c</sup> Department of Adult Critical Care, Italian Hospital of Buenos Aires, Argentina

<sup>d</sup> Department of Neurosurgery, Italian Hospital of Buenos Aires, Argentina

<sup>e</sup> Neurology Center, "Santa Elena", Salta, Argentina

## ARTICLE INFO

## Article history:

Received 14 August 2015

Received in revised form 21 August 2015

Accepted 24 August 2015

Available online 27 September 2015

## Keywords:

Hemispherectomy

Status epilepticus/surgery

Invasive EEG

Stereoelectroencephalography

Refractory status epilepticus

Super-refractory status epilepticus

## ABSTRACT

**Purpose:** Neurosurgery appears to be a reasonable alternative in carefully selected patients with refractory status epilepticus (RSE) and super-refractory status epilepticus (SRSE). We discuss the optimal timing of the surgery and the use of previous stereoelectroencephalography (SEEG) invasive evaluation.

**Methods:** We identified 3 patients (two pediatric and one adult) who underwent epilepsy surgery because of RSE or SRSE from our epilepsy surgery database, one of them with previous SEEG.

**Results:** Status epilepticus resolved acutely in all of them with no mortality and no substantial morbidity. At follow-up (median: 2 years), 1 patient was seizure-free, and 2 had significant improvement.

**Conclusion:** Surgery should be considered in all cases of RSE and SRSE early in the course of the evolution of the disease.

© 2015 The Authors. Published by Elsevier Inc. This is an open access article under the CC BY-NC-ND license (<http://creativecommons.org/licenses/by-nc-nd/4.0/>).

## 1. Introduction

Refractory status epilepticus (RSE) is defined as a status epilepticus (SE) that fails to respond to first- and second-line anticonvulsant drug therapy [1]. Super-refractory status epilepticus (SRSE) is a RSE that continues or recurs 24 h or more after the onset of anesthetic therapy [2]. Neurosurgery appears to be a reasonable alternative in carefully selected patients and can successfully control both entities [3–5].

Multiple surgical procedures have been described, most of them requiring intraoperative invasive evaluation with electrocorticography (ECoG) to tailor and localize the epileptogenic zone (EZ) [1–4,6].

We present three cases of epilepsy surgery as a successful treatment for RSE and SRSE. In one of them, chronic invasive evaluation was performed using depth electrodes (SEEG) to tailor the epileptogenic zone.

## 2. Methods

From our epilepsy surgery database of consecutive patients who underwent epilepsy surgery at the Italian Hospital of Buenos Aires between 2005 and 2014, we identified 3 cases whose surgery was done for treatment of RSE or SRSE. The consensus to perform surgery was arrived at after careful consideration of clinical and electrophysiological details during patient management conferences, along with parental informed consent. Relevant demographic, clinical, and follow-up information was obtained by chart review.

## 3. Results

## 3.1. Case 1

An eight-year-old girl presented with RSE. She was the product of a normal pregnancy and delivery. Except for the fact that she had slight learning disabilities with dyslexic features since she was 5 years old, her neurological exam was unremarkable. Her first seizure was at the age of seven.

She was on clobazam (CLB) (1 mg/kg/day), oxcarbazepine (OXC) (40 mg/kg/day), valproic acid (VPA) (40 mg/kg/day), levetiracetam

\* Corresponding author at: Italian Hospital of Buenos Aires, Juan D. Perón 4190 (C1199ABD) Buenos Aires, Argentina. Tel.: +54 11 4959 0200; fax: +54 11 4959 0322.  
E-mail address: [carolina.cuello@hiba.org.ar](mailto:carolina.cuello@hiba.org.ar) (C. Cuello-Oderiz).

(LEV) (60 mg/kg/day), and topiramate (TPM) (9 mg/kg/day), with poor seizure control. Eight months after seizure onset, she was admitted to our hospital because of partial SE without loss of consciousness. Electroencephalograms showed a normal and symmetric background with frequent right frontotemporal spikes and sharp waves during sleep. Ictal video EEG showed spikes and sharp waves arising from the right anterior temporal region. Brain MRIs showed right hemisphere atrophy. A second MRI showed no significant changes. Cerebral spinal fluid (CSF) analysis, including oligoclonal banding, was normal.

Despite pharmacological treatment with lorazepam (LZP), phenytoin (PHT), and phenobarbital (PHB) and a ketogenic diet, she continued having multiple focal seizures lasting 30 to 120 min. Because of the presence of a focal MRI lesion and lack of criteria for Rasmussen's encephalitis, surgical treatment was chosen in a multidisciplinary epilepsy management meeting. A 2-stage epilepsy surgery was performed after 25 days of focal SE.

Twelve depth electrodes were implanted over the right fronto-temporoparietal region. Stereoelectroencephalography evaluation showed a continuous ictal pattern arising from the amygdala and hippocampus (Fig. 1). A right anterior temporal lobectomy was indicated. Ultimately, the amygdala and hippocampus were not resected because of bleeding and congestive edema in the lesion area. Refractory status epilepticus resolved after surgery.

Brain pathology reported focal architectural disorganization consistent with malformation of cortical development (MCD).

Four years after surgery, she has had one seizure without loss of consciousness per month. Her current medications are lacosamide (LCM) and CLB.

### 3.2. Case 2

An 18-year-old left-handed woman was referred to our hospital because of recurrent focal afebrile seizures. She was the product of a normal pregnancy and delivery. At the age of six, she developed progressive right hemifacial atrophy. Six years later, she developed epilepsy. Parry Romberg syndrome was diagnosed because the patient presented, with no apparent cause, progressive unilateral facial atrophy involving soft tissues without scleroderma and hair abnormalities, and focal epilepsy. Brain MRI showed right parietal and occipital cortical and subcortical T2-hyperintensity and mild atrophy. Occasionally, these findings

are seen in Parry Romberg syndrome as well. Neuropsychological evaluation revealed mild mental retardation with a global IQ of 62, with no differences between the verbal and nonverbal scales.

She had visual disturbances (mainly photopsia) followed by left leg numbness and tonic-clonic movements with occasional loss of consciousness. Her condition was refractory to adequate doses of VPA, lamotrigine (LMT), and LEV.

She was initially admitted to a local hospital because of complex partial SE. Loading doses of diazepam (DZP), PHB, and PHT were administered without success. Midazolam (MDZ) (4 mg/kg/min) was the next drug administered. Every time MDZ was discontinued, an EEG pattern of SE was seen. A trial with gamma globulin (2 g/kg) and methylprednisolone failed as well. Finally, she was referred to our hospital because of SRSE.

On admission, her neurological exam revealed right facial atrophy and a left-sided weakness. Her episodes lasted between 30 and 60 min with a frequency of 12 to 20 per day. Her EEG showed a slow asymmetric background, frequent right frontotemporal epileptiform discharges, and right frontotemporal electrographical seizures with clinical correlation.

On admission, she received a loading dose of VPA followed by LEV. Because of a lack of response, coma was again induced with MDZ for three days. Seizures reappeared during tapering. She also went on a ketogenic diet for two weeks, with no changes in seizure frequency. After 39 days of complex partial SE, a right hemispherotomy was performed which led to successful resolution of SRSE. Brain pathology showed only reactive gliosis. A neurological exam at discharge showed left hemiparesis involving the limbs and aphasia.

At 1-year follow-up, she remains seizure-free on LCM 400 mg/day, LEV 2000 mg/day, and CLB 40 mg/day. She still has moderate left hemiparesis with a slightly improved IQ of 70, with better scores on language scales and nonverbal reasoning.

### 3.3. Case 3

A 21-year-old, right-handed woman with mental retardation and mild right hemiparesis secondary to left hemispheric MCD was admitted to our hospital because of complex partial SE. She was the product of a normal pregnancy and delivery. She started with myoclonias during her first day of life and later developed flexor spasms. At the age of 8 years, she evolved with dyscognitive focal seizures characterized by

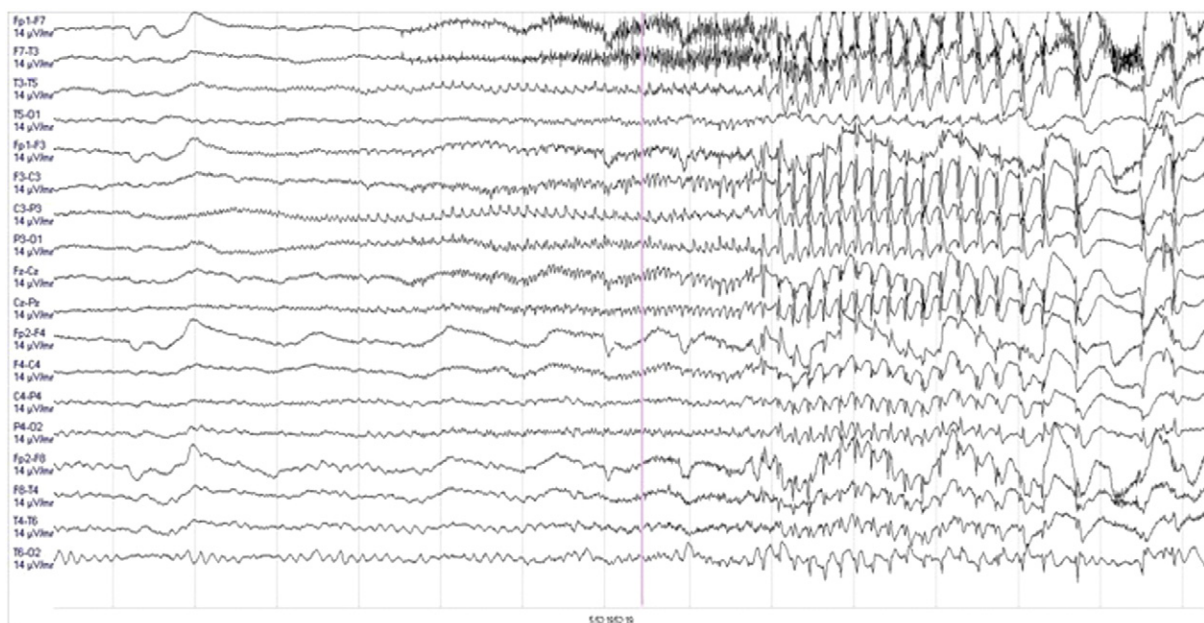


Fig. 1. Case 2. SEEG evaluation: Ictal pattern arising from the amygdala and hippocampus.

**Table 1**  
Surgical treatment of focal symptomatic refractory status epilepticus. Summary of the findings.

Use of invasive EEG	Surgery	Pathology	Morbidity	Follow-up duration	Permanent deficit
Yes	T cortisectomy	MCD	Hemorrhage during surgery	RSE resolved. One seizure per month (4 years)	No
No	Right FH	Gliosis	Hydrocephalus	RSE resolved. Seizure-free (1 year)	Left hemiparesia, mild dysphasia
No	Left FH	Focal cortical dysplasia type IIA	Urinary infection, ileus, and hypotension	RSE resolved. Seizure only during Tx rearrangements (1.5 years)	

Abbreviations: T= temporal, MCD=malformation of cortical development, RSE=refractory status epilepticus, FH=functional hemispherotomy, Tx=treatment.

the head and eyes turning to the right with slight tonic posturing of both arms lasting for 2–3 min, occurring once to twice a month.

Two months before admission, her episodes increased in frequency up to 20 per day despite treatment with LMT, LEV, CZP, PHB, PHT, and CLB. She had a partial response to VPA and CBZ. Brain MRI showed left hemispheric (with frontal predominance) polymicrogyria. An EEG showed continuous left hemispheric spike–slow wave complexes.

Two days prior to admission, she evolved with complex partial SE; she was lethargic and had bilateral isolated myoclonic jerks. She also presented recurrent brief motor seizures characterized by the head and eyes turning to the right. Continuous EEG monitoring showed the following: a) interictally: independent bifrontal spike/polyspike and wave complexes and b) ictally: frequent left frontal paroxysmal fast activity. Routine laboratory and CSF analysis were unremarkable. A second brain MRI showed, apart from left MCD, restricted diffusion in the left frontal lobe. The patient received a loading dose of intravenous VPA with partial response. Coma was induced with MDZ, but seizures recurred after tapering. Afterwards, thiopental (3.5 g/24 h) was started, with good seizure control, but it had to be discontinued because of side effects such as paralytic ileus and hypotension. Finally, ketamine (90 µg/kg/min) was administered, with adequate clinical response; however, continuous interictal epileptiform discharges persisted. At this point, in view of the convergence of clinical semiology, structural–functional imaging studies, and the EEG recording, it was decided to perform a left functional hemispherotomy on day 20 of intensive care unit (ICU) hospitalization. This led to complete cessation of SRSE.

Brain pathology showed focal cortical dysplasia type IIA.

At 1.5-year follow-up, she has a right hemiparesis. She had only two seizures during medication adjustments. Her current medications are PHT and PHB (Table 1).

#### 4. Discussion

While guidelines exist for the initial management of SE, the optimal management of RSE and SRSE is less clear. These cases highlight several points with regard to surgical treatment of SE.

First is the optimal timing for surgery. It has been reported in a range between 8 days and 10 weeks from SE onset [4]. However, numerous studies indicate that the outcome of late surgical treatment (after more than 30 ICU days) has been disappointing mainly because of the accumulating morbidity due to prolonged hospitalization [4,7]. Some authors have suggested evaluating surgery plausibility after two weeks of medical treatment failure [4,7]. Cases 1 and 3 show the efficacy of early surgical intervention (before 30 ICU days) in RSE and SRSE, respectively. In Case 2, surgery was performed on 39th ICU day, also with a favorable outcome.

Secondly, while the benefits of surgery in SE have been reported in diverse etiologies, it seems that MCD is the pathology most benefited by this therapeutic procedure [4]. Our series is too small to draw conclusions at this point. However, in all patients, surgery was successful in the treatment of SE regardless of etiology (Cases 1 and 3: MCD and Case 2: right parietal and occipital atrophy secondary to Parry Romberg syndrome).

Thirdly, there is also a great variability in the age of patients undergoing surgery for SE. In our limited experience, both adults and children could be good candidates for surgical treatment of SE.

Finally, various surgical procedures have been used to treat RSE and SRSE: focal resection, lobar or multilobar resections, and hemispherectomy (functional, anatomical, and/or modified). Also, corpus callosotomy, multiple subpial transection, vagal nerve stimulator implantation, and low-frequency repetitive cortical electrical stimulation have been described [4]. Criteria to select a patient for surgery should include the following: 1 – failure of usual treatment protocols for SE and 2 – defined epileptogenic zone (EZ) by EEG, semiology, and structural and functional imaging studies [4]. In patients with hemispheric lesions, clear lateralized semiology and EEG findings and disconnection procedures, such as hemispherectomy, represent a good strategy. On the other hand, in patients with a nonlesional SE and/or with a poorly defined EZ, invasive EEG monitoring should be considered. Most of the cases reported required intraoperative ECOG evaluation to delineate the EZ and/or tailor the extension of resection and/or perform functional motor mapping [3,4,7]. We report our experience with functional hemispherectomy and the first focal temporal cortisectomy guided by SEEG during SER, which, to our knowledge, is the first case of surgical treatment of RSE using chronic SEEG evaluation reported.

In regard to seizure control, all of our patients had resolution of RSE. Drug-induced coma was stopped in two patients. As of this writing, their seizure control and quality of life are continuously improving.

#### 5. Conclusion

Epilepsy surgery is a valuable therapeutic option in RSE and SRSE in children and adults with a defined EZ or at least lateralized seizure semiology with EEG correlation associated with hemispheric structural lesions. Surgery should be considered in all cases of RSE and SRSE early in the course of the evolution of the disease. Further studies are required to establish the optimal timing and type of invasive evaluation required. To our knowledge, we report the first case of surgical treatment of RSE using SEEG evaluation.

#### Conflict of interest

The authors have no conflict of interest to declare.

#### References

- [1] Mayer SA, Claassen J, Lokin J, Mendelsohn F, Dennis LJ, Fitzsimmons BF. Refractory status epilepticus. Frequency, risk factors, impact and outcome. *Arch Neurol* 2002; 59(2):205–10.
- [2] Shorvon S, Ferlisi M. The treatment of super-refractory status epilepticus: a critical review of available therapies and a clinical treatment protocol. *Brain* 2011;134(Pt 10): 2802–18.
- [3] Ma X, Liporace J, O'Connor MJ, Sperling MR. Neurosurgical treatment of medically intractable status epilepticus. *Epilepsy Res* 2001;46(1):33–8.
- [4] Lhatoo SD, Alexopoulos AV. The surgical treatment of status epilepticus. *Epilepsia* 2007;48(8):61–5.
- [5] Duane DC, Ng YT, Rekeate HL, Chung S, Bodensteiner JB, Kerrigan JF, et al. Treatment of refractory status epilepticus with hemispherectomy. *Epilepsia* 2004; 45(8):1001–4.
- [6] Alexopoulos A, Lachhwani DK, Gupta A, Kotagal P, Harrison AM, Bingaman W, et al. Resective surgery to treat refractory status epilepticus in children with focal epileptogenesis. *Neurology* 2005(3):567–70 8;64.
- [7] Costello DJ, Simon MV, Eskandar EN, Frosch MP, Henninger HL, Chiappa KH, et al. Efficacy of surgical treatment of de novo, adult-onset, cryptogenic, refractory focal status epilepticus. *Arch Neurol* 2006;63(6):895–901.