

CORRECTION

Open Access



Correction to: Early versus late intramedullary nailing for traumatic femur fracture management: meta-analysis

Ayman El-Menyar^{1,2,3*}, Mohammed Muneer⁴, David Samson¹, Hassan Al-Thani⁵, Ahmad Alobaidi⁶, Paul Mussleman⁷ and Rifat Latifi⁸

Correction

Following the publication of this article [1], the authors reported that they had submitted an incorrect version of Figs. 2, 3 and 4. They apologize for this error and the correct versions of Figs. 2, 3 and 4 with captions have been included in this Correction. There is a typographical error in the following sentence: Two retrospective cohort studies reported results on any and all complications [23, 30]. The correct version of this sentence is: Two retrospective cohort studies reported results on any complication [24, 34].

Author details

¹Department of Surgery Clinical Research Unit, Westchester Medical Center Health Network, Valhalla, NY, USA. ²Trauma Surgery, Clinical Research, Hamad General Hospital, Doha, Qatar. ³Clinical Medicine, Weill Cornell Medical School, Doha, Qatar. ⁴Department of Surgery, Hamad General Hospital, Doha, Qatar. ⁵Department of Surgery, Trauma and Vascular Surgery, Hamad General Hospital, Doha, Qatar. ⁶Department of Surgery, Orthopedic Surgery, Al Wakrah Hospital, Doha, Qatar. ⁷Distributed eLibrary, Weill Cornell Medical School, Doha, Qatar. ⁸Department of Surgery, Westchester Medical Center Health Network and New York Medical College, Valhalla, NY, USA.

Received: 5 July 2018 Accepted: 6 July 2018

Published online: 24 July 2018

Reference

1. El-Menyar, et al. Early versus late intramedullary nailing for traumatic femur fracture management: meta-analysis. *J Orthop Surg Res.* 2018;13:160. <https://doi.org/10.1186/s13018-018-0856-4>.

* Correspondence: aymanco65@yahoo.com

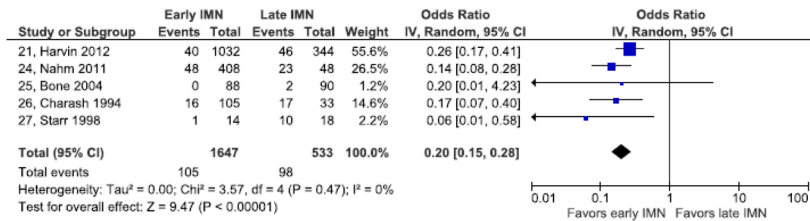
¹Department of Surgery Clinical Research Unit, Westchester Medical Center Health Network, Valhalla, NY, USA

²Trauma Surgery, Clinical Research, Hamad General Hospital, Doha, Qatar

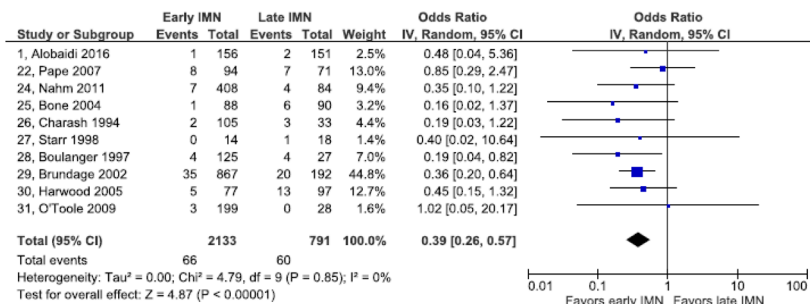
Full list of author information is available at the end of the article



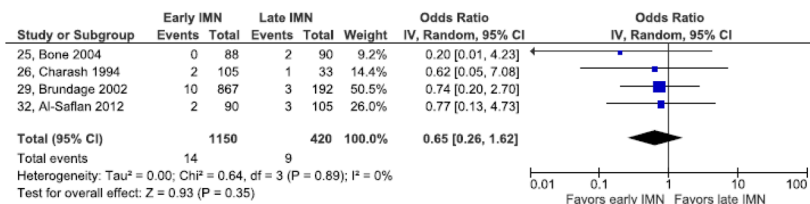
a) Pulmonary complications



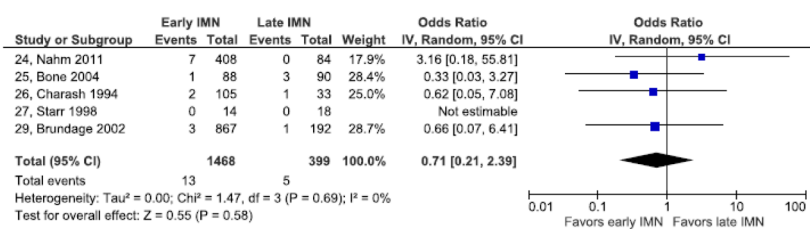
b) Acute respiratory distress syndrome



c) Fat embolism



d) Pulmonary embolism



e) Pneumonia

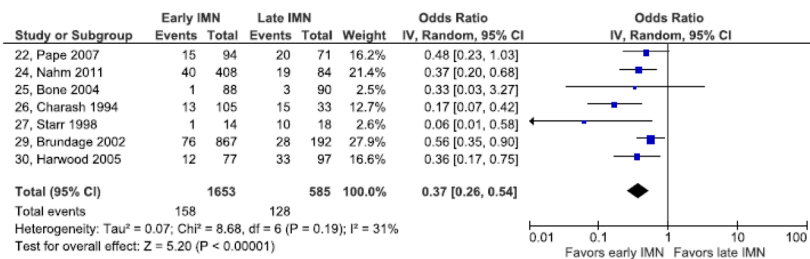
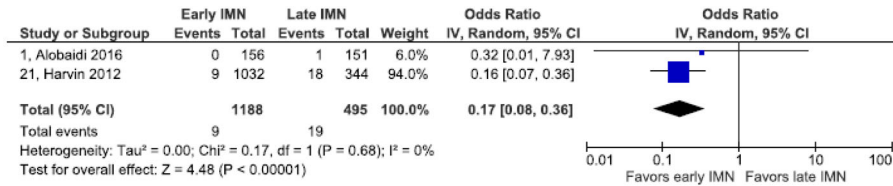
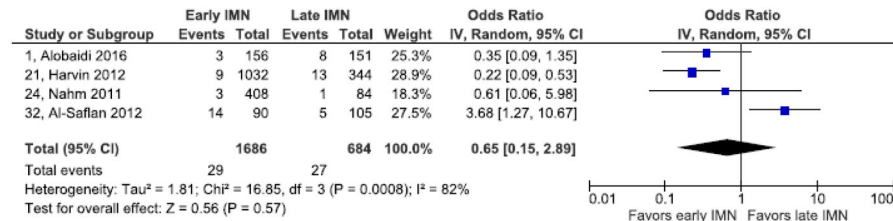


Fig. 2 Forest plot of pulmonary complications. **a** Pulmonary complications. **b** Acute respiratory distress syndrome. **c** Fat embolism. **d** pulmonary embolism. **e** Pneumonia

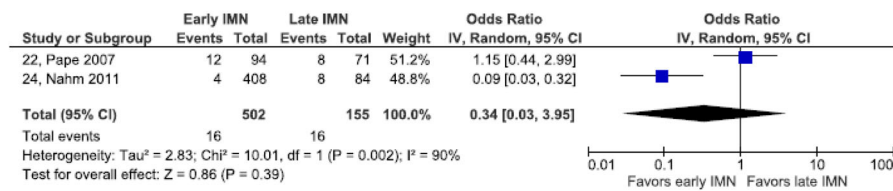
a) Decubitus ulcers



b) Wound infection



c) Sepsis



d) Deep vein thrombosis

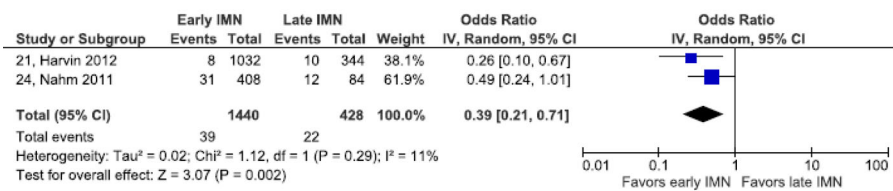
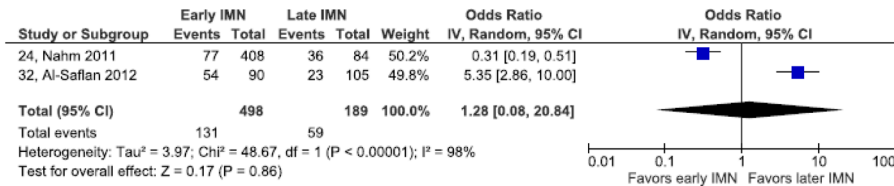
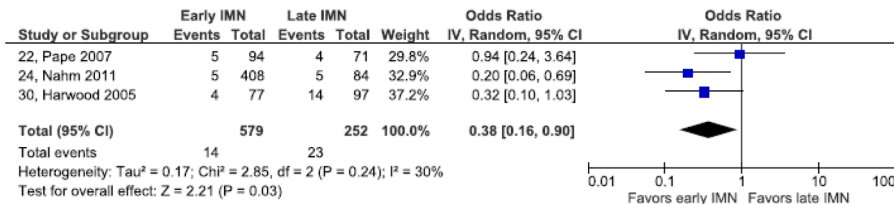


Fig. 3 Forest plots of cutaneous, infectious and venous complications: **a** decubitus ulcers. **b** wound infection. **c** sepsis. **d** deep vein thrombosis

a) Any complication



b) Multiorgan failure



c) Mortality

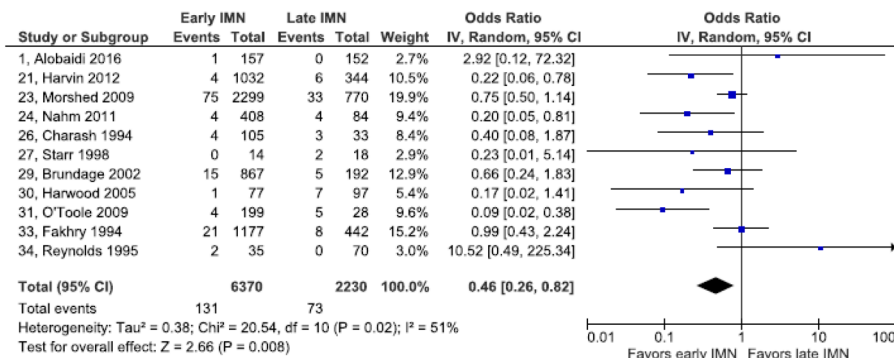


Fig. 4 Forest plots of other complications: a. Any complication. b multiorgan failure c. mortality