

Clinical Article

Minimum 3-Year Outcomes in Patients with Lumbar Spinal Stenosis after Bilateral Microdecompression by Unilateral or Bilateral Laminotomy

Sang-Mi Yang, M.D., Hyung-Ki Park, M.D., Ph.D., Jae-chil Chang, M.D., Ph.D., Ra-Sun Kim, M.D., Sukh-Que Park, M.D., Ph.D., Sung-Jin Cho, M.D., Ph.D.

Department of Neurosurgery, College of Medicine, Soonchunhyang University, Seoul, Korea

Objective : Lumbar spine stenosis (LSS) can result in symptomatic compression of the neural elements, requiring surgical treatment if conservative management fails. Minimally invasive surgery has come to be more commonly used for the treatment of LSS. The current study describes outcomes of bilateral microdecompression by unilateral or bilateral laminotomy (BML) for degenerative LSS after a minimum follow-up period of 3 years and investigates factors that result in a poor outcome.

Methods : Twenty-one patients who were followed-up for at least 3 years were included in this study. For clinical evaluation, the Japanese Orthopedic Association (JOA) scoring system for low back pain was used. The modified grading system of Finneson and Cooper was used for outcome assessment. Radiographic evaluation was also performed for spondylolisthesis, sagittal rotation angle, and disc height.

Results : Twenty-one patients (10 men, 11 women) aged 53-82 years (64.1 ± 8.9 years) were followed-up for a minimum of 3 years (36-69 months). During follow-up, two patients underwent reoperation. Average preoperative JOA score and clinical symptoms, except persistent low back pain, improved significantly at the latest follow-up. There were no significant differences in radiological findings preoperatively and postoperatively. Thirteen patients (61.9%) had excellent to fair outcomes.

Conclusion : BML resulted in a favorable and persistent outcome for patients with degenerative LSS without radiological instability over a mid-term follow-up period. Persistent low back pain unrelated to postoperative instability adversely affects mid-term outcomes.

Key Words : Minimally invasive · Lumbar stenosis · Laminotomy · Midterm · Outcomes.

INTRODUCTION

Lumbar spine stenosis (LSS) can result in symptomatic compression of the neural elements, requiring surgical treatment if conservative management fails. Decompressive laminectomy is widely used to treat LSS. Although satisfactory surgical outcomes have been reported using this technique, instability following the procedure is one of the greatest concerns amongst surgeons as it may cause deterioration of symptoms³³. The following factors are known to be essential for a good clinical outcome : sufficient dural and nerve root decompression, minimum resection of facet joints to maintain spinal stability, early surgical intervention before severe paralysis becomes apparent, postoperative application of hard orthotics for at least 3 months, and

postoperative trunk muscle exercises⁹.

Minimally invasive surgery using microsurgical or endoscopic procedures has come to be more commonly used for the treatment of LSS over the last decade. The goal of these procedures is maximal preservation of structural components such as mid-line structures, facet joints, and paravertebral muscle to prevent postoperative instability. It has been hypothesized that these techniques yield better clinical outcomes by reducing tissue trauma and preserving spinal architecture, but only limited follow-up data exist to confirm this hypothesis²².

In the current study, we describe the outcomes after at least 3 years of follow-up of patients who underwent bilateral microdecompression by unilateral or bilateral laminotomy (BML) for degenerative LSS and we investigate factors that resulted in

• Received : April 2, 2013 • Revised : August 16, 2013 • Accepted : September 8, 2013

• Address for reprints : Hyung-Ki Park, M.D., Ph.D.

Department of Neurosurgery, College of Medicine, Soonchunhyang University, 22 Daesagwan-gil, Yongsan-gu, Seoul 140-743, Korea
Tel : +82-2-709-9268, Fax : +82-2-792-5976, E-mail : phk007@schmc.ac.kr

• This is an Open Access article distributed under the terms of the Creative Commons Attribution Non-Commercial License (<http://creativecommons.org/licenses/by-nc/3.0>) which permits unrestricted non-commercial use, distribution, and reproduction in any medium, provided the original work is properly cited.

poor outcomes.

MATERIALS AND METHODS

Patients

Twenty-one patients were operated on by one author who were followed-up for a minimum of 3-years were included in this study. Twenty-eight patients underwent BML without fusion procedures by one author from 2007 through 2009. Seven patients were not followed-up because of inability to locate new addresses (4 cases), and death due to malignant tumor, heart disease, or stroke (3 cases). The diagnosis of LSS was based on clinical symptoms such as low back pain, leg pain, numbness during standing or walking, and intermittent claudication. In all patients, stenotic spinal lesions were confirmed by magnetic resonance imaging scans. Clinical indications for BML were leg pain and/or leg numbness inducing intermittent claudication (>6 weeks) rather than back pain. Furthermore, this procedure was preferentially considered over fusion surgery in older patients and those with comorbidities, regardless of persistent back pain. Radiologic indications for use of this surgical procedure were LSS without instability and foraminal stenosis excluding degenerative lumbar spondylolisthesis (≥ 3 mm on the lateral neutral radiograph), and degenerative lumbar scoliosis (Cobb's angle : $\geq 25^\circ$).

Operative technique

BML was modified from the previously reported unilateral approach method for bilateral decompression (ULBD)^{35,37}. Laminotomy was performed on the contralateral side for lateral recess stenosis to preserve as much of the facet joints as possible. If there was bilateral lateral recess stenosis, laminotomy was performed on both sides. A paramedian or midline linear skin incision of approximately 3 cm was made. The latissimus dorsi and the multifidus muscle from one side were stripped from their attachments, the interlaminar space exposed, and a Cas-

par retractor applied. Under a surgical microscope, the upper and lower laminae were partially removed in the area of the ligamentum flavum insertion. The basal part of the spinous process of the caudal half of the cranial lamina and a small cranial portion of the caudal lamina were removed with a high speed drill. Then the contralateral lamina was undercut with a high-speed air drill leaving the ligamentum flavum in place as protection for the dural sac and the nerve root. Following sufficient resection of the bony segment, the ligamentum flavum was removed en bloc with a curette. With recognition of the inner aspect of the pedicle on the contralateral side, we confirmed adequate decompression of the contralateral side. If the ipsilateral lateral recess needed to be decompressed, we performed an additional contralateral laminotomy for adequate decompression of the ipsilateral side. Concomitant discectomy was not performed except in patients with apparent disc herniation, because preservation of the anterior stabilizer of the spinal column was considered desirable at laminectomy. The average surgical time was 50 minutes for one segmental decompression, and average intraoperative blood loss was less than 50 cc per one level. Patients were generally allowed to walk with a corset brace within 3 days of surgery, and corset brace use was recommended for 4-6 weeks. Rehabilitation was not recommended (Fig. 1).

Clinical evaluation

We used the Japanese Orthopedic Association scoring system for low back pain (JOA score) (Table 1) for clinical evaluation. Preoperative clinical evaluation data and JOA scores were obtained from medical charts, and postoperative final scores were obtained by data collection and telephone interviews. Patients were asked about current status, subjective improvement in symptoms, satisfaction with the surgical procedure and operative results, associated medical conditions, and current therapy. The modified grading system devised by Finneson and Cooper⁵ was used to assess outcomes (Table 2). Ratings of excellent, good, and fair were classified as successful operative results.

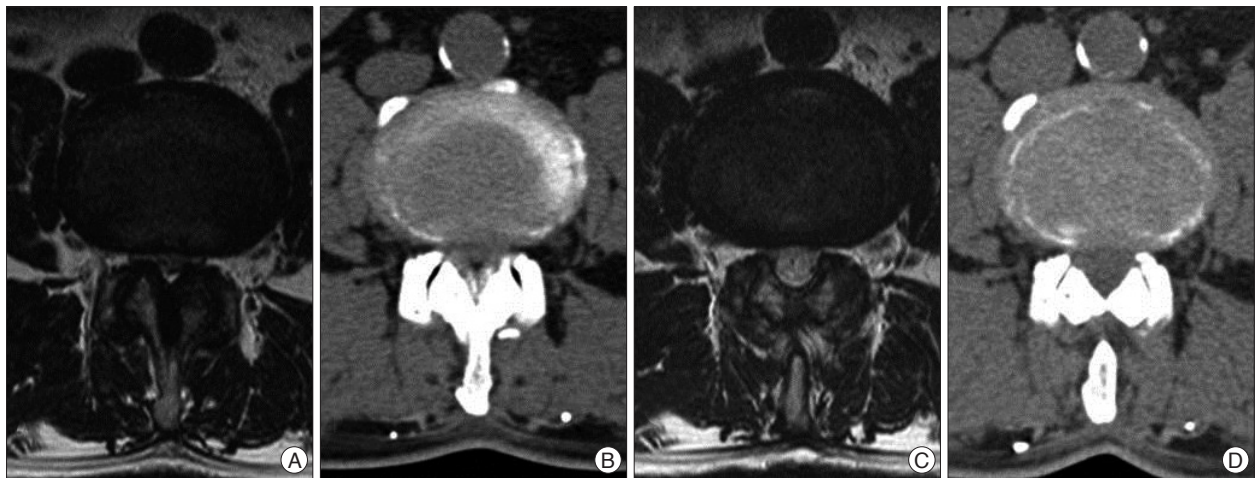


Fig. 1. At the L4/5 level, preoperative axial T2-weighted (A) and CT (B) images show spinal stenosis. Postoperative axial T2-weighted (C) and CT (D) images show the spinal canal decompressed by bilateral laminotomy.

Table 1. Japanese Orthopedic Association scoring system for low back pain

Subjectives	Low back pain	None	3
		Occasionally mild	2
		Always present or sometimes severe	1
		Always severe	0
	Leg pain and/or numbness	None	3
		Occasionally mild	2
		Always present or sometimes severe	1
		Always severe	0
	Walking ability	Normal walking	3
		Able to walk longer than 500 m, pain/numbness/weakness present	2
		Unable to walk 500 m due to pain/numbness/weakness	1
		Unable to walk 100 m due to pain/numbness/weakness	0
Objectives	Straight leg raising	Normal (over 70°)	2
		30 to 70°	1
		Less than 30°	0
	Sensory function	Normal	2
		Mild sensory loss, not recognized by patient	1
		Apparent sensory loss	0
	Motor function	Normal (MMT : normal)	2
		Slight motor loss (MMT : good)	1
		Apparent motor loss (MMT : less than fair)	0

MMT : manual muscle testing

Table 2. Patient outcomes after mid-term follow-up based on the rating scale of Finneson and Cooper

Rating	Definition	No. of patients (n=21)
Excellent	Pain free and able to function well	4 (19.0%)
Good	Pain improved and able to function well	4 (19.0%)
Fair	Pain improved, but occasional medication and time off from activities	5 (24.0%)
Marginal	Pain improved, but considerable discomfort that requires frequent medication and time off from activities	4 (19.0%)
Poor	Pain unimproved or worse	4 (19.0%)

Radiographic evaluation

Radiographic examination was performed by one of the authors without knowledge of the clinical features of 19 patients for whom both pre- and postoperative radiographs were available. Evaluations were also performed independent of clinical assessment. Measurements to determine spondylolisthesis and the sagittal rotation angle were done in operated segments⁹. Disc heights were measured on a lateral radiograph with identification of the following points : a-anterior disc height, b-middle disc height, c-posterior disc height. Disc height was calculated as the mean of the anterior, middle, and posterior disc heights¹⁰.

Statistical analysis

SPSS version 12.0 statistical package (SPSS Inc., Chicago, IL, USA) was utilized for statistical analyses. Data are presented as means±standard deviations. *p*-values less than 0.05 were considered statistically significant. The paired t-test was used to analyze the significance of differences between the JOA score and radiological measurements pre-operatively and at the latest

postoperative follow-up (>3 years), and Fisher's exact test was used to analyze the significance of clinical improvements from the preoperative period to the latest postoperative follow-up (>3 years).

RESULTS

Demographic data

Twenty-one patients (10 men, 11 women) aged 53-82 years (64.1±8.9 years) at index surgery were followed-up for a minimum of 3 years. The average follow-up period was 50.2±10.1 months (range, 36-69 months). Ten patients had primary symptoms of intermittent claudication with bilateral leg numbness and pain. Nine patients had persistent leg pain. Persistent low back pain continuing for more than one month was also found in 10 patients. Manual muscle testing identified apparent motor deficits at less than a fair level in seven patients, including one with complete drop foot (Table 3, 4). Sixteen patients (76.2%) underwent single level surgery, and five patients (23.8%) un-

derwent two-level surgery. The level of surgery was L2-L3 in three patients, L3-L4 in eight patients, L4-L5 in 14 patients, and L5-S1 in one patient (Table 3). Comorbidity was high. Eighteen patients (85.7%) had multiple medical problems, including hypertension (9; 42.9%), diabetes mellitus (9; 42.9%), heart disease (3; 14.3%), chronic renal failure (2; 9.5%), and hypothyroidism (1; 4.8%). Only three patients (14.3%) had no evidence of a concomitant health problem (Table 3).

Clinical outcome

Two of 21 patients underwent reoperation. A 55-year-old male patient had a fusion operation due to foraminal stenosis on the same level 4 months after decompression surgery. A 57-year-old male patient had a fusion operation at the same level due to intractable low back pain 34 months after surgery.

Four patients had excellent outcomes (19.0%), four patients had good outcomes (19.0%), five patients had fair outcomes (24.0%), four patients had marginal outcomes (19.0%), and four patients had poor outcomes (19.0%) at evaluation on the latest follow-up. Thirteen patients (61.9%) had excellent to fair outcomes (Table 2).

The average preoperative JOA score (total points, 15) for all patients was 6.7 ± 1.8 points. It improved to 10.9 ± 1.6 points at 1 year after surgery, and then decreased to 9.2 ± 2.0 points at the latest follow-up (>3 years) ($p=0.001$) (Fig. 2).

The number of patients who reported persistent low back pain continuing for more than one month increased slightly from 10 to 12 after surgery ($p=0.74$). In contrast, the number of patients with persistent leg pain decreased from nine to two ($p=0.029$). The number of patients with neurogenic claudication decreased from 10 before surgery to two after surgery ($p=0.013$). Seven patients with apparent motor deficits recovered well, but one patient did not show any improvement ($p=0.042$) (Table 4).

Radiological outcome

Preoperative anterior slippage ranged from -3 to 2 mm, with a mean of 0.6 ± 0.7 mm. The anterior slippage at the latest follow-up ranged from 0 to 5 mm, with a mean of 1.1 ± 1.4 mm. Asymptomatic progression (>3 mm) in anterior slippage after this surgical procedure was observed in one patient. There were no significant differences in progression of anterior slippage among these diseases ($p=0.12$). The preoperative sagittal angle was $9.6 \pm 2.3^\circ$ and progressed slightly to $10.5 \pm 2.8^\circ$ at the latest follow-up ($p=0.23$). Preoperative disc height was 11.2 ± 2.5 mm and decreased slightly to 10.4 ± 2.7 mm at the latest follow-up after surgery ($p=0.29$) (Table 5).

Surgical-related complications

During the follow-up period, two patients underwent subsequent lumbar surgery. Reoperations consisted of spinal fusion to treat foraminal stenosis and secondary lumbar instability inducing persistent low back pain. We observed two surgical-related complications (10.5%); superficial disturbance of wound

healing ($n=1$) and deep wound infection ($n=1$). Both of these patients recovered without sequelae.

DISCUSSION

Bilateral microdecompression by laminotomy

Unilateral or bilateral laminotomy for decompression of LSS was introduced in 1981 by Getty et al.⁷ as a less invasive surgical option. Microsurgical bilateral decompression via a unilateral approach was first described by Poletti²⁵. More recently, ULBD initially described by Young et al.³⁷ in 1988, was modified by McCulloch¹⁸ and has been successfully used and subsequently modified as a minimally invasive unilateral approach for bilateral decompression^{17,23,25,28-30,35}. Nakanishi et al.²¹ reported microsurgical lumbar flavectomy that preserves facet joints in cases of lumbar degenerative spondylolisthesis. Comparable results (improvement rates of 59% to 91% after laminotomy) have been reported by other authors for a mean follow-up peri-

Table 3. Patients demographics

Average age (years)	64.1±8.9 (53-82)
Sex	10 men, 11 women
Average follow-up (months)	50.2±10.1 (36-69)
No. levels decompressed (%)	
1 level	16 (76.2)
2 level	5 (23.8)
Level (%)	
L2-L3	3 (11.5)
L3-L4	8 (30.8)
L4-L5	14 (53.8)
L5-S1	1 (3.9)
Comorbidity (%)	18 (85.7)
Hypertension	9 (42.9)
DM	9 (42.9)
Heart disease	3 (14.3)
CRF	2 (9.5)
Hypothyroidism	1 (4.8)

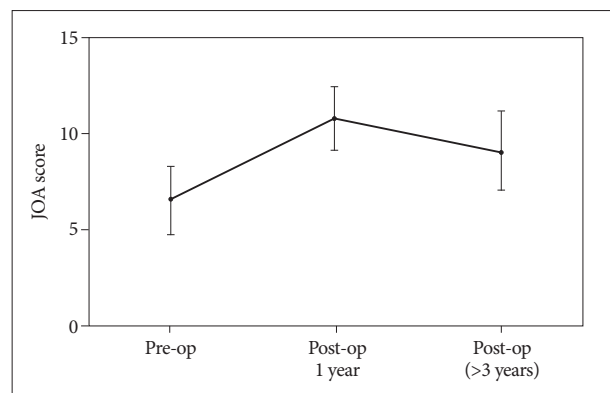


Fig. 2. Average preoperative and postoperative JOA scores. JOA scores improved 1 year after the operation and slightly decreased at the last follow-up (>3 years). JOA : Japanese Orthopedic Association.

Table 4. Clinical evaluation preoperatively and the latest follow-up

	Preoperative (%)	Latest follow up (%)	Significance (Fisher's exact test)
Persistent low back pain	10 (52.6)	12 (63.1)	0.74
Persistent leg pain	9 (47.4)	2 (10.5)	0.029
Neurogenic claudication	10 (52.6)	2 (10.5)	0.013
Apparent motor weakness	7 (36.8)	1 (5.3)	0.042

Table 5. Radiologic evaluation preoperatively and at the latest follow-up

	Preoperative	Latest follow up	Significance
Anterior slippage	0.6±0.7 mm	1.1±1.4 mm	0.12
Sagittal angle	9.6±2.3°	10.5±2.8°	0.23
Disc height	11.2±2.5 mm	10.4±2.7 mm	0.29

od of up to 5.5 years^{1,7,14,15,18,20,28,37}.

Laminotomy vs. laminectomy

Laminectomy entails removal of the entire spinous process, the laminae, and the adjacent supra- and interspinous ligaments in addition to the ligamentum flavum and as much as half of each facet complex. Laminotomy involves partial removal of bone from the inferior aspect of one lamina and the superior aspect of the subjacent lamina, excision of the ligamentum flavum, and as much as one-half of the facet, with preservation of the spinous process and supra- and interspinous ligaments³¹. Only a few series have directly compared laminotomy with laminectomy^{26,27,31}. With success rates of 50% and 58% for laminotomy versus laminectomy, respectively, Thomas et al.³¹ reported no significant differences in clinical outcome and postoperative instability between these different techniques. However, with 14 and 12 patients in each group and a mean follow-up period of 3.1 years, the patient population was small, and the follow-up period was short. Postacchini et al.²⁶ compared the clinical results and postoperative stability of 41 patients treated by laminectomy with those of 26 patients who underwent bilateral laminotomy after a mean follow-up period of 3.7 years. Spinal instability was more frequent after laminectomy than after laminotomy, whereas the clinical results were comparable (78% vs. 81% good outcomes, respectively). Rompe et al.²⁷ evaluated the results of 117 patients treated either by laminotomy, laminectomy alone, or laminectomy plus instrumented fusion (mean follow-up interval, 8 years). The rate of good outcomes after laminotomy (36%) was better than that after laminectomy alone (31%). These findings indicate that compared with laminectomy, laminotomy can adequately decompress LSS, and that laminectomy may be too aggressive for adequate preservation of spinal stability. Johnsson et al.¹¹ reported postoperative slippage in 18 of 45 patients (40%) who underwent a laminectomy. In their study, 65% of patients with degenerative spondylolisthesis exhibited a high risk of further slippage after operation and 20% of patients with LSS exhibited additional slippage. Mardjetko et al.¹⁶ reviewed the incidence of progression of slippage after decompression and reported it to be 31%. In some cases,

spinal fusion combined with adequate decompression is therefore required. To sum up these reports, laminotomy showed results in superior than laminectomy in clinical and radiological outcomes to laminectomy.

Laminotomy and postoperative instability

A randomized trial and a study with alternating treatment assignments revealed better outcomes after decompression plus fusion than conventional decompression alone^{6,8}. However, these

studies evaluated patients with degenerative spondylolisthesis with LSS. Surgical decompression may lead to increased rates of spondylolisthesis postoperatively. In patients without preoperative spondylolisthesis, the rate of progressive postoperative spondylolisthesis can be as high as 31%, and in patients with preoperative spondylolisthesis, the incidence of progressive slipping after surgery is even higher, ranging from 30 to 100%^{12,22}. Some authors have suggested that patients treated with spinal fusion have a higher likelihood of greater blood loss, a longer operative time, and a higher rate of complications, and thus require more extensive revision surgery, than patients treated by surgical decompression alone³³. Thus, decompression surgery without fusion with clinical outcomes equivalent to those of conventional decompression surgery, but less postoperative instability, is desirable³³. Recently, Oertel et al.²² demonstrated that in patients treated by ULBD, no postoperative increase of instability should be expected, even in cases with pre-operative fixed spondylolisthesis. Müslüman et al.¹⁹ reported that neutral and dynamic slip percentages did not change significantly in patients with Grade I degenerative spondylolisthesis after ULBD. These authors suggested spondylolisthesis in itself is not an indication for fusion. Costa et al.⁴ reported that 87.9% of 374 patients experienced clinical benefits and only 8% of patients suffered from segmental instability at the treated level after a mean follow-up duration of 30.3 months (range, 16-53 months). In the present study, no patient showed instability in the preoperative radiological study and with the exception of two patients that underwent reoperation, only one patient showed evidence of asymptomatic spondylolisthesis 3 years after surgery. We found little progression of spinal slippage after BML over a minimum of 3-years of follow-up. Less radiographic changes were observed after this procedure than reported for LSS after decompression.

Outcomes

Tsai et al.³⁴ reported clinical results after microscopic laminotomy based on a retrospective study. After a mean follow-up period of 2.25 years, 84% of 50 patients showed good postoperative results. McCulloch¹⁸ developed unilateral laminotomy for

bilateral ligamentectomy and reported a satisfactory outcome in 76% of 22 patients with degenerative LSS. Weiner et al.³⁵⁾ investigated outcomes of limited osteoplastic laminectomy with spinous process osteotomy preserving the midline osseo-ligamentous structures, and found high rates of satisfaction in 87% of patients at the 9-month follow-up. Thomé et al.³²⁾ reported that clinical outcomes after ULBD were equivalent to those obtained with conventional laminectomy after a minimum follow-up of 12 months. Oertel et al.²²⁾ reported that 85.3% of 102 patients had excellent to fair surgical results over 4 to 10 years (mean, 5.6 years) of follow-up, with a reoperation rate of 11.8%. Cavuşoğlu et al.³⁾ reported good results in 68% of patients at 4 years and noted that reoperation was not required for recurrent spinal stenosis at the same segments within 4 to 7 years. Toyoda et al.³³⁾ evaluated clinical outcome and radiographic changes for LSS including degenerative spondylolisthesis and scoliosis over a minimum 5-year follow-up. They reported that ULBD yielded satisfactory surgical outcomes.

We showed in the present study that 61.9% of 21 patients had excellent to fair results 3 years after surgery, while two patients (9.5%) required reoperation. Persistent low back pain at the latest follow-up in some patients resulted in poor outcome scores, even though there were significant clinical improvements in the other clinical symptoms of persistent leg pain, neurogenic claudication, and apparent motor weakness. In comparison with interbody fusion, a major concern after decompression is the recurrence of low back pain because of secondary instability. However, only a few of our patients showed vertebral hypermobility or a significant increase in spondylolisthesis after surgery. Spine-related adverse events such as osteoporosis, postsurgical clinical instability, and extensive multilevel surgery are known to adversely affect medium- and long-term outcomes²⁴⁾. We demonstrated that persistent back pain was not related to radiological instability. We hypothesize that the causes of persistent low back pain are aging or aggravated osteoporosis and degeneration of disk and facet joints post-operatively. Another possible cause may be that BML was preferentially considered over fusion in older patients and/or those with comorbidities.

Complications

Based on a multicentric study of 270 patients with degenerative lumbar stenosis who were stabilized with or without instrumentation, Weinstein et al.³⁶⁾ reported a dural tear incidence of 10% and a reoperation rate of 12% in the second year as well as a death rate of 1% and a wound infection incidence of 3.5%. Oertel et al.²²⁾ reported that the incidence of complications related to unilateral laminotomy was 9.8%. These complications included incidental durotomy, disturbance of wound healing, and deep wound infection. In the present study, there were two surgical-related complications (10.5%); superficial disturbance of wound healing and deep wound infection without mortality. Despite the high preoperative comorbidity, we did not experience complications related to the coexisting medical diseases,

which could be interpreted as an advantage of microdecompression by laminotomy.

In our present series, two patients (9.5%) underwent subsequent lumbar surgery. Reoperations consisted of spinal fusion to treat foraminal stenosis and secondary lumbar instability inducing persistent low back pain. Oertel et al.²²⁾ reported a reoperation rate of 11.8% due to complication, restenosis, and spinal instability. Toyoda et al.³³⁾ reported a reoperation rate of 0% for LSS, 10% for degenerative spondylolisthesis, and 25% for degenerative scoliosis. The mean rate of reoperation was 7.0%. Katz et al.¹³⁾ reported that 23% of patients who underwent conventional decompressive surgery had a reoperation over a 7 to 10 year follow-up period. Iguchi et al.⁹⁾ reported that three of 37 patients (8.1%) who underwent decompression alone with a longer than 10-year follow-up required additional surgery because of disc herniation at segments subjected to laminectomy. Atlas et al.²⁾ found that 23% of patients who underwent decompression alone required at least 1 additional lumbar spine operation within 10 years after their original procedure. Our reoperation rate is consistent with those reported in previous studies.

Study limitations

This study has several limitations. First, this was a retrospective study without any control group. Second, indications for the surgical procedure were limited to patients without degenerative spondylolisthesis and scoliosis. Third, fewer patients were evaluated in this study than in some of the previous studies. Fourth, BML was preferentially considered over fusion surgery in older patients or those with comorbidities, even in patients with persistent back pain. This bias may have affected the outcomes of our study.

CONCLUSION

BML provided favorable and persistent outcomes in patients with degenerative LSS without radiological instability over a mid-term follow-up period. Persistent low back pain unrelated to postoperative instability adversely affected mid-term outcomes.

• Acknowledgements

This work was supported by the Soonchunhyang University Research Fund.

References

1. Aryanpur J, Ducker T : Multilevel lumbar laminotomies : an alternative to laminectomy in the treatment of lumbar stenosis. *Neurosurgery* 26 : 429-432; discussion 433, 1990
2. Atlas SJ, Keller RB, Wu YA, Deyo RA, Singer DE : Long-term outcomes of surgical and nonsurgical management of lumbar spinal stenosis : 8 to 10 year results from the maine lumbar spine study. *Spine (Phila Pa 1976)* 30 : 936-943, 2005
3. Cavuşoğlu H, Kaya RA, Türkmenoglu ON, Tuncer C, Colak I, Aydın Y : Midterm outcome after unilateral approach for bilateral decompression of lumbar spinal stenosis : 5-year prospective study. *Eur Spine J* 16 :

- 2133-2142, 2007
4. Costa F, Sassi M, Cardia A, Ortolina A, De Santis A, Luccarell G, et al. : Degenerative lumbar spinal stenosis : analysis of results in a series of 374 patients treated with unilateral laminotomy for bilateral microdecompression. *J Neurosurg Spine* 7 : 579-586, 2007
 5. Finneson BE, Cooper VR : A lumbar disc surgery predictive score card. A retrospective evaluation. *Spine (Phila Pa 1976)* 4 : 141-144, 1979
 6. Fischgrund JS, Mackay M, Herkowitz HN, Brower R, Montgomery DM, Kurz LT : 1997 Volvo Award winner in clinical studies. Degenerative lumbar spondylolisthesis with spinal stenosis : a prospective, randomized study comparing decompressive laminectomy and arthrodesis with and without spinal instrumentation. *Spine (Phila Pa 1976)* 22 : 2807-2812, 1997
 7. Getty CJ, Johnson JR, Kirwan EO, Sullivan MF : Partial undercutting facetectomy for bony entrapment of the lumbar nerve root. *J Bone Joint Surg Br* 63-B : 330-335, 1981
 8. Herkowitz HN, Kurz LT : Degenerative lumbar spondylolisthesis with spinal stenosis. A prospective study comparing decompression with decompression and intertransverse process arthrodesis. *J Bone Joint Surg Am* 73 : 802-808, 1991
 9. Iguchi T, Kurihara A, Nakayama J, Sato K, Kurosaka M, Yamasaki K : Minimum 10-year outcome of decompressive laminectomy for degenerative lumbar spinal stenosis. *Spine (Phila Pa 1976)* 25 : 1754-1759, 2000
 10. Inoue H, Ohmori K, Miyasaka K, Hosoe H : Radiographic evaluation of the lumbosacral disc height. *Skeletal Radiol* 28 : 638-643, 1999
 11. Johnsson KE, Willner S, Johnsson K : Postoperative instability after decompression for lumbar spinal stenosis. *Spine (Phila Pa 1976)* 11 : 107-110, 1986
 12. Jolles BM, Porchet F, Theumann N : Surgical treatment of lumbar spinal stenosis. Five-year follow-up. *J Bone Joint Surg Br* 83 : 949-953, 2001
 13. Katz JN, Lipson SJ, Chang LC, Levine SA, Fossel AH, Liang MH : Seven- to 10-year outcome of decompressive surgery for degenerative lumbar spinal stenosis. *Spine (Phila Pa 1976)* 21 : 92-98, 1996
 14. Kleeman TJ, Hiscoe AC, Berg EE : Patient outcomes after minimally destabilizing lumbar stenosis decompression : the "Port-Hole" technique. *Spine (Phila Pa 1976)* 25 : 865-870, 2000
 15. Mackay DC, Wheelwright EF : Unilateral fenestration in the treatment of lumbar spinal stenosis. *Br J Neurosurg* 12 : 556-558, 1998
 16. Mardjetko SM, Connolly PJ, Shott S : Degenerative lumbar spondylolisthesis. A meta-analysis of literature 1970-1993. *Spine (Phila Pa 1976)* 19 (20 Suppl) : 2256S-2265S, 1994
 17. Mayer HM, List J, Korge A, Wiechert K : [Microsurgery of acquired degenerative lumbar spinal stenosis. Bilateral over-the-top decompression through unilateral approach]. *Orthopade* 32 : 889-895, 2003
 18. McCulloch JA : Microdecompression and uninstrumented single-level fusion for spinal canal stenosis with degenerative spondylolisthesis. *Spine (Phila Pa 1976)* 23 : 2243-2252, 1998
 19. Müslüman AM, Cansever T, Yılmaz A, Çavuşoğlu H, Yüce İ, Aydın Y : Midterm outcome after a microsurgical unilateral approach for bilateral decompression of lumbar degenerative spondylolisthesis. *J Neurosurg Spine* 16 : 68-76, 2012
 20. Nakai O, Ookawa A, Yamaura I : Long-term roentgenographic and functional changes in patients who were treated with wide fenestration for central lumbar stenosis. *J Bone Joint Surg Am* 73 : 1184-1191, 1991
 21. Nakanishi K, Tanaka N, Fujimoto Y, Okuda T, Kamei N, Nakamae T, et al. : Medium-term Clinical Results of Microsurgical Lumbar Flavectomy That Preserves Facet Joints in Cases of Lumbar Degenerative Spondylolisthesis : Comparison of Bilateral Laminotomy With Bilateral Decompression by a Unilateral Approach. *J Spinal Disord Tech* 26 : 351-358, 2013
 22. Oertel MF, Ryang YM, Korinath MC, Gilsbach JM, Rohde V : Long-term results of microsurgical treatment of lumbar spinal stenosis by unilateral laminotomy for bilateral decompression. *Neurosurgery* 59 : 1264-1269; discussion 1269-1270, 2006
 23. Palmer S, Turner R, Palmer R : Bilateral decompression of lumbar spinal stenosis involving a unilateral approach with microscope and tubular retractor system. *J Neurosurg* 97 (2 Suppl) : 213-217, 2002
 24. Papavero L, Thiel M, Fritzsche E, Kunze C, Westphal M, Kothe R : Lumbar spinal stenosis : prognostic factors for bilateral microsurgical decompression using a unilateral approach. *Neurosurgery* 65 (6 Suppl) : 182-187; discussion 187, 2009
 25. Poletti CE : Central lumbar stenosis caused by ligamentum flavum : unilateral laminotomy for bilateral ligamentectomy : preliminary report of two cases. *Neurosurgery* 37 : 343-347, 1995
 26. Postacchini F, Cinotti G, Perugia D, Gumina S : The surgical treatment of central lumbar stenosis. Multiple laminotomy compared with total laminectomy. *J Bone Joint Surg Br* 75 : 386-392, 1993
 27. Rompe JD, Eysel P, Zöllner J, Nafe B, Heine J : Degenerative lumbar spinal stenosis. Long-term results after undercutting decompression compared with decompressive laminectomy alone or with instrumented fusion. *Neurosurg Rev* 22 : 102-106, 1999
 28. Sanderson PL, Wood PL : Surgery for lumbar spinal stenosis in old people. *J Bone Joint Surg Br* 75 : 393-397, 1993
 29. Spetzger U, Bertalanffy H, Naujokat C, von Keyserlingk DG, Gilsbach JM : Unilateral laminotomy for bilateral decompression of lumbar spinal stenosis. Part I : anatomical and surgical considerations. *Acta Neurochir (Wien)* 139 : 392-396, 1997
 30. Spetzger U, Bertalanffy H, Reinges MH, Gilsbach JM : Unilateral laminotomy for bilateral decompression of lumbar spinal stenosis. Part II : clinical experiences. *Acta Neurochir (Wien)* 139 : 397-403, 1997
 31. Thomas NW, Rea GL, Pikul BK, Mervis LJ, Irsik R, McGregor JM : Quantitative outcome and radiographic comparisons between laminectomy and laminotomy in the treatment of acquired lumbar stenosis. *Neurosurgery* 41 : 567-574; discussion 574-575, 1997
 32. Thomé C, Zevgaridis D, Leheta O, Bázner H, Pöckler-Schöniger C, Wöhrle J, et al. : Outcome after less-invasive decompression of lumbar spinal stenosis : a randomized comparison of unilateral laminotomy, bilateral laminotomy, and laminectomy. *J Neurosurg Spine* 3 : 129-141, 2005
 33. Toyoda H, Nakamura H, Konishi S, Dohzono S, Kato M, Matsuda H : Clinical outcome of microsurgical bilateral decompression via unilateral approach for lumbar canal stenosis : minimum five-year follow-up. *Spine (Phila Pa 1976)* 36 : 410-415, 2011
 34. Tsai RY, Yang RS, Bray RS Jr : Microscopic laminotomies for degenerative lumbar spinal stenosis. *J Spinal Disord* 11 : 389-394, 1998
 35. Weiner BK, Walker M, Brower RS, McCulloch JA : Microdecompression for lumbar spinal canal stenosis. *Spine (Phila Pa 1976)* 24 : 2268-2272, 1999
 36. Weinstein JN, Lurie JD, Tosteson TD, Hanscom B, Tosteson AN, Blood EA, et al. : Surgical versus nonsurgical treatment for lumbar degenerative spondylolisthesis. *N Engl J Med* 356 : 2257-2270, 2007
 37. Young S, Veerapen R, O'Laoire SA : Relief of lumbar canal stenosis using multilevel subarticular fenestrations as an alternative to wide laminectomy : preliminary report. *Neurosurgery* 23 : 628-633, 1988