



## Case report

## Wilms' tumor of the ovary

Vinita M. Alexander <sup>a,\*</sup>, Jane Meisel <sup>b</sup>, Shannon O'Brien <sup>c</sup>, Namita Khanna <sup>a</sup><sup>a</sup> Division of Gynecologic Oncology, Department of Gynecology and Obstetrics, Emory University School of Medicine, Atlanta, GA, USA<sup>b</sup> Department of Hematology and Oncology, Emory University School of Medicine, Atlanta, GA, USA<sup>c</sup> Department of Pathology, Emory University School of Medicine, Atlanta, GA, USA

## ARTICLE INFO

## Article history:

Received 17 October 2016

Received in revised form 7 December 2016

Accepted 12 December 2016

Available online 14 December 2016

## Keywords:

Wilms' tumor of ovary

Immature teratoma

## ABSTRACT

Extrarenal Wilms' tumor of the ovary is a very rare tumor likely derived from embryonic mesonephros. We present the first reported case of a teratoid extrarenal Wilms' tumor of the ovary with a short review of the existing literature. In the case, a 26-year-old woman presented with back pain and was found to have a dermoid cyst; three years later, she presented again, now pregnant, with severe abdominal pain. She was diagnosed with an immature teratoma consisting of a Wilms' tumor (immature component) arising within a mature teratoma and treated exclusively with surgery and surveillance. The recovery from surgery was uneventful and the patient remains without evidence of disease with eleven months of follow-up.

© 2016 Emory University School of Medicine; Department of Gynecology and Obstetrics. Published by Elsevier Inc. This is an open access article under the CC BY-NC-ND license (<http://creativecommons.org/licenses/by-nc-nd/4.0/>).

## 1. Clinical presentation

In March 2014, a 26-year-old female reported back pain, and MRI revealed a 10 cm right ovarian mass and a two-centimeter left ovarian dermoid cyst. She subsequently underwent a laparoscopic right ovarian cystectomy. Gross specimen showed tufts of hair. Final pathology revealed a mature cystic teratoma; no components of immature teratoma were identified. In December 2015, the now twenty-eight-year-old G1P0 female at 11 weeks' gestation presented to an outside hospital. A dating ultrasound was performed, showing a fetus, a 13.8 × 11.1 cm multi-loculated right ovarian cyst with little ovarian tissue, and a 2.6 × 2.4 cm left ovarian dermoid cyst. She remained asymptomatic, reporting no pain or gastrointestinal complaints.

In early January 2016, now at 14 weeks 2 days' gestation, the patient underwent surgery for management of suspected ovarian torsion and rupture. Exploratory laparotomy revealed bilateral adnexal cysts (13 cm on right and 3 cm on left), and she underwent a right oophorectomy. Given concerns for blood loss and difficulty delineating normal ovarian tissue from dermoid cyst on the left, decision was made not to proceed with left-sided oophorectomy. Pathology was reviewed at Emory University and then at Massachusetts General Hospital by an expert in gynecologic pathology, and a diagnosis was made: malignant immature teratoma of right ovary, composed of a small element of Wilms' tumor (immature component) arising within a mature teratoma and associated with a mucinous cystadenoma.

## 2. Treatment

Since the Wilms' tumor represented a minute component of an otherwise benign dermoid cyst and she was 22 weeks pregnant, chemotherapy was not recommended. Plan was made for close observation with repeat imaging following pregnancy, and consideration of surgical re-exploration if recurrent or grossly enlarging cysts were noted on imaging.

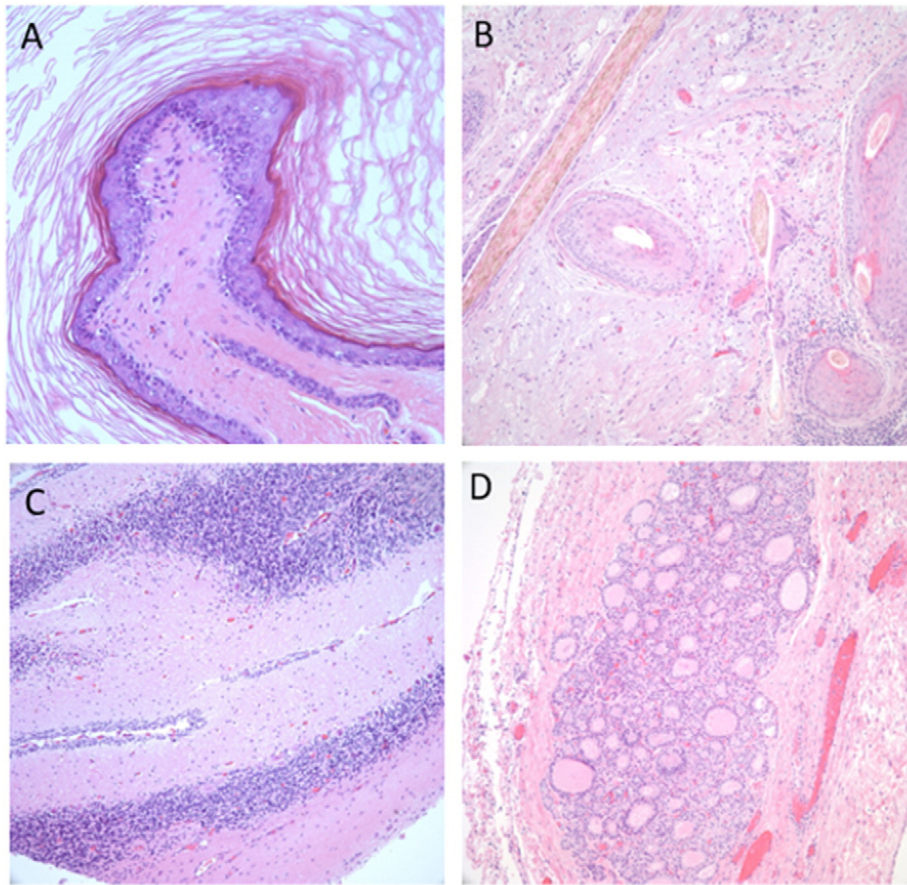
## 3. Outcome and follow-up

The patient did not receive adjuvant therapy, and she remains without evidence of disease after eleven months of follow-up. In fact, ultrasound imaging eight months following surgery revealed a left ovary with a non-enlarging dermoid cyst (measuring three centimeters, the same left cyst noted at prior surgery). Given stability of cyst size, plan was made to follow the cyst with surveillance ultrasound imaging every 6 months for 12 months, and annually thereafter.

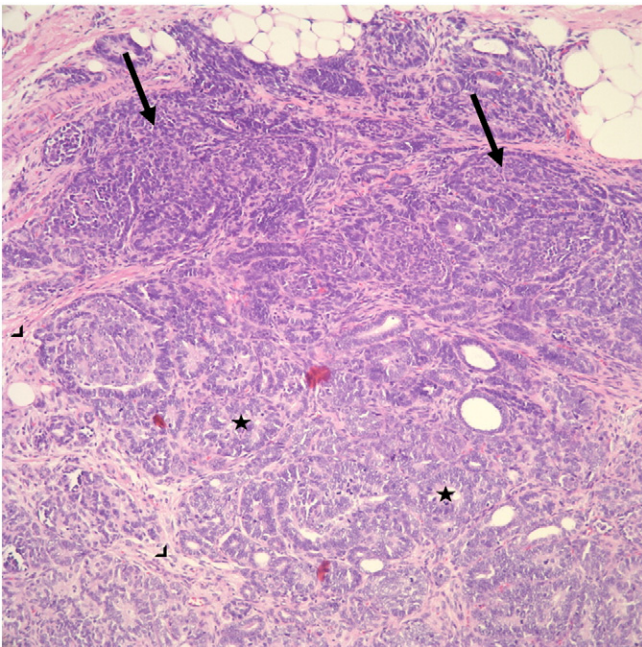
## 4. Pathology

In our case, examined sections of tumor showed mature cystic teratoma (see Fig. 1) and a small one-centimeter focus of Wilms' tumor (see Fig. 2), determined to represent a malignancy within a dermoid cyst. One of the trademark features of ovarian extra-renal Wilms tumor (EWT) is that undifferentiated blastemal tissue with stromal, tubular, and glomeruloid elements characteristic of classic Wilms' Tumor is found within in extra-renal location without evidence of a primary tumor elsewhere (Fig. 2).

\* Corresponding author at: 69 Jesse Hill Jr. Drive SE, Atlanta, GA 30303, United States.  
E-mail address: [vinita.alexander@emory.edu](mailto:vinita.alexander@emory.edu) (V.M. Alexander).



**Fig. 1.** Mature teratoma. This benign tumor is composed of ectodermal (epidermis), endodermal (respiratory, gastrointestinal, thyroid, etc.), mesodermal (smooth muscle, bone, teeth, cartilage, fat), and neuroectodermal tissue (cerebrum, cerebellum, etc.). Images A and B demonstrate the ectodermal elements including skin and hair, respectively. Cerebellar and thyroid tissue were also identified and are shown in images C and D.



**Fig. 2.** Wilms tumor (nephroblastoma). Wilms tumor is a triphasic neoplasm which consists of blastemal (arrow), stromal (arrowhead) and epithelial elements (abortive tubules and glomeruli; star). This tumor is typically positive for WT-1 and negative for CD99.

## 5. Review of the literature

### 5.1. Epidemiology and origins

Wilms' Tumor is the commonest malignancy of genitourinary tracts in children, but development of this tumor outside kidneys is rare (Andrews et al., 1992). By definition, diagnosis of EWT excludes a primary tumor in kidneys and has been reported to occur in a variety of locations, including the sacrococcygeal region, adjacent to kidneys, lumbar region, and pelvis (Andrews et al., 1992). For the diagnosis of EWT to apply, it is important that intrarenal tumor and supernumerary kidney be ruled out. In a review of 80 cases of childhood pure EWT (under age 14), female predominance was observed (female to male ratio 3:2) (Shojaeian et al., 2016).

There are two types of EWT: (1) EWTs found as components of teratomas (teratoid WT) and (2) pure EWTs of one tissue type. Teratoid EWT are rarer than pure EWTs. According to Variend et al.'s criteria for diagnosing a teratoid Wilms' tumor, the heterologous elements should comprise >50% of the tumor in an organoid arrangement (Variend et al., 1984). Many believe embryogenesis of pure EWT parallels that of intrarenal Wilms' tumor, and presence of persistent mesonephric duct remnants in walls of adults' cervix, vagina, ovary, and inguinal regions point to the mesonephros as the origin of the pure EWT (Andrews et al., 1992). Other theories include Connheims' cell rest theory, which holds that cells with persistent embryonic potential will eventually undergo malignant transformation and form pure EWT (Andrews et al., 1992). Similarly, others postulate that teratoid EWT originate directly from misplaced totipotent primitive nephrogenic



**Table 2**

Reported cases of extrarenal teratoid Wilms' tumor. Summary of the 5 other cases of extrarenal teratoid Wilms' tumor.

First Author, year	Age in years Sex	Location	Presenting symptoms	Treatment	Tumor traits (dimensions)	Presence of anaplasia?	Outcome	Follow-up
Pawel et al. (1998)	7/M	Partly cystic ureteropelvic mass	1 week of abdominal pain	Exploratory laparotomy + excision of retroperitoneal mass + vincristine & actinomycin-D × 18 weeks	8 × 4 cm (spherical)	No	No recurrence	18 months
Song et al. (2010)	13/F	Partly cystic mass in vagina originating from uterine cervix (no mass in endometrial cavity)	vaginal spotting	Removal of vaginal mass + vincristine, cyclophosphamide, & actinomycin D × 6 months	6 × 5 cm	No	No recurrence	84 months
Song et al. (2010)	1 day/F	Multilobulated sacrococcygeal mass	Detected on ultrasound during prenatal care	Excision of mass on Day 2 of life + vincristine & actinomycin-D × 6 months	15 × 15 cm	No	No recurrence	29 months
Chowhan et al. (2011)	1.3/M	Retroperitoneal mass below left kidney	Growing abdominal distention	Exploratory laparotomy with excision of mass + vincristine & actinomycin-D × 6 months	6.6 × 5.9 cm	No	No recurrence	6 months
Baskaran (2012)	3/M	Right sided solid abdominal mass	Abdominal distention due to mass	Exploratory laparotomy with excision of mass	10 × 11 cm	No	No recurrence	12 months

of Stage I definition in NWTS should be modified to specify a localized tumor amenable to complete excision with clear margins (Shojaeian et al., 2016).

#### 5.4. Prognosis

Caution should be exercised in interpreting survival data given small numbers of patients. However, it appears from the general trend noted above that prognosis of ovarian EWT and teratoid EWT with favorable histology (i.e. cystic variants, no anaplasia) is similar to that of intrarenal Wilms' Tumor (Narasimharao et al., 1989). From the limited review of six cases of ovarian EWT and four cases of teratoid WT treated with surgery and adjuvant chemotherapy (ten cases), a single case of ovarian EWT treated with surgery and chemoradiation, and two cases of teratoid WT treated with surgery alone (including the presented case), we cannot make statements on differences in disease recurrence and mean recurrence interval. However, authors of a review of 80 cases of childhood EWT suggest radiotherapy be reserved for unresectable tumors or those with gross residual disease, recurrence, or metastasis (Shojaeian et al., 2016). From the now two existing case reports on teratoid EWT, surgical excision alone seems reasonable (Baskaran, 2012).

## 6. Conclusion

Ovarian Wilms' tumor likely arises from mesonephric tissue in the ovary or associated teratoma, and only eight cases of ovarian EWT and six cases of teratoid EWT (including the presented case) have been reported in the literature. The most common presenting symptoms are abdominal pain and abnormal bleeding

Ovarian Wilms' Tumor is a pathologically complex diagnosis, since nephroblastic elements characteristic of EWT can occur alone or in association with teratomatous elements. Based on the reported outcomes of teratoid EWT at other sites, it appears teratoid ovarian EWT carries a better prognosis than pure EWT.

In this review of extrarenal Wilms' tumor of the ovary and teratoid EWT in general, the recurrence rate was 0%, and median follow-up for

ovarian EWT was 15.5 months (median follow-up for teratoid EWT was 18 months). From this review, we advocate that at a minimum, treatment for ovarian EWT should consist of removal of affected ovary with consideration of adjuvant chemotherapy for those with pure EWT based on additional histologic grading factors.

Written informed consent was obtained from the patient for publication of this case report and accompanying images. A copy of the written consent is available for review by the Editor-in-Chief of this journal on request.

## References

- Andrews, P.E., Kelalis, P.P., Haase, G.M., 1992. Extrarenal Wilms' tumor: results of the National Wilms' Tumor Study. *J. Pediatr. Surg.* 27 (91), 1181–1184.
- Baskaran, D., 2012. Extrarenal teratoid Wilms' tumor in association with horseshoe kidney. *Indian J. Surg.* 75, 128–132.
- Chowhan, A.K., et al., 2011. Extrarenal teratoid Wilms' tumour. *Singap. Med. J.* 52 (6), e134–e137.
- Isaac, M.A., et al., 2000. Pure cystic nephroblastoma of the ovary with a review of extrarenal Wilms' tumors. *Hum. Pathol.* 31, 761–764.
- Li, L., Zhou, X., Zhang, H., 2008. Adult extrarenal Wilms' tumor of the ovary. *Chin. J. Pathol.* 37, 284–285.
- Madanat, F., et al., 1978. Extrarenal Wilms tumor. *J. Pediatr.* 93, 439–443.
- Marwah, N., et al., 2012. Extrarenal Wilms' tumor of the ovary: a case report and short review of the literature. *J. Gynecol. Surg.* 28, 306–309.
- Narasimharao, K.L., et al., 1989. Extrarenal Wilms' tumor: a case report. *Paediatr. Surg.* 24, 212–214.
- Nicod, J.L., 1965. Tumeur de Wilms dans l'ovaire. *Bull. Cancer* 52, 173–178.
- Oner, U., et al., 2002. Wilms' tumor of the ovary: a case report. *J. Pediatr. Surg.* 37, 127–129.
- Pawel, B., et al., 1998. Teratoid Wilms tumor arising as a botryoid growth within a supernumerary ectopic ureteropelvic structure. *Arch. Pathol. Lab. Med.* 122, 925–928.
- Pereira, F., et al., 2000. Extrarenal Wilms tumor of the left ovary: a case report. *J. Pediatr. Hematol. Oncol.* 22, 88–89.
- Sahin, A., Benda, J.A., 1988. Primary ovarian Wilms' tumor. *Cancer* 61, 1460–1463.
- Shojaeian, R., Hiradfar, M., Sharifabad, P.S., Zabolnejad, N., van den Hevel-Eibrink, M.M., 2016. Extrarenal Wilms' tumor: challenges in diagnosis, embryology, treatment, and prognosis. *Wilms Tumor. Codon Publications, Brisbane, Australia*, pp. 77–93.
- Song, J.S., et al., 2010. Extrarenal teratoid Wilms' tumor: two cases in unusual locations, one associated with elevated serum AFP. *Pathol. Int.* 60, 35–41.
- Variend, S., Spicer, R.D., Mackinnon, A.E., 1984. Teratoid Wilms' tumor. *Cancer* 53, 1936–1942.