

Scrotal hematoma resulting from extracorporeal shock wave lithotripsy for a renal calculus: a sign of retroperitoneal hemorrhage

Raja Devanathan¹, Darren J. Katz¹, Lachlan J. Dodds²

¹Department of Urology, Ballarat Base Hospital, Vermont, Victoria, Australia

²St. John of God Hospital, North Ballarat, Victoria, Australia

KEY WORDS

scrotum ► hematoma ► retroperitoneal hemorrhage ► lithotripsy

ABSTRACT

We report a rare case of a patient presenting with scrotal hematoma associated with retroperitoneal hemorrhage after extracorporeal shock wave lithotripsy (ESWL). We propose a mechanism for the formation of scrotal hematoma and its importance as a sign of retroperitoneal hemorrhage.

INTRODUCTION

ESWL is a safe and effective procedure despite several complications being reported over the years. There are a number of mechanisms involved in stone fragmentation during ESWL such as spall fracture, shear stress, cavitation, and superfocusing. These mechanical forces can sometimes be transmitted to the renal parenchyma. As a result, the two most common side effects that result are hemorrhage and edema within or around the kidney [1]. Occasionally, perinephric or more superficial soft tissue hemorrhage becomes significant enough to cause clinical symptoms localized to the loin area. Much more infrequently the scrotal area can become involved. We present such a case.

CASE REPORT

A 58-year-old man, with a past history of hypercholesterolemia,

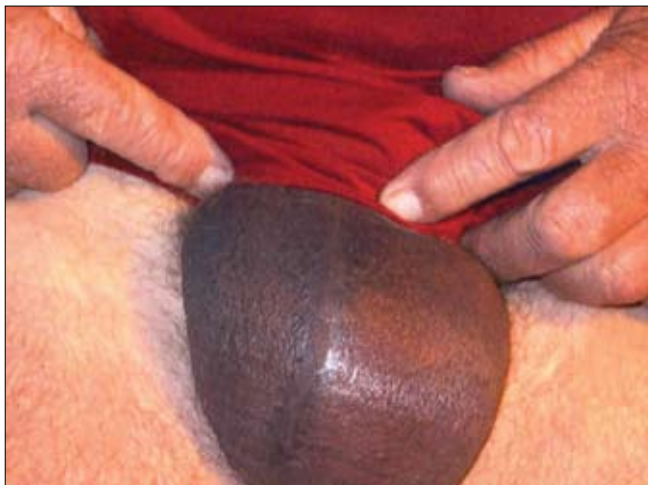

Fig. 1. Scrotal hematoma 3 hours post ESWL.

hypertension, and gout, presented with a symptomatic 10 mm calculus in the left proximal ureter to the emergency department. A plain X-ray of the kidneys, ureter, and bladder (KUB) demonstrated an opacity just below the left transverse process of L3. Computed tomography (CT) of the kidney, ureter, and bladder confirmed the presence of the calculus. It also revealed moderate hydronephrosis of the left kidney after which cystoscopy, retrograde pyelogram, and flexible ureteroscopy was performed. The calculus proved difficult to visualize and fragment due to hematuria, so a 6.0 French Soflex stent was inserted over a guide wire and was seen to be in good position under image intensifier. The stone had been flushed into the renal pelvis. This was followed by ESWL as a day case two months later. The lithotripter used was a Dornier Compact Delta II. A total of 3,000 shocks were administered at 80% intensity and achieved good stone fragmentation under the image intensifier. After ESWL the patient had minimal pain and no macroscopic hematuria so he was discharged the same day.

The patient then presented to the emergency department three hours after discharge with severe left sided flank pain. Physical examination detected a tender left flank and moderate scrotal swelling (Fig 1). A CT revealed a 12 cm x 8 cm x 4 cm left sided perinephric and retroperitoneal hematoma (Fig 2A). There was no evidence of upper tract dilatation. He was admitted for observation, and discharged the following day requiring only simple analgesia. His hemoglobin pre-ESWL was 14.5 g/dL and during representation with pain his hemoglobin was measured at 12.6 g/dL. His scrotal and perinephric hematoma resolved over the ensuing weeks.

DISCUSSION

ESWL is a well-recognized procedure for the fragmentation of renal stones. Symptomatic subcapsular, perirenal fluid collections and hematomas are rare complications and only occur in less than 1% of patients [2]. To our knowledge, there have only been two previously reported cases of scrotal hematomas following ESWL. Both articles suggested that the cause was tracking of retroperitoneal hemorrhage inferiorly.

There are several risk factors associated with hematoma formation post ESWL such as: bleeding diathesis, antiplatelet activity, obesity, hypertension, diabetes, type of lithotripter, as well as intensity and number of shocks [3, 4]. However, none of this has been proven to be consistent. Our case had only one of these risk factors, namely hypertension.

Blacklock and Biri et al. have reported scrotal bruising that occurred as a result of ESWL. The mechanism proposed was hematoma extension into the retroperitoneal space, and tracking inferiorly through the inguinal canal [5, 6]. We found evidence of blood tracking inferiorly in the retroperitoneum in our case (Fig 2B).

Symptomatic perinephric hematomas are rare post ESWL, however, if all patients were routinely imaged post procedure, detection rate would increase dramatically. In fact with routine CT or MRI imaging, the hematoma rate may increase to 25% [7]. The

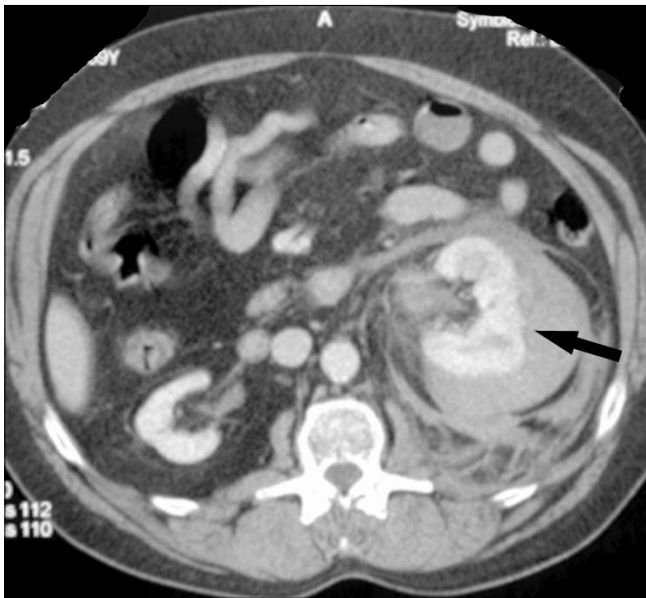


Fig. 2A. Perinephric and retroperitoneal hematoma.

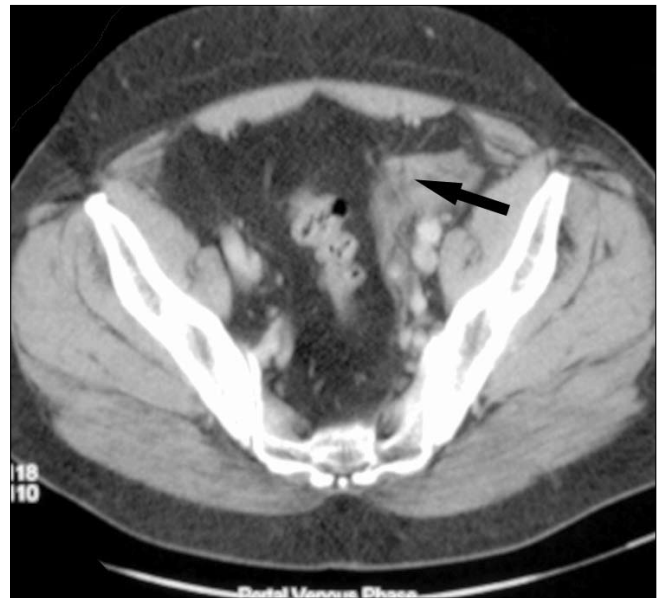

Fig. 2B. Retroperitoneal hematoma tracking inferiorly.

vascularity of the kidney predisposes it to bleed, but in most cases this is a focal process leaving the majority of the renal parenchyma unaffected. However, persistent flank pain post ESWL should be flagged as an early warning sign of perinephric and retroperitoneal bleeding. Furthermore, patients with scrotal ecchymosis alone post ESWL should be considered for further imaging.

With the new generation of lithotripters, ESWL has proven to be a safe and effective method for fragmenting renal calculi. We present a clinically significant but rare complication. We would suggest that a scrotal hematoma after ESWL should prompt consideration of investigation of the retroperitoneum.

REFERENCES

1. Pearle MS, Lotan Y: *Urinary lithiasis: Etiology, Epidemiology, and Pathogenesis*. In: Wein AJ, Kavoussi LR, Novick AC, Partin AW, et al: *Campbell-Walsh Urology*. Saunders, Philadelphia, 2007; pp. 1472-1476.
2. Dhar NB, Thornton J, Karafa MT, et al: *A multivariate analysis of risk factors associated with subcapsular hematoma formation following electromagnetic shock wave lithotripsy*. *J Urol* 2004; 172: 2271-2274.
3. Graber SF, Danuser H, Hochreiter WW, et al: *A prospective randomized trial comparing 2 lithotripters for stone disintegration and induced renal trauma*. *J Urol*. 2003; 169: 54-57.
4. Momose A, Funyu T, Takahashi N, et al: *Effect of pressure distribution of shockwave on renal hemorrhage after extra corporeal shock wave lithotripsy: comparison of EDAP LT-01 and Seimens Lithostar*. *J Endourol* 1999; 13: 165-171.
5. Blacklock ARE: *Painless scrotal bruising following extra corporeal shock wave lithotripsy for renal calculus*. *Br J Urol* 1999; 74: 675.
6. Biri H, Sinik Z, Alkibay T, et al: *Scrotal bruising as a sign of retroperitoneal hematoma following extracorporeal shock wave lithotripsy*. *Int Urol Neph* 1997; 29: 287-290.
7. Skolarikos A, Alivizatos G, De La Rosette J: *Extracorporeal Shock Wave Lithotripsy 25 years later: Complications and their Prevention*. *Eur Uol* 2006; 50: 981-990.

Correspondence

Raja Devanathan
23, Frank Street
Vermont, Victoria 3133, Australia
phone: +61 412 491 766
rajagopalan_d@hotmail.com