

Expression of vascular endothelial growth factor receptor in thymic epithelial tumors

KENSUKE CHIBA¹, TAKAYUKI MURASE², KEISUKE YOKOTA¹, TSUTOMU TATEMATSU¹, RISA ODA¹, RYUJI NAKAMURA¹, SHOGO YOBITA¹, TAKATSUGU TAKANO¹ and KATSUHIRO OKUDA¹

¹Department of Thoracic and Pediatric Surgery, Nagoya City University Graduate School of Medical Sciences, Nagoya, Aichi 467-8601, Japan; ²Department of Pathology and Molecular Diagnostics, Nagoya City University Graduate School of Medical Sciences, Nagoya, Aichi 467-8601, Japan

Received March 1, 2024; Accepted May 31, 2024

DOI: 10.3892/ol.2024.14516

Abstract. Thymic epithelial tumors (TETs) are rare and the major symptoms are not obvious until the tumor progresses to a relatively large size and compresses the surrounding organs. As its growth is aggressive and it metastasizes to distant organs, it is important to find novel effective therapies. Lenvatinib, a vascular endothelial growth factor receptor (VEGFR) inhibitor, is approved as a drug therapy for thymic carcinoma (TC); however, although it is a molecular targeted therapy, there are no obvious predictors of therapeutic efficacy. The present study aimed to assess the association between clinicopathological factors and the protein expression of VEGFR, which is associated with tumor aggressiveness and the efficacy of VEGFR inhibitors. The VEGFR-2 protein expression was evaluated in 144 patients with TETs who underwent surgical resection. The present study assessed whether the expression of VEGFR-2 protein was associated with TET classification and pathological stage, progression-free survival and overall survival (OS). A total of 94 cases (65.2%) were positive for VEGFR-2 protein. The expression of VEGFR-2 was higher in the more aggressive type B3 thymoma and TC (88.5%) than in types A, AB, B1 and B2 thymoma (60.2%). The 5-year OS rate for the overall population was 53.1%. The 5-year OS rates of patients with negative VEGFR-2 staining score values (66.5%) were significantly longer than in patients with positive VEGFR-2 staining score values (42.5%; $P=0.000078$). Furthermore, the

pathological stage was the only factor significantly associated with OS in multivariate analysis. The results of the present study suggest the possibility that the indications for VEGF inhibitor therapy could be extended to type B3 thymoma.

Introduction

Clinical studies to establish novel effective drug therapy for thymic epithelial tumors (TETs), which are tumors located in the anterior mediastinum, are difficult to plan, due to the lack of a large number of cases. The European Society for Medical Oncology guidelines recommend cisplatin + doxorubicin + cyclophosphamide and platinum-based anticancer therapies, such as carboplatin + paclitaxel, for thymic carcinoma (TC) (1).

The multi-vascular endothelial growth factor (VEGF) receptor (VEGFR) inhibitor lenvatinib has been shown to be effective for TC, based on the results of the REMOMA trial, and can now be used in clinical practice (2). Lenvatinib, a molecularly targeted drug against tyrosine kinases, is effective in patients with TC, but it also carries the risk of several side effects, such as proteinuria and hypothyroidism (3). We hypothesize that more effective treatment plans for TC can be formulated if the efficacy can be predicted before prescription. By doing so, the prognosis of patients with TET could be improved.

VEGFR-1 and -2 are mainly involved in tumor angiogenesis; however, VEGFR-1 also has a main role in modulating the inflammatory response (4). It has also been reported that VEGFR-2 is primarily involved in activating signals for tumor angiogenesis (5). The present study first assessed VEGFR-2 to identify a group of patients who would respond to lenvatinib in TET. In a previous study, VEGF expression was evaluated in 17 thymic specimens, with VEGFR-1 and -2 expression reported in the normal thymic region and in the lesion area, and VEGF expression was reported in the tumor epithelial cells of thymomas, in the vascular endothelium and in the stroma close to the tumor (6). Predicting the response to lenvatinib prior to the administration of pharmacotherapy may help to optimize the postoperative management of advanced TC and the treatment of recurrent disease. In the present study, immunohistochemistry (IHC) was used to assess the expression of VEGFR-2 protein, as potentially relevant to the efficacy

Correspondence to: Professor Katsuhiko Okuda, Department of Thoracic and Pediatric Surgery, Nagoya City University Graduate School of Medical Sciences, 1 Kawasumi, Mizuho, Nagoya, Aichi 467-8601, Japan
E-mail: kokuda@med.nagoya-cu.ac.jp

Abbreviations: TET, thymus epithelial tumor; TC, thymic carcinoma; VEGF, vascular endothelial growth factor; IHC, immunohistochemistry; VEGFR, VEGF receptor; PBS, phosphate-buffered saline; EGF, epidermal growth factor

Key words: TET, VEGF, protein expression, thymoma, TC

of VEGF inhibitors in patients with TETs, including TC. The present study also evaluated thymomas that were completely resected by surgery to assess the possibility of expanding the therapeutic indications.

Patients and methods

Patients. The present study analyzed completely resected tumor tissues from 144 TETs from patients aged 25-87 years who were treated at Nagoya City University Hospital (Nagoya, Japan) between April 2004 and March 2021. Exclusion criteria were as follows: i) Cases in which postoperative pathology did not diagnose TETs; ii) cases in which surgery did not result in specimen removal; and iii) cases in which the specimen block was no longer available. There were no missing data, except for 7 cases in which outpatient follow-up was stopped midway through. Patients who were lost to follow-up early were not excluded from prognostic studies or other analyses.

The present study was performed in accordance with the Declaration of Helsinki and was approved by the institutional review board of Nagoya City University Graduate School of Medical Sciences in 2020 (approval no. 70-19-0016). The requirement for individual patient consent was waived due to the retrospective nature of this study and since individuals were not identified. The original hematoxylin and eosin-stained slides were reviewed by a pathologist. The 2021 edition of the World Health Organization classification was used for histopathology (7) and the 8th edition of the Union for International Cancer Control classification was used for typing and staging of TETs (8).

IHC staining. VEGFR-2 protein expression was assessed using IHC, with hematoxylin and eosin-stained sections (5 μ m-thick) evaluated using microscopy. Immunostaining was performed as follows: Deparaffinization was performed by immersion in xylene, followed by immersion in 100, 90, 80 and 70% ethanol for 5 min each. After washing in running water, antigen activation was performed by heat treatment (120°C for 15 min) in 10 mM citrate buffer (pH 6.0), washing in phosphate-buffered saline (PBS), and soaking in methanol with 0.3% hydrogen peroxide for 30 min to prevent endogenous peroxidase activity. After another wash in PBS, the slides were covered with Block Ace (undiluted at room temperature for 10 min) (Megmilk Snow Brand Co., Ltd.), a normal animal serum, to block non-specific reactions, and allowed to react for 10 min in a wet box. The slides were then coated with 200-fold diluted mouse anti-VEGFR-2 antibodies (cat. no. sc-393163; Santa Cruz Biotechnology, Inc.) and kept in a 4°C, dark place in a wet box overnight. They were then washed with PBS and coated with mouse horseradish peroxidase-conjugated EnVision+ Single Reagent (undiluted; room temperature for 45 min) (cat. no. K400111-2; Agilent Technologies, Inc.) and incubated for 45 min in a wet box. Subsequently, they were washed with PBS and incubated for 10 min in DAB/hydrogen peroxide (Sigma-Aldrich; Merck KGaA) reaction solution after checking for staining. The slides were then washed with running water. Nuclei were stained with hematoxylin (room temperature for 1 min), dehydrated in 100% ethanol and xylene, and permeated and sealed.

Evaluation methods. VEGFR-2 staining was evaluated under an optical microscope at x400 magnification. The plasma membrane of the tumor cells (epithelial cells) was evaluated for staining intensity and the proportion of staining. Lymphocytes were excluded from the evaluation.

As there is no established method for evaluating immunostaining for VEGFR-2, the method for determining human epidermal growth factor (EGF) receptor 2, a membrane protein like VEGFR, was referred to. The evaluation of immunostaining was prepared according to the method for determining immunostaining in the American Society of Clinical Oncology/College of American Pathologists guidelines (9). No staining of the plasma membrane was scored as 0. Patchy staining of the plasma membrane was scored as 1, and a specimen with >50% of the plasma membrane stained was scored as 2. Complete circumferential staining of all the cell membranes was scored as 3. The % stained cells within the tumor cells was also assessed. In the case of thymoma type AB and tumors with mixed parts with multiple scores, the part with the highest score was targeted for evaluation.

Statistical analysis. All statistical analyses were performed using EZR (version 1.61; Division of Hematology, Saitama Medical Center, Jichi Medical University) (10).

Pearson's correlation coefficient was used to determine correlation coefficients. Welch's test was used for comparisons between two groups when the variance was not considered equal. The Kruskal-Wallis test was used to compare the other groups, followed by the Steel-Dwass multiple comparisons test. $P < 0.05$ was considered to indicate a statistically significant difference. The log-rank test was used to compare overall survival (OS) and disease-free survival (DFS) between groups using Kaplan-Meier curves. Univariate and multivariate analyses were performed using Cox proportional hazard regression models.

Results

VEGFR-2 staining score in 144 patients with TETs. The expression of VEGFR-2 was assessed in 144 patients who underwent surgical resection of a TET (Table I). The mean and median ages of the patients at the time of surgery were 59.0 and 58 years, respectively. The histological types of thymomas were as follows: Type A (n=15), type AB (n=30), type B1 (n=39), type B2 (n=34), type B3 (n=13) and TC (n=13) (5). The pathological stages of thymoma were as follows: Stage 1 (n=31), stage 2 (n=73), stage 3 (n=15) and stage 4 (n=12). The pathological stages of TC were as follows: Stage 1 (n=8), stage 2 (n=1), stage 3 (n=2) and stage 4 (n=2). The following treatments were administered: Preoperative treatment (n=18), steroid pulse therapy (n=13), carboplatin + paclitaxel (n=2), radiotherapy (n=1), cisplatin + etoposide (n=1) and doxorubicin + cisplatin + vincristine + cyclophosphamide therapy (n=1) (data not shown).

Table II presents the VEGFR-2 staining scores for all cases according to the pathological type of TETs. The immunohistochemical staining score for VEGFR-2 protein was 0 in 50 cases, 1 in 66 cases, 2 in 22 cases, and 3 in 6 cases.

Representative images of hematoxylin and eosin staining and IHC are presented in Figs. 1 and 2. A case of type A thymoma is shown in Figs. 1A and 2A (VEGFR-2 staining

Table I. Patient characteristics (n=144).

| Characteristic | Value |
|------------------------------------|-----------|
| Age, n (%) | |
| <60 years | 74 (51.4) |
| ≥60 years | 70 (48.6) |
| Sex, n (%) | |
| Male | 70 (48.6) |
| Female | 74 (51.4) |
| Pathology, n (%) | |
| Thymoma type A | 15 (10.4) |
| Thymoma type AB | 30 (20.8) |
| Thymoma type B1 | 39 (27.1) |
| Thymoma type B2 | 34 (23.6) |
| Thymoma type B3 | 13 (9.0) |
| Thymic carcinoma | 13 (9.0) |
| Tumor size, mm ^a | 78.5 (50) |
| Thymoma UICC stage, n (%) | |
| 1 | 31 (21.5) |
| 2 | 73 (50.7) |
| 3 | 15 (10.4) |
| 4 | 12 (8.3) |
| Thymic carcinoma UICC stage, n (%) | |
| 1 | 8 (5.6) |
| 2 | 1 (0.7) |
| 3 | 2 (1.4) |
| 4 | 2 (1.4) |

^aData are presented as mean (median). UICC, Union for International Cancer Control.

intensity score, 0; 0%); a case of type B1 thymoma is shown in Figs. 1B and 2B (VEGFR-2 staining intensity score, 1; 40%); a case of type B3 thymoma is shown in Figs. 1C and 2C (VEGFR-2 staining intensity score, 2; 65%); and a case of TC is shown in Figs. 1D and 2D (VEGFR-2 staining intensity score, 3; 95%).

The relationship between the staining score and the pathological stage is presented in Table III. There was a significant positive correlation between the VEGFR-2 staining score and the pathological stage (correlation coefficient, 0.167; P=0.04). A significant positive correlation was also demonstrated between the tumor diameter and VEGFR-2 staining score (correlation coefficient, 0.339; P=0.00003). There was no correlation with any other clinicopathological factor (data not shown).

Association between the VEGFR-2 staining score value and clinicopathological factors. When the product of the VEGFR-2 staining score and the % stained cells (defined as the VEGFR-2 staining score value) was evaluated, the mean value was 18.5, and the median value was 5. Fig. 3 demonstrates the range of VEGFR-2 staining scores for each type of TET. Type B1 thymoma had the lowest staining score.

In the present study, Type A, AB, B1 and B2 thymomas were categorized as low-grade TETs, whilst type B3

Table II. Number of VEGFR-2 stained cases per pathological type of thymus epithelial tumor.

| Pathology | VEGFR-2 score | | | | Total |
|------------------|---------------|----|----|---|-------|
| | 0 | 1 | 2 | 3 | |
| Thymoma type A | 2 | 12 | 1 | 0 | 15 |
| Thymoma type AB | 9 | 20 | 1 | 0 | 30 |
| Thymoma type B1 | 30 | 6 | 3 | 0 | 39 |
| Thymoma type B2 | 6 | 19 | 8 | 1 | 34 |
| Thymoma type B3 | 2 | 4 | 4 | 3 | 13 |
| Thymic carcinoma | 1 | 5 | 5 | 2 | 13 |
| Total | 50 | 66 | 22 | 6 | 144 |

VEGFR, vascular endothelial growth factor receptor.

Table III. Number of VEGFR-2 stained cases per pathological stage of thymus epithelial tumor.

| Pathological stage | VEGFR-2 score | | | | Total |
|--------------------|---------------|----|----|---|-------|
| | 0 | 1 | 2 | 3 | |
| I | 15 | 14 | 2 | 0 | 31 |
| II | 26 | 43 | 10 | 3 | 82 |
| III | 4 | 6 | 6 | 2 | 18 |
| IV | 5 | 3 | 4 | 1 | 13 |
| Total | 50 | 66 | 22 | 6 | 144 |

There was a significant positive correlation between the VEGFR-2 staining score and the pathological stage (correlation coefficient, 0.167; P=0.04). VEGFR, vascular endothelial growth factor.

thymomas and TCs were categorized as high-grade TETs. The mean ± standard deviation of the VEGFR-2 staining score value was 9.11±88.05 for low-grade TET, compared with 61.03±88.06 for high-grade TET. The values were significantly higher in the high-grade TET group compared with in the low-grade TET group (P=0.0063; Fig. 4).

Preoperative treatment. The association between preoperative steroid pulse therapy and the VEGFR-2 staining score value was analyzed and the results demonstrated that the VEGFR-2 staining score values of patients who received steroid pulse therapy did not differ from those of patients who did not receive steroid pulse therapy (data not shown).

No significant differences were identified between the groups categorized according to pathological stage (P=0.226; Fig. 5). Advanced-stage TET (stages 3-4) had a higher VEGFR-2 staining score in comparison with early-stage TET (stage 1-2); however, the difference between the groups was not statistically significant (P=0.24).

Association between the VEGFR-2 staining score value and the prognosis. The 5-year OS and DFS rates for the overall population were 53.1 and 50.8%, respectively. The 5-year OS

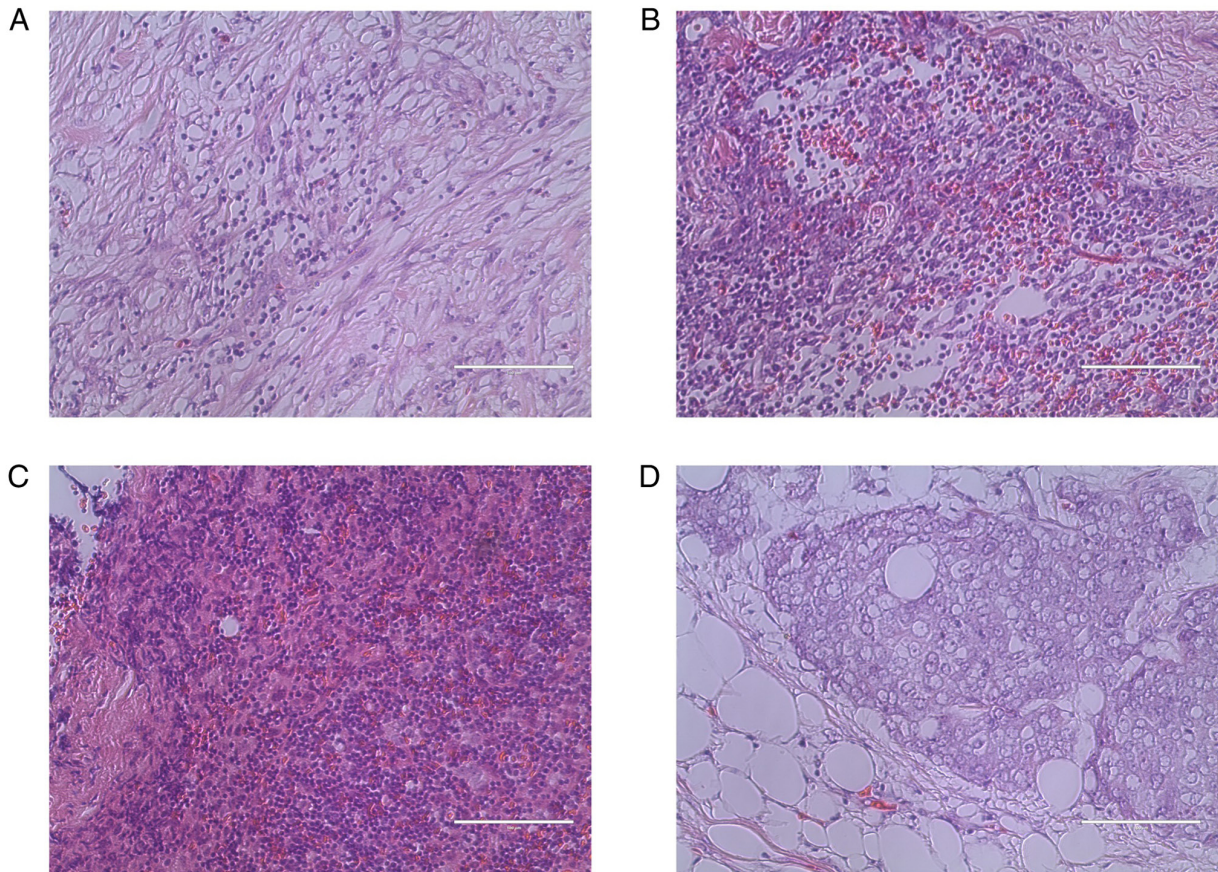


Figure 1. HE staining of thymic epithelial tumors. HE staining of (A) thymoma type A, (B) thymoma type B1, (C) thymoma type B3 and (D) thymic carcinoma. HE, hematoxylin and eosin. Magnification, $\times 400$.

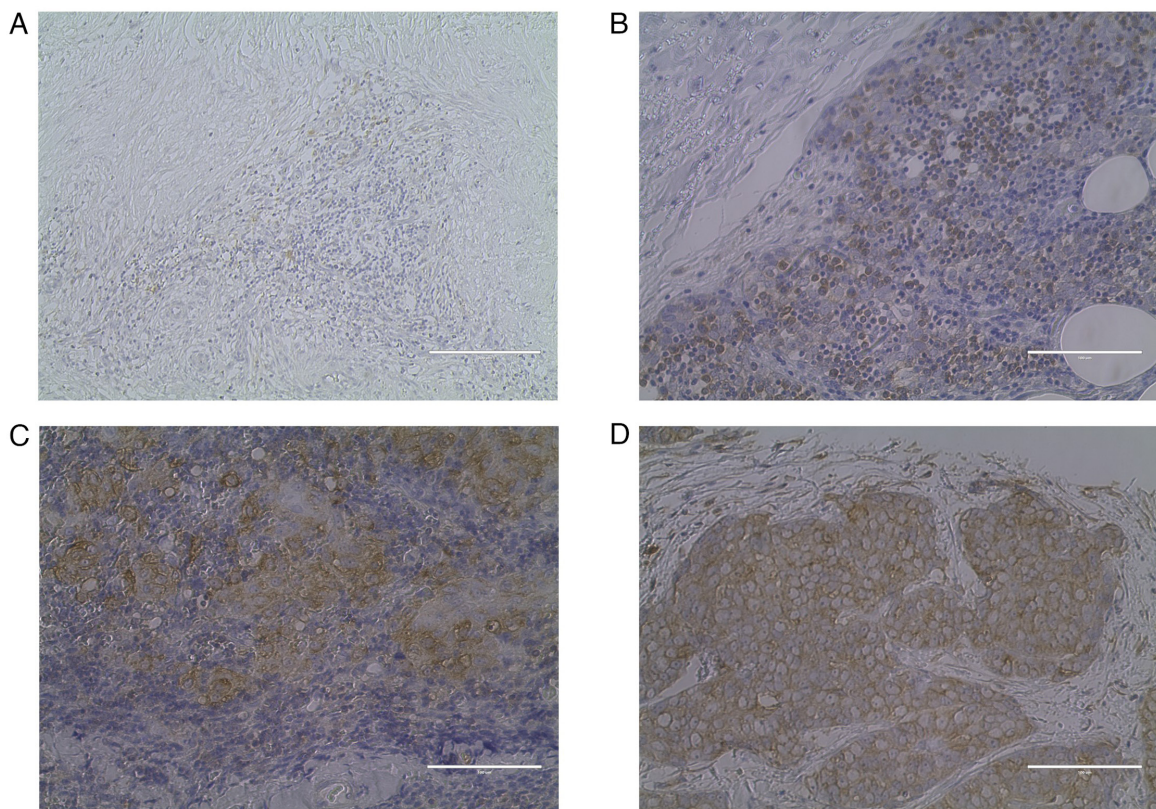


Figure 2. Immunostaining of thymic epithelial tumors. Vascular endothelial growth factor receptor staining score was (A) 0, (B) 1 with 40% stained cells, (C) 2, with 65% stained cells, and (D) 3, with 95% stained cells. Magnification, $\times 400$.

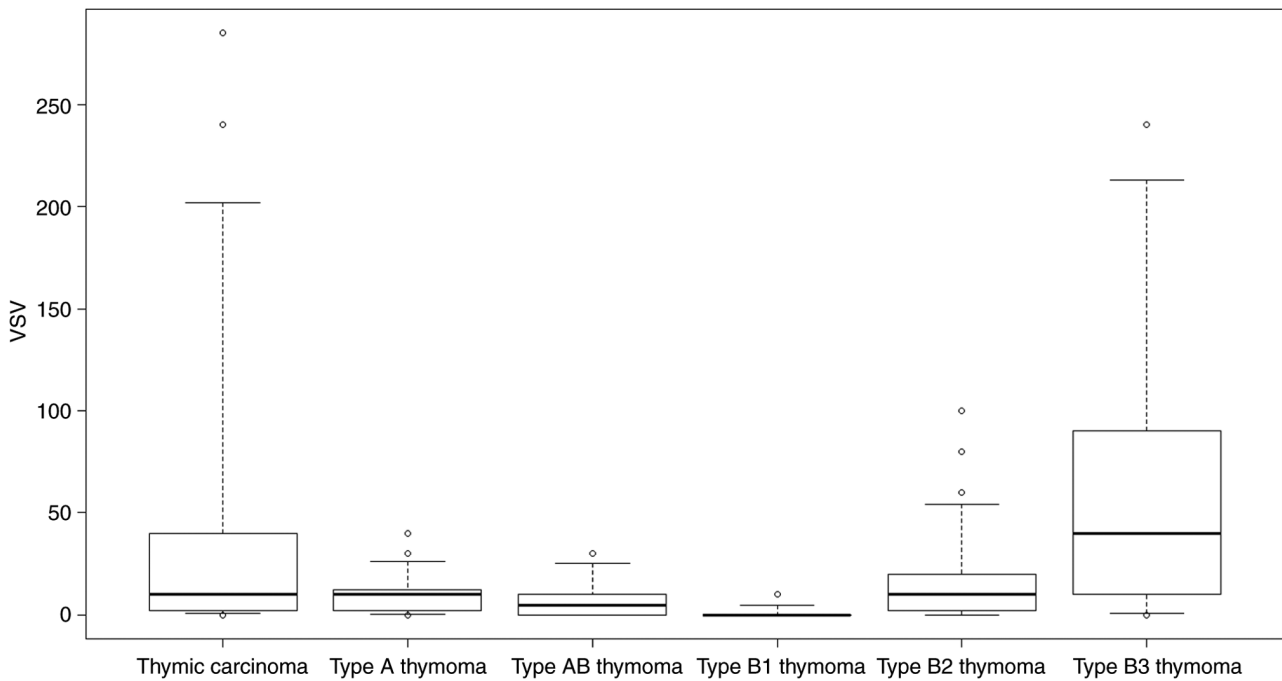


Figure 3. Average VSV for thymic epithelial tumors grouped by pathological type. VSV, vascular endothelial growth factor receptor score value.

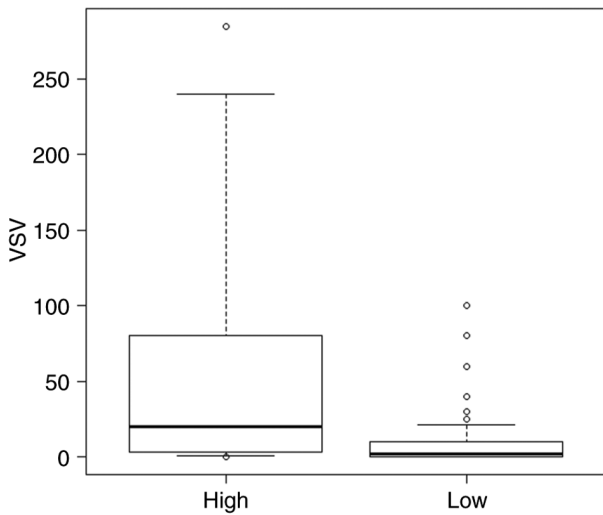


Figure 4. Average VSV for thymic epithelial tumors grouped by grade type. VSV, vascular endothelial growth factor receptor score value.

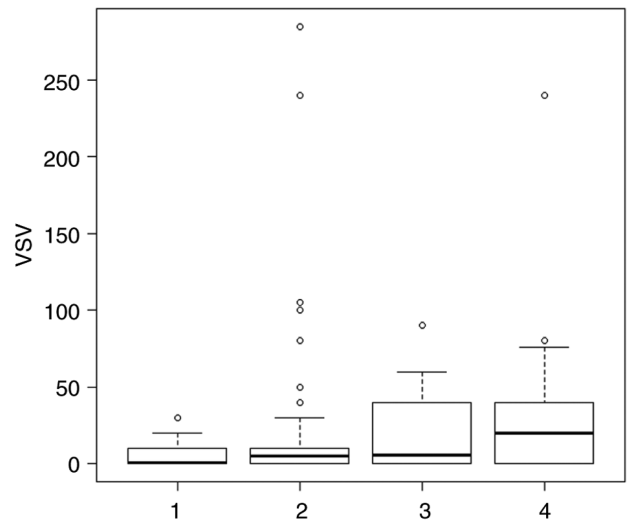


Figure 5. Average VSV for thymic epithelial tumors grouped according to the 8th edition of the Union for International Cancer Control classification stage. VSV, vascular endothelial growth factor receptor score value.

and DFS rates in the low-grade TET group (OS, 53.4%; DFS, 54.3%) were notably higher than those in the high-grade TET group (OS, 36.6%; DFS, 32.2%); however, the differences were not significant (OS, $P=0.48$; DFS, $P=0.408$). Furthermore, the 5-year OS and DFS rates of patients with negative VEGFR-2 staining score values (OS, 66.5%; DFS, 65.5%) were higher than those of patients with positive VEGFR-2 staining score values (OS, 42.5%; DFS, 45.4%), and the differences were found to be significant (OS, $P=0.000078$; DFS, $P=0.00051$).

Table IV shows univariate and multivariate analysis of TETs prognosis. Univariate analyses identified preoperative therapy ($P=0.00869$), VEGFR-2 staining score value >1 ($P=0.0438$) and advanced pathological stage ($P=0.000253$) as significant risk factors for OS. Age ($P=0.5661$), sex

($P=0.06429$), histological grade ($P=0.1139$), smoking history ($P=0.9193$), and tumor size ($P=0.6264$) were not associated with OS. Advanced pathological stage was the only factor that showed a significant association with OS in the multivariate analysis ($P=0.008076$).

Of the 13 deaths in the current study, 7 were tumor-related deaths and 6 were deaths from other diseases.

Discussion

TET is a rare tumor, and the elucidation of improved treatment for advanced and relapsed cases, especially for TC and type B3 thymoma, is needed. Overcoming the difficulties of

Table IV. Univariate and multivariate analysis of thymic epithelial tumor prognosis.

| Variable | Univariate analysis | | Multivariate analysis | |
|----------------------|---------------------|---------|-----------------------|---------|
| | HR (95% CI) | P-value | HR (95% CI) | P-value |
| Age | 1.01 (0.975-1.047) | 0.5661 | | |
| Sex | | | | |
| Male | 2.58 (0.95-7.02) | 0.0643 | | |
| Female | 1 | | | |
| Preoperative therapy | | | | |
| Yes | 4.70 (1.48-14.92) | 0.0087 | 1.67 (0.47-5.99) | 0.4302 |
| No | 1 | | | |
| Histological grade | | | | |
| Low | 1 | | | |
| High | 2.33 (0.82-6.65) | 0.1139 | | |
| VEGFR score | | | | |
| Positive | 3.25 (1.03-10.22) | 0.0438 | 2.23 (0.71-70.34) | 0.1714 |
| Negative | 1 | | | |
| Smoking | | | | |
| Never | 1 | | | |
| Smoker | 1.05 (0.40-2.77) | 0.9193 | | |
| Pathological stage | | | | |
| 1 and 2 | 1 | | | |
| 3 and 4 | 2.45 (1.52-3.95) | 0.0003 | 2.08 (1.21-3.58) | 0.0080 |
| Tumor size | | | | |
| ≤5 cm | 1 | | | |
| >5 cm | 1.27 (0.49-3.30) | 0.6264 | | |

HR, hazard ratio; CI, confidence interval; VEGFR, vascular endothelial growth factor receptor.

planning a clinical study to establish novel effective drug therapies, a previous study reported that a daily dose of 24 mg lenvatinib demonstrated a 38.1% response rate, and achieved a marked reduction in tumor size for recurrent or unresectable TC (2). Regarding VEGFR molecular-targeted therapeutic drug inhibitor for TC and B3 thymomas, the RELEVANT phase II trial reported that carboplatin + paclitaxel + ramucirumab, a monoclonal antibody with antiangiogenic activity that specifically targets the extracellular domain of VEGFR-2, was effective for untreated metastatic TC and B3 thymoma (11).

To date, no genetic driver mutations have been reported in thymomas and TC that could serve as therapeutic targets for effective therapy, to the best of our knowledge. A previous study reported that no obvious driver mutations can be detected in thymomas and TC (12). According to the results of a biomarker analysis in a phase 2 trial of lenvatinib for advanced medullary thyroid cancer, several factors, including high serum VEGF, soluble VEGFR-3 and platelet-derived growth factor- α , and low baseline levels of soluble Tie-2, were reported as positive predictive markers for the efficacy of lenvatinib (13). Circulating fibroblast growth factor (FGF)19 and FGF23 were also indicated as positive predictive markers for the efficacy of lenvatinib in hepatocellular and thyroid carcinoma, respectively (14,15).

For the growth of tumors, blood vessels are needed to carry nutrients and oxygen along with waste products and metabolites. The limit of diffusion in the interstitial fluid is $\sim 200 \mu\text{m}$, and as long as tumors are small, metabolic maintenance is possible without blood vessels entering the tumor. However, for tumors $>1\text{-}2 \text{ mm}$, angiogenesis into the tumor is required. Angiogenesis is associated with tumor growth and distant metastasis, and angiogenic factors include VEGF, basic fibroblast growth factor, angiopoietin, hepatocyte growth factor, EGF and placental growth factor (16). The findings of the present study suggest that low-grade TETs, specifically thymoma types A and B1, express minimal VEGFR-2 expression levels. Conversely, high-grade TETs, including TC and thymoma type B3, demonstrated elevated VEGFR-2 expression levels. Larger tumors and more advanced-stage lesions were also demonstrated to express VEGFR-2. To the best of our knowledge, no other studies have evaluated tumor size and the expression of VEGFR-2. The expression of VEGF mRNA has been reported to be increased in many solid tumors, including brain, gastric, renal, colon and ovarian tumors (17-19). Since the formation of blood vessels is necessary for solid tumors to grow beyond a certain size, it is conceivable that the expression of VEGF, which is strictly specific to vascular endothelial cells, increases during tumor growth (20).

Factors known to adversely affect the recurrence and life expectancy in patients with TETs include tumor size, incomplete resection and pathological staging; however, age, sex, and myasthenia gravis are not considered to have a prognostic impact (21,22). Furthermore, colorectal cancer (23), gastric cancer (24), cervical cancer (25) and papillary thyroid cancer (26,27) have been reported to have an adverse effect on the prognosis in VEGF- and VEGFR-positive case groups. However, to the best of our knowledge, there are no previous studies assessing the relationship between VEGF or VEGFR and prognosis in thymoma and TC. In the univariate analysis in the present study, a high expression of VEGFR-2 was associated with a worse prognosis; however, the expression of VEGFR-2 showed no prognostic impact in the multivariate analysis. The present study investigated the PFS and OS according to differences in VEGFR-2 expression; however, as the numbers of cases with thymic cancer and type B3 thymoma, and stage III and IV disease are small, no significant differences were observed in terms of PFS or OS.

If the expression of VEGFR-2 is confirmed to predict the efficacy of lenvatinib in future studies, there may be benefits, such as increased complete resection rates, if lenvatinib can be used as a preoperative therapy for TETs with surrounding organ invasion. To this end, future research should evaluate VEGFR-2 in biopsy specimens and surgical specimens from patients treated with lenvatinib for the postoperative recurrence of TET and patients who are diagnosed with unresectable TET, as well as the antitumor efficacy of lenvatinib and the subsequent recurrence rate. Alternatively, tumors that require concomitant resection prior to treatment may no longer require concomitant resection after treatment. Furthermore, future research should use cell lines to perform a functional analysis of VEGFR-2.

The present study had several limitations, including the inclusion of cases in which tissue sections were stored for long periods, the retrospective case-count design, the single center setting, and the fact that immunostaining of the tissues was performed by hand, which may have resulted in uneven staining in comparison with machine staining. Moreover, the selection bias was not ignored. In particular, the number of the cases with thymic cancer and type B3 thymoma, and stage III and IV disease was low, making it difficult to fully examine them. Despite these limitations, there are no reports assessing VEGFR-2 expression in TETs, to the best of our knowledge, and it is hoped that the present study is a useful report suggesting that VEGFR may be a novel target for the treatment of TETs. Finally, of the 13 deaths in the current study, seven were tumor-related deaths and six were deaths from other diseases. As a high proportion of the deaths from other diseases, the influence of this factor could not be excluded.

In conclusion, among TETs, the expression of VEGFR-2 was notably high in TETs that were of a higher grade, larger tumors and advanced stages. Future research should evaluate the effects of modulating VEGFR-2 expression on other thymic cancer cells using cell lines for VEGFR-2 and other receptors in TET.

Acknowledgements

Not applicable.

Funding

No funding was received.

Availability of data and materials

The data generated in the present study may be requested from the corresponding author.

Authors' contributions

KC and KO conceived and designed the study. KC, TM and SY performed the experiments, acquired data and assessed the authenticity of all raw data to ensure its legitimacy. KC, KY, TsT, RO, RN and TaT analyzed the data. KC drafted the manuscript. KO and KC confirm the authenticity of all the raw data. All authors have read and approved the final manuscript.

Ethics approval and consent to participate

The present study was performed in accordance with the Declaration of Helsinki and approved by the Institutional Ethics Committee of Nagoya City University Graduate School of Medical Sciences (Nagoya, Japan; approval no. 70-19-0016). The requirement for individual patient consent was waived due to the retrospective nature of the present study and since individuals were not identified.

Patient consent for publication

Not applicable.

Competing interests

The authors declare that they have no competing interests.

References

- Girard N, Ruffini E, Marx A, Faivre-Finn C and Peters S; ESMO Guidelines Committee: Thymic epithelial tumours: ESMO clinical practice guidelines for diagnosis, treatment and follow-up. *Ann Oncol* 26 (Suppl 5): v40-v55, 2015.
- Sato J, Satouchi M, Itoh S, Okuma Y, Niho S, Mizugaki H, Murakami H, Fujisaka Y, Kozuki T, Nakamura K, *et al*: Lenvatinib in patients with advanced or metastatic thymic carcinoma (REMORA): A multicentre, phase 2 trial. *Lancet Oncol* 21: 843-850, 2020.
- Zhu C, Ma X, Hu Y, Guo L, Chen B, Shen K and Xiao Y: Safety and efficacy profile of lenvatinib in cancer therapy: A systematic review and meta-analysis. *Oncotarget* 7: 44545-44557, 2016.
- Luttun A, Tjwa M, Moons L, Wu Y, Angelillo-Scherrer A, Liao F, Nagy JA, Hooper A, Priller J, De Klerck B, *et al*: Revascularization of ischemic tissues by PIGF treatment, and inhibition of tumor angiogenesis, arthritis and atherosclerosis by anti-Flt1. *Nat Med* 8: 831-840, 2002.
- Ellis LM and Hicklin DJ: VEGF-targeted therapy: Mechanisms of anti-tumour activity. *Nat Rev Cancer* 8: 579-591, 2008.
- Cimpean AM, Marius R, Svetlana E, Cornea R and Viorica B: Immunohistochemical expression of vascular endothelial growth factor A (VEGF) and its receptors (VEGFR1, 2) in normal and pathologic conditions of human thymus. *Ann Anat* 190: 238-245, 2008.
- WHO classification of tumours editorial board: International agency for research on cancer: Thoracic Tumours. 5th Edition. Lyon, France, 2021.
- Brierley JD, Gospodarowicz MK and Wittekind C: The TNM classification of malignant tumors. 8th Edition. Wiley Blackwell, Oxford, 2017.

9. Wolff AC, Hammond MEH, Allison KH, Harvey BE, Mangu PB, Bartlett JMS, Bilous M, Ellis IO, Fitzgibbons P, Hanna W, *et al*: Human epidermal growth factor receptor 2 testing in breast cancer: American society of clinical oncology/college of American pathologists clinical practice guideline focused update. *Arch Pathol Lab Med* 142: 1364-1382, 2018.
10. Kanda Y: Investigation of the freely available easy-to-use software 'EZ' for medical statistics. *Bone Marrow Transplant* 48: 452-458, 2013.
11. Imbimbo M, Vitali M, Fabbri A, Ottaviano M, Pasello G, Petrini I, Palmieri G, Berardi R, Zucali P, Ganzinelli M, *et al*: RELEVENT trial: Phase II trial of ramucirumab, carboplatin, and paclitaxel in previously untreated thymic carcinoma/B3 thymoma with area of carcinoma. *Clin Lung Cancer* 19: e811-e814, 2018.
12. Petrini I, Meltzer PS, Kim IK, Lucchi M, Park KS, Fontanini G, Gao J, Zucali PA, Calabrese F, Favaretto A, *et al*: A specific missense mutation in GTF2I occurs at high frequency in thymic epithelial tumors. *Nat Genet* 46: 844-849, 2014.
13. Schlumberger M, Jarzab B, Cabanillas ME, Robinson B, Pacini F, Ball DW, McCaffrey J, Newbold K, Allison R, Martins RG, *et al*: A phase II trial of the multitargeted tyrosine kinase inhibitor lenvatinib (E7080) in advanced medullary thyroid cancer. *Clin Cancer Res* 22: 44-53, 2016.
14. Chuma M, Uojima H, Numata K, Hidaka H, Toyoda H, Hiraoka A, Tada T, Hirose S, Atsukawa M, Itokawa N, *et al*: Early changes in circulating FGF19 and ang-2 levels as possible predictive biomarkers of clinical response to lenvatinib therapy in hepatocellular carcinoma. *Cancers (Basel)* 12: 293, 2020.
15. Tahara M, Schlumberger M, Elisei R, Habra MA, Kiyota N, Paschke R, Dutcus CE, Hihara T, McGrath S, Matijevic M, *et al*: Exploratory analysis of biomarkers associated with clinical outcomes from the study of lenvatinib in differentiated cancer of the thyroid. *Eur J Cancer* 75: 213-221, 2017.
16. Bergers G and Benjamin LE: Tumorigenesis and the angiogenic switch. *Nat Rev Cancer* 3: 401-410, 2003.
17. Dvorak HF, Brown LF, Detmar M and Dvorak AM: Vascular permeability factor/vascular endothelial growth factor, microvascular hyperpermeability, and angiogenesis. *Am J Pathol* 146: 1029-1039, 1995.
18. Mustonen T and Alitalo K: Endothelial receptor tyrosine kinases involved in angiogenesis. *J Cell Biol* 129: 895-898, 1995.
19. Ferrara N, Houck K, Jakeman L and Leung DW: Molecular and biological properties of the vascular endothelial growth factor family of proteins. *Endocr Rev* 13: 18-32, 1992.
20. Luo JC, Yamaguchi S, Shinkai A, Shitara K and Shibuya M: Significant expression of vascular endothelial growth factor/vascular permeability factor in mouse ascites tumors. *Cancer Res* 58: 2652-2660, 1998.
21. Detterbeck F, Youssef S, Ruffini E and Okumura M: A review of prognostic factors in thymic malignancies. *J Thorac Oncol* 6 (7 Suppl 3): S1698-S1704, 2011.
22. Asamura H, Nakagawa K, Matsuno Y, Suzuki K, Watanabe S and Tsuchiya R: Thymoma needs a new staging system. *Interact Cardiovasc Thorac Surg* 3: 163-167, 2004.
23. Ishigami SI, Arii S, Furutani M, Niwano M, Harada T, Mizumoto M, Mori A, Onodera H and Imamura M: Predictive value of vascular endothelial growth factor (VEGF) in metastasis and prognosis of human colorectal cancer. *Br J Cancer* 78: 1379-1384, 1998.
24. Ichikura T, Tomimatsu S, Ohkura E and Mochizuki H: Prognostic significance of the expression of vascular endothelial growth factor (VEGF) and VEGF-C in gastric carcinoma. *J Surg Oncol* 78: 132-137, 2001.
25. Lancaster JA, Cooper RA, Logue JP, Davidson SE, Hunter RD and West CM: Vascular endothelial growth factor (VEGF) expression is a prognostic factor for radiotherapy outcome in advanced carcinoma of the cervix. *Br J Cancer* 83: 620-625, 2000.
26. Klein M, Vignaud JM, Hennequin V, Toussaint B, Bresler L, Plénat F, Leclère J, Duprez A and Weryha G: Increased expression of the vascular endothelial growth factor is a pejorative prognosis marker in papillary thyroid carcinoma. *J Clin Endocrinol Metab* 86: 656-658, 2001.
27. Hsueh C, Lin JD, Wu IC, Chao TC, Yu JS, Liou MJ and Yeh CJ: Vascular endothelial growth factors and angiopoietins in presentations and prognosis of papillary thyroid carcinoma. *J Surg Oncol* 103: 395-399, 2011.



Copyright © 2024 Chiba et al. This work is licensed under a Creative Commons Attribution-NonCommercial-NoDerivatives 4.0 International (CC BY-NC-ND 4.0) License.