

## CASE REPORT

# The usefulness of OK-432 for the treatment of postoperative chylothorax in a low-birth-weight infant with trisomy 18

Yoshiaki Takahashi  | Yoshiaki Kinoshita | Takashi Kobayashi | Yuhki Arai | Toshiyuki Ohyama | Naoki Yokota | Koichi Saito | Yu Sugai | Shoichi Takano

Department of Pediatric Surgery,  
Niigata University Graduate School of  
Medical and Dental Sciences, Niigata,  
Japan

**Correspondence**

Yoshiaki Takahashi, Department of  
Pediatric Surgery, Niigata University  
Graduate School of Medical and Dental  
Sciences, 1-757, Asahimachi-dori,  
Chuo-ku, Niigata City, 951-8510, Japan.  
Email: [yoshiaki-t@med.niigata-u.ac.jp](mailto:yoshiaki-t@med.niigata-u.ac.jp)

**Funding information**

Not applicable

**Abstract**

Chylothorax is a rare but life-threatening condition in neonates. We herein report the successful use of OK-432 for a low-birth-weight infant with trisomy 18 who developed refractory chylothorax after thoracic surgery. Increasing the concentration of OK-432 seems useful in cases with a lot of pleural effusion.

**KEYWORDS**

chylothorax, low-birth-weight infant, OK-432, pleurodesis, trisomy 18

## 1 | INTRODUCTION

Chylothorax is a postoperative complication after thoracic or cardiovascular surgery.<sup>1</sup> The chronic loss of chyle leads to nutritional, metabolic, and immunological problems that are responsible for longer hospital stays and a relatively high mortality in patients with chylothorax.<sup>2</sup> Treatment of chylothorax has traditionally been performed conservatively<sup>3</sup> including the administration of MCT-based formula, octreotide, somatostatin analogs, or corticosteroids. Chemical pleurodesis with instillation of various agents (OK-432, bleomycin, and povidone-iodine) in the pleural space is occasionally needed as second-line treatment.

Recently, the successful treatment of prenatal and neonatal chylothorax by pleurodesis using OK-432 has been reported.<sup>3</sup> However, there have been only a few reports describing whether or not treatment using OK-432 for infants with chromosomal abnormalities is effective and safe.

We herein report the successful use of OK-432 for a low-birth-weight infant with trisomy 18 who developed refractory chylothorax after thoracic surgery.

## 2 | CASE PRESENTATION

A 40-year-old, gravida 4, para 2 woman was referred to our perinatal center at 34 weeks' gestation because of suspected left congenital diaphragmatic hernia (CDH). No abnormal family history was recorded.

A female infant weighing 1920 g was born via Cesarean section at 37 weeks and 2 days' gestation. Immediately after delivery, she was intubated, and synchronous intermittent mandatory ventilation (SIMV) was started. Low-set ears and widely spaced eyes were shown at birth. Chest X-ray showed an elevated hemidiaphragm with the mediastinum shifted to the right side and gastric herniation into the thoracic cavity. An echocardiogram on the first day of life showed ventricular septal defect (VSD),

This is an open access article under the terms of the [Creative Commons Attribution-NonCommercial-NoDerivs](https://creativecommons.org/licenses/by-nc-nd/4.0/) License, which permits use and distribution in any medium, provided the original work is properly cited, the use is non-commercial and no modifications or adaptations are made.

© 2022 The Authors. *Clinical Case Reports* published by John Wiley & Sons Ltd.

coarctation of aorta (CoA), and a large patent ductus arteriosus (PDA) with bidirectional shunt and severe pulmonary hypertension. A genetic analysis was performed because there were multiple malformations, revealing trisomy 18.

The respiratory and circulatory dynamics gradually stabilized, and surgery was performed at three days of life. Laparotomy revealed left diaphragmatic hernia with a hernial sac containing the left lateral segment of the liver and stomach. The sac was removed, and patch closure was performed with a Gore-Tex sheet.

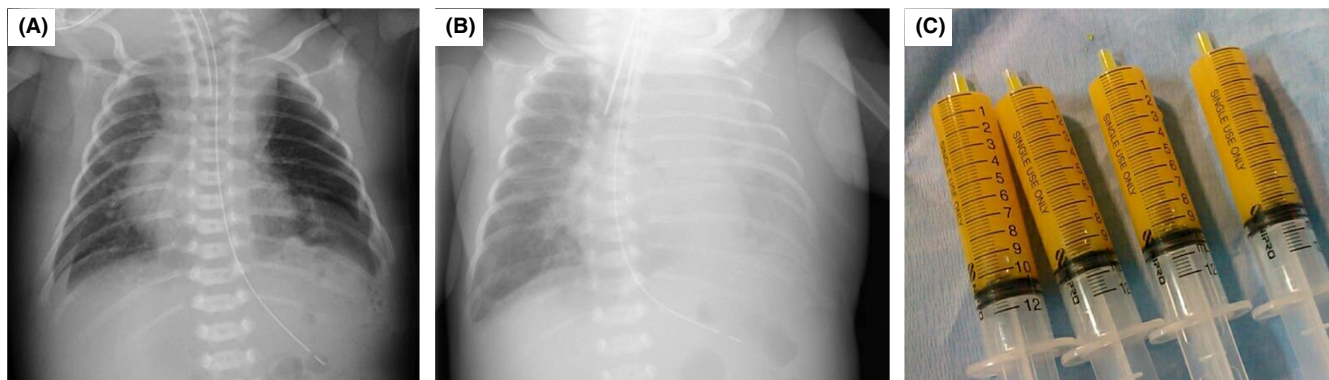Mechanical ventilation was also required after surgery. Chest X-ray showed that the left pleural effusion had increased gradually after initiating breast milk feeding (Figure 1A and B), so thoracentesis was performed at 15 days of life, and chylothorax was confirmed by the appearance and analysis of pleural effusion (Figure 1C, chylous effusion and elevated triglyceride 358 mg/dL). Furthermore, bilateral pleural effusion was shown on ultrasonography and chest X-ray, so bilateral thoracic drainage was performed. Conservative therapy with fasting and octreotide and corticosteroids was initiated, but the pleural effusion did not decrease. Octreotide infusion was initiated at 0.5 µg/kg/h and increased to a maximum dose of 10 µg/kg/h.

High pulmonary blood flow due to VSD became apparent, so bilateral pulmonary artery banding was performed at 25 days of life. The chylous effusion further increased after cardiovascular surgery (Figure 2). The chylothorax was resistant to conservative therapy for more than 3 weeks, so pleurodesis using OK-432 was planned at 38 days after obtaining informed consent. First, 1 KE OK-432 (at a concentration of 1 KE in 10 ml normal saline) was injected into the right pleural cavity. The chest drain was clamped after injection of OK-432 for as long as possible. The patient's posture was changed from the supine

position to the right lateral decubitus position two hours later and to the left lateral decubitus position a further two hours later. In the first pleurodesis, the chest drain was clamped for only four hours because the breathing status deteriorated as the pleural effusion increased. Chylous effusion was not decreased after initial pleurodesis. In the second pleurodesis session at 45 days of life, the same method was performed and led to the same result. The concentration was, therefore, changed from 0.1 KE/ml to 0.2 KE/ml, and 1 KE of OK-432 was injected into the same side at 52 days, with the chest drain clamped for 9 h. The same method was again used at 58 and 67 days, with the chest drain clamped for 14 and 20 h, respectively. The chylous effusion decreased gradually after the third pleurodesis procedure (Figure 2). The left and right chest drains were able to be removed at 72 and 74 days, respectively. There was no recurrence of chylothorax after removing the drainage tube. Mechanical ventilation was able to be withdrawn at 143 days. At present, only oxygenation with a 0.5 L nasal cannula is required at 1 year old, with no recurrence of chylothorax or left CDH having been noted (Figure 3).

### 3 | DISCUSSION

Chylothorax is a rare but life-threatening condition in neonates, particularly in neonates with chromosomal abnormalities. It is well known that chylothorax is often seen in children with chromosomal abnormalities, such as trisomy 21, Turner's syndrome, and Noonan's syndrome due to vascular and lymphatic malformations.<sup>2</sup> Conservative treatment using MCT-based formula, octreotide, somatostatin analogs, or corticosteroids has traditionally been performed due to their effect on splanchnic circulation and lipid absorption.<sup>4</sup> With conservative



**FIGURE 1** Chest X-ray after surgery for CDH and the appearance of pleural effusion. (A) Pleural effusion was not noted just after the operation. (B) The pleural effusion increased after initiating breast milk feeding. (C) Chylothorax was confirmed by the appearance of pleural effusion underwent thoracentesis at 15 days

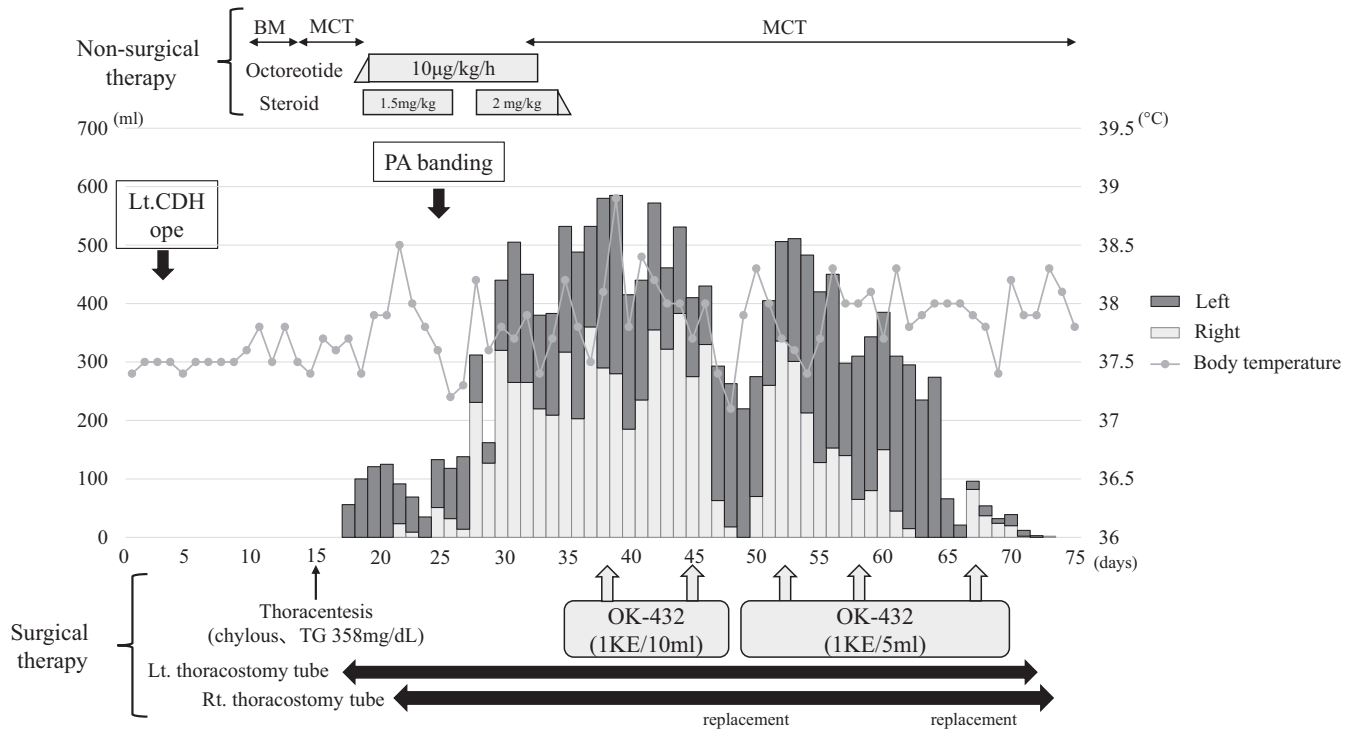


FIGURE 2 Clinical course and therapeutic management of postoperative chylothorax

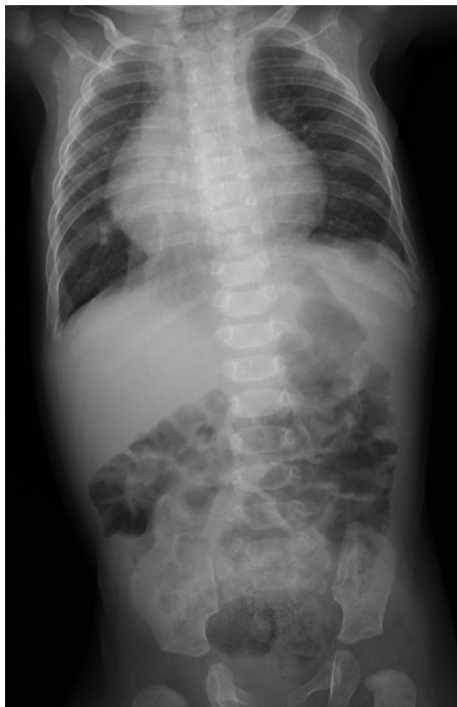

FIGURE 3 Chest and abdominal X-ray findings at one year old. Chest X-ray indicated no recurrence of chylothorax or left CHD at one year old

treatment, complete resolution of pleural fluids can be observed within 30 days for 80% of congenital chylothorax patients.<sup>5</sup>

However, there are no definite guidelines about which treatment is the most useful for persistent chylothorax. Some authors have suggested that surgical intervention may be necessary in cases with massive or persistent pleural drainage.<sup>6,7</sup> However, surgery such as pleuroperitoneal shunting, thoracic duct ligation, and lymphaticovenous anastomosis, should be performed only when conservative treatments fail, as such approaches are highly invasive in children. Pharmacologic or chemical pleurodesis has also been suggested as a possible alternative step before surgery in pediatric patients, with instillation of various agents (OK-432, bleomycin, tetracycline, and povidone-iodine) in the pleural space.<sup>8</sup> However, there are no recommendations about which agent is the most useful for managing chylothorax.

OK-432 is an inactivated preparation of *Streptococcus pyogenes* that is an effective sclerosing agent.<sup>9</sup> It causes pleurodesis by inducing a strong cellular and cytokine-mediated inflammatory response and has been widely used to treat macrocystic lymphatic malformations in children.<sup>10</sup> Although the successful treatment of neonatal and prenatal chylothorax by intrapleural instillation of OK-432 has been reported,<sup>3,5,7</sup> there are only a few reports in neonates with chylothorax, with reports concerning such patients with chromosomal abnormalities being even rarer. Furthermore, there have been no reports concerning the efficacy of pleurodesis using OK-432 for high-risk patients, such as a low-birth-weight infant with 18 trisomy.

We selected OK-432 because it was allowed for the treatment of chylothorax under the insurance system of our country and had fewer side effects than other agents.<sup>5</sup> Regarding the dosage, previous reports described the injection of 0.5 KE OK-432 for pleurodesis.<sup>3</sup> In our case, 1 KE OK-432 (at a concentration of 1 KE in 10 ml normal saline) was injected into the pleural cavity, as substantial chylous effusion was noted, so the concentration of OK-432 might have become diluted. OK-432 was ineffective at the first two sessions due to the shortness of the clamp time because of the patient's respiratory disorder associated with increasing pleural effusion. Therefore, at the third pleurodesis session, the concentration was changed from 0.1 KE/ml to 0.2 KE/ml, and 1 KE of OK-432 was injected. The chylous effusion gradually decreased due to the increased concentration of OK-432, and chylothorax was ultimately cured after performing pleurodesis five times.

OK-432 is useful for refractory chylothorax, but there are some side effects, including a fever and respiratory disorder.<sup>5</sup> A fever was observed in the present case after pleurodesis but resolved within a few days. Furthermore, this patient was able to finally be withdrawn from mechanical ventilation at 143 days of life. Now, only oxygenation with a 0.5 L nasal cannula is required at 1 year old, and chest X-ray has shown that the lung field is clear.

## 4 | CONCLUSIONS

Intrapleural injection of OK-432 was useful for treating a low-birth-weight infant with trisomy 18 who developed refractory chylothorax after thoracic surgery. This approach has been shown to effectively increase the concentration of OK-432 in cases with a large amount of pleural effusion. However, there are some side effects, including a fever and respiratory disorder. Given the small number of cases involving pleurodesis with OK-432, the accumulation of cases is difficult at present. Therefore, reports concerning the usefulness of OK-432 for high-risk patients with chromosomal anomalies, like our case, are essential to prove its effectiveness and highlight its side effects and safety of use.

## AUTHOR CONTRIBUTIONS

Yoshiaki Takahashi wrote the manuscript. Yoshiaki Kinoshita and Takashi Kobayashi revised the manuscript. Yuhki Arai, Toshiyuki Ohyama, Naoki Yokota, Koichi Saito, Yu Sugai, and Shoichi Takano managed the postoperative course.

## ACKNOWLEDGMENT

The authors thank Brian Quinn for helping to prepare the manuscript.

## CONFLICTS OF INTERESTS

The authors declare no conflict interest.

## DATA AVAILABILITY STATEMENT

Data sharing is not applicable to this article.

## ETHICAL APPROVAL

This case report was performed according to the Ethical Guidelines for Clinical Research published by the Ministry of Health, Labor and Welfare of Japan on July 30, 2003 (revised 2008) and complied with the 1964 Declaration of Helsinki (revised 2008). Informed consent was obtained from patient's parents.

## CONSENT

Written informed consent was obtained from the patient to publish this report in accordance with the journal's patient consent policy.

## ORCID

Yoshiaki Takahashi  <https://orcid.org/0000-0002-3034-693X>

## REFERENCES

1. Church JT, Antunez AG, Dean A, et al. Evidence-based management of chylothorax in infants. *J Pediatr Surg.* 2017;52:907-912.
2. Buchwald MA, Laasner U, Balmer C, Cannizzaro V, Latal B, Bernet V. Comparison of postoperative chylothorax in infants and children with trisomy 21 and without dysmorphic syndrome: is there a difference in clinical outcome? *J Pediatr Surg.* 2019;54:1298-1302.
3. Matsukuma E, Aoki Y, Sakai M, et al. Treatment with OK-432 for persistent congenital chylothorax in newborn infants resistant to octreotide. *J Pediatr Surg.* 2009;44:37-39.
4. Vass G, Evans Fry R, Roehr CC. Should newborns with refractory chylothorax be tried on higher dose of octreotide? *Neonatology.* 2021;25:1-5.
5. Kim JE, Lee C, Park KI, Park MS, Namgung R, Park IK. Successful pleurodesis with OK-432 in preterm infants with persistent pleural effusion. *Korean J Pediatr.* 2012;55:177-180.
6. Cleveland K, Zook D, Harvey K, Woods RK. Massive chylothorax in small babies. *J Pediatr Surg.* 2009;44:546-550.
7. Takahashi Y, Kinoshita Y, Kobayashi T, et al. Management of refractory chylothorax in the neonatal intensive care unit: a 22-year experience. *Pediatr Int.* 2021;64(1):e15043. doi:10.1111/ped.15043
8. ScottoniF FF, Conforti A, Morini F, Bagolan P. Pleurodesis with povidone-iodine for refractory chylothorax in newborns:

- personal experience and literature review. *J Pediatr Surg.* 2015;50:1722-1725.
9. Ono S, Iwai N, Chiba F, Furukawa T, Fumino S. OK-432 therapy for chylous pleural effusion or ascites associated with lymphatic malformations. *J Pediatr Surg.* 2010;45(9):e7-e10. doi:[10.1016/j.jpedsurg.2010.06.010](https://doi.org/10.1016/j.jpedsurg.2010.06.010)
  10. Ogita S, Tsuto T, Deguchi E, Tokiwa K, Nagashima M, Iwai N. OK-432 therapy for unresectable lymphangiomas in children. *J Pediatr Surg.* 1991;26:263-268.

**How to cite this article:** Takahashi Y, Kinoshita Y, Kobayashi T, et al. The usefulness of OK-432 for the treatment of postoperative chylothorax in a low-birth-weight infant with trisomy 18. *Clin Case Rep.* 2022;10:e05844. doi:[10.1002/ccr3.5844](https://doi.org/10.1002/ccr3.5844)