

## Evaluation of Thiel cadaveric model for MRI-guided stereotactic procedures in neurosurgery

Sam Eljamel, Alexander Volovick<sup>1,2</sup>, Timur Saliev<sup>1</sup>, Roos Eisma<sup>3</sup>, Andreas Melzer<sup>1</sup>

Centre for Neurosciences, College of Medicine, Dentistry and Nursing, Ninewells Hospital and Medical School, <sup>3</sup>Department of Neurosurgery, Anatomy and Human Identification College of Life Sciences, Dundee, <sup>1</sup>Department of Anatomy and Human Identification, Institute for Medical Science and Technology, University of Dundee, UK, <sup>2</sup>Department of Imaging at IMSAT and R and D, Department at Insightic, InSightec Ltd., Tirat Carmel, Israel

E-mail: \*Sam Eljamel - [sameljamel@doctors.net.uk](mailto:sameljamel@doctors.net.uk); Alexander Volovick - [AlexanderV@Insightec.com](mailto:AlexanderV@Insightec.com); Timur Saliev - [T.Saliev@dundee.ac.uk](mailto:T.Saliev@dundee.ac.uk);

Roos Eisma - [R.Eisma@dundee.ac.uk](mailto:R.Eisma@dundee.ac.uk); Andreas Melzer - [A.Melzer@dundee.ac.uk](mailto:A.Melzer@dundee.ac.uk)

\*Corresponding Author

Received: 27 December 13 Accepted: 10 March 14 Published: 05 September 14

**This article may be cited as:** Eljamel S, Volovick A, Saliev T, Eisma R, Melzer A. Evaluation of Thiel cadaveric model for MRI-guided stereotactic procedures in neurosurgery. *Surg Neurol Int* 2014;5:S404-9.

Available FREE in open access from: <http://www.surgicalneurologyint.com/text.asp?2014/5/9/404/140199>

Copyright: © 2014 Eljamel S. This is an open-access article distributed under the terms of the Creative Commons Attribution License, which permits unrestricted use, distribution, and reproduction in any medium, provided the original author and source are credited.

### Abstract

**Background:** Magnetic resonance imaging (MRI)-guided deep brain stimulation (DBS) and high frequency focused ultrasound (FUS) is an emerging modality to treat several neurological disorders of the brain. Developing reliable models to train and assess future neurosurgeons is paramount to ensure safety and adequate training of neurosurgeons of the future.

**Methods:** We evaluated the use of Thiel cadaveric model to practice MRI-guided DBS implantation and high frequency MRI-guided FUS in the human brain. We performed three training sessions for DBS and five sonications using high frequency MRI-guided FUS in five consecutive cadavers to assess the suitability of this model to use in training for stereotactic functional procedures.

**Results:** We found the brains of these cadavers preserved in an excellent anatomical condition up to 15 months after embalment and they were excellent model to use, MRI-guided DBS implantation and FUS produced the desired lesions accurately and precisely in these cadaveric brains.

**Conclusion:** Thiel cadavers provided a very good model to perform these procedures and a potential model to train and assess neurosurgeons of the future.

**Key Words:** Assessment, deep brain stimulation, focused ultrasound, magnetic resonance imaging guided, Thiel embalment, training

Access this article  
online

Website:

[www.surgicalneurologyint.com](http://www.surgicalneurologyint.com)

DOI:

10.4103/2152-7806.140199

Quick Response Code:



### INTRODUCTION

The use of computer-assisted neurosurgery is an established technique in functional neurosurgical procedures such as treatment of Parkinson's disease,<sup>[1-4,9,18,29,30]</sup> dystonia,<sup>[35]</sup> tremor<sup>[2,5]</sup> and craniotomy for intracranial lesions,<sup>[12]</sup> and gaining support in the treatment of epilepsy,<sup>[13,31]</sup> chronic pain,<sup>[8,17]</sup> and psychiatric disorders.<sup>[20,26]</sup> These procedures include ablative procedures such as thalamotomy,<sup>[4]</sup> pallidotomy,<sup>[18,30]</sup> anterior cingulotomy, anterior

capsulotomy, and lesionectomy,<sup>[12]</sup> or neurostimulation such as deep brain stimulation (DBS).<sup>[1-5,8,9,13,17,18,20,26,29-31,35]</sup> The main techniques used to generate stereotactic ablative procedures are stereotactic radiofrequency thermal lesioning or stereotactic radiosurgery (SRS). High frequency focused ultrasound (HFFUS), in contrast, is a newer less-invasive technique using ultrasonic energy to thermally ablate a target in the brain. All these techniques are performed without real time feedback or real time anatomical monitoring of the exact size and location of

the lesion or the implant. Computer-assisted magnetic resonance imaging (MRI)-guided focused ultrasound (MgfUS) and MRI-guided DBS implantation are techniques where the exact size or location of the lesion or the implant can be monitored in real time and the size of the lesions can be tailored to the individual patient.

As surgical training is becoming more formalized and had to be delivered in a much shorter time frame, future neurosurgeons may benefit immensely from practicing and mastering their craft in as real as possible scenario before performing these procedures on patients. Furthermore mentors, trainers, and assessors in neurosurgery are under pressure to ensure that neurosurgeons of the future are competent to perform these procedures. We therefore evaluated Thiel cadavers as a model for computer-assisted MRI-guided functional neurosurgery.

## MATERIALS AND METHODS

The study involved Thiel embalmed human cadavers, donated to the Centre for Anatomy and Human Identification at the University of Dundee for medical education and research in accordance to the UK-Anatomy Act (2006). The study was approved by the ethical board responsible for governance of Thiel cadaver program. Table 1 summarizes the background characteristics of cadavers that were used in these procedures. Four cadavers were over 83 years of age at the time of death and the average death to embalming was 72 h (24-144 h). On average the cadavers were in use for 9.4 months (4-15 months) before they were used in this study.

In order to assess the quality of the Thiel cadaver's brain, MRI was used to screen each cadaver prior to its use. MRI scans were performed using 1.5 Tesla GE HDx MRI-machine (Milwaukee, WI). Two sequences were obtained using 8-channels head coil; T2-weighted sequence (TE 89 ms, TR >4000, bandwidth 20.8 kHz) to evaluate the anatomical integrity of the Thiel brain and Fiesta sequence (TE 4.2 ms, TR 7.1 ms, bandwidth 62.5 kHz) to assess amount of air bubbles in the brain.

**Table 1: Summary of Thiel cadavers characteristics**

Cadaver no	Age before death	Gender	Cause of death	Death to embalming (hours)	Time from embalming to use
1	87 years	Female	Coronary heart disease	24	15 months
2	84 years	Female	Cerebrovascular event and sepsis	72	10 months
3	92 years	Female	Congestive heart failure	144	12 months
4	89 years	Male	Congestive heart and renal failure	72	4 months
5	64 years	Female	Non-small cell lung cancer	48	6 months

To study the use of focused ultrasound (FUS) in these cadavers we performed craniotomies to overcome bone and enable us to use the FUS body system. The location of the craniotomies was selected on the basis of providing direct trajectory to the basal ganglia without traversing the ventricle or major sulci. The craniotomies were cited in the frontoparietal area. A skin flap was first raised, followed by drilling four burr holes using standard neurosurgical air driven craniotome. The dura matter was then carefully dissected off the inner surface of the skull to establish clear path between each adjacent burr holes. The cutting craniotome was used to cut the bone between each adjacent burr holes avoiding opening the dura matter and avoiding ingress of air into the intradural cavity. After the bone flap was removed, the craniectomy bone defect above the dura was filled with ultrasonic gel for coupling the ultrasonic probe. Throughout the procedure, the head was fixed using MRI-compatible surgical suite head clamp (GE, Milwaukee, WI).

We evaluated the quality of MRI images, assessed air bubbles, positioning of FUS probe, thermal spot shape produced by computer-assisted MgfUS, influence of aperture (ratio between the transmitting radius and focal distance of FUS) and effect of increasing the acoustic energy on temperature-rise and tissue displacement. Then we assessed cavitation thresholds induced by computer-assisted MgfUS. We also ran three workshops to implant DBS using MRI guidance and SurgiVision ClearPoint system.

### Computer-assisted MgfUS and MRI-thermometry

Computer-assisted MgfUS was performed with ExAblate 2100 Conformal Bone System (InSightec Ltd, Tirat Carmel, Israel) inside 1.5 Telsa MRI (GE, Milwaukee, WI). The FUS system consisted of 1000 elements array transducer with central frequency of 0.55 MHz. The system allows sonications under MRI Proton Resonance Frequency (PRF) according to the following equation:  $\Delta T = \Delta\Phi / \alpha \gamma TE B_0$ , where  $\Delta T$  is the difference in temperature,  $\Delta\Phi$  is the phase shift,  $\gamma$  is the gyromagnetic ratio, TE is the repetition time,  $B_0$  is the magnetic field strength, and  $\alpha$  is a PRF coefficient. In order to assess the tissue response to different physical applications of FUS, a total of 50 sonications were performed on cadavers 2 and 3, using different apertures, different sites in the brain, and different acoustic power levels.

### MRI-acoustic radiation force imaging

MRI-Acoustic radiation force imaging (ARFI) sequence described by Hertzberg *et al.*<sup>[15]</sup> was used to assess tissue displacement of the cadaveric brain. Three different acoustic power levels were used.

### Quality assurance

Thermal spot shape and the level of heating of the Conformal Bone System were assessed in a phantom for quality assurance, the thermal spot shape and heating changed according to the location of the thermal spot.

Therefore, the same sonications in the same locations as in cadavers were performed in tissue mimicking phantom for comparison purposes. The tissue-mimicking phantom is part of the ExAblate system tool-kit and is regularly used for daily Quality Assurance (QA) procedures prior to computer-assisted MgfUS interventions.

### Cavitation threshold

During transmission of ultrasound energy, one of the ultrasonic channels of conformal bone transducer was used as a receiver, collecting reflected signals. Cavitation is a process, where micro-bubbles (gas cavities) are formed due to ultrasonic application. There are two types of cavitation; stable and transient. Stable cavitation defined as gas bubble's oscillation, changing its size and shape according to ultrasonic wave application. This cavitation has an acoustical signature, which can be recorded in frequency domain and is seen as peaks in multiplications (or divisions) of the main transmitting frequency. Transient cavitation is a phenomenon, where the gas bubbles can no longer sustain its size and violently collapse, causing mechanical distraction, rather than thermal ablation. Transient cavitation is seen as a broad-band noise on the frequency domain. As a result of this definition it is expected that the threshold for transient cavitation will be higher than that required for stable cavitation. Figure 1 depicts three types of sonication recordings as seen on the ExAblate 2100 spectrum measurement; no cavitation, stable cavitation, and transient cavitation.

In order to assess cavitation thresholds in this model, sonication with increasing acoustic power levels to determine the cavitation threshold for stable and transient cavitation was performed.

## RESULTS

### Magnetic resonance imaging

The quality of brains depicted by MRI imaging was excellent with good preservation of white gray matter differentiation as seen in Figure 2. The images were of good quality to be used in both the ExAblate and

ClearPoint planning software systems. In addition, there were no concentrations of visible air bubbles.

### Tissue handling

The scalp and bone qualities of Thiel cadavers were excellent. They both handled very well with similar properties to *in vivo* procedures as Thiel embalment techniques preserves cadavers in away the tissues remain soft. The dura matter was often adherent to the inner table of the skull consistent with advanced age of the subjects. Therefore extra care during dissection of the dura matter from the bone was necessary to avoid dural penetration.

### Sonication

Thiel embalmed brains proved to have linear dependence of applied acoustic energy to thermal rise [Figure 3]. In addition, Thiel embalmed brains had linear dependence of tissue displacement as a function of applied power [Figure 4]. The thermal spot shape resembled the spot shape produced in tissue mimicking phantom, moreover, aperture dependence also resembled the sonications in phantom [Figure 5].

### Cavitation threshold

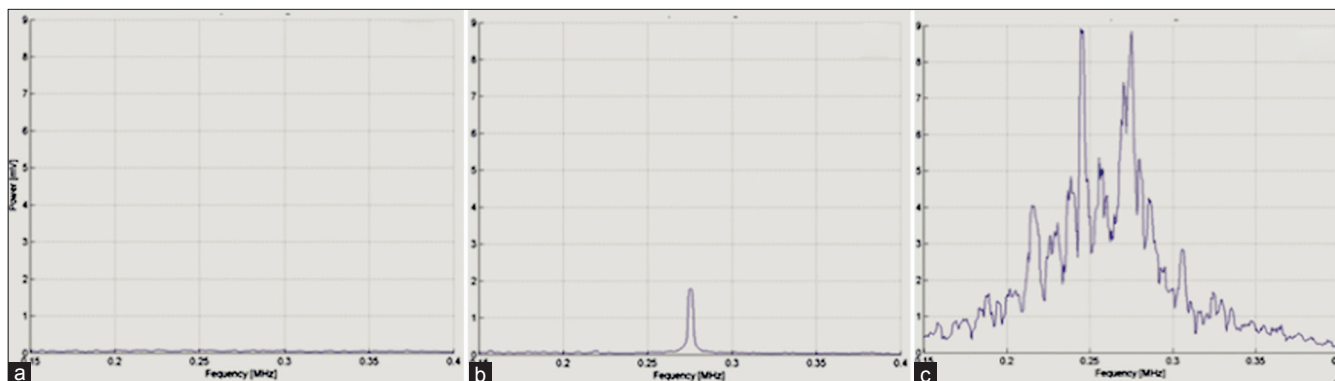
Cavitation threshold was found to be 40 Acoustic Watt for stable cavitation and 60 Acoustic Watt for transient cavitation. Given the sonication location and applied acoustic power, these values are compliant to mechanical index (MI) of 4.3 and 5.3, respectively. However, once the transient cavitation threshold was reached at certain location, transient cavitation was observed at the same location.

### Postprocedure MRI assessment

One major advantage of MgfUS is immediate postprocedure evaluation. Thiel cadaver in these experiments enabled postprocedures evaluation of the location and size of the lesion. Figure 6 depicts immediate postprocedure results [Figure 6].

### MRI-guided DBS implantationx

It was possible to teach residents to implant DBS in Thiel cadavers using MRI guidance and the Surgi-Vision ClearPoint system.

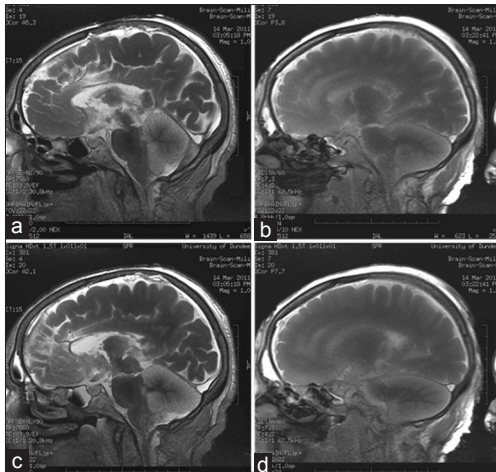


**Figure 1: Cavitation sorting. Maximal spectrum reading for a-no cavitation (cadaver 4, sonication power 20 W). b-stable cavitation (cadaver 4, sonication power 50 W). c-transient cavitation (cadaver 4 sonication power 60 W)**

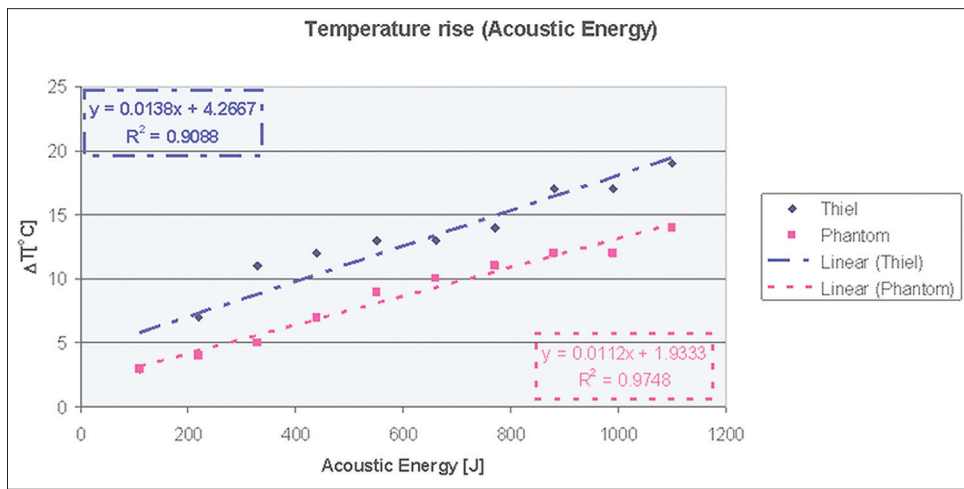
**DISCUSSION**

MRI imaging of Thiel embalmed cadaveric brains suggests great preservation of the brain tissue and revealed suitable imaging characteristics with clear differentiation between

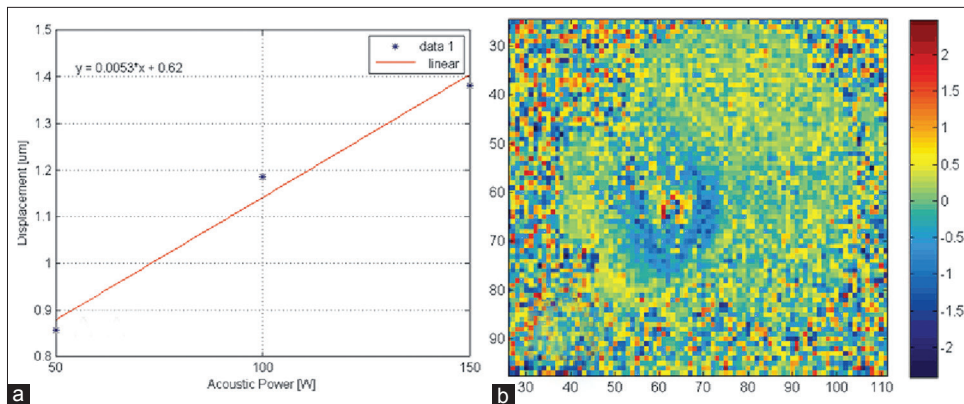
white and gray matters. The long-term usability of these cadavers up to 15 months makes the Thiel embalmed cadaver an excellent model for any other computer-assisted image-guided minimally invasive neurosurgery for training, such as DBS insertion. Life-like tissue flexibility simulates operative procedures in the operation room and far exceeds the properties of formalin-embalmed cadavers<sup>[11]</sup> and equals the quality of fresh cadavers without the constraints of rapid decay and infection risk. Other authors found similar advantages of Thiel cadavers in extracranial applications.<sup>[6,14,16,20-24]</sup> The ability to focus the ultrasonic beam and linear temperature and displacement behavior of the Thiel cadaveric brain tissue suggests that Thiel embalmed cadavers can be used for developing and testing various stereotactic functional neurosurgical procedures and establishing treatment envelope limits, focusing algorithms, and skull heating effects using HFFUS. However, there was significant difference of MRI-temperature mapping between sonications of Thiel embalmed brain tissue and tissue mimicking phantom. This can be explained by the fact that the PRF coefficient ( $\alpha$ ) is different between normal brain because of its increased water content and cerebral perfusion and Thiel



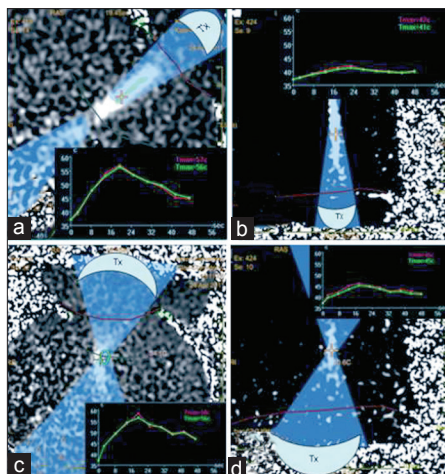
**Figure 2: MRI imaging of the brain of Thiel embalmed cadaver 3. a, c -T2-weighted Fast Spin Echo (TR/TE=89.9/7560 ms, bw=20.8 kHz). b, d-FIESTA pulse sequence (TR/TE=4.2/7.3 ms, BW=62.5 kHz)**



**Figure 3: Graph of thermal rise as a function of applied acoustic energy, performed on Cadaver 3**



**Figure 4: MR-ARFI, a-graph of displacement as a function of applied acoustic power and b-displacement map for applied acoustic power of 100 W (applied on Cadaver 3)**

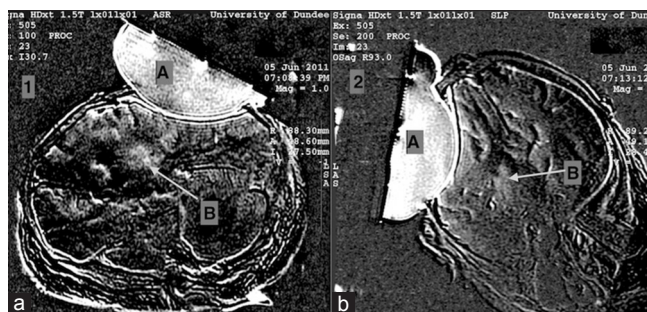


**Figure 5: Thermal spot shapes as seen on Cadaver 2 and tissue mimicking phantom. a,c-sonication on Thiel embalmed cadaver with and ó of the transmitting transducer, respectively. b, d- sonication on phantom with the same parameters as been used for cadaver sonications**

preservation fluid. Another possible explanation is that the embalming process could change the heat capacity properties of the brain and its elasticity. Future testing needs to be calibrated and scaled to fit the *in vivo* tissue behavior. The relatively low cavitation threshold is in line with the work of Benkhadra *et al.*,<sup>[7]</sup> who observed a higher echogenicity of the Thiel embalmed cadavers compared with fresh cadavers. The authors believe that improved embalment and storage processes dedicated to this purpose would reduce this threshold. Nevertheless the ability to create cavitation can be used for transcranial cavitation studies. For most training and testing purposes, postprocedure assessment can be achieved by immediate MRI imaging. Future Thiel embalmed tissue characterization, PRF coefficient measurements, and embalming techniques are currently being investigated and likely to answer these questions. Several groups already reported small series using computer-assisted MgfUS to treat functional and other conditions such as tumors.<sup>[19,22,24,25,28]</sup> As computer-assisted MgfUS applications emerge, it is important to study its effects in as real as possible conditions and provide a platform for training and assessing competence in these procedures. Thiel cadavers using Thiel embalment techniques<sup>[32,33]</sup> provides better and more realistic operative and positioning conditions compared with animal models.<sup>[10,21,27,34]</sup> We used this model to run three successful MRI-guided DBS implantation courses to train residents as an example of using it as a model in teaching and learning MRI-guided stereotactic procedures.

## CONCLUSIONS

A Thiel embalmed cadaveric model to develop, assess, and monitor minimally invasive computer-assisted MgfUS neurosurgical procedures and to train residents



**Figure 6: Subtraction Images of Coronal (1) and axial (2) T2-weighted MRI images of Thiel cadaver brain. These images were produced by subtracting preoperative images from postoperative images to demonstrate tissue damage (b), a= the ExAblate probe**

in MRI-guided DBS implantation was developed. Thiel embalmed cadaveric brains are anatomically matched model for any computer-assisted MR-guided brain-related minimal intervention procedures.

## ACKNOWLEDGMENTS

The research leading to these results received funding from InSightec Ltd and the European Community's Seventh Framework Programme (FP7/2007-2013) under grant agreement no 230674 (Nanoporation project) and no 238802 (IIIOS project).

The authors would like to thank Ms. Osnat Dogadkin of InSightec Ltd for her help with the MRI parameters tweaking. The authors would also like to express their gratitude to Ms. Helen Mcleod and Mr. Ioannis Karakitsios of Institute for Medical Science and Technology for their help during the experimental work. We also like to acknowledge the support we have received during the DBS courses from SurgiVision, BrainLab and GE.

## REFERENCES

1. Benabid AL, Benazzouz A, Hoffmann D, Limousin P, Krack P, Pollak P. Long-term electrical inhibition of deep brain targets in movement disorders. *Mov Disord* 1998;13 Suppl 3:119-25.
2. Benabid AL, Pollak P, Seigneuret E, Hoffmann D, Gay E, Perret J. Chronic VIM thalamic stimulation in Parkinson's disease, essential tremor and extra-pyramidal dyskinesias. *Acta Neurochir Suppl (Wien)* 1993;58:39-44.
3. Benabid AL, Pollak P, Gross C, Hoffmann D, Benazzouz A, Gao DM, *et al.* Acute and long-term effects of subthalamic nucleus stimulation in Parkinson's disease. *Stereotact Funct Neurosurg* 1994;62:76-84.
4. Benabid AL, Pollak P, Louveau A, Henry S, de RJ. Combined (thalamotomy and stimulation) stereotactic surgery of the VIM thalamic nucleus for bilateral Parkinson disease. *Appl Neurophysiol* 1987;50:344-6.
5. Benito-Leon J, Louis ED. Clinical update: Diagnosis and treatment of essential tremor. *Lancet* 2007;369:1152-4.
6. Benkhadra M, Bouchot A, Gerard J, Genlot D, Trouilloud P, Martin L, *et al.* Flexibility of Thiel's embalmed cadavers: The explanation is probably in the muscles. *Surg Radiol Anat* 2011;33:365-8.
7. Benkhadra M, Faust A, Ladoire S, Trost O, Trouilloud P, Girard C, *et al.* Comparison of fresh and Thiel's embalmed cadavers according to the suitability for ultrasound-guided regional anesthesia of the cervical region. *Surg Radiol Anat* 2009;31:531-5.
8. Bittar RG, Kar-Purkayastha I, Owen SL, Bear RE, Green A, Wang S, *et al.* Deep brain stimulation for pain relief: A meta-analysis. *J Clin Neurosci* 2005;12:515-9.

9. Blond S, Siegfried J. Thalamic stimulation for the treatment of tremor and other movement disorders. *Acta Neurochir Suppl (Wien)* 1991;52:109-11.
10. Cohen ZR, Zaubermann J, Harnof S, Mardor Y, Nass D, Zadicario E, et al. Magnetic resonance imaging-guided focused ultrasound for thermal ablation in the brain: A feasibility study in a swine model. *Neurosurgery* 2007;60:593-600.
11. Eisma R, Mahendran S, Majumdar S, Smith D, Soames RW. A comparison of Thiel and formalin embalmed cadavers for thyroid surgery training. *Surgeon* 2011;232:142-6.
12. Eljamel MS, Hofer M. From letterbox to keyhole approach for resecting intracranial lesions. *Stereotact Funct Neurosurg* 2003;81:30-6.
13. Fisher R, Salanova V, Witt T, Worth R, Henry T, Gross R, et al. Electrical stimulation of the anterior nucleus of thalamus for treatment of refractory epilepsy. *Epilepsia* 2010;51:899-908.
14. Giger U, Fresard I, Hafliker A, Bergmann M, Krahenbuhl L. Laparoscopic training on Thiel human cadavers: A model to teach advanced laparoscopic procedures. *Surg Endosc* 2008;22:901-6.
15. Hertzberg Y, Volovick A, Zur Y, Medan Y, Vitek S, Navon G. Ultrasound focusing using magnetic resonance acoustic radiation force imaging: Application to ultrasound transcranial therapy. *Med Phys* 2010;37:2934-42.
16. Holze F, Franz EP, Lehmbrock J, Weihe S, Teistra C, Deppe H, et al. Thiel embalming technique: A valuable method for teaching oral surgery and implantology. *Clin Implant Dent Relat Res* 2012;14:121-6.
17. Hosobuchi Y, Adams JE, Rutkin B. Chronic thalamic stimulation for the control of facial anesthesia dolorosa. *Arch Neurol* 1973;29:158-61.
18. Latinen LV, Bergenheim AT, Hariz MI. Leksell's posteroventral pallidotomy in the treatment of Parkinson's disease. *J Neurosurg* 1992;76:53-61.
19. Martin E, Jeanmonod D, Morel A, Zadicario E, Werner B. High intensity focused ultrasound for non-invasive functional neurosurgery. *Ann Neurol* 2009;66:858-61 doi: 10.1002.
20. Mayberg HS, Lozano AM, Voon V, McNeely HE, Seminowicz D, Hamani C, et al. Deep brain stimulation for treatment-resistant depression. *Neuron* 2005;45:651-60.
21. McDannold N, Arvanitis CD, Vykhodtseva N, Livingstone MS. Temporary disruption of the blood-brain barrier by use of ultrasound and microbubbles: Safety and efficacy evaluation in rhesus macaques. *Cancer Res* 2012;72:3652-63.
22. McDannold N, Clement GT, Black P, Jolesz F, Hynynen K. Transcranial magnetic resonance imaging guided focused ultrasound surgery of brain tumors: Initial findings in 3 patients. *Neurosurgery* 2010;66:323-32.
23. McLeod G, Eisma R, Schwab A, Corner G, Soames R, Cochran S. An evaluation of the Thiel embalmed cadavers for ultrasound based regional anaesthesia training and research. *Ultrasound* 2010;18:125-9.
24. Medel R, Crowley RW, McKisic MS, Dumont AS, Kassel NF. Sonothrombolysis: An emerging modality for the management of stroke. *Neurosurgery* 2009;65:979-93.
25. Medel R, Monteith SJ, Elias WJ, Eames M, Snell J, Sheehan JP, et al. Magnetic resonance-guided focused ultrasound surgery: Part 2: A review of current and future applications. *Neurosurgery* 2012;71:755-63.
26. Nuttin B, Cosyns P, Demeulemeester H, Gybels J, Meyerson B. Electrical stimulation in anterior limbs of internal capsules in patients with obsessive-compulsive disorder. *Lancet* 1999;354:1526.
27. Pernet M, Aubry JF, Tanter M, Boch AL, Kujas M, Fink M. Ultrasonic transcranial brain therapy: First *in vivo* clinical investigation on 22 sheep using adaptive focusing. *Proceedings of the IEEE Ultrasonics Symposium 09/2004*; DOI: 10.1109/ULTSYM.2004.1417940 ISBN: 0-7803-8412-1 In proceeding of: Ultrasonics Symposium, 2004 IEEE, Volume: 2 doi: 0-7803-8412-1/04.
28. Ram Z, Cohen ZR, Harnof S, Tal S, Faibel M, Nass D, et al. Magnetic resonance imaging-guided, high-intensity focused ultrasound for brain tumor therapy. *Neurosurgery* 2006;59:949-56.
29. Siegfried J, Lippitz B. Bilateral chronic electrostimulation of ventroposterolateral pallidum: A new therapeutic approach for alleviating all parkinsonian symptoms. *Neurosurgery* 1994;35:1126-9.
30. Sventnilson E, Torvik A, Lowe R, Leksell L. Treatment of Parkinsonism by stereotactic thalamotomy in the pallidal region. A clinical evaluation of 81 cases. *Acta Psychiatr Scand* 1960;35:358-77.
31. Tellez-Zenteno JF, Dhar R, Wiebe S. Long-term seizure outcomes following epilepsy surgery: A systematic review and meta-analysis. *Brain* 2005;128:1188-98.
32. Thiel W. Supplement to the conservation of an entire cadaver according to W. Thiel. *Ann Anat* 2002;184:267-9.
33. Thiel W. Die Konservierung ganzer Leichen in natürlichen Farben. The preservation of the whole corpse with natural color. *Ann Anat* 1992;174:185-95.
34. Treat LH, McDannold N, Vykhodtseva N, Zhang Y, Tam K, Hynynen K. Targeted delivery of doxorubicin to the rat brain at therapeutic levels using MRI-guided focused ultrasound. *Int J Cancer* 2007;121:901-7.
35. Vidailhet M, Vercueil L, Houeto JL, Krystkowiak P, Benabid AL, Cornu P, et al. Bilateral deep-brain stimulation of the globus pallidus in primary generalized dystonia. *N Engl J Med* 2005;352:459-67.