



Pancreatic candidiasis in a cat

Kelsey Renner¹ , Sarah Hill¹, Alex Grinberg² and Amy Weeden³

Journal of Feline Medicine and Surgery Open Reports
1–5

© The Author(s) 2021

Article reuse guidelines:

sagepub.com/journals-permissions

DOI: 10.1177/20551169211052889

journals.sagepub.com/home/jfmsopenreports

This paper was handled and processed

by the European Editorial Office (ISFM)

for publication in *JFMS Open Reports*



Abstract

Case summary An 11-year-old female spayed Maine Coon cat was referred for assessment of hyporexia, weight loss, vomiting and diarrhoea. An abdominal ultrasound revealed an enlarged and hypoechoic pancreas containing two large fluid-filled structures. Fine-needle aspiration of the cyst-like structures was performed, and cytology revealed moderate-to-marked predominantly suppurative inflammation with yeast cells. *Candida glabrata* was cultured from the fluid. The patient was treated with oral itraconazole and the clinical signs resolved, although repeat abdominal ultrasound and cytology revealed persistence of the infected cyst-like structures. The patient remained asymptomatic for 8 months after the discontinuation of antifungal medications, despite the persistence of the pancreatic infection with *C glabrata*.

Relevance and novel information To our knowledge, this is the first report of pancreatic infection with *Candida* species in a cat, followed by a chronic subclinical infection persisting for at least 8 months after treatment discontinuation.

Keywords: *Candida glabrata*; pancreatic cysts; pancreatitis; diabetes mellitus

Accepted: 24 September 2021

Introduction

Candida species are commensal in a range of hosts, including humans, cats and dogs.^{1–3} They commonly inhabit the gastrointestinal tract, lower urinary tract and upper respiratory tract.^{1,3} Internal organ candidiasis is well described in humans, but there are few publications on infection in domestic animals.³ In the reported cases, the lower urinary tract is the most common site of infection.^{4,5} However, single cases of cholecystitis and alimentary granulomas have been described in cats, and several cases of fungal peritonitis have been described in dogs.^{1,2,6,7}

Disruption of cutaneous or mucosal surfaces is usually required for *Candida* species to cause internal organ infections. In both humans and animals, concurrent illness, underlying immune suppression, antibiotic use and indwelling catheters are considered predisposing factors for candidiasis. Diseases such as diabetes mellitus, feline immunodeficiency virus and feline leukaemia virus have also been found to predispose to *Candida* infections in cats.^{1–4} *Candida albicans* is the most prevalent *Candida* species causing disease in humans and is the most common species reported in companion animals.^{1,2,6–8}

To our knowledge, this is the first case of pancreatic infection with *Candida* species in a cat. Histopathology

was not performed in this case; therefore, we could not definitively diagnose the fluid-filled pancreatic structures as cysts. For simplicity, we defined these fluid-filled structures within the pancreas as cyst-like.

Case description

A 11-year-old female spayed Maine Coon cat was referred for investigation of reduced appetite, polydipsia (PD), polyuria (PU), weight loss, vomiting and diarrhoea of 3 months' duration. The patient had been diagnosed with diabetes mellitus by the referring veterinarian 2 weeks prior to referral and insulin therapy (Caninsulin; MSD

¹Animal Referral Centre, Department of Internal Medicine, Auckland, New Zealand

²Massey University, School of Veterinary Science, Palmerston North, New Zealand

³Gribbles Veterinary Pathology New Zealand, Auckland, New Zealand

Corresponding author:

Kelsey A Renner BVSc, Animal Referral Centre, Department of Internal Medicine, 224 Albany Highway, Schnapper Rock, Auckland 0632, New Zealand
Email: kelseyrenner@hotmail.co.nz



Creative Commons Non Commercial CC BY-NC: This article is distributed under the terms of the Creative Commons

Attribution-NonCommercial 4.0 License (<https://creativecommons.org/licenses/by-nc/4.0/>) which permits non-commercial use, reproduction and distribution of the work without further permission provided the original work is attributed as specified on the SAGE and Open Access pages (<https://us.sagepub.com/en-us/nam/open-access-at-sage>).

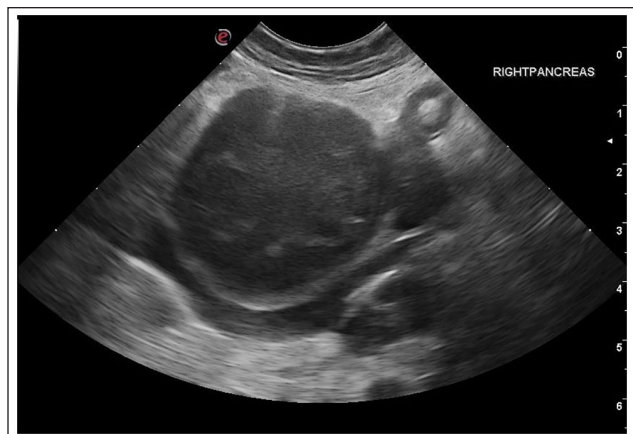

Figure 1 Ultrasound image of one of the pancreatic cystic structures at the time of diagnosis. Large, spherical structure filled with anechoic fluid within the hypoechoic pancreas

Animal Health) had been started. At the time of referral, the patient was receiving 6 IU in the morning and 1 IU in the evening. The owner reported that the patient's appetite had improved slightly since starting treatment; however, PU/PD persisted and the patient continued to lose weight.

Two weeks prior to referral, a complete blood count showed a mild-to-moderate non-regenerative anaemia ($4.47 \times 10^{12}/l$; reference interval [RI] 4.8–9) with mild lymphopenia ($1.0 \times 10^9/l$; RI 1.5–7) and a normal neutrophil count with a left shift and mild toxic change ($6.7 \times 10^9/l$; RI 2.5–12.5). Biochemistry performed at the same time revealed mild hypoalbuminemia (29 g/l; RI 33–43). Blood glucose, total thyroxine and fructosamine were also measured and were 21.8 mmol/l (RI 3.0–7.0), 11.7 nmol/l (RI 17–43) and 509 μ mol/l (RI 178–304), respectively. Feline pancreatic-specific lipase (Spec fPL; IDEXX) levels were consistent with pancreatitis (25.7 μ g/l; RI 0–5.4). Abdominal and thoracic radiographs taken by the referring veterinarian were interpreted by a board-certified radiologist, who concluded that there was free abdominal fluid, a large soft tissue structure in the left cranial quadrant of the abdomen and a small cranial mediastinal mass, which was most likely caused by summation artefact of a collapsed portion of the left cranial lung lobe.

At the time of referral, the patient was bright and alert, with normal vital parameters. The cat had a body condition score of 7/9, and a greasy coat. The physical examination, including abdominal palpation and thoracic auscultation, was unremarkable.

Abdominal ultrasound revealed an enlarged and hypoechoic pancreas that contained two large cystic structures with diameters of 3.5 cm and 2.7 cm, respectively (Figure 1). The surrounding mesentery was diffusely hyperechoic, and there was a scant amount of

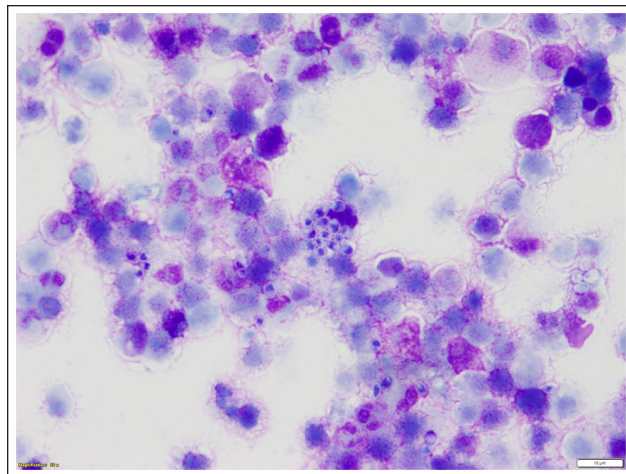


Figure 2 Direct smear of the pancreatic fluid. Abundant necrotic debris and several degenerate neutrophils are present. There is a central cluster of *Candida* yeast with additional yeast scattered throughout the image (modified Diff Quick stain $\times 500$)

anechoic abdominal fluid present. The abdominal ultrasound findings were supportive of severe pancreatitis. Fine-needle aspiration of the cysts was performed under sedation. The patient was sedated with 0.2 mg/kg intravenous (IV) butorphanol (Butorgesic; Ilium) and 0.2 mg/kg midazolam IV (Midazolam; Pfizer). Alfaxalone (Alfaxan; Jurox Animal Health) was administered IV during the procedure, as required, to maintain sedation. The abdomen was clipped and prepped using an aseptic technique. A 25 G 1.5" hypodermic needle was introduced percutaneously into the cystic structures using ultrasound guidance. A 3 ml syringe was used to aspirate fluid from both cysts. A total of 10 ml of cream-coloured, turbid fluid was drained from the cysts. The fluid was collected in sterile plain and EDTA specimen tubes, and fresh smears were made. Complete drainage of the cysts could not be achieved as a result of the needles becoming obstructed.

The fluid samples were submitted to a commercial clinical veterinary laboratory (Gribbles Veterinary, Mt Wellington, Auckland, New Zealand) for cytology. Direct smears stained with Modified Diff Quick revealed a moderate-to-marked, predominantly neutrophilic inflammation and numerous oval, teardrop and round 3–5 μ m yeasts with thin, clear capsules and mottled basophilic cytoplasm (Figure 2). Aerobic bacterial culture yielded a heavy growth of yeasts on the plate, suggestive of *Candida* species, but no bacterial colonies were observed. Fungal culture was also performed, and the yeast submitted for identification by matrix-assisted laser desorption/ionisation-time of flight mass spectrometry (MALDI-TOF) at a human laboratory, and was confirmed as *Candida glabrata*, with an identification

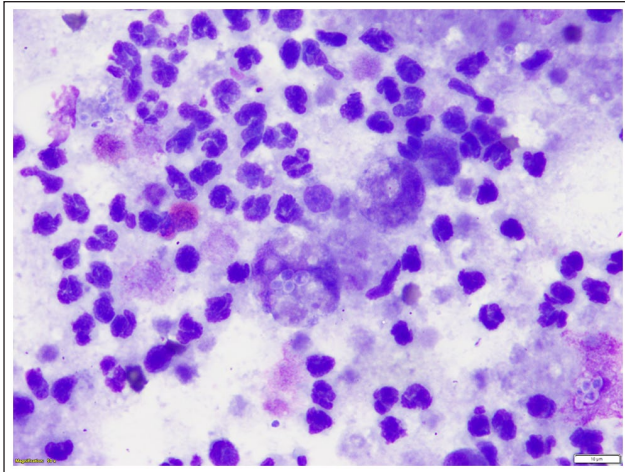


Figure 3 Concentrated cytocentrifuged smear of the post-treatment pancreatic fluid. Yeasts were not identified in the direct smears, but they were identified in the concentrated smear. There are numerous neutrophils, as well as two macrophages, near the centre of the image. The partially degraded macrophage below centre contains four yeasts. There are also extracellular yeasts at the top left and right and lower right of the image (modified Diff Quick stain $\times 500$)

score of 2.11 (high confidence identification). Antifungal sensitivities could not be performed at this laboratory.

Following the culture result, the patient was prescribed 11 mg/kg q24h PO itraconazole (Itrazole; Mylan) for 4 weeks. The insulin protocol was changed to 4IU Caninsulin q12h subcutaneously, owing the patient's persistent PU/PD and continued weight loss. It was recommended that if glycaemia control was not achieved with this regime, then a different insulin (Insulin Glargine; Lantus) should be administered instead of Caninsulin.

A repeat abdominal ultrasound was performed 1 week prior to finishing the 4-week course of itraconazole. At this time, the owner reported that the patient's energy levels, thirst and urination had returned to normal and its appetite had improved significantly. The patient was bright and alert with a normal physical examination. Ultrasonography revealed that the pancreas remained markedly abnormal, with four cystic structures measuring 1–2 cm in diameter present. Using the same technique described above, but without sedation, fluid was collected from the largest cyst. The cystic fluid was clear. Cytology revealed mild-to-moderate mixed, predominantly non-degenerate neutrophilic inflammation and very low numbers of oval, teardrop and round 2–3 μm diameter yeast cells (Figure 3). Fungal culture produced a light growth of *C glabrata*. A further 2-month course of itraconazole at the same dosage was prescribed.

The patient was presented for a repeat ultrasound 4 months after completion of the 3-month course of itraconazole. A repeat ultrasound was recommended before

discontinuation of the itraconazole; however, financial constraints prevented this. The owner reported that the cat had gained weight and was well at home. The cat's appetite, thirst and frequency of urination were reportedly normal. The patient was administered insulin as prescribed. At examination, the patient was bright and alert with normal vital parameters. The cat had gained weight since the last visit (10.8 kg) and had a body condition score of 8/9. The abdominal ultrasound revealed a markedly enlarged pancreas containing two large cystic structures, 18.5 mm and 9.6 mm in diameter, respectively. The surrounding mesentery was diffusely hyperechoic. One of the cystic structures was sampled using the same technique as for the second aspiration. A concentrated, cyto-centrifuged smear stained with modified Diff Quick revealed moderate-to-marked, predominantly degenerate neutrophilic inflammation with occasional yeast cells. A mixed bacterial population composed of bacilli, filamentous bacteria and cocci was present on the smears stained with modified Diff Quick, with occasional phagocytosed cocci. Fungal and aerobic bacterial culture revealed moderate growth of *C glabrata* and a light growth of a coagulase-negative *Staphylococcus* species.

No further treatment was recommended as the patient was asymptomatic. Ten months after treatment the patient remained clinically well and was reported to have a good appetite, was maintaining weight and no longer showing signs of PU/PD.

Discussion

Candidiasis most commonly involves the urinary tract in cats and dogs, and internal organ candidiasis seems to be uncommon in companion animals, with little published literature describing such infections. To our knowledge, this is the first report of pancreatic candidiasis in a companion animal.

This case posed a number of therapeutic challenges. Treatment protocols for candidiasis are largely based on human literature.^{4,5} Oral fluconazole is the recommended therapy for the treatment of symptomatic candiduria in humans. A 2-week course is recommended by the Infectious Diseases Society of America.⁸ There are three recognised lesions associated with pancreatic infections in humans: infected pancreatic necrosis; infected pseudocyst; and pancreatic abscess.⁹ Pancreatic infections in humans are most commonly bacterial, and are typically endogenous, involving enteric flora. Fungal pancreatitis is described less frequently in the human literature, with *Candida* species being the most common fungi involved.^{9–11} Similarly to bacterial infections, it is believed that fungal pancreatic infections originate from an endogenous source.⁹ The virulence of the specific invading *Candida* strain also seems to contribute to the pathogenesis of this infection.^{9,10}

Conditions that result in an altered immune response, such as steroid use, chemotherapy, advanced age and comorbidities such as diabetes mellitus are reported risk factors to fungal pancreatic infections in humans.^{9,12}

Fungal pancreatitis in humans is usually associated with severe acute pancreatitis and patients are often critically ill.^{10,12} In contrast, this patient was stable and outpatient treatment was appropriate.

Feline pancreatitis is commonly associated with concurrent disease processes, including hepatobiliary disease, inflammatory bowel disease and diabetes mellitus.¹³ Concurrent pancreatitis, hepatobiliary disease and inflammatory bowel disease in cats is termed triaditis, and occurs in 50–56% of cats diagnosed with pancreatitis.¹³ The pathogenesis of pancreatitis in triaditis is unclear; however, translocation of enteric bacteria into the duodenal papilla and subsequently into the pancreas and biliary tract has been proposed. This hypothesis has been supported by several studies that have successfully identified enteric bacteria in the pancreas and hepatobiliary tract.^{14,15} Dysbiosis resulting from intestinal inflammation, altered immune response and increased intraduodenal pressure during vomiting has been proposed as inciting causes of bacterial translocation to the pancreas.^{13,16}

The patient in this case had several risk factors for candidiasis. First, the cat presented with poorly controlled diabetes. Secondly, it had a history of vomiting, which has been proposed as an inciting cause of bacterial translocation; and, thirdly, the patient may have had intestinal inflammation secondary to pancreatitis. Similar to the pathogenesis of bacterial translocation, it is possible that commensal intestinal *Candida* were permitted to ascend into the pancreas through the duodenal papilla.

Treatment of pancreatic infections is well described in humans. The standard of care for bacterial pancreatic infections in humans has been necrosectomy and postoperative drainage in combination with systemic antibacterial therapy. In the absence of established specific guidelines, the same approach is commonly adopted for fungal infections.^{9,10} Recently, less invasive procedures such as percutaneous drainage and laparoscopic necrosectomy have been introduced as an alternative to laparotomy.^{9,10,17}

Surgical debridement of the cystic structures was not an option in this case owing to financial constraints. Thus, percutaneous drainage in conjunction with antifungal therapy was chosen. The patient may have had a partial response to treatment, as there was an apparent reduction in the fungal load within the cystic fluid and resolution of patient's clinical signs. Lack of complete resolution of the infection may have been due to not all the fluid being drained percutaneously owing to the needle becoming repeatedly obstructed, or fungal material adhered to the tissue. Persistent chronic pancreatitis and poorly controlled diabetes could have also contributed to the ongoing infection.

Ideally, regular blood glucose monitoring would have been performed to ensure euglycaemia without hypoglycaemia, as recommended in the ISFM consensus guidelines on the practical management of diabetes mellitus in cats.¹⁸ In this case, insulin adjustment was based on persistent signs of hyperglycaemia (PU/PD, persistent weight loss) alone, as blood glucose monitoring in hospital was unsuccessful as the patient would not eat in clinic, and at home glucose monitoring was not an option for this client. The patient's PU/PD resolved, and it gained weight after adjusting the insulin dose. Therefore, we continued to use these parameters to monitor diabetic control.

The presence of bacteria in the most recent sample of cystic fluid was unexpected, as it was not cultured from the first two samples. The introduction of bacteria into the pancreas during the previous aspiration is a possibility, as is translocation of intestinal bacteria via the duodenum. Specimen contamination was an unlikely cause, as cytological examination revealed phagocytosed cocci. Regardless of the cause, the infection was subclinical in this patient given the lack of clinical signs at the time of diagnosis.

The use of antifungal medications in domestic animals is not well documented, so we extrapolated doses and duration of treatment from human medicine. Also, few antifungal medications are licensed for veterinary species, forcing the use of medications off-label.³ Generally, the duration of treatment with antifungal medications is greater than with antibiotics, often months, due to the slow growth rate of fungi and the fact that antifungal medications are fungistatic.

The majority of case reports in human literature document amphotericin B as the medication of choice to treat fungal pancreatic infections;¹⁰ however, amphotericin B must be given by slow IV infusion.¹⁹ Fluconazole has good penetration in humans with acute pancreatitis and had comparable efficacy to amphotericin B in the treatment of fungal pancreatitis.^{9,10,20,21} Fluconazole and itraconazole have been used to treat several cases of *Candida* in animals, including peritonitis, cholecystitis, urinary tract infections and intestinal granulomatous disease, with encouraging results.^{1,2,6,7} Ideally, antifungal therapy would have been based on susceptibility results; however, this could not be performed in New Zealand. Itraconazole was chosen because of its encouraging results in veterinary species and convenient tablet size.

The duration of treatment was intended to be determined by culture result. A negative culture result was not achieved after a 12-week course of itraconazole. Interestingly, the patient remained free of clinical signs for 8 months after stopping the itraconazole. Surgical debridement may have resolved the infection, but this could not be justified in an asymptomatic patient.

It is unclear whether the cause of the patient's presenting clinical signs was due to the pancreatic infection, pancreatitis or poorly controlled diabetes. It is also not possible to conclude whether the patient's resolution of clinical signs was a result of better glycaemic control, or the marked reduction in *Candida* growth.

Conclusions

We describe the first report of pancreatic candidiasis in a companion animal. The clinical significance of this infection remains unclear, as the patient's clinical signs resolved despite persistence of *C glabrata* for several months within the pancreas.

Conflict of interest The authors declared no potential conflicts of interest with respect to the research, authorship, and/or publication of this article.

Funding The authors received no financial support for the research, authorship, and/or publication of this article.

Ethical approval This work involved the use of non-experimental animals only (including owned or unowned animals and data from prospective or retrospective studies). Established internationally recognised high standards ('best practice') of individual veterinary clinical patient care were followed. Ethical approval from a committee was therefore not specifically required for publication in *JFMS Open Reports*.

Informed consent Informed consent (either verbal or written) was obtained from the owner or legal custodian of all animal(s) described in this work (either experimental or non-experimental animals) for the procedure(s) undertaken (either prospective or retrospective studies). For any animals or humans individually identifiable within this publication, informed consent (either verbal or written) for their use in the publication was obtained from the people involved.

ORCID iD Kelsey Renner  <https://orcid.org/0000-0002-5680-4257>

References

- Duchaussory A, Rose A, Talbot J, et al. **Gastrointestinal granuloma due to *Candida albicans* in an immunocompetent cat.** *Med Mycol Case Rep* 2015; 10: 14–17.
- Palermo SM, Newman AW and Koch MW. ***Candida albicans* cholecystitis with associated hepatitis in a cat.** *JFMS Open Rep* 2019; 5. DOI: 10.1177/2055116919854165.
- Sykes J. Candidiasis. In: Sykes J (ed). *Canine and feline infectious diseases*. St Louis, MO: Elsevier Saunders, 2014, pp 653–660.
- Reagan K, Dear J, Kass P, et al. **Risk factors for *Candida* urinary tract infections in cats and dogs.** *J Vet Intern Med* 2019; 33: 648–653.
- Toll J, Ashe C and Trepanier L. **Intravesicular administration of clotrimazole for treatment of candiduria in a cat with diabetes mellitus.** *J Am Vet Med Assoc* 2013; 223: 1156–1158.
- Bradford K, Meinkoth J, McKeirnen K, et al. ***Candida* peritonitis in dogs: report of 5 cases.** *Vet Clin Pathol* 2013; 42: 227–233.
- Ong R, Raisis A and Swindells K. ***Candida albicans* peritonitis in a dog.** *Vet Emerg Crit Care Soc* 2010; 20: 143–147.
- Pappas PG, Kauffman CA, Andes DR, et al. **Clinical practice guidelines for the management of Candidiasis: 2016 update by the Infectious Diseases Society of America.** *Clin Infect Dis* 2016; 62: 1–50.
- Shanmugam N, Isenmann R, Barkin J, et al. **Pancreatic fungal infection.** *Pancreas* 2003; 27: 133–138.
- Kochhar R, Noor M and Wig J. **Fungal infections in severe acute pancreatitis.** *J Gastroenterol Hepatol* 2011; 26: 952–959.
- Kumar S, Bandyopadhyay M, Bhattacharyya K, et al. **A rare case of pancreatic abscess due to *Candida Tropicalis*.** *J Global Infect Dis* 2011; 3: 396–398.
- Seong M, Kang T and Ha S. **Pancreatic candidiasis that mimics a malignant pancreatic cystic tumor on magnetic resonance imaging: a case report in an immunocompetent patient.** *Korean J Radiol* 2015; 16: 1253–1256.
- Simpson KW. **Pancreatitis and triaditis in cats: causes and treatment.** *J Small Anim Pract* 2015; 56: 40–49.
- Brain P, Barrs V, Martin P, et al. **Feline cholecystitis and acute neutrophilic cholangitis: clinical findings, bacterial isolates and response to treatment in six cases.** *J Feline Med Surg* 2006; 8: 91–103.
- Simpson K. Culture-independent detection of bacteria in feline pancreatitis. 21st ACVIM Forum; 2011 Jun 15–18; Denver, CO, USA. American College of Veterinary Internal Medicine. Denver, pp 507–508.
- Janeczko S, Atwater D, Bogel E, et al. **The relationship of mucosal bacteria to duodenal histopathology, cytokine mRNA, and clinical disease activity in cats with inflammatory bowel disease.** *Vet Microbiol* 2008; 128: 178–193.
- Wronski MC, W, Karkocha D, Slodkowski M, et al. **Ultrasound-guided percutaneous drainage of infected pancreatic necrosis.** *Surg Endosc* 2013; 27: 2841–2848.
- Sparkes A, Cannon M, Church D, et al. **ISFM consensus guidelines on the practical management of diabetes mellitus in cats.** *J Feline Med Surg* 2015; 17: 235–250.
- Plumb D. *Plumb's veterinary drug handbook*. 9th ed. Stockholm, WI: John Wiley and Sons, 2018.
- Shrikhande S, Friess H, Issenegger C, et al. **Fluconazole penetration into the pancreas.** *Antimicrob Agents Chemother* 2000; 44: 2569–2571.
- Rex J, Bennett JE, Sugar A, et al. **A randomised trial comparing fluconazole with amphotericin B for the treatment of candidemia in patients without neutropenia.** *N Engl J Med* 1994; 1325–1330.