

Review

# Interference screws vs. suture anchors for isolated medial patellofemoral ligament femoral fixation: A systematic review

Filippo Migliorini<sup>a,\*</sup>, Alice Baroncini<sup>a</sup>, Jörg Eschweiler<sup>a</sup>, Markus Tingart<sup>a</sup>, Nicola Maffulli<sup>b,c,d</sup>

<sup>a</sup> Department of Orthopaedics, University Clinic Aachen, Rheinisch-Westfälische Technische Hochschule (RWTH) Aachen University Clinic, Aachen 52074, Germany

<sup>b</sup> Department of Medicine, Surgery and Dentistry, University of Salerno, Baronissi 84081, Italy

<sup>c</sup> School of Pharmacy and Bioengineering, School of Medicine, Keele University, Stoke on Trent ST4 7QB, UK

<sup>d</sup> Centre for Sports and Exercise Medicine, Barts and the London School of Medicine and Dentistry, Mile End Hospital, Queen Mary University of London, London E1 4DG, UK

Received 6 July 2020; revised 2 September 2020; accepted 19 October 2020

Available online 28 November 2020

2095-2546/© 2022 Published by Elsevier B.V. on behalf of Shanghai University of Sport. This is an open access article under the CC BY-NC-ND license. (<http://creativecommons.org/licenses/by-nc-nd/4.0/>)

## Abstract

**Purpose:** The present study aimed to systematically review and compare 2 femoral autograft fixation techniques, namely, interference screws and suture anchors, for isolated medial patellofemoral ligament reconstruction in patients with recurrent patellofemoral instability at mid- to long-term follow-up.

**Methods:** A literature search was performed in September 2020. All studies reporting the outcomes of primary isolated medial patellofemoral ligament reconstruction for recurrent patellofemoral instability were considered for inclusion. Only studies reporting the type of femoral autograft fixation under examination were considered. Studies reporting data from patients with elevated tibial tuberosity-tibial groove, patella alta, and/or Dejour's trochlear dysplasia types C and D, were not included. Only articles reporting data with a minimum follow-up period of 18 months were considered.

**Results:** Data from 19 studies (615 patients) were retrieved. The overall age was  $24.4 \pm 6.7$  years (mean  $\pm$  SD). The mean follow-up was  $46.5 \pm 20.9$  months. There were 76 patients in the anchor group and 539 in the screw group. Comparability was found with regard to age and follow-up duration between the 2 study groups. There was comparability between the Kujala, Lysholm, and Tegner scores at baseline. At the last follow-up, no worthy differences were found in terms of mean Kujala (+2.1%;  $p=0.04$ ), Lysholm (+1.7%;  $p=0.05$ ), and Tegner (+15.8%;  $p=0.05$ ) scores. Although complications occurred almost exclusively in the screw cohort, no statistically significant difference was found.

**Conclusion:** Femoral autograft fixation through interference screws or suture anchors report similar clinical scores and rate of apprehension test, persistent joint instability, re-dislocations, and revisions. These results must be interpreted within the limitations of the present study.

**Keywords:** Femoral fixation; Medial patellofemoral ligament reconstruction; Patellofemoral instability

## 1. Introduction

Recurrent instability of the patellofemoral joint is a multifactorial disorder with higher prevalence in active and young populations.<sup>1–3</sup> After the first dislocation, up to 96% of patients present damage to the medial patellofemoral ligament (MPFL).<sup>4</sup> MPFL reconstruction yields excellent outcomes and patient satisfaction, with a low rate of re-dislocations.<sup>5</sup> In fact,

the centers performing MPFL reconstruction have doubled in the last decade.<sup>6</sup> Several studies have focused on ways to optimize the results of MPFL reconstruction. The semitendinosus tendon autograft for MPFL reconstruction has been shown to perform better than the gracilis.<sup>7</sup> A recent meta-analysis supported the use of a double bundle graft.<sup>8</sup> Concerning patellar fixation, suture anchors produced a lower rate of anterior knee pain and complications compared with the bone-tunnel technique.<sup>9</sup> To the best of our knowledge, no study concerning femoral fixation has been conducted. Several techniques have been described for femoral graft fixation, but the most

Peer review under responsibility of Shanghai University of Sport.

\* Corresponding author.

E-mail address: [migliorini.md@gmail.com](mailto:migliorini.md@gmail.com) (F. Migliorini).

<https://doi.org/10.1016/j.jshs.2020.11.011>

Cite this article: Migliorini F, Baroncini A, Eschweiler J, Tingart M, Maffulli N. Interference screws vs. suture anchors for isolated medial patellofemoral ligament femoral fixation: A systematic review. *J Sport Health Sci* 2022;11:123–9.

common techniques are interference screws and suture anchors. Thus, we conducted a systematic review to compare interference screws and suture anchors graft fixation techniques for primary MPFL reconstruction in patients with recurrent patellofemoral instability. The present study focused on clinical scores and complications such as re-dislocation, revision, apprehension test, and persistent joint instability sensation. We hypothesized that both fixation techniques would achieve optimal fixation with a low rate of complications.

## 2. Methods

### 2.1. Search strategy

This systematic review of the literature was conducted according to the Preferred Reporting Items for Systematic Reviews and Meta-Analyses (PRISMA) guidelines.<sup>10</sup> The following PICOT algorithm guided the preliminary search:

- (P) Population: recurrent patellofemoral instability
- (I) Intervention: isolated MPFL reconstruction
- (C) Comparison: femoral fixation through interference screws vs. suture anchors
- (O) Outcomes: clinical scores, complications
- (T) Timing: mid-term follow-up

### 2.2. Literature search

The literature search was performed independently by 2 authors (FM and AB) in September 2020. The following databases were searched: PubMed, Embase, Google Scholar, and Scopus. The keywords used for the search were, in combination: “patellofemoral”, “patellar”, “instability”, “recurrent”, “pain”, “syndrome”, “dislocation”, “luxation”, “subluxation”, “therapy”, “surgery”, “management”, “MPFL”, “rupture”, “tear”, “reconstruction”, “tendon”, “graft”, “femoral”, “fixation”, “schöttle”, “interference”, “screw”, and “anchor”. Titles and related abstracts were screened by the same 2 authors. If the topic matched, the full text of the article was accessed. The bibliographies were screened for additional articles.

### 2.3. Eligibility criteria

All studies reporting the outcomes of isolated MPFL reconstruction for recurrent patellofemoral instability via an autologous graft were eligible. Only articles indicating the type of femoral fixation were considered for inclusion. Missing information on end points or lack of quantitative data under the outcomes of interest warranted exclusion from the study. The minimum length of follow-up required for inclusion was 18 months. To obtain the most reliable results, studies reporting data from patients with elevated tibial tuberosity-tibial groove and/or patella alta were not included, along with those presenting trochlear dysplasia types C and D according to the Dejour classification.<sup>11</sup> Articles reporting data on first-time patellar dislocation patients were excluded. Articles with a level of evidence of I–IV, according to the Oxford Centre of Evidence-Based Medicine,<sup>12</sup> were included. Given the authors’ language

capabilities, articles in English, German, Spanish, Italian, and French were included. Comments, letters, technique notes, protocols, editorials, guidelines, and registries were excluded. Computational, animal, biomechanical, and cadaveric studies were also excluded. Articles referring to patients who had received or planned to have knee arthroplasty were excluded. Articles referring to revision setting were excluded. Articles combining MPFL reconstruction with other proximal or distal alignment were excluded. Disagreements between the authors were debated and decided by a third author (NM).

### 2.4. Outcomes of interest

Two of the authors (FM and AB) performed the following data extraction: generalities (author, year, journal, and type of study), patient demographics (number of knees and mean patient age), follow-up duration, and surgical techniques (type, fixation, source, and bundle insertion of the graft). The following outcomes of interest were collected: Kujala Anterior Knee Pain Scale,<sup>13</sup> Lysholm Knee Scoring Scale,<sup>14</sup> Tegner Activity Scale,<sup>15</sup> and complications. Complications of interest included the positive apprehension test, persistent sensation of instability, revision, and re-dislocation. In accordance with Nikku et al.,<sup>16</sup> sensation of persistent instability was defined as recurrence and/or subjective sensation of subluxation or instability.

### 2.5. Methodological quality assessment

For the methodological quality assessment, the Coleman Methodology Score (CMS) was used.<sup>17</sup> The CMS is widely used to evaluate the methodological quality of systematic reviews and meta-analyses and is highly reliable.<sup>18–20</sup> This score allows for an analysis of the included papers based on several points of interest, including study size, follow-up duration, surgical approach, type of study, description of diagnosis, surgical technique, and rehabilitation. Additional outcome criteria assessment, the procedures for assessing outcomes and the subject selection process were also evaluated. The CMS rates articles with values between 0 (*poor*) and 100 (*excellent*). Articles with values of greater than 60 are considered satisfactory.

### 2.6. Statistical analysis

For statistical analysis, SPSS software (Version 25.0; IBM Corp., Armonk, NY, USA) was used. The mean difference (MD) was used for continuous variables. For binary variables, the odds ratio effect measure was adopted. For binary comparisons, the confidence interval was set at 95%. The unpaired *t* test was performed for continuous variables, while the chi-square test for binary data. Values of  $p < 0.05$  were considered statistically significant.

## 3. Results

### 3.1. Search results

The literature search resulted in 1994 articles being identified. Of these, 509 duplicates were excluded. An additional

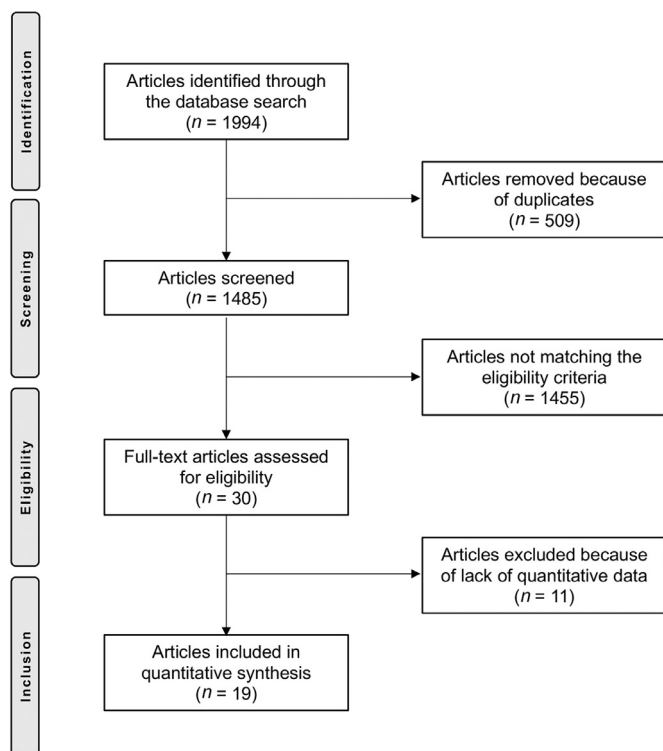


Fig. 1. Flow-chart of the literature search.

1455 articles were excluded because of one of the following reasons: language limitation ( $n=36$ ), acute onset ( $n=15$ ), revision setting ( $n=21$ ), presence of pathoanatomical risk factors ( $n=471$ ), short follow-up term ( $n=114$ ), using an allograft or xenograft or synthetic graft ( $n=39$ ), type of study ( $n=401$ ), patients with planned or previous knee arthroplasty ( $n=13$ ), combined surgeries ( $n=278$ ), uncertain results ( $n=11$ ), and other reasons ( $n=56$ ). Ultimately, an additional 11 articles were excluded because they lacked quantitative data under the outcomes of interest. This left 19 articles for inclusion, 5 on the use of suture anchors and 14 on the use of interference screws (Fig. 1).

### 3.2. Methodological quality assessment

The CMS identified some limitations and points of strength in the present study. The study size and follow-up duration of the included articles were acceptable. Surgical approach, diagnosis, and rehabilitation were well-described in most articles. Outcome measures and timing of assessment were often defined, providing moderate reliability. General health measures were rarely reported. The procedures for assessing outcomes and subject selection were often biased and not satisfactorily described. The CMS for the articles was 75%, attesting to this study a good quality of the methodologies for the included articles. The CMS is reported in Table 1.

### 3.3. Patient demographics

Data were retrieved for 615 patients. The age was  $24.4 \pm 6.7$  years (mean  $\pm$  SD). The mean follow-up was  $46.5 \pm 20.9$

months. There were 76 patients in the anchor group and 539 in the screw group. Comparability was found with regard to age and follow-up duration between the 2 study groups. The autografts used for reconstruction were semitendinosus ( $n=11$ ), gracilis ( $n=6$ ), quadriceps ( $n=2$ ), hamstring ( $n=2$ ), and patellar ( $n=1$ ). A double-bundle patellar fixation was reported on in 12 cohorts, and 6 cohorts reported on a single bundle fixation. Patellar fixation was achieved via suture anchors ( $n=10$ ), bone tunnel ( $n=5$ ), soft tissue ( $n=2$ ), Endobutton ( $n=1$ ), and transosseous suture ( $n=1$ ). Study generalities and patient demographics baseline are shown in Table 2.

### 3.4. Outcomes of interest

There was comparability between the 2 groups for the scores at baseline. At last follow-up, the mean Kujala score was greater in the screw group ( $+2.1\%$ ;  $p=0.04$ ), while no difference was found with regard to the Lysholm ( $+1.7\%$ ;  $p=0.05$ ) and Tegner ( $+15.8\%$ ;  $p=0.05$ ) scores. These results are shown in detail in Table 3.

Although complications occurred almost exclusively in the screw cohort, no statistically significant difference between the 2 groups was found. The complications related to each technique are shown in detail in Table 4.

## 4. Discussion

The present systematic review evaluated femoral fixation techniques for autograft for isolated MPFL reconstruction in patients with recurrent patellofemoral instability at mid- to long-term follow-up. The main findings in our study indicated that femoral fixation through interference screws produced clinical scores similar to those produced by suture anchors. No differences were found for rates of positive apprehension tests, persistent joint instability, re-dislocation, or revision.

The MPFL is the most important dynamic restraint to patellar lateralization during the first  $30^\circ$  of flexion.<sup>21,22</sup> Several studies have investigated efforts to improve reconstruction techniques, but to the best of our knowledge the effects of femoral fixation (interference screw vs. suture anchors) have not

Table 1  
Coleman Methodology Scores for the included articles (mean  $\pm$  SD).

End point	Score
<b>Part A: only 1 score to be given for each of the 7 sections</b>	
1. Study size: number of patients	$7.2 \pm 3.0$
2. Mean follow-up	$6.2 \pm 2.0$
3. Surgical approach	$13.1 \pm 2.5$
4. Type of study	$7.2 \pm 3.5$
5. Description of diagnosis	$1.7 \pm 2.4$
6. Description of surgical technique	$9.7 \pm 1.2$
7. Description of postoperative rehabilitation	$4.7 \pm 1.2$
<b>Part B: scores may be given for each option in each of the 3 sections if applicable</b>	
1. Outcome criteria	$7.8 \pm 1.2$
2. Procedure of assessing outcomes	$8.1 \pm 3.4$
3. Description of subject selection process	$9.3 \pm 2.9$
<b>Total</b>	$75.0 \pm 3.0$

Table 2  
Study generalities and patient demographics baseline.

Author (year)	Study design	Follow-up (month)	Knees (n)	Mean age (year)	Patellar fixation	Graft type	Bundle
<b>Suture Anchor cohort</b>							
Calanna et al. (2016) <sup>56</sup>	Retrospective	22.0	19	25.5	Suture anchor	Semitendinosus	—
Calapodopulos et al. (2016) <sup>39</sup>	Prospective	30.0	22	23.1	—	Quadriceps	Single
Kim et al. (2015) <sup>40</sup>	Retrospective	19.3	9	24.6	Soft tissue	Gracilis	—
Vavalle et al. (2016) <sup>41</sup>	Retrospective	38.0	16	22.0	—	Quadriceps	Single
Witonski et al. (2013) <sup>57</sup>	Prospective	43.0	10	27.2	—	Patellar	—
<b>Screw cohort</b>							
Astur et al. (2015) <sup>58</sup>	Randomized	60.0	30	31.1	Endobutton	Gracilis	Single
			28	28.3	Suture anchor	Gracilis	Double
Ballal et al. (2018) <sup>42</sup>	Prospective	12.0	20	24.4	Suture anchor	Semitendinosus	—
Feller et al. (2014) <sup>59</sup>	Retrospective	42.0	26	24.4	Bone tunnel	Hamstring	Double
Kang et al. (2013) <sup>60</sup>	Randomized	24.0	82	28.8	Soft tissue	Semitendinosus	Double
Ji et al. (2020) <sup>61</sup>	Retrospective	86.0	30	23.4	Suture anchor	Semitendinosus	Double
			30	23.3	Bone tunnel	Semitendinosus	Double
Lin et al. (2015) <sup>43</sup>	Retrospective	35.0	18	—	Suture anchor	Semitendinosus	Double
Panni et al. (2011) <sup>62</sup>	Retrospective	33.0	48	28.0	Bone tunnel	Semitendinosus	Double
Pinheiro et al. (2018) <sup>63</sup>	Retrospective	31.2	16	27.1	Suture anchor	Semitendinosus	Single
Raghuveer et al. (2012) <sup>64</sup>	Prospective	42.0	15	29.2	Bone tunnel	Semitendinosus	Single
Ronga et al. (2009) <sup>65</sup>	Prospective	37.0	37	28.0	Bone tunnel	Hamstring	Double
Wang et al. (2010) <sup>44</sup>	Retrospective	42.0	28	29.0	Suture anchor	Semitendinosus	Single
Wang et al. (2016) <sup>45</sup>	Retrospective	38.2	26	26.3	Suture anchor	Gracilis	Double
Ye et al. (2020) <sup>66</sup>	Prospective	43.5	31	28.9	Suture anchor	Gracilis	Double
		44.7	34	18.2	Transosseous suture	Gracilis	Double
Zhang et al. (2019) <sup>67</sup>	Prospective	96.0	60	21.0	Suture anchor	Semitendinosus	Double

yet been investigated. Our study offers new insights regarding the issue of femoral fixation, evidencing remarkable similarity between interference screws and suture anchors. We acknowledge that our study has several limitations, which were mainly due to the lack of studies in the literature.

In the present study, complications (even though not statistically significant) occurred almost exclusively in the interference screw cohort. Fixation through interference screws increased local pressure around the tendon–cancellous bone interface, which should provide quicker healing.<sup>23</sup> Bone mineral density, material properties, core diameter, pitch or thread height, geometry, placement, length, insertion torque, and gap size influenced the fixation.<sup>24–26</sup> Several mechanisms of failure for interference screws have been described: graft pull-out,<sup>26</sup> slippage and laceration by the screw threads,<sup>25</sup> and/or fatigue fracture during screw insertion.<sup>27</sup> The use of suture anchors has spread rapidly in the past few years. Anchors may have become less expensive and now have a lower risk of overtightening. Furthermore, their use does not affect the

growth plates, which offers an attractive alternative in skeletally immature patients. These features make suture anchors favorable. However, anchors do not provide better surgical outcomes than interference screws. In the studies included in our review, different types of interference screws and suture anchors were used, thus leading to biased results. On the other hand, the literature presents a large variability in instrumentation; thus, it was not feasible to directly compare 2 specific implants in our systematic review.

Improper femoral fixation leads to a high risk of failure.<sup>28</sup> In a cadaveric study, the femoral insertion of the MPFL was reported to have been approximately 1 cm wide, with an oblique decussation originating from the superficial medial collateral ligament.<sup>29</sup> The femoral origin of the MPFL is located between the adductor tubercle and the medial epicondyle, but it is closer to the adductor tubercle, just 2 mm anterior and 4 mm distal to this prominence.<sup>30</sup> The optimal landmarks for graft insertion have been described by Schöttle et al.<sup>31</sup> The first anatomical reference is represented by the tangent to the

Table 3  
Analyses of scores (mean ± SD).

End point	Anchor (n = 57)	Screw (n = 539)	MD	p
Kujala baseline	55.88 ± 11.74	52.62 ± 4.12	3.3	0.4
Kujala last FU	86.23 ± 7.71	88.37 ± 3.71	2.1	0.04
Lysholm baseline	51.13 ± 11.47	50.68 ± 6.20	0.5	0.1
Lysholm last FU	87.67 ± 5.59	89.35 ± 2.57	1.7	0.05
Tegner baseline	3.98 ± 1.88	2.98 ± 0.18	1.01	0.3
Tegner last FU	5.43 ± 0.38	7.01 ± 1.15	1.58	0.05

Abbreviations: FU = follow-up; MD = mean difference.

Table 4  
Analyses of complications.

End point	Events/Observations		OR	95%CI	p
	Anchor	Screw			
Apprehension test	2/55	13/259	0.70	0.15–3.20	0.6
Re-dislocations	0/73	9/479	0.34	0.02–5.85	0.5
Revision	0/38	9/511	0.69	0.04–12.03	0.8
Instability sensation	1/52	3/419	2.72	0.28–26.63	0.4

Abbreviations: 95%CI = 95% confidence interval; OR = odds ratio.

posterior femoral cortex. Two lines perpendicular to the first line are drawn: one at the posterior aspect of the Blumensaat's line<sup>32</sup> and one at the transition of the posterior femoral condyle curves. The Schöttle point is 2 mm anterior to the posterior cortical line between these 2 perpendicular lines. To find this point, it is essential to obtain a perfect lateral of the distal femur. Indeed, minimal position variations also lead to nonanatomic femoral graft fixation. A fixation that is too proximal increases graft tension during flexion, thus enhancing the contact pressure between the medial patellar and trochlear facet joints, whereas a fixation that is too distal reduces graft tension, causing lateralization of that patella and maltracking.

Skeletally immature patients require special consideration. The literature presents conflicting evidence about the relationship between the femoral insertion of the MPFL and the distal femoral physis. MPFL reconstruction is considered to be the optimal treatment for skeletally immature patients,<sup>33,34</sup> however, given the adjacent physis, the treatment requires additional considerations because it is controversial whether the Schöttle point should be placed proximally or distally to the physis. Following the criteria described by Schöttle et al.,<sup>31</sup> Shea et al.<sup>35</sup> found that the optimal placement was approximately 2–5 mm proximal to the physis. However, other evidence supports its location distally to the physis.<sup>36</sup> These data have been also confirmed by further magnetic resonance<sup>37,38</sup> and cadaveric studies.<sup>29,30</sup>

Our investigation included 7 studies<sup>39–45</sup> that involved trochlear dysplasia types A and B according to the Dejour classification.<sup>11</sup> MPFL reconstruction alone cannot compensate for severe trochlear dysplasia because bony surgery aiming to restore the physiological morphology would be indicated in these patients.<sup>46,47</sup> The exclusion of patients with severe trochlear dysplasia may represent a limitation to our study. However, several studies investigated the use of isolated MPFL reconstruction in patients with mild dysplastic abnormalities and reported excellent results.<sup>48–51</sup> For this reason (and because of the lack of studies on patients who had no pathoanatomical risk factors), we included them in our review. The underlying morphology of bony and soft tissues is responsible for instability, and most of the patients in the studies we included presented 2 or more pathoanatomical risk factors that predisposed them to dislocation.<sup>52–54</sup> However, in the presence of mild to moderate pathoanatomical risk factors, isolated MPFL reconstruction with a thicker graft may compensate for the tendency to lateralization, providing good patellar tracking and avoiding more invasive procedures.

In addition to the above limitation, our study has a few others. First, half of the included studies were retrospective in nature, and many lacked randomization. This leads to a high risk of selection bias and uncertain results. None of the included studies used any blinding methods, thus increasing the risk of detection bias. Given the paucity of studies in the literature reporting data on anchor fixation, we included only 5 such studies in our analysis. However, we believe that even with an increase in the number of anchor fixation procedures, the rate of complications experienced in the use of the 2 techniques would remain comparable. The lack of the evaluation

of predisposing risk factors among the participants is another important limitation. An analysis of surgical outcomes of MPFL reconstruction based on pathoanatomical bony morphology would achieve more reliable results and should be addressed in future studies. Moreover, our study did not compare or evaluate the length of stay in the hospital, the duration of the surgery, or the cost effectiveness of the procedure. Similarly, there were end points that may have been relevant but were not analyzed, such as the infection rate.<sup>55</sup> There are several other techniques for achieving MPFL graft femoral fixation, including bone plugs, Endobuttons staples, and soft tissues fixation on the tendon of the adductor magnus. Furthermore, we did not evaluate the position of the femoral attachment, which affects patellar stability and functional results of MPFL reconstruction. Another potential limitation that may have influenced the outcomes was the differing patellar fixation techniques, autografts, and bundles used in MPFL reconstruction. Given the lack of data on these issues, we were not able to address them in our study. Other important limitations involve the heterogeneous type of graft used for reconstruction (quadriceps, patellar, hamstring, semitendinosus, or gracilis), the type of graft insertion (double or single bundle), and the type of patellar fixation used (tunneling techniques, Endobutton, or soft tissue procedures). Some of the included studies investigated the use of a lateral retinacular release in the event of high lateral patellar pressure. Despite the absence of any clearly stated guidelines, this technique is often performed in combination with MPFL reconstruction. Future studies should investigate its effect on patellofemoral biomechanics, as well as its surgical indication. Some studies were included despite the fact that participants had had previous knee surgeries. This may have negatively affected the surgical outcomes and led to heterogeneity. However, given the lack of data on these outcomes, further subgroup analyses were not possible. Given these limitations, the results from our study should be interpreted with caution, and the limitations should be addressed in future investigations.

Important strengths of our work include the strict eligibility criteria we used and the comprehensive nature of our literature search. The use of isolated MPFL reconstruction in patients presenting elevated tibial tuberosity-tibial groove, patella alta, and severe dysplasia is controversial, and the debate about its value continues. Therefore, studies including patients with pathoanatomical risk factors that predispose them to instability were not included in our analysis.

## 5. Conclusion

Femoral autograft fixation using interference screws or suture anchors reported similar clinical scores and rate of positive apprehension test, persistent joint instability, re-dislocations, and revisions. The results of our review must be interpreted with its limitations in mind.

## Authors' contributions

FM performed the literature search, data extraction, statistical analyses, and writing; AB performed the literature search

and data extraction; JE made revisions; MT supervised; NM made the final revisions and final approval. All authors have read and approved the final version of the manuscript, and agree with the order of presentation of the authors.

### Competing interests

The authors declare that they have no conflicts of interest.

### References

- Migliorini F, Driessen A, Quack V, Gatz M, Tingart M, Eschweiler J. Surgical versus conservative treatment for first patellofemoral dislocations: A meta-analysis of clinical trials. *Eur J Orthop Surg Traumatol* 2020; **30**:771–80.
- Migliorini F, Rath B, Tingart M, Meisen N, Eschweiler J. Surgical management for recurrent patellar dislocations in skeletally immature patients. *Eur J Orthop Surg Traumatol* 2019; **29**:1815–22.
- Migliorini F, Rath B, Tingart M, Niewiera M, Eschweiler J. Distal alignment procedures for patellofemoral instability: Comprehensive review of the literature. *Eur J Orthop Surg Traumatol* 2019; **29**:1579–88.
- Nomura E, Horiuchi Y, Inoue M. Correlation of MR imaging findings and open exploration of medial patellofemoral ligament injuries in acute patellar dislocations. *Knee* 2002; **9**:139–43.
- Reagan J, Kullar R, Burks R. MPFL reconstruction: Technique and results. *Orthop Clin North Am* 2015; **46**:159–69.
- Stupay KL, Swart E, Shubin Stein BE. Widespread implementation of medial patellofemoral ligament reconstruction for recurrent patellar instability maintains functional outcomes at midterm to long-term follow-up while decreasing complication rates: A systematic review. *Arthroscopy* 2015; **31**:1372–80.
- Migliorini F, Trivellas A, Driessen A, Quack V, Tingart M, Eschweiler J. Graft choice for isolated MPFL reconstruction: Gracilis versus semitendinosus. *Eur J Orthop Surg Traumatol* 2020; **30**:763–70.
- Migliorini F, Trivellas A, Colarossi G, Eschweiler J, Tingart M, Rath B. Single- versus double-bundle patellar graft insertion for isolated MPFL reconstruction in patients with patellofemoral instability: A systematic review of the literature. *Arch Orthop Trauma Surg* 2020; **140**:769–76.
- Migliorini F, Driessen A, Quack V, Schenker H, Tingart M, Eschweiler J. Patellar fixation graft via suture anchors versus tunnel techniques during isolated MPFL reconstruction for recurrent patellofemoral instability: A systematic review of the literature. *Arch Orthop Trauma Surg* 2020; **140**:1201–10.
- Moher D, Liberati A, Tetzlaff J, Altman DG, Group P. Preferred reporting items for systematic reviews and meta-analyses: The PRISMA statement. *BMJ* 2009; **339**:b2535. doi:10.1136/bmj.b2535.
- Lippacher S, Dejour D, Elsharkawi M, et al. Observer agreement on the Dejour trochlear dysplasia classification: A comparison of true lateral radiographs and axial magnetic resonance images. *Am J Sports Med* 2012; **40**:837–43.
- Howick JCI, Glasziou P, Greenhalgh T, et al. *The 2011 Oxford levels of evidence*. Available at: <https://www.cebm.ox.ac.uk/resources/levels-of-evidence/ocbm-levels-of-evidence> [accessed 01.11.2020].
- Kujala UM, Jaakkola LH, Koskinen SK, Taimela S, Hurme M, Neli-markka O. Scoring of patellofemoral disorders. *Arthroscopy* 1993; **9**:159–63.
- Lysholm J, Gillquist J. Evaluation of knee ligament surgery results with special emphasis on use of a scoring scale. *Am J Sports Med* 1982; **10**:150–4.
- Briggs KK, Lysholm J, Tegner Y, Rodkey WG, Kocher MS, Steadman JR. The reliability, validity, and responsiveness of the Lysholm score and Tegner activity scale for anterior cruciate ligament injuries of the knee: 25 years later. *Am J Sports Med* 2009; **37**:890–7.
- Nikku R, Nietosvaara Y, Aalto K, Kallio PE. Operative treatment of primary patellar dislocation does not improve medium-term outcome: A 7-year follow-up report and risk analysis of 127 randomized patients. *Acta Orthop* 2005; **76**:699–704.
- Coleman BD, Khan KM, Maffulli N, Cook JL, Wark JD. Studies of surgical outcome after patellar tendinopathy: Clinical significance of methodological deficiencies and guidelines for future studies. *Scand J Med Sci Sports* 2000; **10**:2–11.
- Shang X, Chen J, Chen S. A meta-analysis comparing tenotomy and tenodesis for treating rotator cuff tears combined with long head of the biceps tendon lesions. *PLoS One* 2017; **12**:e0185788. doi:10.1371/journal.pone.0185788.
- Eberbach H, Hohloch L, Feucht MJ, Konstantinidis L, Sudkamp NP, Zwillingmann J. Operative versus conservative treatment of apophyseal avulsion fractures of the pelvis in the adolescents: A systematic review with meta-analysis of clinical outcome and return to sports. *BMC Musculoskelet Disord* 2017; **18**:162. doi:10.1186/s12891-017-1527-z.
- Hohloch L, Eberbach H, Wagner FC, et al. Age- and severity-adjusted treatment of proximal humerus fractures in children and adolescents—A systematic review and meta-analysis. *PLoS One* 2017; **12**:e0183157. doi:10.1371/journal.pone.0183157.
- Bicos J, Fulkerson JP, Amis A. Current concepts review: The medial patellofemoral ligament. *Am J Sports Med* 2007; **35**:484–92.
- Farr J, Schepesis AA. Reconstruction of the medial patellofemoral ligament for recurrent patellar instability. *J Knee Surg* 2006; **19**:307–16.
- Weiler A, Hoffmann RF, Bail HJ, Rehm O, Sudkamp NP. Tendon healing in a bone tunnel. Part II: Histologic analysis after biodegradable interference fit fixation in a model of anterior cruciate ligament reconstruction in sheep. *Arthroscopy* 2002; **18**:124–35.
- Milano G, Mulas PD, Ziranu F, Piras S, Manunta A, Fabbriani C. Comparison between different femoral fixation devices for ACL reconstruction with doubled hamstring tendon graft: A biomechanical analysis. *Arthroscopy* 2006; **22**:660–8.
- Kousa P, Jarvinen TLN, Vihavainen M, Kannus P, Jarvinen M. The fixation strength of six hamstring tendon graft fixation devices in anterior cruciate ligament reconstruction. Part I: Femoral site. *Am J Sports Med* 2003; **31**:174–81.
- Ahmad CS, Gardner TR, Groh M, Arnouk J, Levine WN. Mechanical properties of soft tissue femoral fixation devices for anterior cruciate ligament reconstruction. *Am J Sports Med* 2004; **32**:635–40.
- Golish SR, Caldwell 3rd PE, Miller MD, et al. Interference screw versus suture anchor fixation for subpectoral tenodesis of the proximal biceps tendon: A cadaveric study. *Arthroscopy* 2008; **24**:1103–8.
- Camp CL, Krych AJ, Dahm DL, Levy BA, Stuart MJ. Medial patellofemoral ligament repair for recurrent patellar dislocation. *Am J Sports Med* 2010; **38**:2248–54.
- Baldwin JL. The anatomy of the medial patellofemoral ligament. *Am J Sports Med* 2009; **37**:2355–61.
- LaPrade RF, Engebretsen AH, Ly TV, Johansen S, Wentorf FA, Engebretsen L. The anatomy of the medial part of the knee. *J Bone Joint Surg Am* 2007; **89**:2000–10.
- Schöttle PB, Schmeling A, Rosenstiel N, Weiler A. Radiographic landmarks for femoral tunnel placement in medial patellofemoral ligament reconstruction. *Am J Sports Med* 2007; **35**:801–4.
- Iriuchishima T, Goto B, Ryu K, Fu FH. The Blumensaat's line morphology influences to the femoral tunnel position in anatomical ACL reconstruction. *Knee Surg Sports Traumatol Arthrosc* 2019; **27**:3638–43.
- Brown GD, Ahmad CS. Combined medial patellofemoral ligament and medial patellotibial ligament reconstruction in skeletally immature patients. *J Knee Surg* 2008; **21**:328–32.
- Deie M, Ochi M, Sumen Y, Yasumoto M, Kobayashi K, Kimura H. Reconstruction of the medial patellofemoral ligament for the treatment of habitual or recurrent dislocation of the patella in children. *J Bone Joint Surg Br* 2003; **85**:887–90.
- Shea KG, Grimm NL, Belzer J, Burks RT, Pfeiffer R. The relation of the femoral physis and the medial patellofemoral ligament. *Arthroscopy* 2010; **26**:1083–7.
- Nelitz M, Dornacher D, Dreyhaupt J, Reichel H, Lippacher S. The relation of the distal femoral physis and the medial patellofemoral ligament. *Knee Surg Sports Traumatol Arthrosc* 2011; **19**:2067–71.

37. Ladd PE, Laor T, Emery KH, Salisbury SR, Parikh SN. Medial collateral ligament of the knee on magnetic resonance imaging: Does the site of the femoral origin change at different patient ages in children and young adults? *J Pediatr Orthop* 2010;**30**:224–30.
38. Kepler CK, Bogner EA, Hammoud S, Malcolmson G, Potter HG, Green DW. Zone of injury of the medial patellofemoral ligament after acute patellar dislocation in children and adolescents. *Am J Sports Med* 2011;**39**:1444–9.
39. Calapodopulos CJ, Nogueira MC, Eustaquio JMJ, Calapodopulos Jr CJ, Rodrigues OA. Reconstruction of the medial patellofemoral ligament using autologous graft from quadriceps tendon to treat recurrent patellar dislocation. *Rev Bras Ortop* 2016;**51**:187–93.
40. Kim TS, Kim HJ, Ra IH, Kyung HS. Medial patellofemoral ligament reconstruction for recurrent patellar instability using a gracilis autograft without bone tunnel. *Clin Orthop Surg* 2015;**7**:457–64.
41. Vavalle G, Capozzi M. Isolated reconstruction of the medial patellofemoral ligament with autologous quadriceps tendon. *J Orthop Traumatol* 2016;**17**:155–62.
42. Ballal M, Vamsinath P, Nawaz Basha MS. Functional outcome of medial patellofemoral ligament injury (MPFL) reconstruction in recurrent patellar dislocation. *Int J Orthop Sci* 2018;**4**:204–7.
43. Lin KY, Lu YC, Renn JH. The double-pulley technique for anatomical double-bundled medial patellofemoral ligament reconstruction. *Injury* 2015;**46**:1619–24.
44. Wang F, Kang HJ, Chen BC, Chen W, Su YL, Zhang YZ. Combination of medial patellofemoral ligament reconstruction with vastus medialis advancement for chronic patellar dislocation. *Chin Med J (Engl)* 2010;**123**:3024–9.
45. Wang HD, Dong JT, Gao SJ. Medial patellofemoral ligament reconstruction using a bone groove and a suture anchor at patellar: A safe and firm fixation technique and 3-year follow-up study. *J Orthop Surg Res* 2016;**11**:138. doi:10.1186/s13018-016-0473-z.
46. Nolan 3rd JE, Schottel PC, Endres NK. Trochleoplasty: Indications and technique. *Curr Rev Musculoskelet Med* 2018;**11**:231–40.
47. Vogel LA, Pace JL. Trochleoplasty, medial patellofemoral ligament reconstruction, and open lateral lengthening for patellar instability in the setting of high-grade trochlear dysplasia. *Arthrosc Tech* 2019;**8**:e961–7.
48. Wang CH, Ma LF, Zhou JW, et al. Double-bundle anatomical versus single-bundle isometric medial patellofemoral ligament reconstruction for patellar dislocation. *Int Orthop* 2013;**37**:617–24.
49. Li J, Li Y, Wei J, Wang J, Gao S, Shen Y. A simple technique for reconstruction of medial patellofemoral ligament with bone-fascia tunnel fixation at the medial margin of the patella: A 6-year-minimum follow-up study. *J Orthop Surg Res* 2014;**9**:66. doi:10.1186/s13018-014-0066-7.
50. Hinterwimmer S, Imhoff AB, Minzlaff P, et al. Anatomical two-bundle medial patellofemoral ligament reconstruction with hardware-free patellar graft fixation: Technical note and preliminary results. *Knee Surg Sports Traumatol Arthrosc* 2013;**21**:2147–54.
51. Fink C, Veselko M, Herbort M, Hoser C. MPFL reconstruction using a quadriceps tendon graft: Part 2: Operative technique and short term clinical results. *Knee* 2014;**21**:1175–9.
52. Hiemstra LA, Kerslake S, Lafave M. Assessment of demographic and pathoanatomic risk factors in recurrent patellofemoral instability. *Knee Surg Sports Traumatol Arthrosc* 2017;**25**:3849–55.
53. Wagner D, Pfalzer F, Hingelbaum S, Huth J, Mauch F, Bauer G. The influence of risk factors on clinical outcomes following anatomical medial patellofemoral ligament (MPFL) reconstruction using the gracilis tendon. *Knee Surg Sports Traumatol Arthrosc* 2013;**21**:318–24.
54. Sillanpää P, Mattila VM, Iivonen T, Visuri T, Pihlajamäki H. Incidence and risk factors of acute traumatic primary patellar dislocation. *Med Sci Sports Exerc* 2008;**40**:606–11.
55. Aicale R, Oliva F, Maffulli N. Defensive Antibacterial Coating (DAC®) for prevention of infection in ACL reconstruction: A feasibility study. *Muscles Ligaments Tendons J* 2020;**10**:151–3.
56. Calanna F, Pulici L, Carminati G, Quaglia A, Volpi P. Medial patellofemoral ligament (MPFL) reconstruction using suture anchors fixation: Preliminary results. *Muscles Ligaments Tendons J* 2016;**6**:64–70.
57. Witonski D, Keska R, Synder M, Sibinski M. An isolated medial patellofemoral ligament reconstruction with patellar tendon autograft. *Biomed Res Int* 2013;**2013**:637678. doi:10.1155/2013/637678.
58. Astur DC, Gouveia GB, Borges JH, et al. Medial patellofemoral ligament reconstruction: A longitudinal study comparison of 2 techniques with 2 and 5-years follow-up. *Open Orthop J* 2015;**9**:198–203.
59. Feller JA, Richmond AK, Wasiaik J. Medial patellofemoral ligament reconstruction as an isolated or combined procedure for recurrent patellar instability. *Knee Surg Sports Traumatol Arthrosc* 2014;**22**:2470–6.
60. Kang H, Cao J, Yu D, Zheng Z, Wang F. Comparison of 2 different techniques for anatomic reconstruction of the medial patellofemoral ligament: A prospective randomized study. *Am J Sports Med* 2013;**41**:1013–21.
61. Ji G, Wang H, Su X, Wang J, Wang F. The modified semi-tunnel bone bridge technique achieved statistically better knee function than the suture anchor technique. *Knee Surg Sports Traumatol Arthrosc* 2020;**28**:995–1001.
62. Panni AS, Alam M, Cerciello S, Vasso M, Maffulli N. Medial patellofemoral ligament reconstruction with a divergent patellar transverse 2-tunnel technique. *Am J Sports Med* 2011;**39**:2647–55.
63. Pinheiro Jr LFB, Cenni MHF, Nicolai OP, Gomes LPH, Leal RS, Coelho DGP. Outcomes of medial patellofemoral ligament reconstruction in patients with patella alta. *Rev Bras Ortop* 2018;**53**:570–4.
64. Raghuvveer RK, Mishra CB. Reconstruction of medial patellofemoral ligament for chronic patellar instability. *Indian J Orthop* 2012;**46**:447–54.
65. Ronga M, Oliva F, Longo UG, Testa V, Capasso G, Maffulli N. Isolated medial patellofemoral ligament reconstruction for recurrent patellar dislocation. *Am J Sports Med* 2009;**37**:1735–42.
66. Ye M, Zhang H, Liang Q. Clinical outcomes after medial patellofemoral ligament reconstruction using transosseous sutures versus suture anchors: A prospective nonrandomized controlled trial. *Orthop J Sports Med* 2020;**8**: 2325967120917112. doi:10.1177/2325967120917112.
67. Zhang L, Li Z. Long-term clinical results of double bundle reconstruction of the medial patellofemoral ligament for patellar instability. *J Knee Surg* 2019;**32**:153–9.