



Contents lists available at ScienceDirect

International Journal of Surgery Case Reports

journal homepage: www.casereports.com

Spontaneous rupture of the urinary bladder (SRUB); A case report and review of literature



Haitham Sawalmeh, Labib Al-Ozaibi*, Ahmed Hussein, Faisal Al-Badri

Rashid Hospital, Dubai Health Authority, Dubai, United Arab Emirates

ARTICLE INFO

Article history:

Received 28 July 2015

Received in revised form

14 September 2015

Accepted 24 September 2015

Available online 3 October 2015

Keywords:

Urinary bladder rupture

Spontaneous urinary bladder rupture

SRUB

ABSTRACT

INTRODUCTION: Spontaneous urinary bladder rupture is a rare urological emergency. It is usually secondary to an underlying pathology and it is an uncommon complication of urosepsis. We report a case of spontaneous urinary bladder rupture as a complication of urosepsis in a 67 year old male patient, who was admitted as a case of left diabetic foot and urinary tract infection.

CASE PRESENTATION: A 67 year old male patient with a long standing indwelling urinary catheter and chronic cystitis developed acute peritonitis. Intraoperative finding was ruptured urinary bladder.

DISCUSSION: A few cases of spontaneous urinary bladder rupture due to infection were found in literature. The majority of the patients present with diffuse abdominal pain, and tenderness due to chemical peritonitis. In the majority of cases the bladder perforation was diagnosed intra-operative.

CONCLUSION: A diagnosis of spontaneous perforation of the bladder should be considered in patients presenting with an acute abdomen. The general surgeon is more likely than the urologist to encounter such patients in the first instance. There should be a high index of suspicion in patients with an acute abdomen and have associated urinary bladder condition.

© 2015 The Authors. Published by Elsevier Ltd. on behalf of IJS Publishing Group Ltd. This is an open access article under the CC BY-NC-ND license (<http://creativecommons.org/licenses/by-nc-nd/4.0/>).

1. Introduction

Spontaneous urinary bladder rupture is an uncommon complication of urosepsis, only few cases reported in the literature [1,7]. In 1929, Sisk and Wear defined the condition as: "if the bladder ruptures without external stimulation, it is spontaneous and deserves to be reported as such" [2]. The diagnosis is considered to be a challenge, and is usually discovered during laparotomy [3].

2. Case report

A 67 year old male patient, known case of diabetes, hypertension and dyslipidemia presented to the emergency with a complaint of left foot pain, swelling, and ulcer in the plantar aspect with pus discharge, associated with fever for last 2 days and generalized weakness. On examination the patient looks ill and pale, febrile with temperature 38.7, tachycardic with pulse 105, left foot swelling, hotness, redness and tenderness. There was a left plantar ulcer, irregular in shape, with undermined edges, pus discharge, and necrotic base. There were neither abdominal distension nor tenderness. A foley catheter inserted which revealed pus with the urine. Laboratory tests done and revealed a White blood cells (WBC) 15.5, hemoglobin (HB) 7.9, C-reactive protein (CRP) 41, potassium

(K) 5.5, sodium (Na) 130, random blood glucose 327 mg/dl, and urine showed numerous WBC and red blood cells (RBC).

Patient admitted, left plantar ulcer debridement done, with daily dressing and intravenous antibiotic. Three days after admission, patient started complaining of sudden onset severe abdominal pain mainly in suprapubic region, constant, associated with fever and vomiting. The abdomen was distended, tense and tender. Abdominal CT scan showed moderate pneumoperitoneum with moderate abdomino-pelvic free fluid, likely due to hollow viscus perforation, diffuse haziness in the mesentery, moderate dilatation of the small bowel loops and Foley's catheter balloon seen in situ with partially distended urinary bladder; **Figs. 1 and 2.**

Patient diagnosed as a perforated viscus and booked for surgery. Exploratory laparotomy done and showed moderate intra-abdominal turbid fluid collection with pockets of pus in the pelvis and right paracolic gutter, dilated congested bowel loop with no signs of perforation, edema of the mesentery and urinary bladder perforation 3 × 3 cm in the dome of the bladder with inflamed mucosa and pus coming from inside the urinary bladder; **Fig. 3.**

Lavage of the peritoneal cavity done, biopsies were taken from the edges of the perforation, the edges of the perforation refreshed and water tight repair in two layers using 2/0 polyglactin was done. A suprapubic and Foley's catheter inserted. The histopathology report confirmed a nonspecific inflammation of bladder wall with no evidence of malignancy. Post-operative recovery of the patient was uneventful. He was kept in the surgical intensive care unit for three days then transferred to the surgical ward, started oral

* Corresponding author.

E-mail address: lsalozabi@gmail.com (L. Al-Ozaibi).

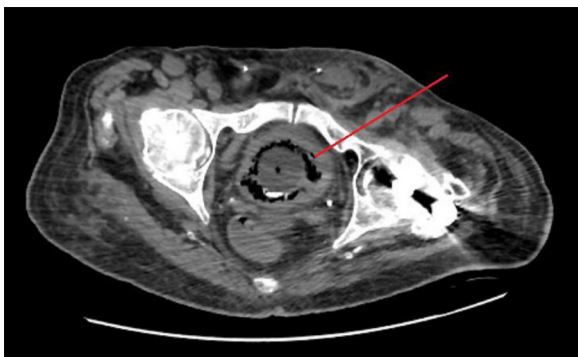


Fig. 1. Thickness in urinary bladder wall with air in it.

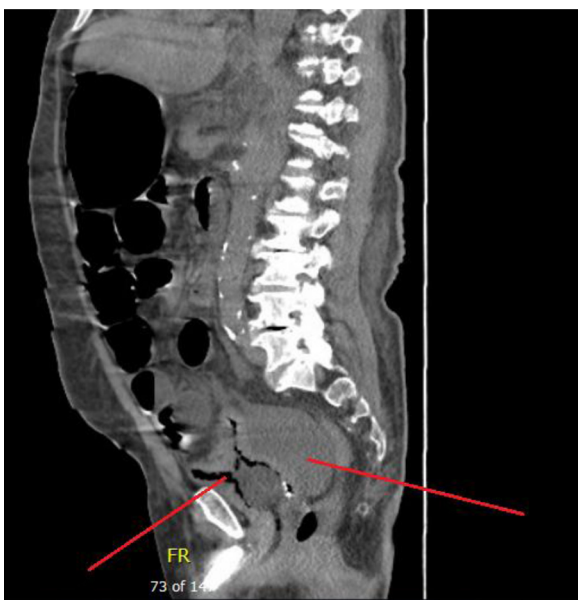


Fig. 2. Collapsed bladder with air in it and free fluid collection.

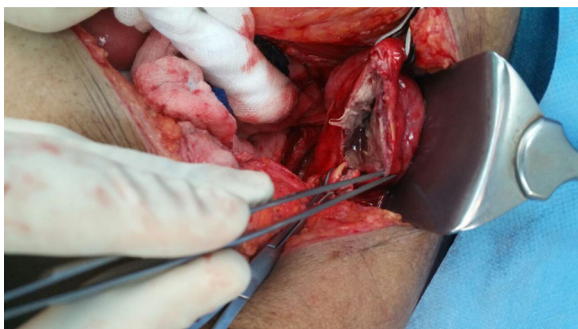


Fig. 3. Intraoperative finding of the ruptured bladder.

fluids of the third post-operative day and full diet commenced on the fifth day. Intravenous antibiotics continued for eight days and he was discharged from the hospital on the tenth postoperative day.

3. Discussion

A few cases of spontaneous urinary bladder rupture were found in literature. In 1939, Falk and Hochman reported three cases due to inflammatory etiology, most of which were of gonorrhoeal origin [4]. Acute inflammation may result from candida cystitis leading to

bladder perforation [5]. Diabetics with decreased bladder sensitivity leading to chronic urinary retention and recurrent urinary tract infections may also have increased incidence of bladder rupture [6].

Other causes of spontaneous bladder rupture other than infection were mentioned in the literature. Gomes et al. reported alcoholism as a cause of spontaneous bladder rupture due to altered sensitivity [6]. Radiotherapy has been reported as an etiology of spontaneous urinary bladder rupture, in 1966 one case was reported by Airman [8]. Also neurologic bladder can be a cause of spontaneous urinary bladder rupture, in 1940 Wilson reported a case due to neurogenic bladder [9]. Obstructed labor can also be a cause either during labor or delayed between the fourth to the tenth day postpartum [10].

Whatever the cause, nearly always there is an underlying pathology that weakens the bladder wall is present to precipitate a perforation. In our case, the underlying cause is the chronic infection which is one of the less common causes of perforation. Almost all the cases were diagnosed intraoperatively during a laparotomy for acute peritonitis which is also the same for our case. There should be a high index of suspicion in patients with an acute abdomen, biochemical evidence of renal dysfunction and have associated conditions such as enterocystoplasty, bladder malignancy, pelvic irradiation, inflammation, infection or long standing indwelling catheter.

4. Conclusion

Spontaneous urinary bladder rupture is a rare emergency which can cause acute abdomen and septic shock, which is difficult to differentiate between it and gastrointestinal tract perforation. It should be suspected in patients with acute abdomen and a history of recurrent urinary tract infection, difficult obstructed labor, pelvic organs malignancy, previous history of pelvic irradiation and patients with neurologic bladder and diabetes. CT scan can help in diagnosis. Diagnostic laparoscopy or explorative laparotomy should not be delayed. It is recommended to take a biopsy from the perforation edges to rule out malignancy.

Conflict of interest

No conflict of interest.

Funding

No source of funding or sponsor.

Consent

Written informed consent was obtained from the patient for publication of this case report and accompanying images. A copy of the written consent is available.

Author contribution

Dr. Labib Al-Ozaibi → Study design.
Dr. Haitham Sawalmeh → Writing.
Dr. Ahmed Hussein → Data collection.
Dr. Faisal Al-Badri → Analysis and review.

References

- [1] J.S. Budd, Spontaneous intraperitoneal rupture of the bladder in association with transitional cell carcinoma, *Postgrad. Med. J.* 64 (1988) 165–166.
- [2] I.R. Sisk, J.B. Wear, Spontaneous rupture of the urinary bladder, *J. Urol.* 21 (1929) 517–521.

- [3] M. Schein, S. Weinstein, A. Rosen, G.A.G. Decker, Spontaneous rupture of the urinary bladder delayed sequel of pelvic irradiation a case report, *S. Afr. Med. J.* 70 (1986) 841–842.
- [4] H.C. Falk, S. Hochman, Rupture of pelvic inflammatory masses into the urinary bladder, *Am. J. Obstet. Gynecol.* 38 (1939) 654.
- [5] M. Mardani, M. Shahzadi, N. Rakhshani, et al., Spontaneous perforation of urinary bladder secondary to candida cystitis: acute abdomen of urologic origin, *Surg. Infect. (Larchmt)* 9 (2008) 525–527.
- [6] C.A. Gomes, A.A. de Figueiredo, C. de Soares Jr., et al., Acute abdomen: spontaneous bladder rupture as an important differential diagnosis, *Rev. Col. Bras. Cir.* 36 (2009) 364–365.
- [7] T. Amano, S. Miwa, H. Takashima, et al., Four cases of spontaneous rupture of the urinary bladder, *Hinyokika Kyo* 48 (2002) 243–245.
- [8] B. Airman, A.G. Horsburgh, Spontaneous rupture of the bladder, *Br. J. Urol.* 38 (1966) 85–88.
- [9] L. Wilson, Spontaneous rupture of the urinary bladder in a tabetic patient, *Med. Bull. Vet. Admin.* 17 (1940) 93–95.
- [10] R. Torpin, Spontaneous rupture of the urinary bladder in labor case report literature and new classification, *Urol. Cutan. Rev.* 44 (1940) 553–557.

Open Access

This article is published Open Access at sciedirect.com. It is distributed under the [IJSCR Supplemental terms and conditions](#), which permits unrestricted non commercial use, distribution, and reproduction in any medium, provided the original authors and source are credited.