

Angiokeratoma Circumscriptum on the Breast: A Case with Unusual Features

Sir,

Angiokeratomas consist of one or more dilated vessels in the papillary dermis accompanied by an epidermal reaction in the form of acanthosis and/or hyperkeratosis.^[1] There are 5 major clinical subtypes of angiokeratoma out of which angiokeratoma circumscriptum (AC) is considered to be the rarest.^[2] Herein, we present an unusual case of acquired angiokeratoma circumscriptum presenting on the breast with few unusual features.

A 45-year-old female presented to our outpatient department with reddish raised lesions over the right breast for the past 15 years, associated with intermittent bleeding on scratching. There was no history of trauma or prolonged breastfeeding. On examination, the patient had multiple erythematous to bluish-colored papules and plaques, with associated underlying telangiectasias. The nipple-areola complex was normal, however, asymmetry in breast size was seen [Figures 1 and 2]. On palpation, the lesions were firm, nontender, and regional lymphadenopathy was absent. Mammography demonstrated prominent ducts in the upper quadrant of the right breast and was assigned a BIRADS category 2 suggesting benign findings. Ultrasound demonstrated soft tissue hypertrophy while the doppler did not reveal any abnormality. Histopathological evaluation revealed dilated and congested papillary

dermal capillaries with irregular acanthosis and variable hyperkeratosis of the epidermis and elongation of the rete ridges forming a collarette [Figures 3 and 4]. Based on the clinicopathological correlation, a diagnosis of angiokeratoma circumscriptum was made.

Angiokeratomas are vascular lesions characterized by ectasia of the papillary dermis vessels with a secondary epidermal reaction.^[1] The pathogenesis remains largely unclear, although several factors such as congenital causes, pregnancy, and tissue asphyxia have been implicated.^[2] Angiokeratoma circumscriptum is considered to be the rarest type and usually presents at birth, although childhood and adult-onset have also been described.^[1,2] They present as single or multiple, 2-10 mm, erythematous to bluish papules and nodules which coalesce to form verrucous, hyperkeratotic plaques.^[1,2] They are most commonly present over the lower limbs, arms, or trunk and are unilateral in most patients.^[2] The histopathological findings are characterized by dilated, thin-walled, congested capillaries in the papillary dermis with the overlying epidermis demonstrating acanthosis and hyperkeratosis. Elongated rete ridges may enclose these dilated vascular channels, forming an epidermal collarette at the margin of the lesions. The deep dermis and hypodermis remain uninvolved.^[3] The differential diagnosis of AC may be ruled out based on their characteristic histopathological differences and may include verrucous hemangioma showing hyperkeratosis, dilated capillaries in the deep dermis and subcutaneous fat, Cobb syndrome, and angioma serpiginosum which is rarely associated with hyperkeratosis lymphangioma circumscriptum which further demonstrates

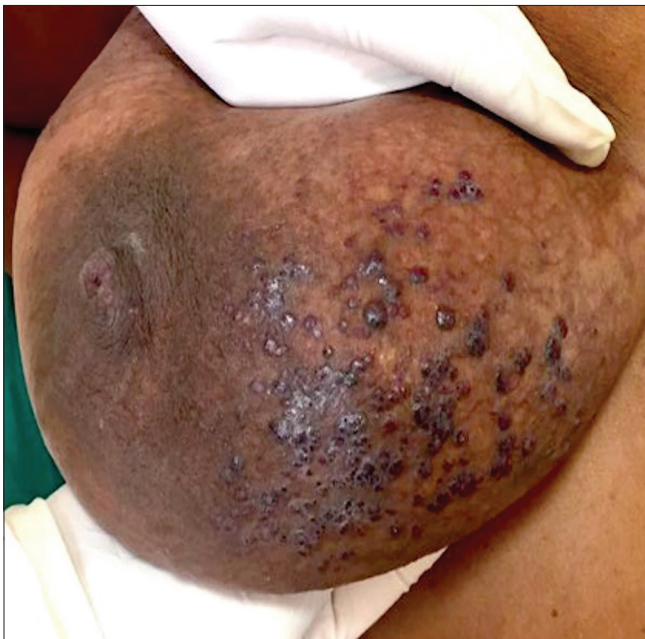


Figure 1: Multiple reddish-purple papules, 2–10 mm in size, with few of them coalescing to form verrucous plaques with underlying telangiectasias over the right breast

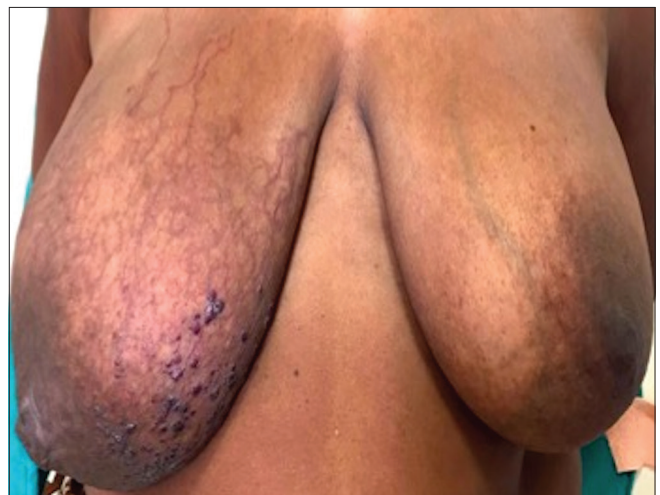

Figure 2: Asymmetry in breast size: affected breast is associated with soft tissue hypertrophy

vascular spaces without congested erythrocytes, verrucae, and melanoma wherein atypical melanocytes invading the dermis are characteristically seen^[4,5] For smaller lesions, local excision or electrocautery remain the preferred treatment modalities while the larger lesions usually respond well to a wide, deep excision, and grafting. Other treatment options include cryotherapy, diathermy, and laser ablation (argon, CO₂, KTP). Herein, we report a case of angiokeratoma circumscriptum on the breast. We report this case due to its unusual features including an uncommon location, associated soft tissue hypertrophy, underlying telangiectasias, and later onset. Moreover, AC on the breast has been rarely reported and to our knowledge, only four case reports [Table 1] exist in the literature.^[4,6-8] Associated telangiectasia's are an unusual finding and soft tissue hypertrophy without an underlying deeper vascular

component has also been rarely described.^[1,4,6,8] Late-onset of disease as in our case has also been uncommonly reported.^[4,6,7,9] Our patient was offered a wide excision and grafting; however, the patient was lost to follow-up.

Financial support and sponsorship

Nil.

Conflicts of interest

There are no conflicts of interest.

Anuva Bansal, Tanvi Gupta

Department of Dermatology, Maulana Azad Medical College, Bahadur Shah Zafar Marg, Delhi, India

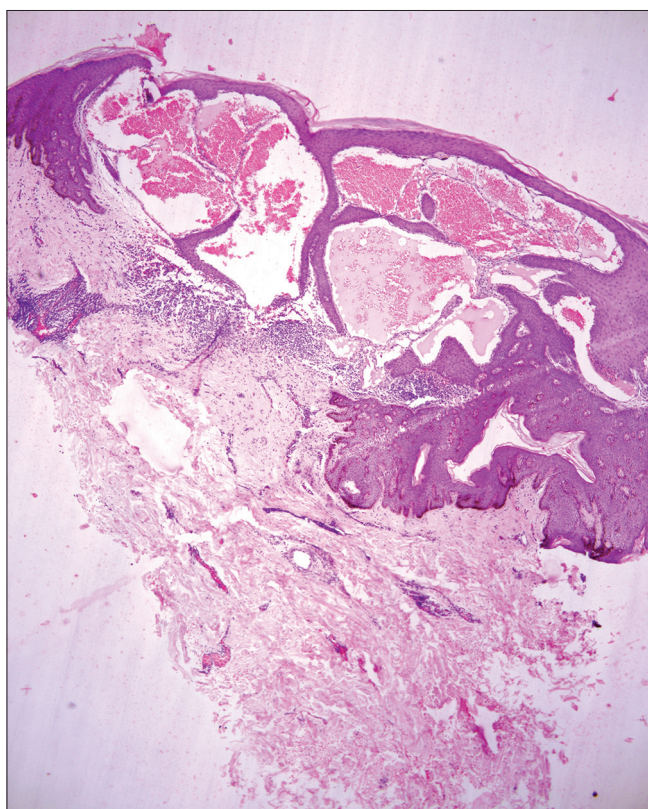


Figure 3: A skin biopsy was done and histopathology revealed- Dilatation of papillary dermal vessels forming large cavernous channels with irregular acanthosis of the epidermis and elongation of the rete ridges partially enclosing the vascular channels forming the epidermal collarette

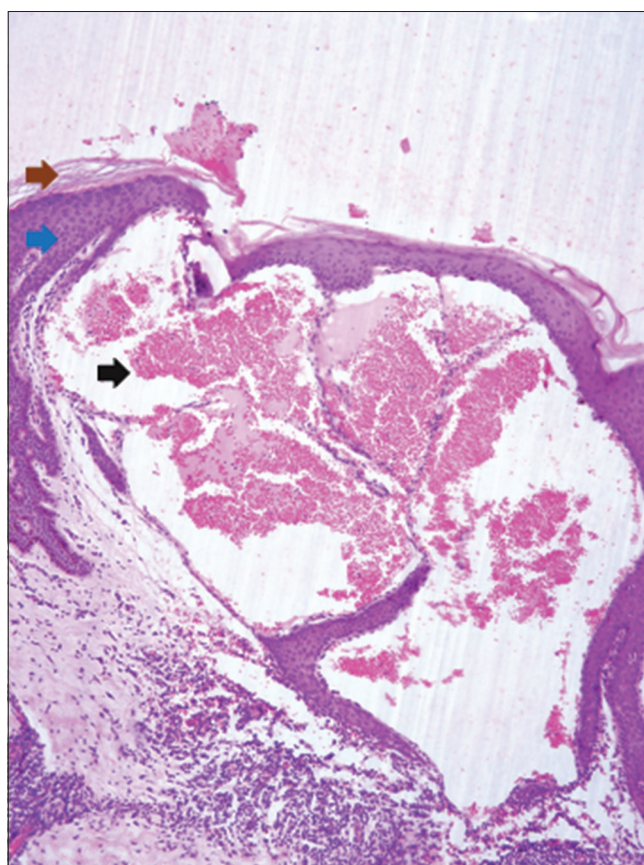


Figure 4: (H and E 400*) Dilatation of papillary dermal vessels forming large cavernous channels with congested erythrocytes inside the vascular spaces (Black arrow). Associated hyperkeratosis and irregular acanthosis of the epidermis (Maroon Arrow). Elongation of the rete ridges partially enclosing the vascular channels forming the epidermal collarette (Blue Arrow)

Table 1: Angiokeratoma circumscriptum on the breast: A review of the literature^[4,6-8]

Case Report	Study	Details
Talwar and Suresh (1992) ^[4]	Angiokeratoma circumscriptum: Some unusual features	Late-onset, unusual site, bilateral involvement and associated telangiectasia
Karadag and Simsek (2009) ^[6]	Multiple Angiokeratomas on the breast	Late-onset, unilateral, no telangiectasias
Cakmak and Gonul (2009) ^[7]	Unilateral Angiokeratomas on the breast	Late-onset, unilateral, no telangiectasias
Kwak and Park (2017) ^[8]	Angiokeratomas on the nipple associated with enlargement of the ipsilateral breast: A rare lesion in an adolescent boy	Early-onset, restricted to the nipple, enlargement of ipsilateral breast

Address for correspondence:

Dr. Anuva Bansal,
Department of Dermatology, Maulana Azad Medical
College, Bahadur Shah Zafar Marg, Delhi - 110 002, India.
E-mail: anuvabansal22@gmail.com


References

- Schiller PI, Ian PH. Angiokeratomas: An update. *Dermatology* 1996;193:275-82.
- Kwon NH, Kim SY, Kim GM. A case of post-injury angiokeratoma circumscriptum of the chest. *Ann Dermatol* 2010;22:66-8.
- Lever WF, Elder DE, editors. *Histopathology of the Skin*. 10th ed. Philadelphia: JB Lippincott; 2009. p. 1101.
- Talwar S, Suresh MS, Jha PK. Angiokeratoma circumscriptum: Some unusual features. *Indian J Dermatol Venereol Leprol* 1992;58:120-1.
- Mittal R, Aggarwal A, Srivastava G. Angiokeratoma circumscriptum: A case report and review of the literature. *Int J Dermatol* 2005;44:1031-4.
- Karadag AS, Şimşek GG. Multiple angiokeratomas on the breast. *Indian J Dermatol Venereol Leprol* 2009;75:437.
- Cakmak SK, Gönül M, Gül U, Gündüz H, Demiriz M, Ustüner E. Unilateral angiokeratoma of the breast. *Eur J Dermatol* 2009;19:75-6.
- Kwak HB, Park SK, Park SW, Rhee CH, Park J, Kim HU, *et al.*

Angiokeratomas on the nipple associated with enlargement of the ipsilateral breast: A rare lesion in an adolescent boy. *Eur J Dermatol* 2017;27:556-7.

- Jindal SR, Chavade P, Jerajani HR. Late onset palmar angiokeratoma circumscriptum: An unusual presentation. *Indian Dermatol Online J* 2014;5:320-2.

This is an open access journal, and articles are distributed under the terms of the Creative Commons Attribution-NonCommercial-ShareAlike 4.0 License, which allows others to remix, tweak, and build upon the work non-commercially, as long as appropriate credit is given and the new creations are licensed under the identical terms.

Access this article online	
Website: www.idoj.in	Quick Response Code 
DOI: 10.4103/idoj.IDOJ_472_19	

How to cite this article: Bansal A, Gupta T. Angiokeratoma circumscriptum on the breast: A case with unusual features. *Indian Dermatol Online J* 2020;4:655-7.

Received: 28-Sep-2019. **Revised:** 10-Nov-2019.

Accepted: 15-Dec-2019. **Published:** 13-Jul-2020.

© 2020 Indian Dermatology Online Journal | Published by Wolters Kluwer - Medknow