

A New Method for Measuring Glenoid Version on Standard Magnetic Resonance Imaging

Journal of Shoulder and Elbow Arthroplasty
Volume 4: 1–6
© The Author(s) 2020
Article reuse guidelines:
sagepub.com/journals-permissions
DOI: 10.1177/2471549220926826
journals.sagepub.com/home/sea



Nicholas J. Maister, BMBS^{1,2}, Andrew Hely, BMBS^{1,2},
Liam G. Twycross, BMBS^{1,2}, Stephen D. Gill, BPhysio, PhD^{1,2,3} ,
and Richard S. Page, BMedSci, MB, BS, FRACS (Orth), FAOrthA^{1,2,3} 

Abstract

Background: The most effective method and modality for measuring glenoid version for different shoulder conditions is uncertain. Computed tomography (CT) imaging exposes the patient to radiation, and standard magnetic resonance imaging (MRI) does not consistently image the entire scapula. This study investigates the reliability of a new method for assessing glenoid version using routine shoulder MRI.

Methods: MRI images of 20 patients undergoing arthroscopy for shoulder instability were independently assessed by 3 clinicians for osseous and chondrolabral glenoid version. To assess glenoid version, a line was drawn from medial corner of the glenoid body to midpoint of the glenoid face. A line perpendicular to this was the reference against which to measure glenoid version. Measurements were repeated after 3 months to assess intra- and interobserver reliability. Reliability was determined using intraclass correlation coefficients (ICCs).

Results: Interclass correlation coefficients showed at least good reliability for most estimates of intraobserver reliability ($ICC \geq .66$) and excellent reliability for most estimates of interobserver reliability ($ICC \geq .84$), with the exception of some inferior glenoid measurements where ICC was poor ($ICC \leq .41$).

Discussion: We propose that this new method of measuring glenoid on standard axial MRI can be used as a simple, practical, and reliable method in shoulder instability patients, which will reduce the requirement for CT in this group.

Keywords

Chondrolabral, glenoid version, magnetic resonance imaging, reliability, shoulder

Date received: 4 December 2019; accepted: 3 April 2020

Introduction

The glenoid fossa of the scapula does not always lie in a plane perpendicular to the axis of the scapular body.¹ This variation in angle is known as glenoid version.

Glenoid version has been implicated in various shoulder pathologies including instability, glenoid labral damage, rotator cuff injury, and joint degeneration.^{1–5} For example, Kim et al.⁵ showed a positive correlation between both osseous and labral glenoid retroversion and patients with posterior instability. Glenoid version is also an important factor in preoperative shoulder arthroplasty planning.^{6–9} Tétreault et al.¹⁰ and Tokgoz et al.¹¹ demonstrated a relationship between glenoid version and rotator cuff pathology; however, this relationship has not been found in all studies.^{12,13}

Taking valid and reliable measurements of glenoid version is important when studying the influence of

glenoid version on pathologies and when planning shoulder arthroplasty to enable accurate implantation of the glenoid prosthesis and augmentation.^{4,6,7,9} However, opinions differ regarding the most effective imaging modality and measurement technique for determining glenoid version. Different imaging and measurement techniques have produced different degrees of version.¹³

¹Barwon Centre for Orthopaedic Research and Education, St John of God Hospital, Geelong, Victoria, Australia

²Department of Orthopaedics, Barwon Health, University Hospital, Geelong, Victoria, Australia

³School of Medicine, Deakin University, Geelong, Victoria, Australia

Corresponding Author:

Nicholas J. Maister, Department of Orthopaedics, University Hospital, Bellerine Street, Geelong, VIC, Australia.
Email: nickmaister@outlook.com



Friedman et al.¹ used computed tomography (CT) images (single axial image per scan) to measure glenoid version relative to a reference line drawn from midway between the anterior and posterior margins of the glenoid fossa to the medial edge of the scapula at the mid glenoid level; glenoid version was the angle of the glenoid face against this reference line. Friedman et al.'s reference line was adopted by Kim et al.;⁵ however, they used magnetic resonance imaging (MRI) and the plane of the scapula body as the reference line against which to measure glenoid version. Randelli and Gambrioli¹⁴ used the general axis of the scapula body as the reference line against which to measure glenoid version using CT, whereas Tétreault et al. used an axis along the supraspinatus fossa at a superior glenoid level as a similar reference point using MRI.^{14,15}

Compared with CT, MRI is increasingly used to visualize shoulder pathology because of its superior ability to visualize soft tissues which is particularly important when assessing rotator cuff disorders and glenohumeral instability. Improved visualization of soft tissues also allows for chondrolabral glenoid versions to be determined, which is important given the glenoid labrum's contribution to glenohumeral stability. However, MRI sequences for glenohumeral pathology do not routinely include the entire scapula in the axial plane, which is necessary for determining glenoid version using the methods described by the above authors.^{1,5,14} Tétreault et al.'s¹⁰ method allows the assessment of glenoid version without visualization of the whole scapula; however, this method, which uses CT, does not allow for the comparison of glenoid version at different points along the glenoid, along which morphology can significantly vary, as provided by Kim et al.'s⁵ method.

The aim of this study was to describe a new method of glenoid version measurement using MRI and assess its test-retest reliability. The method is a modification of Kim et al.'s⁵ technique and is designed to allow osseous and chondrolabral glenoid version to be determined without needing the entire scapula to be imaged. The relationship between osseous and chondral glenoid version was also analyzed.

Materials and Methods

The study was approved by the institution's Human Research Ethics Committee (ref 13/65).

Participants

Preoperative MRIs of 20 patients undergoing arthroscopic surgery for symptomatic shoulder instability and labral tear at arthroscopy were included. The mean age was 26.9 years (standard deviation 5.7,

range 16–36 years). A total of 15 participants (75%) were males.

Imaging

MR arthrography and conventional MRI were performed on a 3 T system (Siemens Trio) using a dedicated Siemens 4-channel shoulder coil. From the routine shoulder protocol, the sequence used for the MR arthrogram analysis was the turbo-spin-echo (TSE) T1-weighted axial fat-saturated (FS) images (Repetition time/Echo time (TR/TE), 797/11; section thickness, 3 mm; intersection gap, 0.4 mm; field of view (FOV) 14 cm; matrix, 224 × 320). The sequence used for the noncontrast MRI was TSE axial proton density FS images (TR/TE, 3310/39; section thickness, 3 mm; intersection gap 0.4 mm, FOV 14 cm; matrix, 192 × 320).

Images were taken with each participant supine, with the arm beside the trunk, the shoulder in slight external rotation, the elbow fully extended and the forearm supinated.

Measuring Glenoid Version

Using the coronal image at mid glenoid as a reference, images were obtained at 25%, 50%, and 75% points along the long axis of the glenoid in the coronal view (Figure 1). These images were used to measure the osseous and chondrolabral glenoid versions. First, a reference line was drawn from the midpoint of the transverse glenoid diameter at the level of the articular surface as used by Kim et al.;⁵ however, in contrast to Kim et al., the second reference point for this line was the medial aspect of the glenoid body, which is the point at which

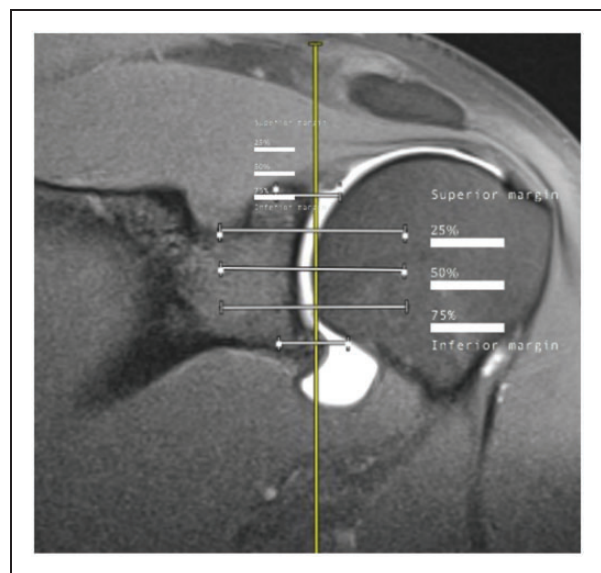


Figure 1. The three cuts shown in the sagittal plane at 25%, 50%, and 75% of glenoid height.

the glenoid body narrows to form the scapula body (Figure 2, line N).

The angle between a line perpendicular to this reference line and a line drawn through the most lateral prominence of the anterior and posterior aspects of the glenoid labrum defined the chondrolabral glenoid version (Figures 2 and 3, line L).

The angle between a line perpendicular to the reference line and a line drawn through the anterior and posterior aspects of the osseous glenoid rim defined the osseous glenoid version (Figures 2 and 3, line O).

Negative angles represented retroversion and positive angles represented anteversion. Three observers independently measured chondrolabral and osseous glenoid versions for all patients. Observers were junior medical officers who were trained in the measurement technique by the senior investigator, an orthopedic surgeon specializing in upper limb surgery.

To assess intraobserver reliability, the measurements were repeated by each observer 3 months later on 9 randomly selected participants. Observers could not access or review their prior measurements when repeating the measurements at 3 months.

All measurements were performed on the picture archiving and communications system monitor (BARCO E-3621) with use of a mouse pointer (cursor) and automated computer calculation of the angle and length.

Statistical Analysis

Descriptive statistics were calculated for the osseous and chondrolabral measurements of glenoid version.

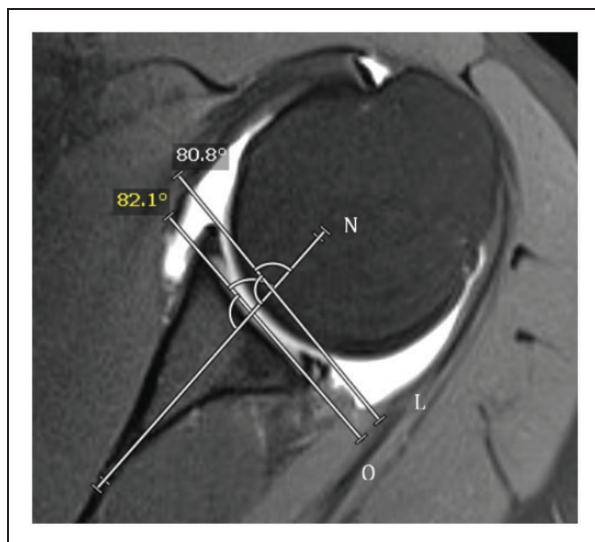


Figure 2. A line is drawn from the medial corner of the glenoid vault to the point half way along the glenoid face in the transverse plane (line N). A line perpendicular to line N is neutral version. Osseous (line O) and labral (line L) are then measured relative to neutral version.

An Anderson–Darling test was used to assess data normality. Interobserver and intraobserver reliability were assessed using intraclass correlation coefficients (ICCs).¹⁶ Interobserver reliability was determined by comparing the 3 observers' scores for each chondrolabral and osseous measurement. Intraobserver reliability was determined by comparing each observer's first measurement with their second measurement taken 3 months later for each chondrolabral and osseous measurement. ICCs were interpreted as <0.40 was poor reliability, 0.40–0.59 fair, 0.60–0.74 good, and >0.74 excellent reliability.¹⁷ We used ICCs because it measures concordance between measurements, whereas correlation coefficients such as Pearson's *r* measure linear relationship but not agreement. Statistical analysis was performed using Statistical Package for the Social Sciences (SPSS), IBM, version 17. Linear regression was conducted to establish the relationship between osseous (dependent variable) and labral version.

Results

Glenoid and chondrolabral versions were retroverted on average 6.0° to 10.2°, respectively (Table 1). Average measurements obtained between observers were similar, with no more than 1.9° difference between average measurements. Intraobserver reliability was good to excellent for the glenoid osseous measurements (ICC: .66–.88, $P < .05$; Table 2), and excellent for all chondrolabral measurement (ICC $\geq .78$; Table 3) except for one

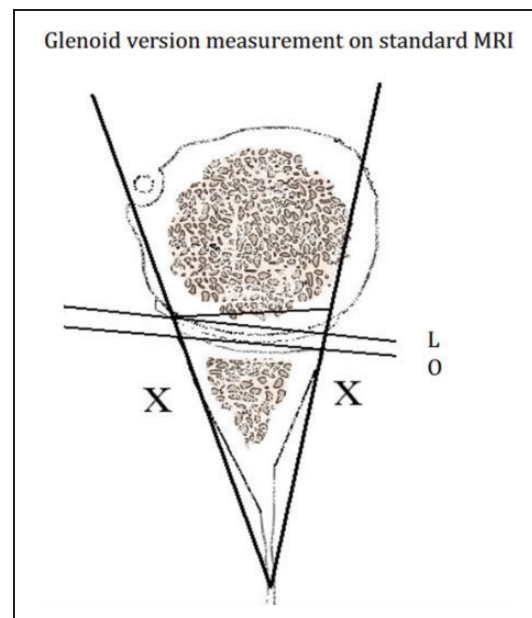


Figure 3. These measurements can then be simplified to be represented by an isosceles triangle where the osseous (line O) and labral (line L) version are independently measured relative to the base of the triangle.

Table 1. Glenoid Version at Initial Measurement for Each Observer.

	Osseous Version Mean (SD)			Chondrolabral Version Mean (SD)		
	Superior	Middle	Inferior	Superior	Middle	Inferior
Observer 1	-8.2 (5.4)	-9.5 (3.9)	-7.9 (4.5)	-8.6 (5.2)	-9.9 (3.2)	-9.3 (4.4)
Observer 2	-9.8 (5.2)	-9.7 (4.0)	-7.5 (5.8)	-9.7 (5.3)	-10.2 (3.7)	-9.5 (4.8)
Observer 3	-9.1 (5.3)	-9.5 (4.2)	-6.0 (5.0)	-9.3 (4.9)	-9.9 (3.8)	-9.1 (5.2)

Superior, middle, and inferior represent 25%, 50%, and 75% along the long axis of the glenoid in the coronal view. A negative value indicates retroversion.

Table 2. Intraobserver Reliability: ICCs for Glenoid Osseous Measurements.

	Superior Glenoid (95% CI)	Middle Glenoid (95% CI)	Inferior Glenoid (95% CI)
Observer 1	0.84 (0.77–0.88)	0.88 (0.82–0.91)	0.71 (0.57–0.84)
Observer 2	0.83 (0.74–0.88)	0.81 (0.71–0.88)	0.66 (0.48–0.81)
Observer 3	0.71 (0.61–0.79)	0.67 (0.58–0.77)	0.82 (0.75–0.86)

N = 9 for all ICCs; $P < .05$ all ICCs; "superior," "middle," and "inferior" represent 25%, 50%, and 75% along the long axis of the glenoid in the coronal view.

Table 3. Intraobserver Reliability: ICCs for Chondrolabral Measurements.

	Superior Glenoid (95% CI)	Middle Glenoid (95% CI)	Inferior Glenoid (95% CI)
Observer 1	0.78 (0.69–0.84)	0.97 (0.93–0.98)	0.41* (0.19–0.79)
Observer 2	0.90 (0.86–0.91)	0.87 (0.79–0.89)	0.91 (0.87–0.92)
Observer 3	0.85 (0.79–0.87)	0.89 (0.82–0.92)	0.91 (0.87–0.93)

N = 9 for all ICCs; $P < .05$ except *; "Superior," "Middle," and "Inferior" represent 25%, 50%, and 75% along the long axis of the glenoid in the coronal view.

which was poor (ICC: .41). Interobserver reliability for both osseous and chondrolabral measurements were typically excellent (ICC \geq .84; Table 4); however, 1 ICC was poor (ICC: .30).

Regression analysis of the relationship between osseous and labral version, at all axial levels measured, indicated that the measurements were highly correlated. Each 1° change in labral version resulted in a 0.99° change in osseous version.

Discussion

This study assessed the reliability of a new method of assessing glenoid version using MRI. Results indicated good to excellent interobserver and intraobserver reliability for most measurements. Inferior glenoid measurements were the most difficult to reliably measure as the bony and chondral landmarks became less clear as the glenoid began to narrow in the transverse plane.

Given the poor reliability of osseous inferior glenoid measurements, greatest weight should be given to the interpretation of superior and middle cuts. We propose this method as an alternative to studying glenoid version at multiple levels in instances where the whole spine of the scapula cannot be visualized on MRI due to limitation of the field of view.

In 2012, Poon and Ting⁸ proposed another method for measuring glenoid version on CT imaging. Similar to our method, they did not use the plane of the scapula as a reference point but rather a point at the junction at which the medial angle of the glenoid endosteal vault meets the body of the scapula in the axial plane. Interobserver and intraobserver reliability was excellent (ICC \geq .95), and average disagreement between observers was 1.6° and within observers 1.5°. Poon and Ting opted not to use the traditional landmark of the glenoid face midpoint as a reference citing concern about the accuracy of this point in an osteoarthritic shoulder. This was not a limitation in our young patient group, none of whom had degenerative changes.

Matsumura et al.¹⁸ used a similar measurement technique to this study to assess osseous glenoid version for preoperative planning in shoulder arthroplasty; however, they used only one measurement in the axial plane in the middle of the glenoid cavity and used CT imaging rather than MRI. Their findings were similar to our results, demonstrating excellent intraobserver and interobserver reliability (ICC $>$.90). Matsumura et al. also compared the glenoid vault method with the traditional scapula body method and found good levels of agreement.

The glenoid labrum plays an important role in glenohumeral stability, and it is necessary to consider its contribution to glenoid version.⁵ MRI allowed us to compare osseous and chondrolabral versions and we identified high correlation between the two measurements suggesting they could be used interchangeably in our population.

The results of this study should be interpreted in light of its limitations. First, it was not always possible to identify a representative axial cut exactly at the glenoid points of 25%, 50%, and 75% in the sagittal plane.

Table 4. Interobserver Reliability: ICC for Osseous and Chondrolabral Measurements.

	Superior Glenoid		Middle Glenoid		Inferior Glenoid	
	Osseous	Chondrolabral	Osseous	Chondrolabral	Osseous	Chondrolabral
ICC (95% CI)	0.84 (0.76–0.88)	0.88 (0.82–0.90)	0.86 (0.81–0.89)	0.86 (0.80–0.89)	0.30* (0.09–0.68)	0.90 (0.86–0.91)

N = 20 for all ICCs; $P < .05$ except *; “Superior,” “middle,” and “inferior” represent 25%, 50%, and 75% along the long axis of the glenoid in the coronal view.

However, cuts should typically occurred 1.5 mm either side of the quartile marks. The sample size was relatively small; despite this, 95% confidence intervals for most ICCs were less than 0.1, suggesting that the point estimate is an accurate measure. Participants were mostly young males with shoulder instability, and further study is required before the technique can be confidently used with degenerative shoulders and preoperative arthroplasty planning. Three-dimensional CT reconstructions have been proposed to help reduce error caused by scapular positions such as rotation or inclination.^{18,19} This reconstruction is not routinely available with MRI; this remains a limitation when assessing glenoid version measurement on current MRI. However, CT imaging is not a universal standard of care in all cases of instability or rotator cuff injury and our new method may have benefit where MRI is the sole imaging modality. Finally, the study investigates the reliability of a new method for assessing glenoid version. Further work is required to investigate its validity by comparing it to established methods.

This new method is quick and simple to perform and enables measurement of both osseous and chondral glenoid versions in the research setting but also on routine MRI scans carried out in clinical practice. With a growing number of studies looking at the relationship between glenoid version and nonosteoarthritic shoulder pathology such as instability,^{2,5} rotator cuff pathology,^{10,11} and labral damage,³ and others correlating other MRI bony measurements with shoulder pathology,^{20–23} this method aims to facilitate further research in this area and will hopefully have positive implications for the prognosis, surgical indication, and management of this group of patients with shoulder pathology.

Conclusion

With MRI being an increasingly common imaging modality in the assessment of shoulder instability and rotator cuff disease, this method of measuring glenoid version demonstrates good to excellent intra- and interobserver reliability, particularly in the middle and upper glenoid. Future research is required to determine the reliability of the technique in degenerative shoulder conditions.

Author Contributions

R. S. P. conceived and designed the study. A. H. and L. G. T. completed study measurements. N. M. completed the first draft of the manuscript. All authors contributed to data analysis and interpretation, manuscript drafting, and approved the final version of the manuscript.



Declaration of Conflicting Interests

The author(s) declared no potential conflicts of interest with respect to the research, authorship, and/or publication of this article.

Funding

The author(s) received no financial support for the research, authorship, and/or publication of this article.

ORCID iDs

Stephen D. Gill  <https://orcid.org/0000-0001-8722-0572>
Richard S. Page  <https://orcid.org/0000-0002-2225-7144>

References

- Friedman RJ, Hawthorne KB, Genez BM. The use of computerized tomography in the measurement of glenoid version. *J Bone Joint Surg Am.* 1992;74:1032–1037.
- Brewer BJ, Wubben RC, Carrera GF. Excessive retroversion of the glenoid cavity. A cause of non-traumatic posterior instability of the shoulder. *J Bone Joint Surg Am.* 1986;68:724–731.
- Harper KW, Helms CA, Haystead CM, et al. Glenoid dysplasia: incidence and association with posterior labral tears as evaluated on MRI. *AJR Am J Roentgenol.* 2005;184:984–988. doi:10.2214/ajr.184.3.01840984
- Inui H, Sugamoto K, Miyamoto T, et al. Evaluation of three-dimensional glenoid structure using MRI. *J Anat.* 2001;199:323–328. doi:10.1046/j.1469-7580.2001.19930323.x
- Kim SH, Noh KC, Park JS, et al. Loss of chondrolabral containment of the glenohumeral joint in atraumatic posteroinferior multidirectional instability. *J Bone Joint Surg Am.* 2005;87:92–98. doi:10.2106/JBJS.C.01448
- Favre P, Moor B, Snedeker JG, et al. Influence of component positioning on impingement in conventional total shoulder arthroplasty. *Clin Biomech (Bristol, Avon).* 2008;23:175–183. doi:10.1016/j.clinbiomech.2007.09.009
- Hoenecke HR, Jr., Hermida JC, Flores-Hernandez C, et al. Accuracy of CT-based measurements of glenoid version

- for total shoulder arthroplasty. *J Shoulder Elbow Surg.* 2010;19:166–171. doi:10.1016/j.jse.2009.08.009
8. Poon PC, Ting FS. A 2-dimensional glenoid vault method for measuring glenoid version on computed tomography. *J Shoulder Elbow Surg.* 2012;21:329–335. doi:10.1016/j.jse.2011.04.006
 9. Bryce CD, Davison AC, Lewis GS, et al. Two-dimensional glenoid version measurements vary with coronal and sagittal scapular rotation. *J Bone Joint Surg Am.* 2010;92:692–699. doi:10.2106/JBJS.I.00177
 10. Tétrault P, Krueger A, Zurakowski D, et al. Glenoid version and rotator cuff tears. *J Orthop Res.* 2004;22:202–207. doi:10.1016/s0736-0266(03)00116-5
 11. Tokgoz N, Kanatli U, Voyvoda NK, et al. The relationship of glenoid and humeral version with supraspinatus tendon tears. *Skeletal Radiol.* 2007;36:509–514. doi:10.1007/s00256-007-0290-x
 12. Kandemir U, Allaire RB, Jolly JT, et al. The relationship between the orientation of the glenoid and tears of the rotator cuff. *J Bone Joint Surg Br.* 2006;88:1105–1109. doi:10.1302/0301-620X.88B8.17732
 13. Dogan M, Cay N, Tosun O, et al. Glenoid axis is not related with rotator cuff tears—a magnetic resonance imaging comparative study. *Int Orthop.* 2012;36:595–598. doi:10.1007/s00264-011-1356-x
 14. Randelli M, Gambrioli PL. Glenohumeral osteometry by computed tomography in normal and unstable shoulders. *Clin Orthop Relat Res.* 1986:151–156.
 15. Tackett JJ, Ablove RH. Magnetic resonance imaging study of glenohumeral relationships between genders. *J Shoulder Elbow Surg.* 2011;20:1335–1339. doi:10.1016/j.jse.2011.03.018
 16. Peolsson A, Hedlund R, Oberg B. Intra- and inter-tester reliability and reference values for hand strength. *J Rehabil Med.* 2001;33:36–41.
 17. Fleiss JL. *Statistical methods for rates and proportions.* 2nd ed. New York, NY: Wiley; 1981.
 18. Matsumura N, Ogawa K, Ikegami H, et al. Computed tomography measurement of glenoid vault version as an alternative measuring method for glenoid version. *J Orthop Surg Res.* 2014;9:17. doi:10.1186/1749-799X-9-17
 19. Weishaupt D, Zanetti M, Nyffeler RW, et al. Posterior glenoid rim deficiency in recurrent (atraumatic) posterior shoulder instability. *Skeletal Radiol.* 2000;29:204–210. doi:10.1007/s002560050594
 20. Watson AC, Jamieson RP, Mattin AC, et al. Magnetic resonance imaging based coracoid morphology and its associations with subscapularis tears: a new index. *Shoulder Elbow.* 2019;11:52–58. doi:10.1177/1758573217744170
 21. Page R, Bhatia DN. Arthroscopic repair of a chondrolabral lesion associated with anterior glenohumeral dislocation. *Knee Surg Sports Traumatol Arthrosc.* 2010;18:1748–1751. doi:10.1007/s00167-010-1095-3
 22. Page RS. Managing chondral lesions of the glenohumeral joint. *Int J Shoulder Surg.* 2008;2:77–78. doi:10.4103/0973-6042.44143
 23. Bonacci J, Manson B, Bowe SJ, et al. Operative shoulder instability injury management in Australian Football League players: a case series. *J Sci Med Sport.* 2017;21:760–764. doi:10.1016/j.jsams.2017.11.011