



Published in final edited form as:

Cancer Treat Commun. 2015 ; 3: 28–32. doi:10.1016/j.ctrc.2014.11.002.

Stabilization of bone marrow infiltration by metastatic breast cancer with continuous doxorubicin

Gaurav Pahouja^a, Robert Wesolowski^b, Raquel Reinbolt^b, Gary Tozbikian^c, Michael Berger^b, Neha Mangini^b, and Maryam B. Lustberg^{b,*}

^aNortheast Ohio Medical University, College of Medicine, Rootstown, OH 44272, USA

^bBreast Program, Stefanie Spielman Comprehensive Breast Center, The Ohio State University Comprehensive Cancer Center, USA

^cDepartment of Pathology, Wexner Medical Center at The Ohio State University, USA

Abstract

Complete bone marrow infiltration with profound pancytopenia is very uncommon in breast cancer. Bone marrow metastasis can frequently occur following development of metastatic breast cancer. However, bone marrow failure as the herald of this disease is not typically seen. Very limited data exists as to the safest and most efficacious manner to treat patients with profound pancytopenia due to metastatic solid tumor involvement. In this case, the patient's thrombocytopenia was particularly worrisome, requiring daily platelet transfusions. There was also concern that cytotoxic chemotherapy would exacerbate the patient's thrombocytopenia and increase bleeding risk. The patient's dramatic response to chemotherapy with full platelet recovery is also highly unusual. For our patient, continuous doxorubicin successfully "unpacked" the bone marrow despite a low baseline platelet level, and without increasing the need for more frequent platelet transfusion or risk of catastrophic bleeding. Given the rarity of this presentation, it is currently unknown if the majority of similar patients experience near full recovery of hematopoietic function after initiation of appropriate systemic treatment for metastatic disease.

Keywords

Pancytopenia; Metastatic breast cancer; Doxorubicin; Continuous

1. Introduction

Breast cancer is the most common malignancy in women and number one cause of death in women between the ages of 45 and 55 in the United States [1]. Although metastatic disease, considered incurable, is rarely seen at the time of initial diagnosis, approximately 20% of

© 2014 The Authors. Published by Elsevier Ltd.

This is an open access article under the CC BY-NC-ND license (<http://creativecommons.org/licenses/by-nc-nd/3.0/>).

*Correspondence to: Assistant Professor of Internal Medicine, B405 Starling Loving Hall, 20 West 10th Avenue, Columbus, Ohio, USA. Maryam.lustberg@osumc.edu (M.B. Lustberg).

Conflict of interest statement

None declared.

women with operable breast cancer eventually relapse, with about 70% of the relapses as distant metastases [2–5]. Approximately 80% of women with metastatic breast cancer have skeletal metastases, which are often the result of bone marrow infiltration of malignant cells with subsequent progression and invasion of the skeletal cortex [6–9]. The most common complications of skeletal metastases are pathologic fractures, spinal cord compression as the result of vertebral compression fracture or extension of the tumor beyond the epidural space, and hypercalcemia [7–9]. Furthermore, skeletal metastases sometimes require surgery or radiation therapy to treat pain or an impending fracture. Bone marrow metastases result in the invasion and destruction of the bone tissue matrix by tumor cells [6]. Although bone marrow infiltration by metastases is commonly present among breast cancer patients, total bone marrow infiltration resulting in profound pancytopenia is extremely rare [6,10].

2. Case report

A 62 year-old female presented with increased fatigue that was interfering with her activities of daily living. Her previous medical history was remarkable only for hypertension. Her family history included lung cancer in her mother. On physical exam, she was ill-appearing and fatigued. Sclera were anicteric. Lips were dry and oral mucosa was notable for blood tinged secretions. Lungs were clear to auscultation bilaterally. Cardiovascular exam was normal, with no murmurs, rubs or gallops appreciated. Abdomen was soft and nontender without organomegaly. Her breast exam was notable for a fixed, 1 cm left axillary lymph node. Neither breast had a palpable mass or skin changes. Peripheral blood laboratory tests indicated severe pancytopenia. Her white blood cell (WBC) count was 3.2 K/ μ L, hemoglobin (Hgb) was 6.8 g/dL, and platelet count was 3 K/ μ L. Multiple imaging studies, including computed tomography (CT) of the chest, abdomen and pelvis, as well as a bone scintigraphy were completed as part of the initial diagnostic work up. Chest CT revealed left axillary adenopathy and a medial, nodular left breast lesion. The bone scintigraphy scan showed diffuse skeletal metastatic disease involving multiple vertebrae and the pelvis. A mammogram had also been performed and showed an irregular spiculated nodule in the upper inner left breast. The patient subsequently underwent a core needle biopsy of an enlarged left axillary lymph node. The biopsy revealed a metastatic lobular carcinoma strongly positive for both estrogen and progesterone receptors (ER and PR) and negative for HER2 and E-cadherin by immunohistochemical staining.

To further evaluate the patient's profound pancytopenia, which required frequent transfusion of packed red blood cells (pRBC) and platelets, the patient underwent a bone marrow biopsy. The pathology showed that the metastatic carcinoma had entirely replaced the bone marrow (Figure 1). The tumor cells were positive by immunohistochemical staining for cytokeratin AE1/AE3, ER and PR, but were negative for HER2, consistent with metastatic breast cancer.

After much discussion of the risks and benefits of therapy in view of profound pancytopenia, the patient initiated systemic therapy with doxorubicin administered as a continuous three day infusion (20 mg/m²/day) on a 21 day cycle in the inpatient setting. A continuous infusion of doxorubicin was selected based on small, prior studies suggesting that acute and chronic toxicities, including bone marrow suppression, may be lessened when doxorubicin is

administered as a continuous versus bolus infusion [11–13]. The patient ultimately received 3 cycles of this therapy. During the first cycle, the doxorubicin dose was reduced by 50% due to increased transaminases that normalized with subsequent cycles of therapy. The second cycle was given at full dose, but was complicated by febrile neutropenia requiring hospitalization. The doxorubicin dose was therefore reduced by 25% during the third cycle. After 3 cycles of therapy, continuous doxorubicin was switched to monthly liposomal doxorubicin (40 mg/m²) for ease of administration in the outpatient setting since the patient's platelets had sufficiently recovered. As shown in Figure 2, the patient's pancytopenia steadily improved after initiation of chemotherapy. Approximately four months after commencing treatment, her WBC rose to 5.4 K/ μ L, Hgb increased to 11.6 g/dL and platelet count improved to 131 K/ μ L. Approximately thirteen months after beginning the treatment, the patient experienced a near full recovery from her pancytopenia with no evidence of anemia or thrombocytopenia. Her laboratory tests showed WBC of 4.8 K/ μ , RBC of 4.00 M/ μ L, Hgb of 12.8 g/dL and platelet count of 160 K/ μ L at that time, indicating a remarkable response to treatment (Figure 2). After four cycles of liposomal doxorubicin, the patient was transitioned to endocrine therapy with an aromatase inhibitor, letrozole. Her laboratory profile remained stable 43 months after initiation of continuous doxorubicin. In her last 12 months of life, her disease progressed in the liver, bone, orbit and brain. She was treated with radiation to the orbital metastasis and brain metastases, but declined further systemic chemotherapy. In her last month of life, her platelets dropped to 15 with normal white blood count and hemoglobin levels. She ultimately died from complications of metastatic breast cancer 44 months after her initial diagnosis.

3. Discussion

Complete bone marrow infiltration with profound pancytopenia is very uncommon in breast cancer. Bone marrow metastasis can frequently occur following development of metastatic breast cancer [14]. However, bone marrow failure as the herald of this disease is not typically seen. Very limited data exists as to the safest and most efficacious manner to treat patients with profound pancytopenia due to metastatic solid tumor involvement.

In this case, the patient's thrombocytopenia was particularly worrisome, requiring daily platelet transfusions. There was also concern that cytotoxic chemotherapy would exacerbate the patient's thrombocytopenia and increase bleeding risk. The patient's dramatic response to chemotherapy with full platelet recovery is also highly unusual. For our patient, continuous doxorubicin successfully "unpacked" the bone marrow despite a low baseline platelet level, and without increasing the need for more frequent platelet transfusion or risk of catastrophic bleeding. Given the rarity of this presentation, it is currently unknown if the majority of similar patients experience near full recovery of hematopoietic function after initiation of appropriate systemic treatment for metastatic disease.

Pancytopenia is not a common presentation in patients with metastatic breast cancer. In several studies, pancytopenia was noted as the consequence of adjuvant chemotherapy with alkylating agents and topoisomerase II inhibitors rather than metastatic disease [15]. Some have suggested that the use of growth factor support such as filgrastim or peg-filgrastim may also contribute to the risk of developing pancytopenia related to myelodysplastic syndrome

or acute myeloid leukemia, although that association has not been completely established [16]. Saito et al. reported on a metastatic breast cancer patient with pancytopenia who had evidence of concurrent therapy-related acute myeloid leukemia and bone marrow metastasis [17].

In our case, bone marrow infiltration with metastatic breast cancer was the primary cause of pancytopenia. This has rarely been described in the literature and includes both patients with both positive and negative outcomes from therapy. Several reports highlight patients who have responded to systemic therapy including low dose capecitabine, endocrine therapy and trastuzumab monotherapy [28–32]. As expected not all patients respond to therapy. Sasada et al. reported on a case of a patient with bone marrow metastasis from breast cancer [18]. The patient developed pancytopenia with disseminated intravascular coagulation (DIC) and was given weekly paclitaxel therapy with blood transfusion and G-CSF injections. Therapy was ineffective and the patient died of gastrointestinal hemorrhage due to complications of pancytopenia that were likely caused by DIC and metastatic disease [18]. Our patient experienced similar bone marrow metastasis and pancytopenia, but was able to achieve sustained disease control through doxorubicin chemotherapy followed by aromatase inhibitor therapy, without bleeding complications. In addition, laboratory tests at the time of diagnosis did not show any evidence of DIC in our case.

In addition to continuous doxorubicin, our patient received zoledronic acid as a part of management of osseous metastasis from breast cancer. Many studies have focused on the prevention of breast cancer due to subclinical bone marrow metastasis caused by dormant disseminated tumor cells (DTCs) in the bone marrow [19–21]. Although DTCs appear to be associated with a higher risk of distant recurrence, they are not known to cause abnormalities in peripheral blood laboratory tests. Solomayer et al. demonstrated the impact of zoledronic acid on DTCs in primary breast cancer patients [22]. The authors found that DTC-positive patients treated with zoledronic acid were more likely to become DTC-negative following a 12 month treatment interval and concluded that treatment with zoledronic acid improved the elimination of DTCs [22]. The role of bisphosphonates in preventing skeletal metastases in patients with high risk early stage breast cancer is controversial [20,23–27]. The contribution of zoledronic acid in bone marrow recovery in this instance is not known.

4. Conclusion

Breast cancer has a tendency to metastasize to the bone marrow, but does not commonly cause bone marrow failure. The case presented describes a patient who developed complete bone marrow infiltration by estrogen receptor positive metastatic breast cancer that led to transfusion dependent pancytopenia. The patient received treatment with continuous doxorubicin and zoledronic acid followed by endocrine therapy, which resulted in complete recovery of normal bone marrow function for 3 years. Drug therapy is a consideration in patients with bone marrow infiltration with good performance status.

Acknowledgments

MBL and RW were supported by NIH K12 training grants.

References

1. Siegel R, Ma J, Zou Z, Jemal A. Cancer statistics. *CA Cancer J Clin.* 2014; 64:9–29. [PubMed: 24399786]
2. Kennecke H, Yerushalmi R, Woods R, et al. Metastatic behavior of breast cancer subtypes. *J Clin Oncol.* 2010; 28:3271–3277. [PubMed: 20498394]
3. Early Breast Cancer Trialists' Collaborative Group (EBCTCG). Effects of chemotherapy and hormonal therapy for early breast cancer on recurrence and 15-year survival: an overview of the randomised trials. *Lancet.* 2005; 365:1687–1717. [PubMed: 15894097]
4. Manders K, van de Poll-Franse LV, Creemers GJ, et al. Clinical management of women with metastatic breast cancer: a descriptive study according to age group. *BMC Cancer.* 2006; 6:179. [PubMed: 16824210]
5. Ahn SG, Lee HM, Cho SH, et al. Prognostic factors for patients with bone-only metastasis in breast cancer. *Yonsei Med J.* 2013; 54:1168–1177. [PubMed: 23918566]
6. Kamby C, Guldhammer B, Vejborg I, et al. The presence of tumor cells in bone marrow at the time of first recurrence of breast cancer. *Cancer.* 1987; 60:1306–1312. [PubMed: 3621113]
7. Coleman RE, Rubens RD. The clinical course of bone metastases from breast cancer. *Br J Cancer.* 1987; 55:61–66. [PubMed: 3814476]
8. Galasko CS. Skeletal metastases. *Clin Orthop Relat Res.* 1986; 210:18–30. [PubMed: 3757360]
9. Galasko CS. The development of skeletal metastases. *Nihon Seikeigeka Gakkai Zasshi.* 1989; 63:667–676. [PubMed: 2794640]
10. Klevesath MB, Pantel K, Agbaje O, et al. Patterns of metastatic spread in early breast cancer. *Breast.* 2013; 22:449–454. [PubMed: 23726130]
11. Legha SS, Benjamin RS, Mackay B, et al. Adriamycin therapy by continuous intravenous infusion in patients with metastatic breast cancer. *Cancer.* 1982; 49:1762–1766. [PubMed: 7074581]
12. Hortobagyi GN, Yap HY, Kau SW, et al. A comparative study of doxorubicin and epirubicin in patients with metastatic breast cancer. *Am J Clin Oncol.* 1989; 12:57–62. [PubMed: 2643296]
13. Jasmin C, Gil-Delgado MA, Marino JP, Ecstein E, Descorps-Declere A, Misset JL. Phase I–II constant infusion of adriamycin (doxorubicin) by ambulatory pump delivery system in heavily pretreated (including adriamycin) breast cancer patients. *Ann Oncol.* 1990; 1:189–193. [PubMed: 2261365]
14. Hüsemann Y, Geigl JB, Schubert F, et al. Systemic spread is an early step in breast cancer. *Cancer Cell.* 2008; 13:58–68. [PubMed: 18167340]
15. Kaplan HG, Malmgren JA, Atwood MK. Increased incidence of myelodysplastic syndrome and acute myeloid leukemia following breast cancer treatment with radiation alone or combined with chemotherapy: a registry cohort analysis 1990–2005. *BMC Cancer.* 2011; 11:260. [PubMed: 21693006]
16. Hershman D, Neugut AI, Jacobson J, et al. Acute myeloid leukemia or myelodysplastic syndrome following use of granulocyte colony-stimulating factors during breast cancer adjuvant chemotherapy. *J Natl Cancer Inst.* 2007; 99:196–205. [PubMed: 17284714]
17. Saito M, Mori A, Irie T, Tanaka M, Morioka M. Therapy-related acute myeloid leukemia with 11q23 abnormality due to paclitaxel coexisting with bone marrow metastasis of breast cancer. *Rinsho Ketsueki.* 2009; 50:192–196. [PubMed: 19352087]
18. Sasada S, Yokoyama G, Takahashi H, Koike K, Ikejiri K, Fujii T. A case of recurrent breast cancer with bone marrow metastasis treated with weekly paclitaxel therapy. *Gan Kagaku Ryoho.* 2008; 35:1611–1613.
19. Hoffman O, Aktas B, Goldnau C, et al. Effect of ibandronate on disseminated tumor cells in the bone marrow of patients with primary breast cancer: a pilot study. *Anticancer Res.* 2011; 31:3623–3628. [PubMed: 21965788]
20. Diel IJ, Solomayer EF, Costa SD, et al. Reduction in new metastases in breast cancer with adjuvant clodronate treatment. *N Engl J Med.* 1998; 339:357–363. [PubMed: 9691101]

21. Rack B, Jückstock J, Günthner-Biller M, et al. Trastuzumab clears HER2/neu-positive isolated tumor cells from bone marrow in primary breast cancer patients. *Arch Gynecol Obstet.* 2012; 285:485–492. [PubMed: 21717141]
22. Solomayer EF, Gebauer G, Hirnle P, et al. Influence of zoledronic acid on disseminated tumor cells in primary breast cancer patients. *Ann Oncol.* 2012; 23:2271–2277. [PubMed: 22383680]
23. Powles T, Peterson S, Kanis JA, et al. Randomized, placebo-controlled trial of clodronate in patients with primary operable breast cancer. *J Clin Oncol.* 2002; 20:3219–3224. [PubMed: 12149294]
24. Ha TC, Li H. Meta-analysis of clodronate and breast cancer survival. *Br J Cancer.* 2007; 96:1796–1801. [PubMed: 17325699]
25. Gnant M, Mlineritsch B, Schippinger W, et al. Endocrine therapy plus zoledronic acid in premenopausal breast cancer. *N Engl J Med.* 2009; 360:679–691. [PubMed: 19213681]
26. Coleman RE, Marshall H, Cameron D, et al. Breast-cancer adjuvant therapy with zoledronic acid. *N Engl J Med.* 2011; 365:1396–1405. [PubMed: 21995387]
27. Saarto T, Blomqvist C, Virkkunen P, Elomaa I. Adjuvant clodronate treatment does not reduce the frequency of skeletal metastases in node-positive breast cancer patients: 5-year results of a randomized controlled trial. *J Clin Oncol.* 2001; 19:10–17. [PubMed: 11134190]
28. Kopp HG, Krauss K, Fehm T, Staebler A, Zahm J, Vogel W, Kanz L, Mayer F. Symptomatic bone marrow involvement in breast cancer—clinical presentation, treatment, and prognosis: a single institution review of 22 cases. *Anticancer Res.* 2011; 31(11):4025–4030. [PubMed: 22110237]
29. Freyer G, Ligneau B, Trillet-Lenoir V. Palliative hormone therapy, low-dose chemotherapy, and bisphosphonate in breast cancer patients with bone marrow involvement and pancytopenia: report of a pilot experience. *Eur J Intern Med.* 2000; 11(6):329–333. [PubMed: 11113657]
30. Ardavanis A, Kountourakis P, Orphanos G, Rigatos G. Low-dose capecitabine in breast cancer patients with symptomatic bone marrow infiltration: a case study. *Anticancer Res.* 2008; 28:539–542. [PubMed: 18383899]
31. Bjelic-Radisic V, Stöger H, Winter R, Beham-Schmid C, Petru E. Long-term control of bone marrow carcinosis and severe thrombocytopenia with standard-dose chemotherapy in a breast cancer patient: a case report. *Anticancer Res.* 2006; 26:1627–1630. [PubMed: 16619583]
32. Xu L, Guo F, Song S, Zhang G, Liu Y, Xie X. Trastuzumab monotherapy for bone marrow metastasis of breast cancer: a case report. *Oncol Lett.* 2014; 7:1951–1953. [PubMed: 24932266]

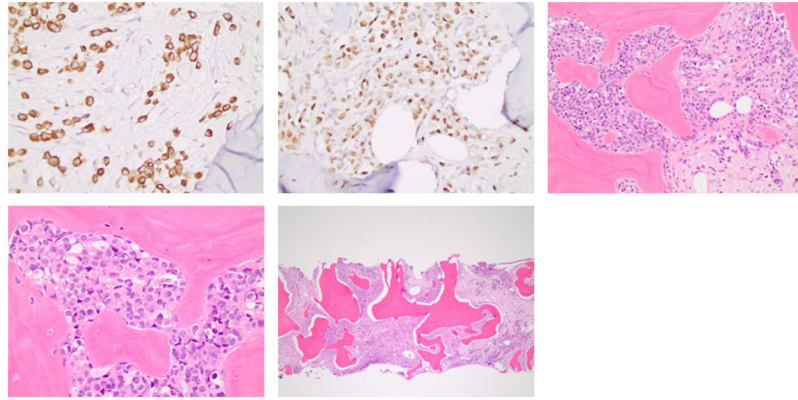


Figure 1.

The bone marrow biopsy shows that the hematopoietic elements are entirely replaced by fibrosis and metastatic carcinoma infiltrating individually and in small clusters, and comprised of intermediate sized cells with round to ovoid nuclei, a thin rim of cytoplasm and occasional intracytoplasmic vacuoles.

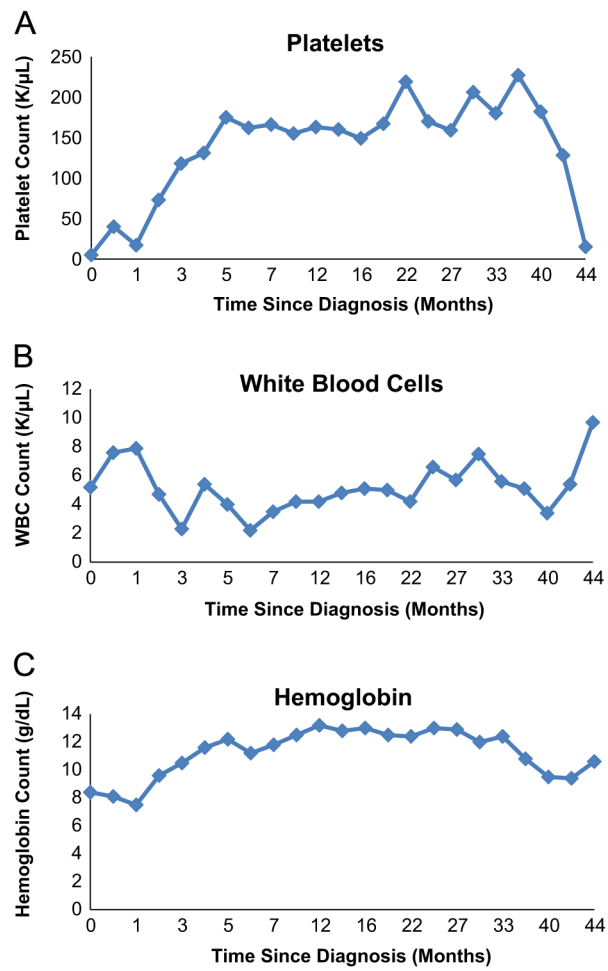


Figure 2. Patient's platelet (A), white blood cell (B) and hemoglobin (C) levels throughout treatment highlighting hematopoietic recovery after continuous doxorubicin therapy.