

Ex Vivo Evaluation of the Accuracy of 3 Electronic Apex Locators in Different Environments: A Micro-Computed Tomography Study

 Firdevs ÇINAR,  Yakup ÜSTÜN

ABSTRACT

Objective: The aim of this study was to compare the accuracy of three electronic apex locators (EALs) (Propex Pixi, Mini Root ZX, Raypex 5) in determining working length (WL) under different environments (existence of blood-pulp/sodium hypochlorite in root canal space) using micro-computed tomography (micro-CT) measurements.

Methods: Twenty-five single-rooted human teeth that were scheduled for extraction were selected for the study. Measurements were performed with the Propex Pixi, Mini Root ZX, Raypex 5 in vivo conditions in the presence of NaOCl irrigant solution or blood-pulp tissue. After that the teeth were extracted and scanned using micro-CT. The measurements of WL obtained with the different EALs in different environments were statistically compared. Significance was set at $P < 0.05$.

Results: There were no significant differences among the WL measurements performed with EALs or micro CT groups under different clinical environments. All EALs tested gave reliable results in respect to apical constriction.

Conclusion: The accuracy of the tested EALs is not affected by pulp tissues and blood or NaOCl.

Keywords: mini Root ZX, NaOCl, Propex pixi, Raypex 5

HIGHLIGHTS

- This study examined the accuracy of three electronic apex locators in determining the working length under different environments.
- The new generation EALs are not affected from NaOCl or blood/pulp tissue existence in the root canal.

INTRODUCTION

In endodontology, the working length (WL) is defined as the distance from a coronal reference point to the point at which canal preparation and root canal filling should terminate. However the end point of instrumentation is still debated (1). In the root canal anatomy, apical constriction (AC) is the narrowest diameter of the root canal system (2, 3). Several

studies consider the AC of the root canal system as the end point of instrumentation or obturation processes (2, 3). However, the location of AC is difficult due to the anatomical variations that could vary depending on various factors (4-6). There are several methods for determination of the WL such as assessment of preoperative radiographs, tactile sensation and electronic apex locators (EALs) (7, 8).

Electronic apex locators (EAL) provide reliable and accurate results in working length determinations (9). Propex Pixi (Dentsply Maillefer, Ballaigues, Switzerland) is a recently introduced multi-frequency EAL, Mini Root ZX (J Morita Corp., Tokyo, Japan) is another contemporary EAL that uses the 'ratio method'. Raypex 5 (VDW, Munich, Germany) is a frequency-based EAL, and it measures the impedance at two different frequencies (0.4 kHz and 8 kHz), but uses only one frequency at each time interval and the measurements are based on mean square values of signals (10).

There are several investigations about the accuracy of EALs in different environments (9, 11-14). However, the accuracy of EALs may be affected by some conditions such as periapical lesions, im-

Please cite this article as: Çınar F, Üstün Y. Ex Vivo Evaluation of the Accuracy of 3 Electronic Apex Locators in Different Environments: A Micro-Computed Tomography Study. Eur Endod J 2020; 3: 226-30

From the Private practice limited to Endodontics (F.Ç.), Ortoperi Dental Clinic, Kayseri, Turkey; Department of Endodontics (Y.Ü. ✉ yakupustun33@hotmail.com), Erciyes University, Faculty of Dentistry, Kayseri, Turkey

Received 23 March 2020,
Accepted 13 June 2020

Published online: 18 December 2020
DOI 10.14744/eej.2020.30633

This work is licensed under a Creative Commons Attribution-NonCommercial 4.0 International License.



mature apex formation, apical foramen size, electrical conductivity of the intracanal fluid (such as, irrigants, pulp) (12, 14-17).

The use of micro-computed tomography (micro-CT) gives opportunity to view detailed 3-dimensional (3D) analyses of extracted teeth's internal anatomy with the high-resolution radiographic scanings of the specimen (18-21). With the aid of micro-CT, the AC can be determined accurately without destruction of the tooth structure (4). The AC can be determined by evaluating the canal cross-sectional area and not by locating the minor diameter in one longitudinal section (22). In one micro-CT study, ElAyouti et al. (4) determined the location and dimension of the AC in molar teeth. Piasecki et al. (5) investigated the accuracy of two apex locators in different anatomic variations using micro-CT. However, according to our knowledge there is no written data comparing the in vivo WL measurements of different EALs under different circumstances using micro-CT.

The aim of this study was to compare the performances of different EALs in determining WL-AC under different circumstances (existence of blood, pulp/sodium hypochlorite in root canal space) with micro-CT measurements.

MATERIALS AND METHODS

Erciyes University Medical Sciences ethical board (Kayseri, Turkey) approved this investigation (Ethics Approval Number: 2016-459). All procedures performed in studies involving human participants were in accordance with the ethical standards of the institutional and/or national research committee and with the 1964 Helsinki declaration and its later amendments or comparable ethical standards.

The present investigation included 18 patients (11 male, 7 female) who were consulted to the Erciyes University Faculty of Dentistry, Department of Oral and Maxillofacial Surgery for extraction of their teeth with single canal and single root (16 incisors, 9 premolars). Inclusion criteria for patients were as following:

- Patients aged 20-60 years who do not have general health problems that would prevent endodontic therapy
- Teeth diagnosed for extraction due to orthodontic or periodontal treatment planning
- Teeth without periapical pathology visible on radiography.
- Teeth with single root and canal with completely formed apices and teeth with no root resorption (internal or external)
- Teeth with vital pulp were included. Teeth that respond to cold test (Coltene/Whaledent Inc, Cuyahoga, OH) were included.

Anesthesia (Ultracain DS forte® Sanofi-Aventis, Frankfurt Main, Germany) was performed, and a dental rubber dam was placed. If a flat reference point was not available, the cusp tip or incisal edge was flattened by using a diamond bur (Henry Schein®, Melville, NY, USA) in a high-speed handpiece under water cooling. Access cavity was opened by using a #4 car-

bide bur. Restrictive cervical bulk dentin was removed by using Gates-Glidden (VDW, Munich, Germany) drills with a low speed handpiece. Apical patency was checked with #8 K-File (Dentsply Maillefer, Ballaigues, Switzerland). Then, WL measurements were performed with EALs by an experienced endodontist.

The WL measurements were performed under two different circumstances (in existence of blood and pulp tissue and in existence of NaOCl in the root canals).

WL measurements in presence of blood and pulp tissue in the root canals

A sterile paper point was inserted into the root canal and checked if it was wet by blood in order to confirm the existence of blood and pulp tissue in the root canal space. The measurements were recorded as WLBlood for each EAL. A #10 size K-file (Dentsply Maillefer) attached to the EAL device was then introduced into the root canal, and the lip hook of each EAL device was put onto the lip of the patient.

WL measurements in presence of 2.5 % sodium hypochlorite in the root canals

Pulp tissue was removed with a sterile barbed broach and root canal was irrigated with copious 2.5% NaOCl by a 27-gauge needle. The measurements were recorded as WLNaOCl for each EAL. A #10 size K-file attached to the EAL device was then introduced into the root canal, and the lip hook of each EAL device was put onto the lip of the patient.

EAL measurements

Measurements with Mini Root ZX

The Mini Root ZX (J Morita Corp., Tokyo, Japan) was used in accordance with the manufacturer's instructions. A size 10 K-file attached to EAL was placed into the root canal and advanced down the canal without force. A rubber stop on the file, which was in contact with the flat, horizontal surface of the crown, was fixed to the file with a flowable light-curing resin (Nova Compo HF Flow; Imicryl, Konya, Turkey) at the position when the flashing bars of the EAL reached the level that presented '00' on its LCD screen.

Measurements with RayPex 5

The Raypex 5 (VDW, Munich, Germany) was used in accordance with the manufacturer's instructions. A #10 K-file was attached to EAL and advanced within the root canal to the major foramen (red light) and retracted until three green and four yellow bars appeared. Then, rubber stop on the file, which was in contact with the flat, horizontal surface of the crown, was fixed to the file with a flowable light-curing resin.

Measurements with Propex Pixi

The Propex Pixi (Dentsply Maillefer, Ballaigues, Switzerland) was used in accordance with the manufacturer's instructions. When the 0.0 signal was seen by the operator, the file was gently moved beyond the apex until the "beyond apex" signal appeared, at which point the file was quickly withdrawn and stopped at the 0.0 point. A rubber stop on the file, which was in contact with the flat, horizontal surface of the crown, was fixed to the file with a flowable light-curing resin.

All measurements were considered to be valid if the reading/signal on screen remained stable for at least 5 seconds. The distances between the stop and the file tip was measured with digital calipers (Insize Mini digital caliper; Istanbul, Turkey) (at 0.01 mm accuracy) and recorded as the initial length of the root. The WL measurements were repeated 3 times with each EAL, and the mean value was recorded. Finally, 0.5 mm was subtracted from this measurement and recorded for each EAL.

After the measurements completed with each EAL for two circumstances, the teeth were extracted in a gently manner without causing any fracture.

Micro-CT Scan

Each sample was scanned in the micro-CT SkyScan 1272 (Bruker microCT, Kontich, Belgium) at a 70 KV, 142 μ A and 12 μ m resolution. Images were reconstructed using NRecon V1.6.9.3 software (Bruker microCT), and analyzed using CTAn v1.11.10 software (Bruker microCT). All scans were visualized by 1 calibrated operator. If the AF was deviated from the long axis of the root, the images were reoriented to show the exact inclination of the AF. The slices were moved coronally from AF to AC and the narrowest diameter was detected by measuring canal lumens in buccolingual and mesiodistal directions (Fig. 1).

The length of the canal was acquired from the coronal reference point (at the most incisal or occlusal plane of teeth with a flat and constant reference point also the same reference point for all EALs in clinical applications) up to the most coronal slice showing the AC (WL) at 0.025 mm precision and recorded (Fig 1). Also distance from AC to major foramen was calculated and recorded. All measurements were completed through the center of the root canals by the same operator.

Statistical analyses

All statistical analyses were performed with Sigmastat 3.1 (SigmaStat; Systat, San Jose, CA). The normality test of Shapiro-

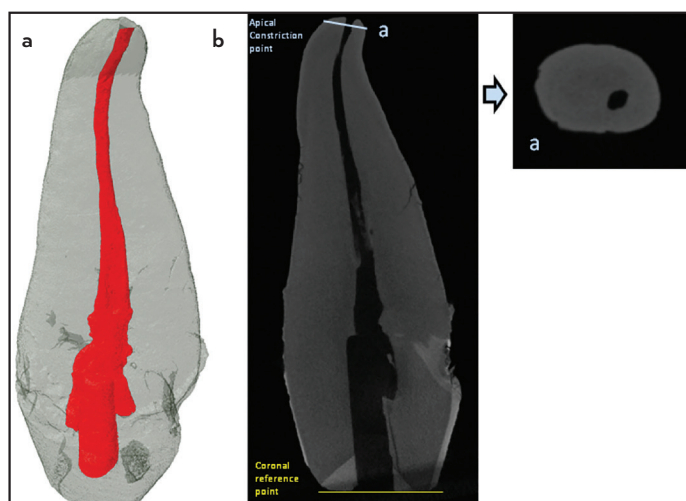


Figure 1. 3D model of the root canal is shown at (a) The apical constriction point of root canal is shown at (b) with “a” and also coronal reference point is shown with yellow line. The horizontal micro-CT section of apical constriction is shown with smaller figure

TABLE 1. Mean and Standard Deviation and error (mm) obtained for distances to AC in absolute value according to the tested EALs under different circumstances

Groups	Mean	SD	SD error
Root ZX Blood	0.385	0.299	0.0611
Root ZX NaOCl	0.359	0.266	0.0543
Raypex Blood	0.429	0.296	0.0605
Raypex NaOCl	0.47	0.274	0.056
Pixi Blood	0.36	0.259	0.0529
Pixi NaOCl	0.464	0.297	0.0607

SD: Standard deviation

Wilk was applied to the data ($\alpha=0.05$). The sample failed the normality test ($P<0.05$); consequently, Friedman Repeated Measures Analysis of Variance on Ranks test was used ($\alpha=0.05$). The EAL measurements were evaluated within the ± 0.50 -mm range from the reference landmarks.

RESULTS

According to the measurements mean distance from AC to major foramen was calculated as 0.416 mm. There were no significant differences among the WL measurements performed with EALs or micro CT groups ($P>0.05$) (Table 1, Fig. 2). Neither the presence of blood-pulp tissue nor 2.5 % NaOCl solution in the root canal did significantly affect the WL measurements.

DISCUSSION

In the present study, accuracies of 3 different EALs used in different clinical conditions to determine AC was compared by micro-CT. In order to obtain a standardized reference point incisal surfaces of teeth were flattened. WL measurements were done from this flattened surface to AC as determined by micro-CT images or EALs.

In order to avoid sequence bias, apex locators were used in a randomized order. Before in vivo measurements, all EALs were always fully charged and always used as described in the manufacturer’s manual.

De Camargo et al. (23) found that preflaring of the root canal orifices give more accurate results in EALs. Therefore all the teeth were preflared before the EAL measurements. In previous studies, EAL readings with an error range of ± 0.5 mm considered as accurate (5, 16, 24, 25). Therefore, in the present study, EAL readings with an error range of ± 0.5 mm were accepted as accurate.

In sample selection, only teeth with single root, straight and single canal and single foramen were used, because all WL measurements were done from the center point of root canal space from apical reference point (apical constriction) to coronal reference point. By this way, all WL measurements were done in a straight line through multiple reference points.

Micro-CT is a nondestructive method for evaluation anatomical landmarks in tooth samples. Therefore, we preferred to use micro-CT analyzing tool for WL measurements. Previous

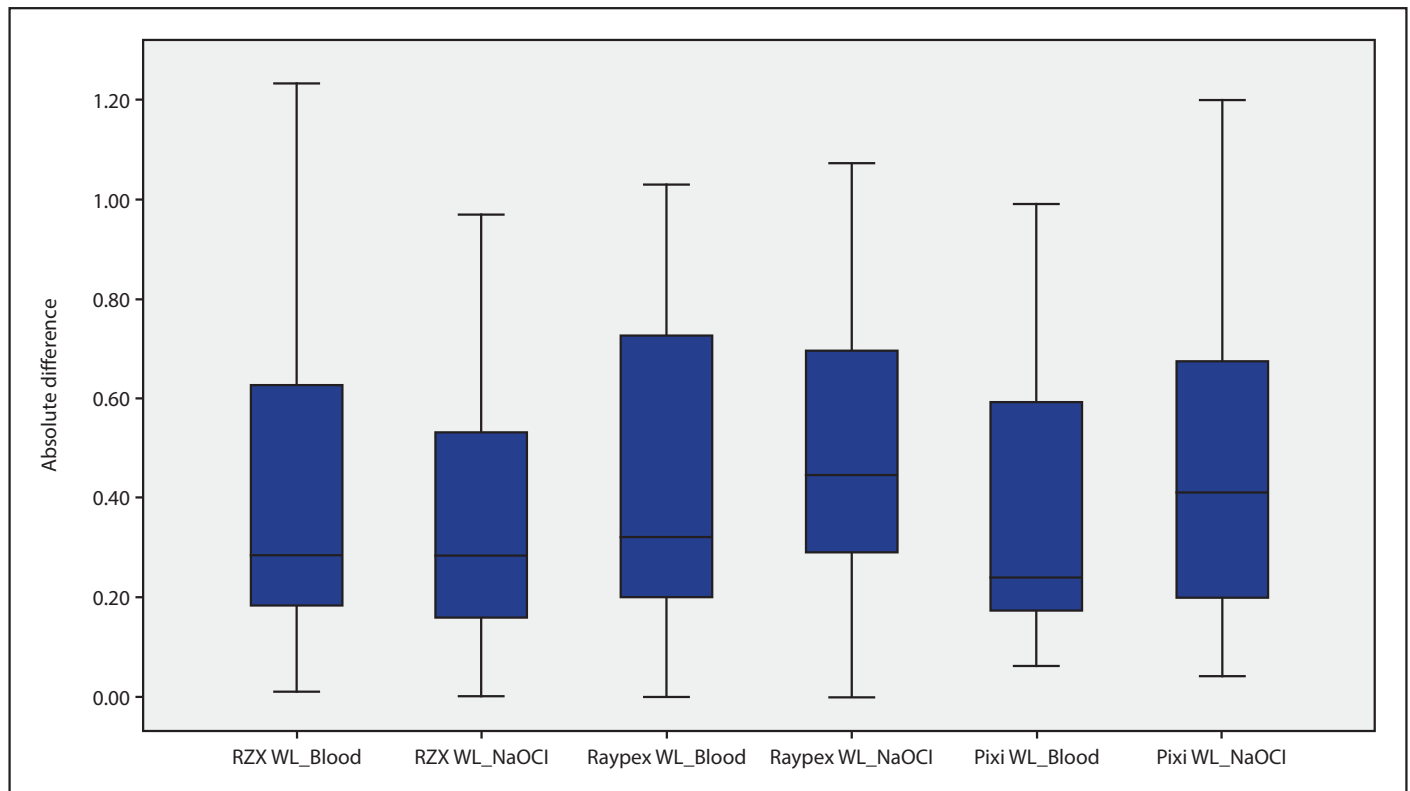


Figure 2. The horizontal line indicates the position of the AC found in Micro Ct measurements. Positive values (above the line) indicate measurements beyond the AC; negative values are short of the AC

studies determined the location of the apical constriction with longitudinal slices (2, 26), however, Schell et al. (22) showed that this method is unsuitable for correct determination of AC. With the aid of micro-CT technology, it is possible to determine the narrowest apical part of the entire root canal.

The distance between AC-AF was investigated by some authors (2, 4). Kuttler (2) stated the distance from AC to AF as 0.52 mm to 0.66 mm. Elayouti et al. (4) showed the AC-AF distance as 0.2 mm. In the present study, we found the mean distance between AC-AF as 0.416 mm. However, in the present study we have evaluated 25 teeth (16 incisors, 9 premolars). Our results could be related to our sample size and different teeth types. Further investigations with larger sample sizes are needed.

In several studies it was reported that endodontic irrigants could affect the accuracy of EALs (27, 28). However, some investigators found that EALs gave accurate results irrespective of the used irrigant (29, 30). Besides, in endodontic treatment process of vital teeth bleeding is inevitable. Since blood is an electrolyte, it may also influence the accuracy of EALs (14, 31).

Saatchi et al.(14) evaluated *in vivo* the accuracy of the Raypex 5 and Root ZX EALs in the presence of blood in the root canal space. They found that presence of blood in the root canal space did not influence the accuracy of tested EALs. Our results were in accordance with the study of Saatchi et al. (14). According to our results, in existence of blood-pulp tissue in

the root canal, there were no statistically significant differences among the groups ($P>0.05$). However, Propex Pixi and Root ZX mini showed more similar results when compared to micro-CT measurements, and Raypex 5 gave slightly different results than Propex Pixi and Root ZX mini ($P>0.05$). This could be related to their new generation technology.

In several studies, EAL measurements performed in existence of NaOCl irrigation solution in the root canal gave inaccurate results (27, 28, 32, 33). In the present study, we found that NaOCl did not affect the accuracy of EALs. None of these studies evaluated the accuracies of EALs with micro-CT. Differences in results may be attributed to different methodologies.

On the other side, Ebrahim et al. (31) found that Root ZX EAL gave accurate results in existence of NaOCl in the root canals. They related this result to NaOCl's highly electro-conductivity and infiltration property into dentinal tubules which resulted in reduction of electrical impedance of the root canal wall. In addition, Gomes et al. (34) showed that NaOCl solution did not affect the *in vivo* accuracy of Raypex 5. According to the results, we also found that NaOCl did not affect the accuracy of EALs. This could be related to the high electro-conductivity and infiltration property of NaOCl.

CONCLUSION

Within the limitations of this study, it can be concluded that the accuracy of Raypex 5, Root ZX mini and Propex Pixi EALs are not affected by existence of blood-pulp tissue or NaOCl.

Disclosures

Conflict of Interest: Authors of this manuscript declare that they have No conflicts of interest related to this work.

Ethics Committee Approval: This study is ethically approved by Erciyes University Medical Sciences ethical board (Ethics Approval Number: 2016-459). All procedures performed in studies involving human participants were in accordance with the 1964 Helsinki declaration and its later amendments or comparable ethical standards.

Peer-review: Externally peer-reviewed.

Financial Disclosure: None declared.

Authorship contributions: Concept – Y.Ü.; Design – Y.Ü.; Supervision – Y.Ü., F.Ç.; Funding – F.Ç.; Materials – F.Ç.; Data collection &/or processing – F.Ç.; Analysis and/or interpretation – F.Ç., Y.Ü.; Literature search – F.Ç., Y.Ü.; Writing – Y.Ü.; Critical Review – F.Ç., Y.Ü.

REFERENCES

- Gutmann JL. Biologic perspectives to support clinical choices in root canal treatment. *Aust Endod J* 2005; 31(1):9–13.
- Kuttler Y. Microscopic investigation of root apexes. *J Am Dent Assoc* 1955; 50(5):544–52.
- Ricucci D, Langeland K. Apical limit of root canal instrumentation and obturation, part 2. A histological study. *Int Endod J* 1998; 31(6):394–409.
- ElAyouti A, Hülber-J M, Judenhofer MS, Connert T, Mannheim JG, Löst C, et al. Apical constriction: location and dimensions in molars-a micro-computed tomography study. *J Endod* 2014; 40(8):1095–9.
- Piasecki L, Carneiro E, da Silva Neto UX, Westphalen VP, Brandão CG, Gambarini G, et al. The Use of Micro-Computed Tomography to Determine the Accuracy of 2 Electronic Apex Locators and Anatomic Variations Affecting Their Precision. *J Endod* 2016; 42(8):1263–7.
- Marceliano-Alves M, Alves FR, Mendes Dde M, Provenzano JC. Micro-Computed Tomography Analysis of the Root Canal Morphology of Palatal Roots of Maxillary First Molars. *J Endod* 2016; 42(2):280–3.
- Heo MS, Han DH, An BM, Huh KH, Yi WJ, Lee SS, et al. Effect of ambient light and bit depth of digital radiograph on observer performance in determination of endodontic file positioning. *Oral Surg Oral Med Oral Pathol Oral Radiol Endod* 2008; 105(2):239–44.
- Üstün Y, Aslan T, Şekerci AE, Sağsen B. Evaluation of the Reliability of Cone-beam Computed Tomography Scanning and Electronic Apex Locator Measurements in Working Length Determination of Teeth with Large Periapical Lesions. *J Endod* 2016; 42(9):1334–7.
- Martins JN, Marques D, Mata A, Caramês J. Clinical efficacy of electronic apex locators: systematic review. *J Endod* 2014; 40(6):759–77.
- Nekoofar MH, Ghandi MM, Hayes SJ, Dummer PM. The fundamental operating principles of electronic root canal length measurement devices. *Int Endod J* 2006; 39(8):595–609.
- Mayed DL, Simon JH, Aymar DF, Finley K. In vivo measurement accuracy in vital and necrotic canals with the Endex apex locator. *J Endod* 1993; 19(11):545–8.
- McDonald NJ. The electronic determination of working length. *Dent Clin North Am* 1992; 36(2):293–307.
- Ustun Y, Uzun O, Er O, Canakci BC, Topuz O. The effect of residual calcium hydroxide on the accuracy of a contemporary electronic apex locator. *Acta Odontol Scand* 2015; 73(2):132–6.
- Saatchi M, Aminozarbian MG, Noormohammadi H, Baghaei B. Influence of Blood on the Accuracy of Raypex 5 and Root ZX Electronic Foramen Locators: An In Vivo Study. *Braz Dent J* 2016; 27(3):336–9.
- Frank AL, Torabinejad M. An in vivo evaluation of Endex electronic apex locator. *J Endod* 1993; 19(4):177–9.
- Herrera M, Ábalos C, Lucena C, Jiménez-Planas A, Llamas R. Critical diameter of apical foramen and of file size using the Root ZX apex locator: an in vitro study. *J Endod* 2011; 37(9):1306–9.
- Marigo L, Gervasi GL, Somma F, Squeo G, Castagnola R. Comparison of two electronic apex locators on human cadavers. *Clin Oral Investig* 2016; 20(7):1547–50.
- Leoni GB, Versiani MA, Pécora JD, Damião de Sousa-Neto M. Micro-computed tomographic analysis of the root canal morphology of mandibular incisors. *J Endod* 2014; 40(5):710–6.
- Marceliano-Alves MF, Sousa-Neto MD, Fidel SR, Steier L, Robinson JP, Pécora JD, et al. Shaping ability of single-file reciprocating and heat-treated multifile rotary systems: a micro-CT study. *Int Endod J* 2015; 48(12):1129–36.
- Versiani MA, Pécora JD, de Sousa-Neto MD. Root and root canal morphology of four-rooted maxillary second molars: a micro-computed tomography study. *J Endod* 2012; 38(7):977–82.
- Versiani MA, Pécora JD, Sousa-Neto MD. Microcomputed tomography analysis of the root canal morphology of single-rooted mandibular canines. *Int Endod J* 2013; 46(9):800–7.
- Schell S, Judenhofer MS, Mannheim JG, Hülber-J M, Löst C, Pichler BJ, et al. Validity of longitudinal sections for determining the apical constriction. *Int Endod J* 2017; 50(7):706–12.
- de Camargo EJ, Zapata RO, Medeiros PL, Bramante CM, Bernardineli N, Garcia RB, et al. Influence of preflaring on the accuracy of length determination with four electronic apex locators. *J Endod* 2009; 35(9):1300–2.
- de Vasconcelos BC, Veríssimo Chaves RD, Vivacqua-Gomes N, Candeiro GT, Bernardes RA, Vivan RR, et al. Ex Vivo Evaluation of the Accuracy of Electronic Foramen Locators in Root Canals with an Obstructed Apical Foramen. *J Endod* 2015; 41(9):1551–4.
- Piasecki L, Carneiro E, Fariniuk LF, Westphalen VP, Fiorentin MA, da Silva Neto UX. Accuracy of Root ZX II in locating foramen in teeth with apical periodontitis: an in vivo study. *J Endod* 2011; 37(9):1213–6.
- Dummer PM, McGinn JH, Rees DG. The position and topography of the apical canal constriction and apical foramen. *Int Endod J* 1984; 17(4):192–8.
- Fan W, Fan B, Gutmann JL, Bian Z, Fan MW. Evaluation of the accuracy of three electronic apex locators using glass tubules. *Int Endod J* 2006; 39(2):127–35.
- Ozsezer E, Inan U, Aydin U. In vivo evaluation of ProPex electronic apex locator. *J Endod* 2007; 33(8):974–7.
- Meares WA, Steiman HR. The influence of sodium hypochlorite irrigation on the accuracy of the Root ZX electronic apex locator. *J Endod* 2002; 28(8):595–8.
- Tinaz AC, Sevimli LS, Görgül G, Türköz EG. The effects of sodium hypochlorite concentrations on the accuracy of an apex locating device. *J Endod* 2002; 28(3):160–2.
- Ebrahim AK, Yoshioka T, Kobayashi C, Suda H. The effects of file size, sodium hypochlorite and blood on the accuracy of Root ZX apex locator in enlarged root canals: an in vitro study. *Aust Dent J* 2006; 51(2):153–7.
- Khursheed I, Bansal R, Bansal T, Singh HP, Yadav M, Reddy KJ. A comparative evaluation of working length with digital radiography and third generation apex locator (ProPex) in the presence of various intracanal irrigants: An in vivo/ex vivo study. *Dent Res J (Isfahan)* 2014; 11(1):56–60.
- Altunbaş D, Kuştarıcı A, Toyoğlu M. The Influence of Various Irrigants on the Accuracy of 2 Electronic Apex Locators in Locating Simulated Root Perforations. *J Endod* 2017; 43(3):439–42.
- Gomes S, Oliver R, Macouzet C, Mercadé M, Roig M, Duran-Sindreu F. In vivo evaluation of the Raypex 5 by using different irrigants. *J Endod* 2012; 38(8):1075–7.