

Benign testicular neoplasm in a human immunodeficiency virus-positive patient masquerading as testicular cancer

Mansi Oberoi¹, Thanmaya Reddy², Jennifer B. Gordetsky³, John V. Thomas¹, Soroush Rais-Bahrami^{1,2}

Departments of ¹Radiology, ²Urology and ³Pathology, University of Alabama at Birmingham, Birmingham, AL, USA

Abstract

Inflammatory myofibroblastic tumor (IMT) is a rare, benign neoplasm comprising spindle myoepithelial cells in the background of inflammatory cells. It can involve multiple anatomic sites in the body but rarely involves the testis. We report a case of 52-year-old male patient with a history of human immunodeficiency virus who presented with a painless, testicular mass for 2 months. Despite being treated with prolonged antibiotics and nonsteroidal anti-inflammatory drugs, scrotal ultrasound demonstrated an increase in the size of the lesion. With a presumed diagnosis of testicular germ cell tumor, a right radical inguinal orchiectomy was performed. Microscopic and immunohistochemical features were consistent with testicular IMT, a benign neoplastic process.

Keywords: Germ-cell tumor, scrotal ultrasound, testis cancer, tumor markers

Address for correspondence: Dr. Soroush Rais-Bahrami, Department of Urology, University of Alabama at Birmingham, Faculty Office Tower 1107, 510 20th Street South, Birmingham, AL 35294, USA.

E-mail: sraibahrami@uabmc.edu

Received: 29.04.2017, **Accepted:** 27.07.2017

INTRODUCTION

Inflammatory myofibroblastic tumor (IMT) is an uncommon neoplasm comprising spindle myoepithelial cells with an associated inflammatory background. Although benign, this tumor can be aggressive and locally invasive. IMT has been described in multiple anatomic sites but rarely involves the testis. When these tumors do occur in the paratesticular area, they can be mistaken clinically for a germ cell tumor or sarcoma.

Germ cell tumors have been reported in patients with human immunodeficiency virus (HIV) infection and adult immunodeficiency virus (AIDS), but there are limited data on testicular IMT in HIV-positive patients.

CASE REPORT

A 52-year-old male with a history of HIV presented with a right testicular mass that had been progressively enlarging for 2 months. The patient was started on a new antiretroviral medication a few weeks before first noticing the mass. He was asymptomatic and denied any history of urinary tract infection, urolithiasis, weight change, systemic symptoms, trauma, or tuberculosis exposure. Physical examination revealed a nontender, 1.5 cm firm mass posterior but adherent to the right testicle, with consideration of possible epididymal versus testicular origin. The overlying scrotal skin was normal. No nodularity or masses were felt on digital rectal examination.

This is an open access article distributed under the terms of the Creative Commons Attribution-NonCommercial-ShareAlike 3.0 License, which allows others to remix, tweak, and build upon the work non-commercially, as long as the author is credited and the new creations are licensed under the identical terms.

For reprints contact: reprints@medknow.com

How to cite this article: Oberoi M, Reddy T, Gordetsky JB, Thomas JV, Rais-Bahrami S. Benign testicular neoplasm in a human immunodeficiency virus-positive patient masquerading as testicular cancer. *Urol Ann* 2017;9:393-6.

| Access this article online | |
|---|-----------------------------------|
| Quick Response Code: | Website: www.urologyannals.com |
|  | DOI: 10.4103/UA.UA_73_17 |

Scrotal ultrasound demonstrated a heterogeneous mass within the right testicular mediastinum with contiguous growth into the region of a heterogeneous epididymal mass [Figure 1]. Incidental, small bilateral hydroceles were also present. Serum tumor markers including alpha-fetoprotein and beta-human chorionic gonadotropin were within the normal range, and the serum lactate dehydrogenase was moderately elevated at 301 U/L. The patient's absolute CD4 count was 129 cell/mm³ with a calculated CD4 percentage of 8%.

Given the patient's history of HIV/AIDS, an infectious/inflammatory etiology was suspected. After consultation with infectious disease experts, the patient was initially treated with antibiotics and nonsteroidal anti-inflammatory drugs while on close surveillance. On follow-up scrotal ultrasound, the mass demonstrated an increase in size. The patient was presumed to have a testicular germ cell tumor and a radical orchiectomy was performed.

Gross examination demonstrated a 3.1 cm firm, white-tan, fibrous mass appearing to involve the epididymal head and adjacent testicular parenchyma. Microscopically, the mass showed a cellular spindle cell proliferation in

the background of chronic inflammation. The tumor predominantly involved the paratesticular tissues with extensive involvement of the epididymis. The rete testis and portions of the seminiferous tubules were also involved. No germ cell neoplasia *in situ* was identified. Tumor cells showed mild cytologic atypia, long cytoplasmic processes, and rare mitotic activity. No tumor necrosis or atypical mitotic figures were identified. Spindle cells were positive for smooth muscle actin (SMA) and negative for caldesmon, anaplastic lymphoma kinase (ALK1), and S-100 immunohistochemical staining. The overall histologic and immunohistochemical features were consistent with primary testicular IMT [Figure 2].

DISCUSSION

IMTs are benign tumors that have been classified under various names including inflammatory pseudotumor, fibrous pseudotumor, atypical myofibroblastic tumor, plasma cell pseudotumor, xanthomatous pseudotumor, atypical fibromyxoid tumor, pseudosarcoma, and plasma cell granuloma.^[1-3] It is classified as a tumor of intermediate biologic potential by the World Health Organization due to tendency of local recurrence and small risk of distant metastasis;^[4] they can occur at any age and involve multiple sites such as lung, skin, soft tissues, breast, gastrointestinal tract, pancreas, oral cavity, bone, central nervous system, retroperitoneum, and genitourinary tract. Very few cases have been reported involving the testicle or paratesticular structures. Balloch first described fibrous pseudotumor of paratestis in 1904.^[5] The majority of intrascrotal IMT arise from the tunica vaginalis. They are rarely associated with tunica albuginea, intratesticular tissues, epididymal, or spermatic cord structures.

The etiology of IMT is not well-defined, but it is most accepted as a reparative process in response to trauma, chronic irritation, or infection. Epstein-Barr virus, mycobacterium avium-intracellulare, human herpes virus 8 and some autoimmune causes have been associated with IMT; however, they have not been reported in paratesticular/testicular IMT as etiological agents. Rarely paratesticular IMT has been identified with testicular infarction, Schistosomiasis, retroperitoneal fibrosis, Gorlin syndrome, and HIV.^[5] Patients with paratesticular IMT usually present with a unilateral painless scrotal mass that is often indistinguishable from other scrotal masses, including testicular germ cell tumors. Other macroscopic mimickers of testicular and paratesticular neoplasms include hydrocele, varicocele, hernia, vascular lesions, inflammatory lesions, malakoplakia, sarcoidosis, meconium periorchitis, sperm granuloma, ectopic

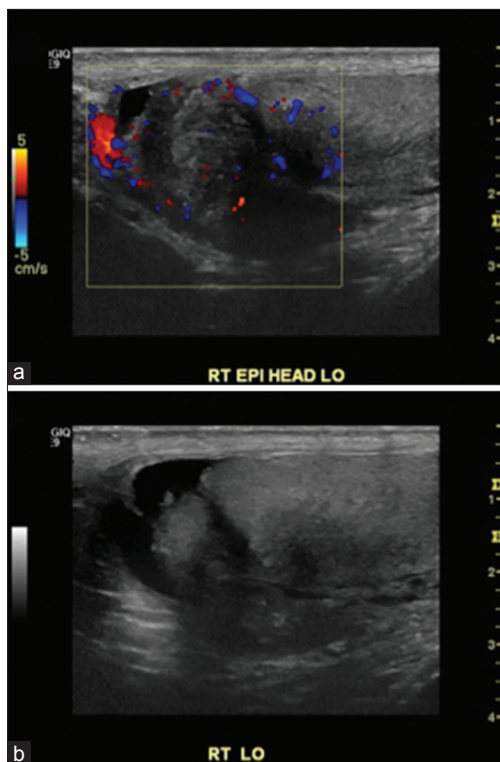


Figure 1: (a) Ultrasound image with color flow Doppler of enlarged mass in right epididymal head demonstrates increased vascularity with extension into adjacent testicular tissue. (b) B-mode ultrasound image of heterogeneous appearing mass within the right testicular mediastinum contiguous with heterogeneous appearing epididymal head mass

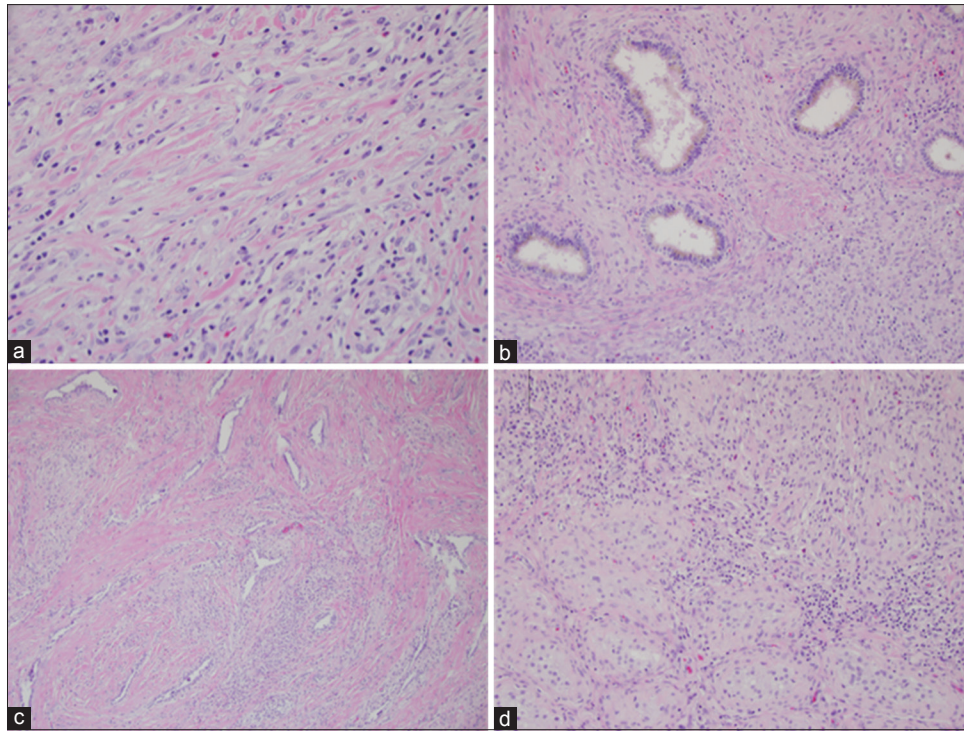


Figure 2: (a) H and E slide at high magnification showing infiltrating spindle cells in a background of inflammatory cells. Spindle cells show mild cytologic atypia and long eosinophilic cytoplasmic processes. (b) H and E slide at high magnification showing involvement of the epididymis by tumor cells. (c) H and E slide at low magnification showing involvement of the rete testis by tumor cells. (d) H and E slide at high magnification showing destruction of seminiferous tubules by infiltrating tumor cells

tissues, testicular appendages, amyloidosis, and sclerosing lipogranuloma.^[6]

Macroscopically, IMT is ovoid, firm, with gray-white or tan cut surface. Necrosis, hemorrhage, calcification, and cystic changes are unusual.^[7] Microscopically, various histologic patterns can be seen, predominantly characterized by myofibroblasts with spindle cell proliferation admixed with inflammatory infiltrate composed of plasma cells, lymphocytes, eosinophils, neutrophils, and loose collagenous stroma. Cellular atypia and mitotic activity are rare. Tumor cells generally show positivity for vimentin (95%–100%) and variable expression for desmin (5%–80%), SMA (48%–100%), ALK1 (50%), and pancytokeratin (10%–89%).^[1] Myogenin and S100 should be negative, which helps distinguish IMT from rhabdomyosarcoma and melanoma.^[3] Our case showed positivity for SMA and negative staining for S100, caldesmon, and ALK1.

Scrotal ultrasound helps in differentiating intratesticular masses which are usually malignant from extratesticular masses which are most commonly benign. Ultrasound also aids in identifying solid masses with internal vascularity, which is a feature associated with malignancy. However, ultrasound cannot reliably distinguish between IMT and a

testicular/paratesticular malignancy. IMT may present as hypoechoic or hyperechoic lesion depending on the degree of collagen or calcification depositions.^[8] Intra-operative frozen section assessment can help in preventing radical orchiectomy for benign testicular and paratesticular masses,^[9,10] but testis sparing may not be possible if the mass is very large or contiguous with paratesticular structures.

CONCLUSIONS

Although rare, IMT should be considered in the differential diagnosis in a solid testicular and paratesticular mass. Since it can mimic testicular malignancy both clinically and on pre-operative imaging, surgical excision is usually required for diagnosis.

Financial support and sponsorship

Nil.

Conflicts of interest

There are no conflicts of interest.

REFERENCES

1. Cheng L, Foster SR, MacLennan GT, Lopez-Beltran A, Zhang S, Montironi R, *et al.* Inflammatory myofibroblastic tumors of the genitourinary tract – Single entity or continuum? *J Urol* 2008;180:1235-40.

2. Chakrabarti N, Shetty R. Inflammatory myofibroblastic sarcoma of the spermatic cord. *Indian J Surg* 2010;72:152-4.
3. Tunuguntla H, Mishra A, Jorda M, Gosalbez R. Inflammatory myofibroblastic tumor of the epididymis: Case report and review of the literature. *Urology* 2011;78:183-5.
4. Gleason BC, Hornick JL. Inflammatory myofibroblastic tumours: Where are we now? *J Clin Pathol* 2008;61:428-37.
5. Singh J, Hafiz A, Rasool M, Singh H, Sharma S, Bashir S. Fibrous pseudotumor of paratestis mimicking a testicular tumor. *Open Pathol J* 2014;8:1-3.
6. Algaba F, Mikuz G, Boccon-Gibod L, Trias I, Arce Y, Montironi R, *et al.* Pseudoneoplastic lesions of the testis and paratesticular structures. *Virchows Arch* 2007;451:987-97.
7. Rafeek N, Joseph LD, Rajendiran S, Narayanan CD. Inflammatory myofibroblastic tumor of spermatic cord. *Int J Surg Case Rep* 2012;3:618-21.
8. Polsky EG, Ray C, Dubilier LD. Diffuse fibrous pseudotumor of the tunica vaginalis testis, epididymis and spermatic cord. *J Urol* 2004;171:1625-6.
9. Subik MK, Gordetsky J, Yao JL, di Sant'Agnese PA, Miyamoto H. Frozen section assessment in testicular and paratesticular lesions suspicious for malignancy: Its role in preventing unnecessary orchiectomy. *Hum Pathol* 2012;43:1514-9.
10. Gordetsky J, Findeis-Hosey J, Erturk E, Messing EM, Yao JL, Miyamoto H, *et al.* Role of frozen section analysis of testicular/paratesticular fibrous pseudotumours: A five-case experience. *Can Urol Assoc J* 2011;5:E47-51.