

Functional MR Imaging of the Porcine Kidney: Physiologic Changes of Prolonged Pneumoperitoneum

Elsbeth M. McDougall, MD, Harold F. Bennett, MD PhD, Terri G. Monk, MD, Cary L. Siegel, MD, Debiao Li, PhD
Elizabeth G. McFarland, MD, Ralph V. Clayman, MD, Terry Sharp, RT, Heidi J. Rayala, BSC,
Steven B. Miller, MD, E. Mark Haacke, PhD

ABSTRACT

Background: Increased intraabdominal pressure (IPA) during laparoscopy has been associated with decreased urine output. The purpose of this study was to use a non-invasive MRI technique to measure renal vessel flow velocity and change in differential renal medulla and cortex perfusion during pneumoperitoneum.

Study Design: Six female farm pigs underwent general endotracheal anesthesia and dynamic imaging following left ventricular (LV) injection of Gd-DTPA, utilizing a dual echo gradient echo sequence. MRI was repeated after three hours of continuous 15 mm Hg pneumoperitoneum in three *study* pigs and after three hours of monitored general anesthesia without pneumoperitoneum in three *control* pigs. Renal artery and renal vein flow velocities were calculated using cine phase-contrast technique. Renal perfusion was independently measured by LV injection of radiolabelled microspheres.

Results: There was a decrease in mean renal vein flow velocity in the pneumoperitoneum group as compared to the control group. During pneumoperitoneum there was a similar percentage reduction in the perfusion of the cortex (-28%) and medulla (-31%); this corresponded with a decreased urine output. In addition, radiolabelled microspheres corroborated the similar decrease in both cortical and medullary perfusion rates during pneumoperitoneum.

Conclusions: Prolonged IAP is associated with a decrease in renal vein flow velocity and urine output. There is a similar decrease in the renal medulla and cortex perfusion rates during pneumoperitoneum of 15 mm Hg.

Key Words: Laparoscopy, Magnetic resonance imaging, Pneumoperitoneum.

INTRODUCTION

Recent investigations have demonstrated that increased intra-abdominal pressure (IAP) during laparoscopic surgery, due to CO₂ insufflation, is associated with oliguria and anuria.¹ Using a porcine model, we have previously shown there to be a direct relationship between the decreased urine output and decreased renal vein flow during increased intra-abdominal pressures.² While these effects appear to have no long term consequences, a better understanding of this renal physiology is important as the frequency and complexity of laparoscopic surgery increases. Some researchers have suggested that the decreased urine output is associated with reduced cortical blood flow and shunting of blood to the renal medulla.³ Other investigators have shown that direct compression of the kidney will result in a similar decrease in urine output.⁴

To date, the physiologic assessment of kidney function during a CO₂ pneumoperitoneum has included invasive monitoring with arterial and venous catheters, laser Doppler needle probes placed in the renal cortex and mechanical compression of the kidney following surgical exposure of the kidneys.²⁻⁴ All of these techniques may, in and of themselves, alter renal physiology and thereby obscure the actual effect of the pneumoperitoneum alone. Noninvasive evaluation of renal perfusion with Magnetic Resonance Imaging (MRI) has recently become feasible with the development of rapid data acquisition techniques.^{5,6}

The purpose of this study was to evaluate noninvasively the differential perfusion of the renal cortex and renal medulla, and renal artery and renal vein flow velocity during prolonged pneumoperitoneum in a porcine model, using MRI.

METHODS AND MATERIALS

Six adult female farm pigs (weighing 70-90 lbs) underwent a standardized general endotracheal anesthetic. Cystoscopically, a guidewire was placed into the bladder and a Foley catheter was positioned over the guidewire to provide continuous bladder drainage and urine output evaluation during the study. Urine was collected at 30-minute intervals during the study. A pulmonary artery catheter was placed via the internal jugular vein using a cut-down tech-

nique, to allow for monitoring of cardiac filling pressures and cardiac output during the study. A left ventricular pig-tail catheter was placed, via a carotid artery cut-down technique, to allow bolus injection of radioactive microspheres and Gadolinium. A femoral artery line was placed using a cut-down technique to allow blood gas monitoring throughout the experiment and to allow blood withdrawal during microsphere injections. Intravenous fluid was administered at 100 cc/hr with additional fluid bolus dosing applied to maintain the central venous pressure at 10-12 mm Hg.

All of the animals underwent two MRI sessions in a 1.5 Tesla whole body imaging magnet (Vision, Siemens Medical Systems, Iselin, NJ). The initial scan established a baseline renal vein and artery blood flow velocity, and renal parenchymal perfusion. For perfusion evaluation, immediately prior to, and following, a bolus injection of the contrast agent Gd-DTPA (0.05 mmol/kg) (Omniscan, gadodiamide, Nycomed Inc., New York, NY), a series of 64 images at the same slice position was obtained using a double echo fast gradient echo technique during the first pass of the agent through the kidney. Regions of interest (ROI) were selected in both the cortex and the medulla of the kidneys and the MR signal intensity versus time was plotted. Application of the dual echo sequence allowed detection of signal enhancement due to T1 effects alone, which are directly proportional to Gd-DTPA concentration present in the tissues.⁶ The perfusion index, time to reach peak signal, was calculated to evaluate the difference in cortical and medullary perfusion. Absolute values of the renal artery and renal vein flow velocity were obtained using a cardiac-gated cine phase-contrast flow quantitation sequence.

After the baseline MRI scan the six pigs were divided into two groups. In the *control* group (n=3), a 12 mm port was placed in the left upper quadrant, but no intra-abdominal insufflation was performed; each pig was monitored during three hours of general anesthesia. In the *study* group (n=3), a 12 mm port was placed in the left upper quadrant and a 15 mm Hg CO₂ pneumoperitoneum was established and maintained for three hours. After three hours of pneumoperitoneum in the study group, or following three hours of general anesthesia in the control group, all six pigs underwent a repeat MRI scan. The same imaging sequences were used to evaluate and measure differential renal parenchymal perfusion, and renal artery and renal vein flow velocity following repeat injection of Gd-DTPA (0.05 mmol/kg). During the evaluation period in both groups, measurements were performed at 30-minute intervals, including: pulse rate, blood pressure, end-tidal CO₂, cardiac output, urine volume, arterial blood gases and serum electrolytes. Urine samples were collected from all animals during the initial and second MRI studies and the measurement of urine osmolality was performed.

As an independent method of measuring renal perfusion, radiolabelled microspheres were used to compare with the initial and subsequent MRI scans. One hundred µCi (3.7 Bmq) of 15 µm diameter radiolabelled Scandium 46 microspheres in one ml of saline were thoroughly mixed with an additional one ml of saline, and injected into the left ventricle near the time of the Gadolinium injection for the baseline MRI study. Using the same technique, Strontium 85 radiolabelled microspheres were injected near the time of the second Gadolinium injection and MR imaging. Using an indwelling femoral artery line and an automatic calibrated withdrawal pump, blood was withdrawn at a constant rate of 10 ml/min during and following each injection, beginning about five seconds before injection and continuing for two minutes.

The contralateral kidney served as an internal control for the time to peak concentration of Gadolinium using MR imaging measurements, and for the independent radiolabelled microsphere perfusion measurements. The change in time to peak Gadolinium measurements and the change in microsphere perfusion measurements were similar for both kidneys (within ±10%) in the cortex and medulla, supporting the reliability of these measurements.

At the completion of the entire study 50 cc of intravenous potassium chloride was used to euthanize each animal and both kidneys were harvested. Five biopsy samples, 0.5 to 1 cm, were taken from the inner cortex, the outer cortex, and the medulla of each kidney; each sample was weighed and counted in a NaI (TI) well scintillation detector. Values of cortical and medullary perfusion in units of ml/g/min, at baseline and during the study period, were determined from the separately recorded Scandium 46 and Strontium 85 count rates.⁶

The Mann-Whitney, unpaired nonparametric statistical analysis was used in the comparison of renal vessel flow velocities and renal cortex and renal medulla perfusion and time to peak concentration of Gadolinium. Statistical analysis of the comparison of the urine osmolality in the two study groups was performed with the Wilcoxon signed rank test. Differences were considered statistically significant if the p value was <0.05.

RESULTS

Due to the small number of animals in the two study groups significant statistical analysis could not be determined; however, trends were apparent on comparison of the various data. The changes noted in urine output in the pneumoperitoneum and control animals were similar to those seen in our previous evaluation of the effect of pneumoperitoneum on renal function in the porcine model.² During the first two hours of pneumoperitoneum, there

was a decrease in urine output in the pneumoperitoneum animals compared to the control group.

The cardiac output decreased in the pneumoperitoneum group on average by 32% (range 17-49% decrease) (Table 1). In the control group, the cardiac output increased an average of 92% (range 24-160% increase). Due to the wide range in standard deviation there was no statistical difference in the decrease in cardiac output between the pneumoperitoneum and control groups.

In the control group of animals the mean renal artery flow velocity decreased by an average of 7% from baseline (Figure 1). In the pneumoperitoneum group the mean renal artery flow velocity decreased by an average of 20%. There was no significant difference in the change of renal artery flow velocity comparing the control and pneumoperitoneum groups. The mean renal vein flow velocity increased by an average of 6% from baseline in the control group. However, the mean renal vein flow velocity decreased on average by 28% from baseline in the pneumoperitoneum group. Despite the small study group size, the reduction in renal vein flow velocity in the pneumoperitoneum group compared to the control group approached, but did not achieve, statistical significance ($p=0.07$) (Figure 1).

The time to peak signal intensity after Gd-DTPA administration in the control group was essentially unchanged, comparing the baseline and the three-hour MRI scans (Table 2). The time to peak concentration of the Gd-DTPA in the pneumoperitoneum group was increased by an average of 99% in the renal cortex and by an average of 79% in the renal medulla, correlating with decreased renal perfusion. In all animals the time to peak enhancement was shorter for the cortex as compared to the medulla, consistent with the known greater blood flow of the cortex.⁷ These results were also corroborated by the microsphere evaluation. The longer time to peak concentration of Gd-DTPA in the pneumoperitoneum group as compared to the control group for both the cortex and the medulla also approached, but did not reach, statistical significance (Figure 2). The increased time to peak concentration of the Gadolinium in the pneumoperitoneum animals was essentially the same for the cortex and medulla.

In the control animals the evaluation of renal perfusion, utilizing radiolabelled microspheres, demonstrated an average 29% increase in the renal cortex perfusion and an average 32% increase in the renal medulla perfusion when compared to baseline values. In the pneumoperitoneum animals the microsphere perfusion evaluation demonstrated an average 28% decrease in renal cortical perfusion and an average 31% decrease in renal medullary perfusion (Table 2). Again, there was a similar decrease in cortical and

Table 1.
Effect of Pneumoperitoneum on Cardiac Output
(Mean \pm Standard Deviation)

	Baseline (ml/min)	3 Hours of Treatment	% Change at 3 Hours from Baseline
Control Cardiac Output (ml/min)	4.2 \pm 0.1	8.0 \pm 3.9	+92%
Pneumoperitoneum Cardiac Output (ml/min)	6.3 \pm 1.8	4.5 \pm 2.2	-32%

medullary perfusion in the pneumoperitoneum group. There was also a similar increase in cortical and medullary perfusion in the control group. The absolute renal perfusion was greater in the cortex than in the medulla in all animals. These data corroborate the MRI findings of decreased perfusion to both the cortex and the medulla for the pneumoperitoneum group as compared to the control group. For both groups there was a highly similar change in perfusion comparing the left and the right kidney, for the cortex and the medulla (less than 10% difference in percentage change of the individual renal perfusion values).

In the control group the urine osmolality increased from a mean of 661 mOsm/kg to 840 mOsm/kg during the three hours of anesthesia. In the pneumoperitoneum group the

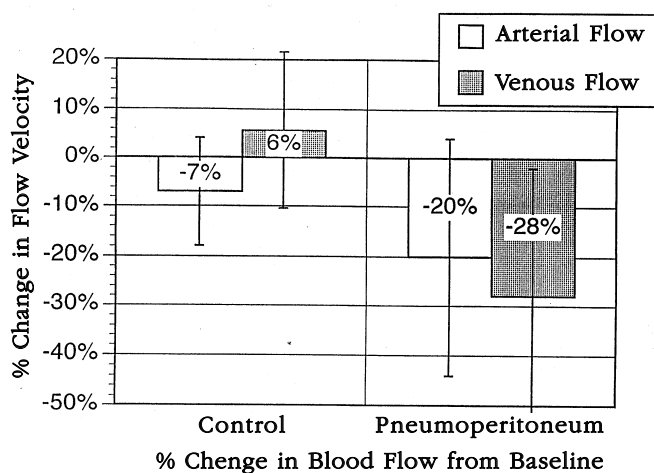


Figure 1. The percent change in blood flow velocity from baseline, in the renal artery and renal vein, in the control and pneumoperitoneum study groups demonstrates the trend to decreased renal vein flow velocity during pneumoperitoneum; this approached but did not achieve statistical significance.

Table 2.

Comparison of Time to Peak Concentration of Gadolinium and Microsphere Perfusion in the Renal Cortex and Medulla

	Control Renal Cortex	Control Renal Medulla	Pneumoperitoneum Renal Cortex	Pneumoperitoneum Renal Medulla
Number of Animals	3	3	3	3
Mean Time to Peak Gadolinium Concentration at Baseline	6.0±0.04 sec	7.7±2.6 sec	5.5±0.6 sec	9.4±3.1 sec
Mean Time to Peak Gadolinium Concentration After 3 Hours of Treatment	5.9±0.44 sec	7.6±0.9 sec	11.0±5.5 sec	16.8±2.9 sec
Mean Baseline Microsphere Perfusion (ml/gm/min)	3.28±0.37	1.80±0.57	2.39±0.49	1.46±0.50
Mean Microsphere Perfusion After 3 Hours of Treatment (ml/gm/min)	4.24±1.70	2.38±1.19	1.73±0.50	1.01±0.41

urine osmolality decreased from a baseline mean of 665 to 544 mOsm/kg during the three hours of 15 mm Hg pneumoperitoneum. Comparison of the urine osmolality in the two groups showed a decrease in urine osmolality during the period of pneumoperitoneum, although this difference was not statistically significant ($p=0.50$) (**Figure 3**).

DISCUSSION

Early clinical experience with laparoscopic nephrectomy demonstrated that prolonged periods of increased intra-abdominal pressure of greater than two hours were associated with decreased urine output. Previous animal studies confirmed a direct correlation between a reduction in renal vein flow and urine output during prolonged periods of pneumoperitoneum.² Other investigators have suggested that compression of the renal parenchyma may result in an alteration of the renal cortical and medullary blood flow and subsequently reduce the urine output.⁹ Some investigators have suggested a shunting of blood flow from the cortex to the medulla to explain the alteration in urine production.^{3,9} However, all previous studies have employed invasive monitoring techniques to evaluate the renal vein and parenchymal blood flow during pneumoperitoneum. These techniques may impact on the renal perfusion independent of the increased intra-abdominal pressure.

Magnetic resonance imaging using phase-contrast techniques has the capability to quantify blood flow velocity in the main renal arteries and veins.^{10,11} The MRI results demonstrating a decrease in renal vein flow velocity with pneumoperitoneum were consistent with the renal vein flow results from our previous study using a renal vein flow catheter.²

A functional approach to renal perfusion using dynamic Gd-DOTA enhanced turboflash MRI compares well with renal scintigraphy.¹² Our experience with MRI to evaluate renal perfusion in the porcine model demonstrated a brief learning period to applying parenchymal evaluations to calculate accurately the perfusion rates. Furthermore, on comparison to radiolabelled microsphere measurement of renal perfusion, the gold standard, the MRI measurements were consistently in agreement with the microsphere calculations. In addition, concerns about the difficulty of identifying the ROI in small blood vessels on MR imaging were largely unfounded as our study findings on renal artery and renal vein flow velocity were similar to those previously reported during 15 to 20 mm Hg pneumoperitoneum.^{2, 4}

This study demonstrated that during a prolonged CO₂ pneumoperitoneum of 15 mm Hg, there was a decrease in renal vein flow velocity and a decrease in renal parenchymal perfusion. There was a similar reduction in the renal cortical perfusion and the renal medullary perfusion during 15 mm Hg pneumoperitoneum. There was no difference in the change of perfusion between the renal cortex and renal medulla during the period of increased intra-abdominal pressure.

Oliguric renal failure has been associated with increased intra-abdominal pressure secondary to ascites, tumor, trauma, and retroperitoneal bleeding.^{9,13} Renal failure can result from reduced renal perfusion; an ischemic, toxic, or obstructive insult to the renal tubule; inflammation or edema within the tubulointerstitium; or a reduction in the filtering capacity of the glomerulus.¹⁴ Intact renal tubular and glomerular function associated with a limited clearance secondary to reduced renal perfusion is defined as prerenal

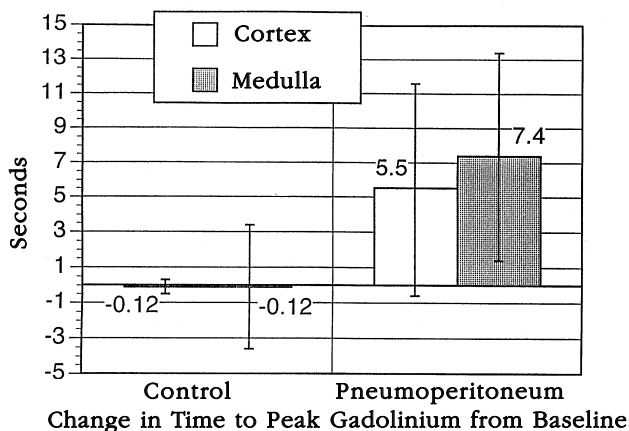


Figure 2. The change in time to peak concentration of gadolinium from baseline, in the renal cortex and medulla, in the control and pneumoperitoneum study groups demonstrates that the time to peak gadolinium concentration was increased in the pneumoperitoneum study group. The change in gadolinium concentration time was similar in the renal cortex and medulla for both study groups.

failure or azotemia. Prerenal azotemia is common in surgical patients and is usually reversible if the underlying cause of the hypoperfusion is corrected. All anesthetic agents and techniques tend to decrease GFR and intraoperative urine flow.¹⁵ Some drugs reduce renal blood flow and GFR secondary to their effects on the central circulation as a result of myocardial depression and peripheral pooling.^{16,17} Preoperative hydration can modify the effects of many anesthetic agents.

Razvi and colleagues created unilateral, 15 mm Hg compression in a dog model and showed that the effective renal blood flow decreased 26% and was associated with a 63% decrease in mean urine output from the treated kidney.⁴ These results are similar to the effects that we have noted with MRI and radiolabelled microsphere evaluation of the renal perfusion and the urine output during 15 mm Hg pneumoperitoneum. We similarly noted an approximately 30% reduction in renal parenchymal perfusion during 15 mm Hg pneumoperitoneum.

Interestingly, in Razvi's animal model the effective renal blood flow did not return to baseline following decompression, although the urine output increased 109%. In this study, cardiac output, flow in the renal vessels, and renal parenchymal perfusion were correspondingly decreased during increased IAP. Data is not available to comment on the recovery time. However, from our previous work we similarly noted an increase in urine output and a return of renal vein flow, albeit slower, toward baseline following two hours of release of pneumoperitoneum.² Reduced car-

diac output and a concomitant reduction in renal vessel flow may result in decreased renal plasma flow and glomerular filtration rate. However, these effects would suggest a shunting of blood away from the cortex and functioning glomeruli to the medulla.⁹ Harmon and colleagues demonstrated that correcting the reduction in cardiac output, during 20 mm Hg intra-abdominal pressure, by administration of a plasma expander, did not correct the observed renal dysfunction.¹⁸ In our previous animal study, we demonstrated that the administration of dopamine at 2 mcg/kg/min during pneumoperitoneum did not change the reduction in urine output.² Compression of the renal parenchyma may result in diffuse small vessel obstruction, independent of the main renal vessel flow. This would also correspond to a generalized and similar reduction of blood flow in both the medulla and the cortex. Our results, in conjunction with the report by Razvi and colleagues, supports a directly mechanical compressive effect on the renal parenchyma as the primary cause of the decreased urine output and concentrating ability of the kidney during pneumoperitoneum.

The loss of the urine concentrating capacity of the kidney is one of the most sensitive indicators of intrinsic renal damage during renal hypoperfusion. A reduction in urine osmolality, which may reflect injury to the renal medulla or the regulatory response of the kidney to decreased medullary perfusion, usually indicates prerenal azotemia. In our study, the decreased cortical and medullary perfusion state of 15 mm Hg pneumoperitoneum was associated with a reduction in urine osmolality suggesting a direct effect on the concentrating ability of the renal tubules. This may be secondary to the directly compressive effect on all tubules in the kidney, an associated sympathetic

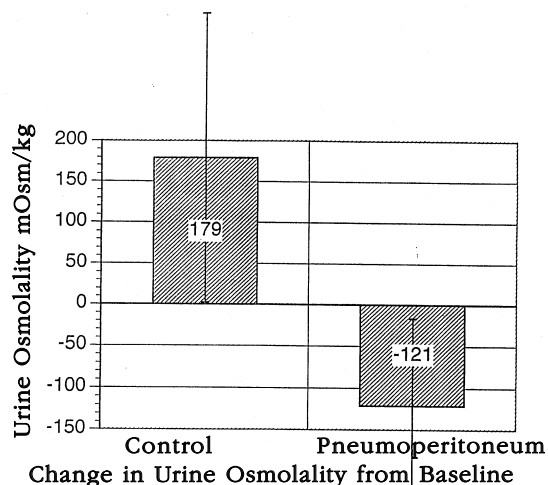


Figure 3. The comparison of the change in urine osmolality from baseline in the control and pneumoperitoneum study groups demonstrates a decrease in the concentrating ability of the pneumoperitoneum group. This was not statistically significant.

tone of the afferent arterioles, or due to hormonal changes (e.g., ADH, renin) and not directly related to the reduced renal vein flow. Further work would be needed to study each of these areas.

This study demonstrated the usefulness of MR imaging to assess renal and parenchymal blood flow to the kidney. The reliability of the renal perfusion measurements by MRI and by radiolabelled microspheres is supported by using the contralateral kidney as a comparative internal control. One of the limitations of the initial application of this technique included a brief learning curve, during the first one or two animals, to accommodate for the small vessel size and accurate identification of the ROI for determination of vessel flow velocity and parenchymal perfusion. The smaller size and greater pulsatility of the renal artery makes measurement of flow velocity more difficult than the same measurement in the renal vein.¹⁹ The small numbers in our sample made statistical analysis for significance difficult. However, definite trends were apparent in urine output, cardiac output, renal vessel flow velocity and parenchymal perfusion, which were in agreement with established techniques for evaluating these parameters. It is important to recognize that these animal studies have been performed on essentially normal functioning kidneys. The effect of the same perfusion reduction in the presence of pre-existing renal dysfunction is as yet unanswered. As such, many investigators have suggested that the effect of prolonged pneumoperitoneum on renal function may be more significant at higher pressures or in patients with underlying renal function compromise.^{2,4} Further laboratory and clinical studies will be necessary to answer these concerns more completely.

CONCLUSION

Magnetic resonance imaging provides a noninvasive evaluation of renal vessel flow and parenchymal perfusion during prolonged pneumoperitoneum. Increased intra-abdominal pressure results in reduced cardiac output, lower flow velocity in the renal vessels, decreased renal parenchymal perfusion and a concomitant reduction in urine output. The changes seen in renal perfusion are similar in the cortex and medulla; no shunting phenomenon could be demonstrated. The decreased renal perfusion during prolonged pneumoperitoneum in the normal kidney may result in a temporary loss of renal concentrating ability and decreased urine osmolality. Further laboratory and clinical evaluation will be necessary to assess the effect of prolonged pneumoperitoneum on the kidney with compromised renal function.

References:

1. Kerbl K, Clayman RV, McDougall EM, Kavoussi LR. Laparoscopic nephrectomy: the Washington University experience. *Br J Urol*. 1994;73:231-236.
2. McDougall EM, Monk TG, Wolf JS Jr, Hicks M, Clayman RV, Gardner S, Humphrey PA, Sharp T, Martin K. The effect of prolonged pneumoperitoneum on renal function in an animal model. *J Am Coll Surg*. 1996;182:317-328.
3. Chiu AU, Azadzi KM, Hatzichristou DG, Siroky MB, Krane RJ, Babayan RK. Effects of intra-abdominal pressure on renal tissue perfusion during laparoscopy. *J Endourol*. 1994;8:99-103.
4. Razi HA, Fields D, Vargas JC, Vaughan ED, Vukasin A, Sosa RE. Oliguria during laparoscopic surgery: evidence for direct renal parenchymal compression as an etiologic factor. *J Endourol*. 1996;10:1-4.
5. Frank JA, Choyke PL, Austin HA, Girton ME. Functional MR of the kidney. *Magn Reson Med*. 1991;22:319-323.
6. Li D, Wang Y, Borrello J, Bennett HF, Haacke EM, Martin D, Miller S, Kaushikkar S. Kidney perfusion imaging using a double-echo gradient-echo sequence. Society of Magnetic Resonance. Third Scientific Meeting. August 1995.
7. Brezis M, Rozen S. Hypoxia of the renal medulla - its implications for disease. *NEJM*. 1995;332:647-655.
8. Chiu AW, Chang LS, Birkett DH, Babayan RK. The impact of pneumoperitoneum, pneumoretroperitoneum and gasless laparoscopy on the systemic and renal hemodynamics. *J Am Coll Surg*. 1995;181:397-406.
9. Richards WO, Scovill W, Shin B, Reed W. Acute renal failure associated with increased intra-abdominal pressure. *Ann Surg*. 1983;197:183-187.
10. Lorenz CH, Powers TA, Partain CL. Quantitative imaging of renal blood flow and function. *Invest Radiol*. 1992;27:S109-114.
11. Sommer G, Noorbehesht B, Pelc N, Jamison R, Pinevich AJ, Newton L, Myers B. Normal renal blood flow measurement using phase-contrast cine magnetic resonance imaging. *Invest Radiol*. 1992;27:465-470.
12. Laissy JP, Faraggi M, Lebtahi R, Soyer P, Brillet G, Mery JP, Menu Y, Le Guludec D. Functional evaluation of normal and ischemic kidney by means of Gadolinium-DOTA enhanced turboflash imaging: a preliminary comparison with ^{99m}Tc-MAG3 dynamic scintigraphy. *Mag Res Imaging*. 1994;12:413-419.
13. Jacques T, Lee R. Improvement of renal function after relief of raised intra-abdominal pressure due to traumatic retroperitoneal hematoma. *Anest Intensive Care*. 1988;16:478-494.
14. Thadhani R, Pascual M, Bonventre JV. Acute renal failure. *NEJM*. 1996;334:1448-460.
15. Sladen RN. Renal physiology. In Miller RD., Anesthesia. New York: Churchill Livingstone Inc. 1994:663-688.
16. Gelman S, Fowler KC, Smith LR. Regional blood flow during isoflurane and halothane anesthesia. *Anesth Analg*. 1984;63:557-565.

17. Tranquilli WJ, Manohar M, Parks CM, Thurmon JC, Theodorakis MC, Benson GJ. Systemic and regional blood flow distribution in the unanesthetized swine and swine anesthetized with halothane and nitrous oxide, halothane or enflurane. *Anesthesiology*. 1982;56:368-379.
18. Harmon PK, Kron IL, McLachlan HD, Freelender AE, Nolan SP. Elevated intra-abdominal pressure and renal function. [*Ann Surg*](#). 1982; 196:594-7.
19. Sommer G, Noorbehesht B, Pelc N. Normal renal blood flow measurement using phase-contrast cine magnetic resonance imaging. [*Invest Radiol*](#). 1992;27:465-70.