

# Lumbar Intervertebral Discal Cyst: A Rare Cause of Low Back Pain and Radiculopathy. Case Report and Review of the Current Evidences on Diagnosis and Management

Francesco Certo<sup>1</sup> Massimiliano Visocchi<sup>2</sup> Alessandro Borderi<sup>1</sup> Claudia Pennisi<sup>1</sup> Vincenzo Albanese<sup>1</sup>  
Giuseppe M. V. Barbagallo<sup>1</sup>

<sup>1</sup>Division of Neurosurgery, Department of Neurosciences, Policlinico “G. Rodolico” University Hospital, Catania, Italy

<sup>2</sup>Department of Neurosurgery, Catholic University, Rome, Italy

Address for correspondence Giuseppe M. V. Barbagallo, MD, Viale XX Settembre 45, 95129 Catania, Italy (e-mail: giuseppebarbagal@hotmail.com).

Evid Based Spine Care J 2014;5:141–148.

## Abstract

**Study Design** Case Report and review of the literature.

**Objective** The objective of the article is to report an illustrative case successfully treated by microsurgery and to review the literature on the current evidence on diagnosis and management of lumbar discal cysts.

**Methods** A 43-year-old male patient presented with severe back pain, radiating down to the right leg, as well as with paraesthesias in the right L3 and L4 dermatomes. Magnetic resonance imaging of the lumbar spine revealed an intraspinal, extradural space-occupying lesion at the L3–L4 disc level, causing compression of the neural structures. The lesion was surgically removed and a diagnosis of lumbar discal cyst was made. Postoperatively, symptoms improved and the patient was discharged with no complications. A systematic review of pertinent articles published up to February 2014 was performed. Key articles were searched to identify studies describing the diagnosis and management modalities of lumbar discal cysts and the comparative effectiveness and safety of microsurgery versus endoscopic treatment.

**Conclusions** Discal cysts are rare causes of low back pain and radiculopathy. Few cases have been reported; however, conclusive information about their natural history is not available and the best mode of treatment remains controversial. We submit that lumbar intervertebral disc cysts, with their peculiar radiological and anatomic features, should be considered in the differential diagnosis among rare causes of low back pain and radiculopathy.

## Keywords

- ▶ discal cyst
- ▶ discography
- ▶ intervertebral disc
- ▶ intraspinal cyst
- ▶ lumbar spine

## Introduction

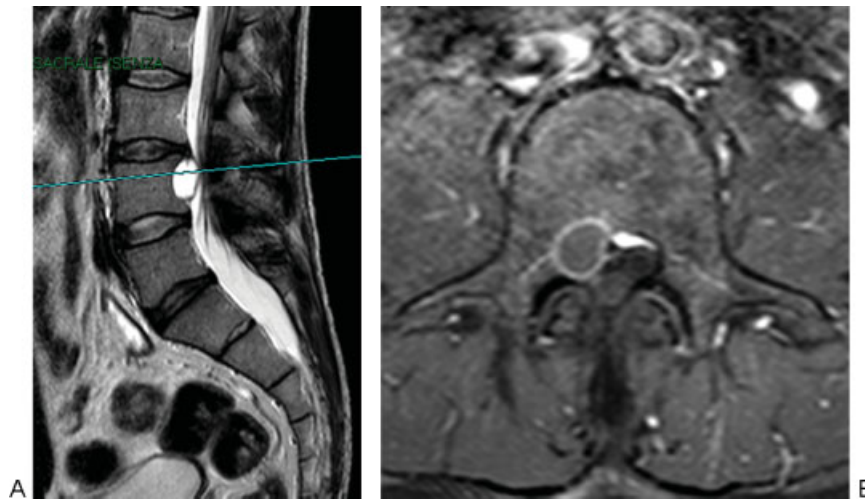
Discal cysts are defined as intraspinal, extradural cysts with a distinct communication with the corresponding intervertebral disc.<sup>1,2</sup> Unlike intracanal cystic masses, such as synovial cysts,<sup>3</sup> that arise from the ligamentum flavum<sup>4</sup> or from the posterior

longitudinal ligament<sup>5</sup> and may involve any spinal segment, discal cysts have only been reported in the lumbar spine. These lesions, which are extremely rare among spinal pathologies and usually occur in the third or fourth decade of life, are more prevalent in male patients with a higher occurrence reported in Asian populations. Nevertheless, reliable evidence about

received  
March 24, 2014  
accepted  
July 2, 2014

© 2014 Georg Thieme Verlag KG  
Stuttgart · New York

DOI <http://dx.doi.org/10.1055/s-0034-1387806>.  
ISSN 1663-7976.



**Fig. 1** Sagittal T2-weighted (A) and axial T1-weighted postgadolinium enhancement (B) MRI of the lumbar spine demonstrates a spherical intraspinal, extradural cystic lesion originating from the L3–L4 disc and extending either laterally to the right side or caudally behind L4 vertebral body. Noticeable is the ring enhancement around the cyst. MRI, magnetic resonance imaging.

epidemiology and natural history of this pathological entity is not available, further accentuated by the lack of large series with longer term follow-up. Indeed, the definition of these lesions was a relatively recent one, with its formal description provided by Chiba et al in 2001.<sup>1</sup>

A review of the literature revealed 37 previously published articles on lumbar discal cysts; all reported cases demonstrate that the clinical picture determined by discal cysts is indistinguishable from other causes of low back pain and radiculopathy such as conventional disc herniations. Although early reports had recommended discography for presurgical diagnosis of discal cysts, advances in imaging techniques, particularly in magnetic resonance imaging (MRI), made the diagnosis easier and noninvasive.<sup>6</sup> Moreover, a more accurate knowledge of their origin and pathoanatomical features has more recently become available.<sup>7,8</sup> Although nearly all reported discal cysts treated by surgery are associated with a successful outcome, their rarity makes it impossible to draw clear conclusions about its natural course history and allow for meaningful recommendations regarding the clinical management. In this article, we provide a brief literature review regarding the management of lumbar discal cysts and describe a new case.

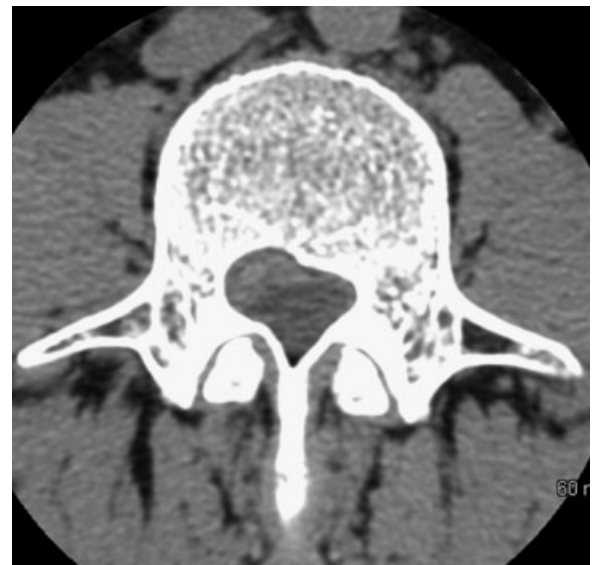
## Case Description

A 43-year-old man presented with a 3-month history of severe back pain, radiating down to his right leg, with associated paraesthesias in the ipsilateral L3 and L4 dermatomes. Neurological examination revealed a slight weakness (4 + /5 BMRC – British Medical Research Council) in thigh flexion as well as in the leg extension on the right side and hypomyotrophy of the right quadriceps femoris muscle. The right knee jerk was absent. The patient's examination was otherwise unremarkable. Lumbar spine X-rays showed no deformities or overt degenerative changes. Lumbar MRI revealed a spherical, intraspinal, extradural

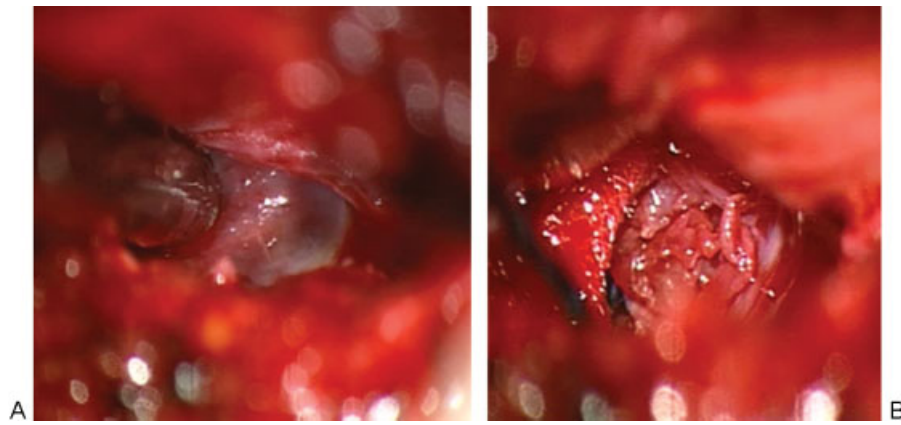
cystic mass adjacent to the right dorsolateral side of the L3–L4 disc and extending into the ipsilateral recess. The cyst appeared hypointense on T1-weighted images and hyperintense on T2-weighted ones. After gadolinium infusion, the cyst wall was homogeneously enhanced. The L3–L4 disc showed clear signs of degeneration (► **Fig. 1**).

On computed tomography (CT), the lesion appeared as a hypodense, slightly hyperdense, round mass sited in the right lateral recess, which appeared enlarged, causing scalloping of the posterior vertebral body's surface (► **Fig. 2**).

In surgery, we performed a partial, right-sided L3 and L4 laminectomy and medial facetectomy under microscopic magnification. After incising the ligamentum flavum, a thin-walled cystic lesion, containing gelatinous material,



**Fig. 2** CT scan reveals the bone erosion and the enlargement of L4 lateral recess. CT, computed tomography.

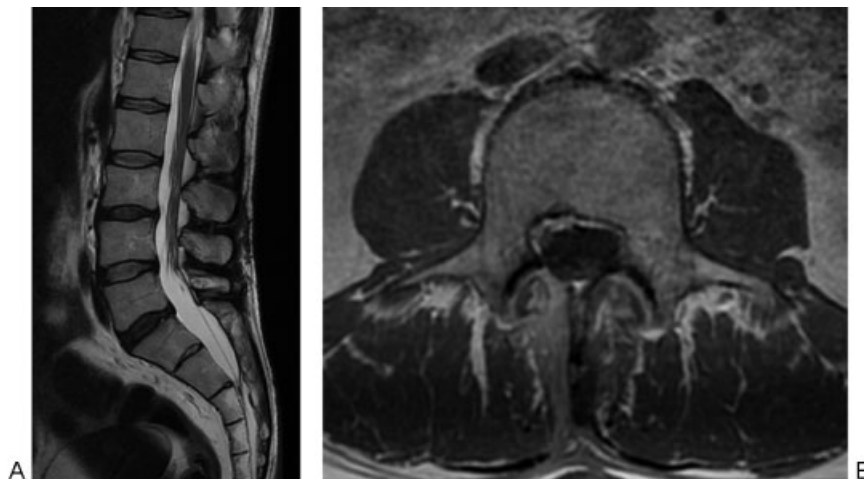

**Fig. 3** The cyst is exposed under microscope light (A). The fissured annulus fibrosus is visible after resection (B).

was observed on the right ventrolateral surface of the dural sac (►Fig. 3A). During dissection maneuvers, the cyst was fenestrated and a citrine gel-like material emerged. The cyst was completely removed by sectioning its connection with the annulus fibrosus. A connection between the cyst and the L3–L4 intervertebral disc, through a round defect in the annulus fibrosus, was identified. Although there was no evidence of disc herniation, a formal microdiscectomy was also performed to prevent the recurrence of the cyst and/or the extrusion of disc fragment from the opened annulus fibrosus (►Fig. 3B). Histopathological examination of the cyst revealed dense fibrous connective tissue, with hemosiderin deposits, without lining cell layers and disc material. No perioperative complications were observed, and the patient was discharged with complete relief of complaints. A 6-month follow-up MRI scan showed the complete resection of the cyst, a good height of the degenerated disc, and a satisfactory decompression of nervous structures (►Fig. 4). At the 2-year follow-up, the patient remains asymptomatic.

### Discussion

In the second half of the 1990s, some cases of cysts within the spinal canal that communicated with the intervertebral disc were reported in the Japanese literature.<sup>9–11</sup> These lesions were defined as cystic hematomas or premembranous hematoma. In 1997, Toyama et al first highlighted the communication between such cystic lesions and the intervertebral disc.<sup>12</sup> Similarly, in 1999, Kono et al<sup>13</sup> described the intraspinal extradural cysts as well-defined, homogeneous lesions located within the ventrolateral extradural space at a lumbar disc level, displacing the dural sac dorsomedially and typically communicating with the corresponding intervertebral disc. Two years later, Chiba et al<sup>1</sup> proposed that disc cysts should encounter the following characteristics: (1) clinical symptoms related to a unilateral single nerve root compression; (2) lesions occurring at a slightly younger age and at a higher intervertebral disc level than typical disc herniation; (3) minimal degeneration of the involved disc on imaging studies; (4) communication between the cyst and the corresponding intervertebral disc;



**Fig. 4** Six-month follow-up sagittal T2-weighted (A) and axial T1-weighted postgadolinium enhancement (B) MRI of the lumbar spine demonstrating the complete resection of the cyst and the absence of recurrence. MRI, magnetic resonance imaging.

(5) intralesional, bloody-to-clear serous fluid content; and (6) absence of either disc material inside the cyst or of a specific lining cell layer on histological examination.

Despite the possibility of CT scans showing indirect signs of long-standing disc cysts, such as bony scalloping in the vertebral body or the lateral recess, imaging of discal cysts is preferably based on MRI. Lee et al<sup>6</sup> described the MRI features of discal cysts: a ventrolateral, extradural cystic mass attached to a lumbar intervertebral disc as well as rim enhancement of its wall on contrast-enhanced MRI and occasional spread of the mass into the lateral recess. Such features were observed in the case we report, where further invasive radiological imaging was not deemed appropriate.

Discography and/or CT discography has shown contrast flow into the cyst through a typical connecting channel, bridging the cyst and the corresponding intervertebral disc. This finding is diagnostic for discal cysts and has not been demonstrated in lumbar disc herniations or other spinal cysts.<sup>6,7,12,14,15</sup> However, MRI has replaced discography as the primary diagnostic tool; it is noninvasive and very sensitive in demonstrating the relationships between discal cysts and the surrounding structures.<sup>6</sup> Clinical symptoms of patients harboring lumbar discal cysts are indistinguishable from those patients with typical intervertebral disc herniation or other spinal cysts. Histologically, the main difference between discal cysts and other intraspinal cysts, such as synovial cysts of the facet joints or cysts of the ligamentum flavum, is based on the absence of lining cells in the discal cyst's wall.<sup>2,15</sup>

The etiology and pathogenesis of discal cysts remain unclear. Currently, two hypotheses have been suggested. Toyama et al<sup>12</sup> and Chiba et al<sup>1</sup> proposed that an epidural hematoma is initially formed by hemorrhage from the epidural venous plexus, resulting from an underlying disc injury. The discal cyst then develops out of incomplete hematoma resorption. This theory was supported by the reports that most of the cysts studied contained hemosiderin deposits. However, this hypothesis cannot explain the linking stalk between the intervertebral disc and the cyst through an annular defect.

Kono et al<sup>13</sup> proposed a mechanical stress-induced focal degeneration of the posterior disc wall, followed by fluid collection, reactive pseudomembrane formation around the fluid collection, and subsequent development of the discal cyst. The histologically confirmed presence of fibrous connective tissue without synovial lining cells, imaging and intraoperative findings of an annular fissure, and a communicating stalk between the intervertebral disc and the cyst support the latter hypothesis.

The reported mean age at diagnosis is  $33.5 \pm 12.6$  years, younger than the population suffering from degenerative lumbar disc herniation.<sup>16</sup> The gradual progression of disc degeneration explains both the later onset of clinical symptoms and the patients' older age in the degenerative lumbar disc herniation population. Conversely, a more acute and stressful mechanical impact may cause even a milder disc degeneration followed by reactive pseudomembrane and/or epidural hematoma formation, both resulting in a lumbar discal cyst onset.

The existing literature about discal cysts is summarized in ►Table 1. Overall, 104 patients have been reported. Of these, 16 underwent conservative therapies or percutaneous injection/aspiration, and 88 underwent surgical microscopic or endoscopic procedures. According to the existing literature,<sup>7,16</sup> the majority of patients are males, with few reported female patients; moreover, a large number of discal cyst cases are reported in the Asian population. The sex-related incidence rate could suggest a hormonal influence in the pathogenesis of discal cysts. The predominant incidence in Asia may be related to lifestyle, habits, or genetic factors. However, further demographic and genetic studies are required to explain such racial distribution.<sup>16</sup>

Some reports described medical treatment as the initial management of discal cysts in cases with tolerable pain and without neurologic deficits. In their literature review, Aydin et al<sup>7</sup> showed that among 56 cases of lumbar disc cysts, 8 cases (14%) had been treated conservatively. Of these, spontaneous regression occurred in three patients (37.5%) (two after steroid injection, and one after S1 nerve block), whereas failure of medical therapies and subsequent surgical intervention was reported in five cases (62.5%). Conversely, Chou et al<sup>17</sup> reported the spontaneous regression of a discal cyst 5 months after a routine steroid epidural injection and selective nerve root block. The real effectiveness and the mechanism of steroid injection are still unclear. Moreover, the percutaneous injection procedures are invasive and not totally free from risks.

An alternative option for management of discal cysts was proposed by Koga et al<sup>18</sup> in 2003. They reported the successful management of a lumbar discal cyst by percutaneous CT-guided aspiration and steroid injection. Similarly, Kang et al<sup>19</sup> applied this technique, without using steroid injection, on eight patients, reporting a good or excellent outcome in seven cases. However, one patient (11%) in Kang's series experienced a recurrence of the cyst. Such a circumstance, together with the relapsing clinical symptoms, may support the need for a more radical management, that is, the surgical resection of the cyst.

Surgical techniques in the treatment of discal cysts include endoscopic and microscopic resection of the cyst. This literature review discovered that most cases of discal cysts (69 cases) were successfully managed by microscopic resection of the cyst. This is a simple technique with no reported related morbidity or mortality, good clinical results, and low rate of cyst recurrence.<sup>7</sup> Chiba et al<sup>1</sup> described eight patients with discal cysts, all of whom were surgically treated. Coscia and Broshears<sup>20</sup> presented two more cases of discal cysts, also successfully treated surgically. More recently, Nabeta et al<sup>2</sup> and Kim and Lee<sup>21</sup> reported other small series of cases of lumbar discal cysts treated by microsurgical resection with good outcomes. Interestingly, Lee et al<sup>6</sup> reported at 1-year follow-up one case of recurrence out of nine patients with discal cysts surgically resected. An endoscopic approach has also been proposed as another treatment modality of discal cysts. Ishii et al, in 2005, first proposed such therapeutic option.<sup>22</sup> Recently, Matsumoto et al<sup>23</sup> and Ha et al<sup>24</sup> described the advantages of endoscopic techniques in resection of discal

**Table 1** Summary of all reported cases of discal cyst

	Author/ year	No. patients	Treatment	Main complications	Follow-up
1	Toyama et al (1997) <sup>12</sup>	7	Surgical resection	NA	NA
2	Kono et al (1999) <sup>13</sup>	2	Surgical resection and discectomy	No	NA
3	Demaerel et al (2001) <sup>26</sup>	1	Medical therapies	No	Spontaneous regression
4	Chiba et al (2001) <sup>1</sup>	8	Surgical resection and discectomy (in two cases)	No	3.9 years (mean)
5	Coscia and Broshears (2002) <sup>20</sup>	2	Surgical resection	No	NA
6	Jeong and Bendo (2003) <sup>16</sup>	1	Surgical resection and discectomy	No	12 months
7	Koga et al (2003) <sup>18</sup>	1	Percutaneous CT-guided aspiration and steroid injection	No	6 months
8	Ishii et al (2005) <sup>22</sup>	1 (the second case is a synovial cyst)	Microendoscopy resection	No	NA
9	Norman et al (2006) <sup>27</sup>	1	Percutaneous CT-guided aspiration and steroid injection	No	NA
10	Kishen et al (2006) <sup>28</sup>	1	Surgical resection and discectomy	No	NA
11	Lee et al (2006) <sup>6</sup>	9	Surgical resection and discectomy	One recurrence	NA
12	Tokunaga et al (2006) <sup>29</sup>	2	Surgical resection	No	NA
13	Chou et al (2007) <sup>17</sup>	1	Epidural injection and selective nerve root block	No	5 months (spontaneous regression)
14	Nabeta et al (2007) <sup>2</sup>	5	Surgical resection and discectomy (in four patients)	No	31 months (mean)
15	Murata et al (2007) <sup>30</sup>	1	Surgical resection	No	30 months
16	Okada et al (2007) <sup>31</sup>	1	Surgical resection	No	NA
17	Kanoke et al (2008) <sup>32</sup>	1	Surgical resection	No	NA
18	Hwang et al (2008) <sup>14</sup>	1	Surgical resection	No	NA
19	Kang et al (2008) <sup>19</sup>	8	Percutaneous CT-guided aspiration	One recurrent disc herniation	13 months (mean)
20	Marushima et al (2008) <sup>33</sup>	1	Surgical resection	No	NA
21	Kim et al (2009) <sup>34</sup>	1	Percutaneous endoscopic interlaminar approach using a side-firing Ho:YAG laser	No	NA
22	Kim et al (2009) <sup>35</sup>	2	Percutaneous endoscopic transforaminal approach	No	NA
23	Dumay-Levesque et al (2009) <sup>36</sup>	1	Percutaneous fluoroscopic-guided steroid injection	No	1 year

(Continued)

Table 1 (Continued)

	Author/ year	No. patients	Treatment	Main complications	Follow-up
24	Kim and Lee (2009) <sup>21</sup>	14	Surgical resection (using CO <sub>2</sub> laser)	No	20.1 months (mean)
25	Kobayashi et al (2010) <sup>8</sup>	2	Surgical resection and discectomy	No	2 years
26	Matsumoto et al (2010) <sup>23</sup>	7	Microendoscopic resections	No	27.9 months (mean)
27	Dasenbrock et al (2010) <sup>37</sup>	1	Percutaneous CT-guided aspiration	No	19 months
28	Aydin et al (2010) <sup>7</sup>	5	Surgical resection and discectomy	No	16 months (mean)
29	Aydin et al (2010) <sup>38</sup>	1	Surgical resection and discectomy	No	NA
30	Takeshima et al (2011) <sup>39</sup>	1	Conservative therapy	No	5 months (spontaneous regression)
31	Lin et al (2011) <sup>40</sup>	1	Surgical resection and discectomy	No	NA
32	Hyung-Jun et al (2011) <sup>41</sup>	1	Surgical resection and discectomy	No	2 years
33	Prasad et al (2011) <sup>42</sup>	1	Medical therapies	No	NA
34	Shibata et al (2011) <sup>43</sup>	1	Surgical resection and discectomy (unilateral approach for bilateral cyst)	No	3 months
35	Lame et al (2011) <sup>44</sup>	1	Surgical resection (one level treated in a multilevel case)	No	10 months
36	Khalatbari and Moharamzad (2012) <sup>45</sup>	1	Surgical resection	No	7 years
37	Ha et al (2012) <sup>24</sup>	8	Endoscopic resection and discectomy	Persistence of symptoms in one case	6 months
38	Present case	1	Surgical resection and discectomy	No	24 months

Abbreviation: NA, not available.

Note: Total number of cases: 105.

cysts. Overall, 19 patients who underwent endoscopic treatment were found in the literature. One of these, in Ha's series, experienced the persistence of symptoms.

It remains unclear whether or not the corresponding intervertebral disc in connection with the cyst should be excised. Even in cases with uncertain preoperative differential diagnosis, surgery has to be performed to relieve the compression of neural structures, regardless of its origin. In such cases, the intraoperative finding of an obvious connection between the corresponding intervertebral disc and the cystic lesion is useful and important to differentiate discal cysts from other intraspinal cysts.

However, this point also remains controversial as highlighted by Marshman, who critically commented on the pathogenetic hypotheses and anatomopathological features of discal cysts as distinct pathological entities.<sup>25</sup>

In the present case, we preferred to excise the discal cyst and also perform a microdiscectomy, as we thought that a more radical excision might decrease the risk of recurrence. At the 2-year follow-up, the patient remains asymptomatic with no MRI evidence of discal cyst recurrence. It is difficult to draw evidences on the best treatment of discal cysts as the natural history and the long-term prognosis remain unclear. More cases with longer follow-up are needed to provide therapeutic guidelines.

The thorough analysis of previously reported data on the management of discal cysts suggests that MRI should be considered as the preferred diagnostic tool; discography, followed by CT scan, is essential to definitely demonstrate a communication between the cyst and the disc space.

Traditional myelography and CT myelography play a marginal role in the diagnosis, confirming the extradural location of the cyst, but these studies do not add relevant information relative to MRI scans.

In conclusion, we report a new case of lumbar discal cysts with symptoms and findings resembling a typical lumbar disc herniation, which was successfully treated by microsurgical resection. Although it is a rare pathological entity, lumbar discal cysts should be considered in the differential diagnosis of low back pain and lower limb weakness.

We submit that the operative indications and management strategy of discal cysts are likely to be similar to those applied to lumbar disc herniations; moreover, microsurgical resection appears to be the best treatment for discal cysts in patients with severe pain and neurological impairment.

#### Disclosures

Francesco Certo, none  
 Massimiliano Visocchi, none  
 Alessandro Borderi, none  
 Claudia Pennisi, none  
 Vincenzo Albanese, none  
 Giuseppe M. Barbagallo, none

#### References

- Chiba K, Toyama Y, Matsumoto M, Maruiwa H, Watanabe M, Nishizawa T. Intraspinial cyst communicating with the intervertebral disc in the lumbar spine: discal cyst. *Spine (Phila Pa 1976)* 2001; 26(19):2112–2118
- Nabeta M, Yoshimoto H, Sato S, Hyakumachi T, Yanagibashi Y, Masuda T. Discal cysts of the lumbar spine. Report of five cases. *J Neurosurg Spine* 2007;6(1):85–89
- Boviatsis EJ, Stavrinou LC, Kouyialis AT, et al. Spinal synovial cysts: pathogenesis, diagnosis and surgical treatment in a series of seven cases and literature review. *Eur Spine J* 2008;17(6):831–837
- Taha H, Bareksei Y, Albanna W, Schirmer M. Ligamentum flavum cyst in the lumbar spine: a case report and review of the literature. *J Orthop Traumatol* 2010;11(2):117–122
- Marshman LAG, Benjamin JC, David KM, King A, Chawda SJ. “Disc cysts” and “posterior longitudinal ligament ganglion cysts”: synonymous entities? Report of three cases and literature review. *Neurosurgery* 2005;57(4):E818
- Lee HK, Lee DH, Choi CG, et al. Discal cyst of the lumbar spine: MR imaging features. *Clin Imaging* 2006;30(5):326–330
- Aydin S, Abuzayed B, Yildirim H, Bozkus H, Vural M. Discal cysts of the lumbar spine: report of five cases and review of the literature. *Eur Spine J* 2010;19(10):1621–1626
- Kobayashi S, Takeno K, Uchida K, et al. Pathogenesis of the discal cysts communicating with an adjacent herniated disc. Histological and ultrastructural studies of two cases. *Joint Bone Spine* 2010; 77(2):184–186
- Nishizawa T, Koyanagi T, Toyama Y, et al. Three cases of intraspinal cyst whose symptoms resembled lumbar disc herniation. *Seikei Geka* 1995;46:1353–1357
- Tokutani S, Katano H, Ichikawa S, et al. Intraspinial cyst (premembranous hematoma): a case report. *Rinsho Seikei Geka* 1996; 31:1195–1198
- Chatani K, Kamata Y, Shirokura M, et al. Intraspinial cystic hematoma associated with lumbar disc herniation. *J Jpn Orthop Assoc* 1996;70:S316
- Toyama Y, Kamata N, Matsumoto M. Pathogenesis and diagnostic title of intraspinal cyst communicating with intervertebral disk in the lumbar spine. *Rinsho Seikei Geka* 1997;32:393–400
- Kono K, Nakamura H, Inoue Y, Okamura T, Shakudo M, Yamada R. Intraspinial extradural cysts communicating with adjacent herniated disks: imaging characteristics and possible pathogenesis. *AJNR Am J Neuroradiol* 1999;20(7):1373–1377
- Hwang JH, Park IS, Kang DH, Jung JM. Discal cyst of the lumbar spine. *J Korean Neurosurg Soc* 2008;44(4):262–264
- Ogawa Y, Kumano K, Hirabayashi S, Aota Y. A ganglion cyst in the lumbar spinal canal. A case report. *Spine (Phila Pa 1976)* 1992; 17(11):1429–1431
- Jeong GK, Bendo JA. Lumbar intervertebral disc cyst as a cause of radiculopathy. *Spine J* 2003;3(3):242–246
- Chou D, Smith JS, Chin CT. Spontaneous regression of a discal cyst. Case report. *J Neurosurg Spine* 2007;6(1):81–84
- Koga H, Yone K, Yamamoto T, Komiya S. Percutaneous CT-guided puncture and steroid injection for the treatment of lumbar discal cyst: a case report. *Spine (Phila Pa 1976)* 2003;28(11): E212–E216
- Kang H, Liu WC, Lee SH, Paeng SS. Midterm results of percutaneous CT-guided aspiration of symptomatic lumbar discal cysts. *AJR Am J Roentgenol* 2008;190(5):W310–4
- Coscia MF, Broshears JR. Lumbar spine intracanalicular discal cysts: two case reports. *J Spinal Disord Tech* 2002;15(5): 431–435
- Kim JS, Lee SH. Carbon dioxide (CO<sub>2</sub>) laser-assisted ablation of lumbar discal cyst. *Photomed Laser Surg* 2009;27(6):837–842
- Ishii K, Matsumoto M, Watanabe K, Nakamura M, Chiba K, Toyama Y. Endoscopic resection of cystic lesions in the lumbar spinal canal: a report of two cases. *Minim Invasive Neurosurg* 2005;48(4): 240–243
- Matsumoto M, Watanabe K, Tsuji T, et al. Microendoscopic resection of lumbar discal cysts. *Minim Invasive Neurosurg* 2010;53(2): 69–73

- 24 Ha SW, Ju CI, Kim SW, Lee S, Kim YH, Kim HS. Clinical outcomes of percutaneous endoscopic surgery for lumbar discal cyst. *J Korean Neurosurg Soc* 2012;51(4):208–214
- 25 Marshman LA. Discal cysts. *J Neurosurg Spine* 2007;7(5):575–576, author reply 576–577
- 26 Demaerel P, Eerens I, Goffin J, Wilms G. Spontaneous regression of an intraspinal disc cyst. *Eur Radiol* 2001;11(11):2317–2318
- 27 Norman ER, Beall DP, Kitley CA, Ly JQ. Intervertebral disk cyst: a case report. *J Comput Assist Tomogr* 2006;30(2):313–315
- 28 Kishen TJ, Shetty AP, Rajasekaran S. Variant of a lumbar disc cyst in a 13-year-old girl: a case report. *J Orthop Surg (Hong Kong)* 2006;14(2):184–186
- 29 Tokunaga M, Aizawa T, Hyodo H, Sasaki H, Tanaka Y, Sato T. Lumbar discal cyst followed by intervertebral disc herniation: MRI findings of two cases. *J Orthop Sci* 2006;11(1):81–84
- 30 Murata K, Ikenaga M, Tanaka C, Kanoe H, Okuaaira S. Discal cysts of the lumbar spine: a case report. *J Orthop Surg (Hong Kong)* 2007;15(3):376–379
- 31 Okada K, Saito H, Nishida J, et al. Discal cyst associated with myxoid change and apoptosis of herniated disc materials: a case report. *Ups J Med Sci* 2007;112(1):39–47
- 32 Kanoke A, Suzuki S, Nimura T, et al. [Case report of lumbar discal cyst]. *No Shinkei Geka* 2008;36(2):159–163
- 33 Marushima A, Uemura K, Sato N, Maruno T, Matsumura A. Osteolytic lumbar discal cyst: case report. *Neurol Med Chir (Tokyo)* 2008;48(8):363–366
- 34 Kim JS, Choi G, Jin SR, Lee SH. Removal of a discal cyst using a percutaneous endoscopic interlaminar approach: a case report. *Photomed Laser Surg* 2009;27(2):365–369
- 35 Kim JS, Choi G, Lee CD, Lee SH. Removal of discal cyst using percutaneous working channel endoscope via transforaminal route. *Eur Spine J* 2009;18(Suppl 2):201–205
- 36 Dumay-Levesque T, Souteyrand AC, Michel JL. Steroid injection performed with fluoroscopy for treatment of a discal cyst. *J Rheumatol* 2009;36(8):1841–1843
- 37 Dasenbrock HH, Kathuria S, Witham TF, Gokaslan ZL, Bydon A. Successful treatment of a symptomatic L5/S1 discal cyst by percutaneous CT-guided aspiration. *Surg Neurol Int* 2010;1:41
- 38 Aydin S, Kucukyuruk B, Yildirim H, Abuzayed B, Bozkus H, Vural M. Acute formation of lumbar discal cyst: what is the mechanism? *J Neurosurg Sci* 2010;54(4):149–152
- 39 Takeshima Y, Takahashi T, Hanakita J, et al. Lumbar discal cyst with spontaneous regression and subsequent occurrence of lumbar disc herniation. *Neurol Med Chir (Tokyo)* 2011;51(11):809–811
- 40 Lin N, Schirmer CM, Proctor MR. Presentation and progression of a disc cyst in a pediatric patient. *J Neurosurg Pediatr* 2011;7(2):209–212
- 41 Hyung-Jun K, Dae-Yong K, Tae-Ho K, et al. Lumbar discal cyst causing bilateral radiculopathy. *Surg Neurol Int* 2011;2:21
- 42 Prasad G, Kabir SM, Saifuddin A, Casey AT. Spontaneous resolution of discal cyst around L5 nerve root: case report and review of literature. *Br J Neurosurg* 2011;25(6):761–763
- 43 Shibata S, Hanakita J, Takahashi T, Minami M, Kuraishi K, Watanabe M. Bilateral discal cysts managed by partial hemilaminectomy and microscopic resection of hemilateral cyst. *Spine (Phila Pa 1976)* 2011;36(25):E1655–E1658
- 44 Lame A, Kaloshi G, Xhumari A, Vreto G, Petrela M. Insights on the natural history and pathogenesis of multilevel discal cysts. *J Clin Neurosci* 2012;19(4):617–619
- 45 Khalatbari MR, Moharamzad Y. Discal cyst in pediatric patients: case report and review of the literature. *Neuropediatrics* 2012;43(5):289–292

## Editorial Perspective

*EBSJ* appreciates the detailed case report on intradiscal cysts and the balanced commentary by Dr. Moisi and colleagues.

These contributions underscore the importance of collecting small series or rare occurrence disorders in a centralized database with an attempt at a consistent treatment protocol to maximize the possibility for scientific insight. The emerging AOSpine Knowledge Forum for degenerative spine disorders could provide such a platform. Alternatively, a region like AOSpine Asia-Pacific might be interested in starting a larger data collection effort given the much higher prevalence of this condition in that particular region.

In the case of discal cysts, we really seem to need just about everything: imaging morphology, clinical symptomatology, natural course history, and intraoperative pathology, using consistent staining techniques and details of surgical techniques—whether a formal discectomy should be preferably added, as recommended by the case-report authors, or if a simple cyst resection suffices, as recommended by Moisi et al in their commentary. Hopefully, this case report will stimulate creation of a rare case database for these types of disc pathology and raise the awareness of the global AOSpine surgery community to this entity. Of course, any further thoughts or experiences with the diagnosis or treatment of this pathology are welcome.