



CASE REPORT

A rare case of plexiform angiomyxoid myofibroblastic tumor in the stomach which was diagnosed at the earliest stage in the literature

Xi Li¹, Shuangqing Li¹, Shenghua Xiong², Zhujun Wang³, Hu Zhang^{3,*}

¹Department of General Practice, West China Hospital of Sichuan University, Chengdu, Sichuan, China,

²Department of Pathology, West China Hospital of Sichuan University, Chengdu, Sichuan, China and

³Department of Gastroenterology, West China Hospital of Sichuan University, Chengdu, Sichuan, China

*Corresponding author. Department of Gastroenterology, West China Hospital of Sichuan University, 37 GuoXue Xiang, Chengdu, Sichuan 610041, China; Tel: + 86-28-85422387; E-mail: zhanghu@scu.edu.cn

Abstract

Plexiform angiomyxoid myofibroblastic tumor (PAMT) is a rare gastric mesenchymal entity with a peculiar plexiform pattern, bland spindle cells and myxoid stroma rich in arborizing blood vessels. Here we report a 44-year-old Chinese woman with PAMT. Initially she was admitted for removal of a gastric antral 'polyp' found on a routine examination 5 months previously. Our gastroscopy showed a 0.8 × 0.8 cm polyp-like mass in the antrum which protruded into the lumen. Endoscopic submucosal dissection (ESD) was performed to remove this mass en bloc. The specimen was carefully examined by pathologists, and the correct diagnosis of PAMT was finally made. The tumor in this case depicted typical histopathological and immunohistochemical features of gastric PAMT. This PAMT was not only the smallest on endoscopic examination in the literature but also—unlike the already reported PAMTs—exhibited a focal hyperechogenic lesion on endoscopic ultrasonography (EUS). This information highlights its value on how to identify a PAMT at its early stage.

Key words: plexiform angiomyxoid myofibroblastic tumor; diagnosis; endoscopic ultrasonography; gastrointestinal stromal tumors

Introduction

Plexiform angiomyxoid myofibroblastic tumor (PAMT) is a recently identified tumor of the stomach which was firstly described in 2007 [1]. Miettinen *et al.* reported that there were more than 150 gastrointestinal stromal tumors (GISTs) of the stomach for every case of PAMT [2]. To date, there have been only 42 reported cases of gastric PAMT in the medical literature [1–17]. PAMT is also called 'plexiform angiomyxoma' [6] or 'plexiform angiomyxoid tumor' [2], and the term 'plexiform

fibromyxoma' was added as the diagnostic term instead of PAMT in the 2010 WHO Classification of Tumours of the Digestive System. However, most researchers are used to the term 'PAMT' at present. PAMT is more appropriate than other terms for referring to this tumor, as it not only includes both histogenesis and histological features but can also avoid potential confusion. Because of the rarity and lack of awareness about this entity, accurate diagnosis of PAMT is difficult at an early stage. Here we report an early diagnosis of a PAMT case.

Submitted: 21 September 2016; Accepted: 23 September 2016

© The Author(s) 2016. Published by Oxford University Press and Sixth Affiliated Hospital of Sun Yat-Sen University

This is an Open Access article distributed under the terms of the Creative Commons Attribution Non-Commercial License (<http://creativecommons.org/licenses/by-nc/4.0/>), which permits non-commercial re-use, distribution, and reproduction in any medium, provided the original work is properly cited. For commercial re-use, please contact journals.permissions@oup.com

Case Report

A 44-year-old Chinese woman was admitted because of an antral 'polyp' in the stomach for 5 months which had been found during a routine health examination with gastroscopy in her local hospital. The patient did not experience any gastric discomfort due to this 'polyp.' She has been diagnosed with type 2 diabetes for 3 year, and had undergone total thyroidectomy, bilateral lymph node dissection and parathyroid auto-transplantation for papillary thyroid carcinoma 5 months ago. Review of tumor markers (CEA, CA125, CA153 and CA199), hemoglobin A1C and thyroid function was normal. A second gastroscopy in our hospital confirmed a 0.8×0.8 cm polyp-like mass with distinct border and without mucosal ulceration at the gastric antrum. Further endoscopic EUS revealed a homogeneous hyperechoic lesion protruding into the lumen which was oval and without a distinct border. Furthermore, the lesion seemed to originate from submucosa and muscularis propria and was clearly demarcated from the serosa (Figure 1). Endoscopic submucosal dissection (ESD) was performed to remove this mass en bloc.

Histological examination revealed that the tumor was mainly occupied by myxoid matrix extending from mucosa to muscularis mucosa at antrum. It also exhibited a plexiform pattern with spindle-shaped bland tumor cells. In order to determine the final diagnosis of this tumor, a group of molecular markers was stained immunohistochemically on the biopsy slides. The tumor cells were positive for vimentin, a cluster of differentiation 34 (CD34) but negative for smooth muscle actin (SMA), desmin, cluster of differentiation 117(CD117), phosphoenolpyruvate carboxykinase (PCK) and S-100. Taken together, a final diagnosis of PAMT was made (Figure 2). Our follow-up indicated that the patient made an uneventful recovery at 6 months after ESD.

Discussion

In this study, we reported a rare but early-diagnosed PAMT case. Together with this case, we analyzed all reported PAMT cases in the literature [1–17]. The size of tumor varies, with the largest size being $14 \times 14 \times 7$ cm. With development of the tumor, the mucosa may be intact, dimpled or even ulcerated [6]. In contrast, our case had a tumor without ulcer at a size of

0.8×0.8 cm when diagnosed which indicated that this female PAMT case was diagnosed at the earliest stage compared with those previously reported cases. The fact of early diagnosis may be the reason why she did not present with any characteristic symptoms: hematemesis, anemia, abdominal discomfort or distention. This tumor grew at the antrum, lying in the submucosa, with a focally thickened muscularis, and it was clearly demarcated from the serosa. This is consistent with the typical location reported previously. In addition, PAMT can also be present in the fundus and body of the stomach [4,7,8]. This tumor grows in submucosa and looks like a polyp under gastroscopy. Moreover, routine biopsy cannot access tumor cells. All of these disadvantages can contribute to a delayed correct diagnosis for PAMT patients.

It is critical to have the mass removed en bloc and then sent out for pathological examination if one correction diagnosis is warranted. Histological finding of this tumor exhibited the typical characteristics of PAMT such as spindle-shaped bland tumor cells arranged characteristically in a plexiform pattern, nodular or multinodular; a myxoid stroma rich in arborizing vessels varying from small thin-walled vascular channels to ectatic; no cytological atypia, necrosis or brisk mitotic rate was found [9]. Immunohistochemical staining can accurately identify the type of tumor cells. Immunohistochemistry of the tumor cells in this case was positive for CD34 and vimentin and negative for CD117, SMA, desmin, PCK and S-100 protein, indicating that the tumor cells were myofibroblastic in origin. Some reports revealed that a subset of tumor cells was positive for SMA, desmin and H-caldesmon [4,6]. Thus, PAMT is not a purely myofibroblastic tumor and may contain some tumor cells arising from smooth muscle differentiation.

EUS revealed a homogeneous hyperechoic lesion of this case. Only 6 of the 42 reported PAMT cases published in the literature had been confirmed by EUS, and all showed hypoechoic lesions [3,6,8–10]. Our case is the first to exhibit a hyperechoic lesion for PAMT on EUS. Our finding enriches the knowledge of PAMT in terms of EUS. It means that PAMT lesions can be either hypoechoic or hyperechoic. EUS is a valuable method in terms of differential diagnosis of submucosal tumors such as PAMT and GIST [18]. It can evaluate the phenotype of tumor and determine the type of tumor cells by EUS-guided fine needle aspiration (EUS-FNA) with immunohistochemical analysis. This is critical to for determining the appropriate operation, thereby avoiding misdiagnosis and unnecessary exploratory laparotomy. In this sense, EUS can work as a key examination for PAMT before surgery.

Although PAMT demonstrates distinctive pathological features, differential diagnosis is an integral step in the process. Given that some other tumors (e.g. GIST) grow under mucosa in a manner similar to PAMT, it is always fundamental to make a differential diagnosis before making a final diagnosis of PAMT. For GIST, tumor cells are arranged in short fascicles rather than a plexiform pattern. Most GISTs are positive for CD117 and DOG1 and have mutations of the KIT or PDGFRA gene [2]. Leiomyoma tumor cells are arranged in fascicles and are diffusely positive for SMA, desmin and H-caldesmon. In desmoid fibromatosis, spindle cells are arranged in long fascicles and show nuclear translocation of β -catenin. Inflammatory fibroid polyps are usually composed of epithelioid-to- spindle shaped fibroblasts and inflammatory cells. Inflammatory myofibroblastic tumor is full of inflammatory cells and is positive for ALK-1. Plexiform neurofibromas are positive for S-100. To make a differential diagnosis, the pathological examination and IHC staining of molecular makers are critical.

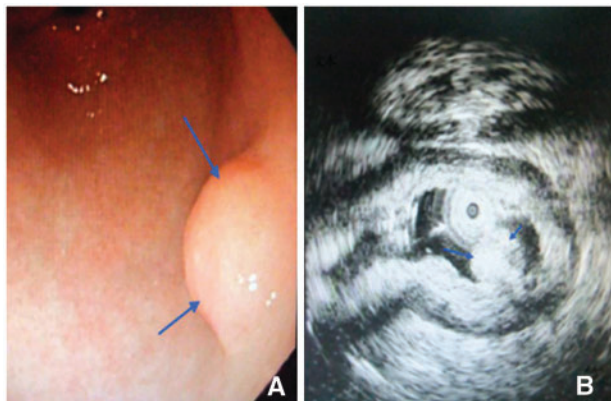


Figure 1. Endoscopic and endosonographic views of the plexiform angiomyxoid myofibroblastic tumor (PAMT) at the antrum of the stomach. (A) Endoscopic view of the tumor showing a 0.8×0.8 cm polyp-like mass; (B) Endosonographic image showing homogeneous hyperechoic lesion protruding into the lumen (indicated by arrows).

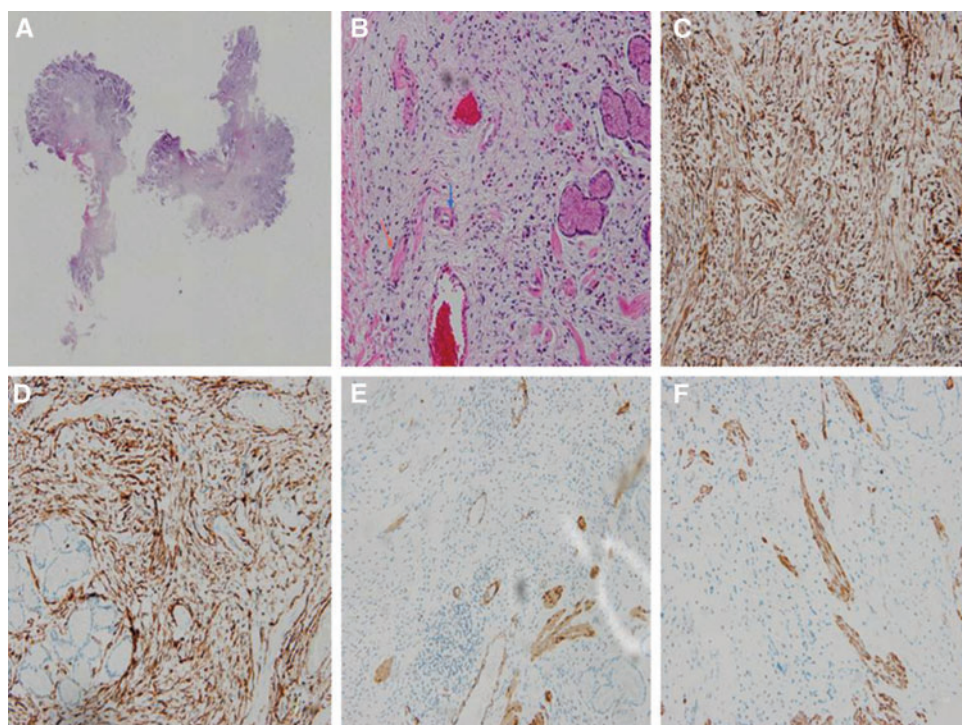


Figure 2. Pathological findings of the plexiform angiomyxoid myofibroblastic tumor (PAMT). (A) Multinodular plexiform growth pattern (hematoxylin-eosin staining, $\times 40$); (B) Multinodular plexiform pattern with bland spindle tumor cells (red arrow), myxoid extracellular matrix and fine arborizing vessels (blue arrow) (hematoxylin-eosin staining, $\times 200$); (C) Diffusely positive staining for vimentin (immunohistochemical staining, $\times 200$); (D) Diffusely positive staining for CD34 (immunohistochemical staining, $\times 200$); (E) Negative staining for SMA (immunohistochemical staining, $\times 200$); (F) Negative staining for CD177 (immunohistochemical staining, $\times 200$).

According to the current literature, gastrectomy (distal or partial) is a major technique for dealing with PAMT. Together with our case, only four patients underwent local excision of tumor [7,10,14]. The common characteristic for the four cases is that the tumors are small enough to be removed under gastroscopy. Compared with gastrectomy, local excision can bring less harm to the patients. On behalf of patients, it is important to diagnose PAMT as early as possible. PAMT is considered to be benign tumor for these reasons: bland nuclear features, low proliferative index, absence of necrosis and vascular invasion and no recurrence or metastasis in all previously reported cases [9]. Because of its small size and good prognosis, this tumor should be removed by ESD under gastroscopy at an early stage.

Conclusion

PAMT is a very rare gastric tumor of mesenchymal origin. Its myofibroblastic bland spindle-shaped cells are arranged in a multinodular plexiform pattern, and proliferation of small vessels is marked. Its appearance can vary on EUS. Accurate diagnosis of PAMT is difficult at the early stage, and it is necessary to differentiate it from GIST and other mesenchymal tumors of the stomach. When a myxoid spindle cell lesion is observed on endoscopic biopsy, PAMT should be considered in the differential diagnosis.

Conflict of interest statement: none declared.

References

1. Takahashi Y, Shimizu S, Ishida T, et al. Plexiform angiomyxoid myofibroblastic tumor of the stomach. *Am J Surg Pathol* 2007, **31**:724–8.
2. Miettinen M, Makhoul HR, Sobin LH, et al. Plexiform fibromyxoma: a distinctive benign gastric antral neoplasm not to be confused with a myxoid GIST. *Am J Surg Pathol* 2009, **33**:1624–32.
3. Duckworth LV, Gonzalez RS, Martelli M, et al. Plexiform fibromyxoma: report of two pediatric cases and review of the literature. *Pediatr Dev Pathol* 2014, **17**:21–7.
4. Ikemura M, Maeda E, Hatao F, et al. Plexiform angiomyxoid myofibroblastic tumor (PAMT) of the stomach. A case report focusing on its characteristic growth pattern. *Int J Clin Exp Pathol* 2014, **7**:685–9.
5. Li P, Yang S, Wang C, Li Y, et al. Presence of smooth muscle cell differentiation in plexiform angiomyxoid myofibroblastic tumor of the stomach: a case report. *Int J Clin Exp Pathol* 2014, **7**:823–7.
6. Yoshida A, Klimstra DS, Antonescu CR. Plexiform angiomyxoid tumor of the stomach. *Am J Surg Pathol* 2008, **32**:1910–2; author reply 1912–3.
7. Kang Y, Jung W, Do IG, et al. Plexiform angiomyxoid myofibroblastic tumor of the stomach: report of two cases and review of the literature. *Korean J Pathol* 2012, **46**:292–6.
8. Wang WY, Li JN, Li GD. Plexiform angiomyxoid myofibroblastic tumour of the gastric fundus: successful diagnosis and treatment by endoscopy. *J Clin Pathol* 2010, **63**:569–70.
9. Takahashi Y, Suzuki M, Fukusato T. Plexiform angiomyxoid myofibroblastic tumor of the stomach. *World J Gastroenterol* 2010, **16**:2835–40.
10. Sing Y, Subrayan S, Mqadi B, et al. Gastric plexiform angiomyxoid myofibroblastic tumor. *Pathol Int* 2010, **60**:621–5.

11. Sakamoto K, Hirakawa M, Atsumi K, et al. A case of gastric plexiform fibromyxoma: radiological and pathological findings. *Jpn J Radiol* 2014, **32**:431–6.
12. Tan CY, Santos LD, Biankin A. Plexiform angiomyxoid myofibroblastic tumour of the stomach: a case report. *Pathology* 2010, **42**:581–3.
13. Kim A, Bae YK, Shin HC, et al. Plexiform angiomyxoid myofibroblastic tumor of the stomach: a case report. *J Korean Med Sci* 2011, **26**:1508–11.
14. Schulz T, Drgac J, Chmelar C, et al. Plexiform angiomyxoid myofibroblastic tumour of the stomach. *Pathologe* 2012, **33**:65–9 (in German).
15. Wang FH, Chen ZR, Niu HL, et al. Plexiform fibromyxoma of stomach: a distinctive benign tumor of gastric antrum. *Zhonghua Bing Li Xue Za Zhi* 2012, **41**:190–1 (in Chinese).
16. Bi R, Yin W, Liu XL, et al. Plexiform angiomyxoid myofibroblastic tumor of stomach. *Zhonghua Bing Li Xue Za Zhi* 2012, **41**:756–60 (in Chinese).
17. Pailoor J, Mun KS, Chen CT, et al. Plexiform angiomyxoid myofibroblastic tumour of the stomach. *Pathology* 2009, **41**:698–9.
18. Vander Noot MR, 3rd, Eloubeidi MA, Chen VK, et al. Diagnosis of gastrointestinal tract lesions by endoscopic ultrasound-guided fine-needle aspiration biopsy. *Cancer* 2004, **102**:157–63.