



Treatment of acromioclavicular joint separations in Japan: a survey

Katsumi Takase, MD, PhD^{*}, Yukihiro Hata, MD, Yutaka Morisawa, MD, Masafumi Goto, MD, Sakae Tanaka, MD, Junichiro Hamada, MD, Kenji Hayashida, MD, Yasunari Fujii, MD, Toru Morihara, MD, Nobuyuki Yamamoto, MD, Hiroaki Inui, MD, Hiroyuki Shiozaki, MD

Scientific Research Project Committee, Japan Shoulder Society, Tokyo, Japan



ARTICLE INFO

Keywords:

Acromioclavicular joint separations
initial treatment
indications for surgery
surgical methods
conservative treatment
Rockwood classification

Level of evidence: Survey Study; Experts

Background: Treatment options for acromioclavicular joint (ACJ) separations are highly dependent on severity, as well as the patient's background. Furthermore, some patients can be switched from conservative to surgical treatment. In this study, we conducted a mail-based questionnaire survey of members of the Japan Shoulder Society on the administration of treatments for ACJ separations.

Methods: A questionnaire survey with 5 categories was mailed to all 1655 members of the Japan Shoulder Society (including 59 councilors): initial treatment, whether surgery was performed, indications for surgery based on severity, switching from conservative to surgical treatment, and surgical methods.

Results: Altogether, 183 members, including 56 councilors, responded. Regarding the initial treatment, 17 respondents opted for treatment without immobilization or fixation and 166 opted for immobilization or fixation. Of the members, 11 opted for only conservative treatment whereas 172 chose surgery depending on the case; of the latter, 9 considered it for patients with a Rockwood classification of type 2 or higher; 120, for patients with type 3 or higher; and 172, for patients with types 4–6. Furthermore, 75 of 172 members had experience switching to surgical treatment during conservative treatment. For 64 of 172 members, the modified Cadenat method was the most common surgical method.

Conclusions: Only 11 members opted for conservative treatment of ACJ separations, and approximately 95% of physicians chose surgery. Furthermore, >70% of physicians considered surgery for an injury classified as type 3 or higher, and 37% of members performed the modified Cadenat method. However, the popularization of arthroscopic surgery may affect the selection of surgical methods in the future.

© 2020 The Author(s). Published by Elsevier Inc. on behalf of American Shoulder and Elbow Surgeons. This is an open access article under the CC BY-NC-ND license (<http://creativecommons.org/licenses/by-nc-nd/4.0/>).

The choice of treatment for acromioclavicular joint (ACJ) separations is highly dependent on severity, as well as the patient's background. Even for shoulder surgery specialists, there is no gold-standard concept for the initial treatment, indications for surgery, and surgical methods for acute injuries. Furthermore, some patients can be switched from conservative to surgical treatment over the course of the injury. The Tossy classification²³ or Rockwood classification¹⁵ is commonly used to classify the severity of ACJ separations; however, the classification method for determining the severity of surgery is not standardized. In this study, we conducted a mail-based questionnaire survey of delegates and

members of the Japan Shoulder Society (JSS) on the administration of treatments for acute injuries with ACJ separations.

Methods

We conducted a mail-based questionnaire survey of all 1655 JSS members (comprising 1596 regular members and 59 councilors as of January 2018) regarding the treatment of patients with acute ACJ separations for which consultations occurred within 2 weeks after injury. The survey items consisted of 5 categories: initial treatment, whether surgery was performed, indications for surgery based on severity, whether patients had changed from conservative to surgical treatment over the course of the injury, and surgical methods (Tables I–IV). The Tossy or Rockwood classification was used to represent severity.^{15,23} For convenience, however, a grade 1 injury according to the Tossy classification was defined as a type 1 injury according to the Rockwood classification; grade 2, as type 2; and

This questionnaire survey was approved by the Ethical Committee of the Japan Shoulder Society.

^{*} Corresponding author: Katsumi Takase, MD, PhD, Department of Orthopedic Surgery, Tokyo Medical University, 6-7-1 Nishishinjuku Shinjuku-ku, Tokyo, 160-0023, Japan.

E-mail address: k-takase@muf.biglobe.ne.jp (K. Takase).

<https://doi.org/10.1016/j.jseint.2020.09.008>

2666-6383/© 2020 The Author(s). Published by Elsevier Inc. on behalf of American Shoulder and Elbow Surgeons. This is an open access article under the CC BY-NC-ND license (<http://creativecommons.org/licenses/by-nc-nd/4.0/>).

Table I

Treatment methods

A: Choice of treatment method
Perform conservative treatment for all
Perform surgery based on the case
B: Initial treatment
No fixation
Sling fixation
Sling fixation + bust bandage
Brace fixation
Other ()*
C: Fixation duration if fixated (weeks)
Sling fixation
(Fixation period: 1/2/3/4/5/6)
Sling fixation + bust bandage
(Fixation period: 1/2/3/4/5/6)
Brace fixation
(Fixation period: 1/2/3/4/5/6)
D: Was there any change to surgery during the course of conservative treatment?
• No
• Yes
E: When the course of conservative treatment was switched to surgery
• Period from injury to surgery ()*
• Reason for changing to surgery ()*

* Respondents were asked to provide fill-in-the-blank responses.

Table II

Indications for surgery based on severity (Rockwood or Tossy classification)*

Rockwood classification
Type I
Type II
Type III
Type IV
Type V
Type VI
Tossy classification
Type I
Type II
Type III

* Multiple answers were allowed.

grade 3, as type 3 or higher. In this study, we used the Rockwood classification to represent severity for all ACJ separations.

Results

The respondents comprised 56 of 59 councilors of the JSS (response rate, 94.9%) and 127 of 1596 regular members (response rate, 8.0%), for a total of 183 respondents. A response rate > 90% was obtained among the shoulder surgeons (JSS councilors) who play a leading role in the JSS.

In terms of treatment options, 11 members opted for only conservative treatment in all cases and 172 members chose surgical treatment depending on the individual case. For the initial treatment, 17 members opted for treatment without immobilization or fixation; 142, treatment with a fixed upper-limb sling; and 24, treatment with a fixed orthosis for holding the shoulder joint. In the immobilization period, the length of sling fixation of the upper limb was 1 week for 10% of members (n = 14), 2 weeks for 36% (n = 51), 3 weeks for 42% (n = 59), 4 weeks for 4% (n = 6), and ≥1 month for 8% (n = 12), whereas the length of orthosis fixation was 3 weeks for 58% of members (n = 14) and 4 weeks for 42% (n = 10).

Among the 172 members who suggested the possibility of surgery, 9 considered it for patients with a Rockwood classification of type 2 or higher; 120, for type 3 or higher; and 172, for types 4-6 (Fig. 1). Factors other than severity on which the members focused regarding surgical indications were occupation (67%, n = 116),

Table III

Factors for surgery other than severity*

Gender
Hand dominance
Occupation
Occupations to actively consider ()†
Sporting activities
Sporting activities to actively consider ()†
Others()†

* Multiple answers were allowed.

† Respondents were asked to provide fill-in-the-blank responses.

Table IV

Expected effects of surgery*

Early rehabilitation
Prevention of osteoarthritis of the ACJ
Prevention of muscle weakness
Prevention of a restricted range of motion of the joints
Prevention of scapulothoracic joint dysfunction
Others ()†

ACJ, acromioclavicular joint.

* Multiple answers were allowed.

† Respondents were asked to provide fill-in-the-blank responses.

sports activity (52%, n = 91), and sex (33%, n = 56). Of the 116 members considering a patient's occupation, in particular, 41 considered surgical indications to include carpenters, plasterers, and teachers (occupations requiring shoulder-raising positions); 28, civil engineering workers (including workers heavy handling heavy loads); 13, farmers; 2, fishers; 2, Self-Defense Forces personnel; 1, dentists; and 1, delivery workers. Furthermore, 108 members (61.4%) conducted surgery to prevent scapulothoracic joint dysfunction; 93 (52.8%), to prevent apparent deformity of the ACJ; 77 (43.8%), to prevent muscle weakness; 36 (20.5%), for early rehabilitation; 29 (16.5%), to prevent joint range-of-motion restriction; and 14, for other reasons.

During conservative treatment, 75 of the 172 members had experience switching to surgical treatment, excluding the 11 members who consistently performed conservative treatment. Of these members, 20 (26.7%) made the switch within 1 month; 28 (37.3%), within 1-3 months; 8 (10.7%), within 3-6 months; 9 (12%), within 6 months to 1 year; and 1 (1.3%), after 1 year. The reason for surgery was pain (n = 39, 52%), patient's wishes (n = 16, 21.3%), fatigue of the shoulder girdle (n = 7, 9.3%), posterior instability of the ACJ (n = 5, 6.7%), postural problems (n = 5, 6.7%), worsening of severity (n = 3, 4%), limited range of motion (n = 2, 3%), or stiff shoulder (n = 1, 1%).

The surgical methods to be selected were roughly classified into open surgery and arthroscopic surgery (including some overlap; Fig. 2). Forty-eight members performed arthroscopic surgery for coracoclavicular ligament reconstruction, whereas 34 members performed arthroscopic coracoclavicular ligament reconstruction plus acromioclavicular ligament and deltoid muscle repair. Regarding open surgery, 67 members performed the modified Cadenat method⁶ (regardless of internal fixation material); 31, coracoclavicular ligament reconstruction; 29, hook plate fixation; 27, the modified Phemister method¹⁴; 25, distal clavicle resection; 24, coracoclavicular ligament reconstruction plus acromioclavicular ligament and deltoid muscle repair; 15, the Weaver-Dunn method²⁵; 12, ACJ fixation with K-wires; 11, the hook plate method plus conoid ligament reconstruction; 6, the Bosworth method⁵; 3, the modified Dewar method⁸; and 3, the modified Neviasser method.¹¹

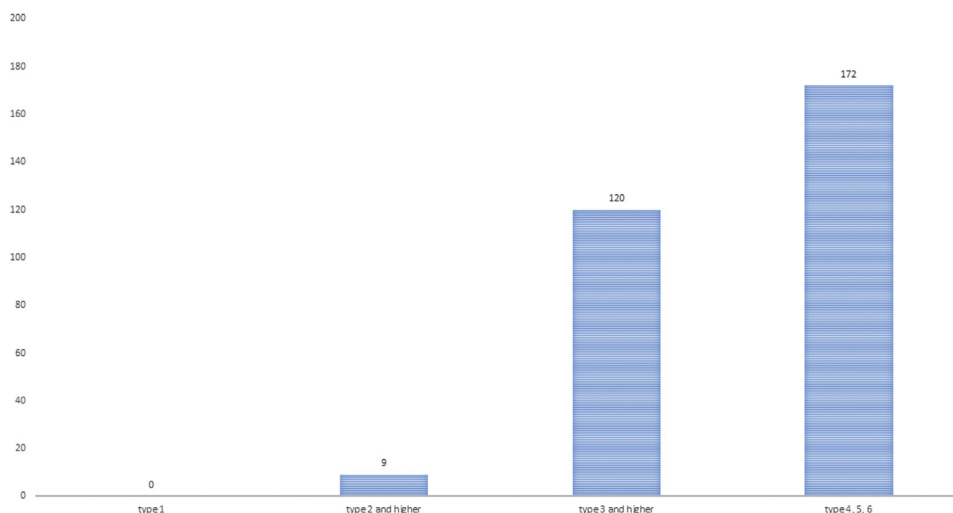


Figure 1 Indications for surgery based on severity (9 members considered surgery for type 2 or higher; 120 members, for type 3 or higher; and 172, for types 4-6).

Discussion

In this study, we mailed a questionnaire survey with questions about the classification of ACJ separation severity to the members of the JSS. The questionnaire was sent to all 1655 JSS members, and 183 (11.1%) responded. Although the overall response rate was low, 56 of 59 councilors—who had >10 years of clinical experience as shoulder surgeons and were in leadership positions at the JSS at the time of the survey—responded. This provided us with very significant results.

In terms of surgical indications,^{3,4,22} Rockwood classification types 1 and 2 generally indicate conservative treatment whereas types 4-6 indicate surgical indications¹; type 3 is controversial.^{10,12,24} However, Song et al¹⁸ reported that 17 patients with type

2 injuries that had been treated conservatively during the 9 years since 1998 underwent surgical treatment of an old ACJ injury because pain and ACJ instability remained. A type 2 injury is ACJ subluxation, and the pathology is rupture of the ACJ capsule and rupture of the acromioclavicular ligament. It is thought that continuity is maintained although there is partial damage to the coracoclavicular ligament. However, Takase²⁰ observed ruptures of the ACJ capsule, acromioclavicular ligament, and trapezoid ligament with an intact conoid ligament in all cases with type 2 injuries evaluated by magnetic resonance imaging within 3 days after injury. According to our results, 9 of 172 members suggested that a type 2 injury was indicative of surgery even in acute cases. Considering the simultaneous tearing of the acromioclavicular and trapezoid ligaments, all type 2 injuries should not consistently be

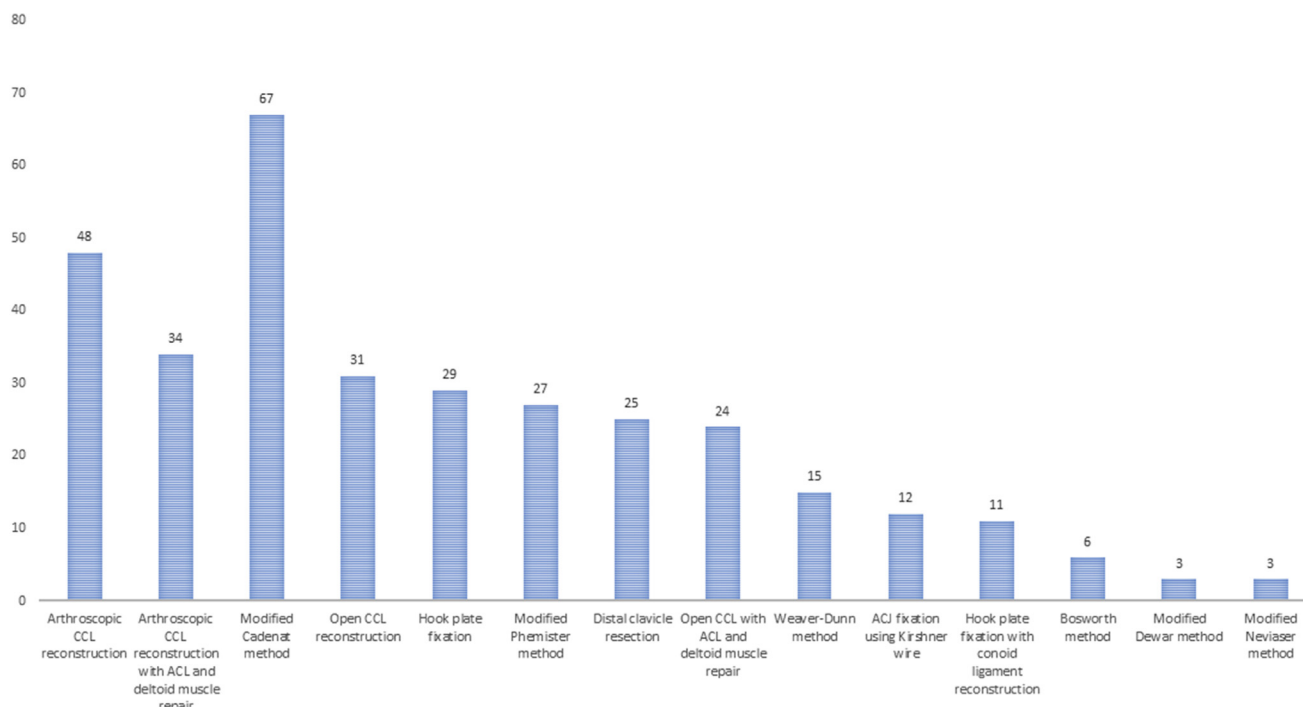


Figure 2 Surgical methods performed by 172 members. CCL, coracoclavicular ligament; ACL, acromioclavicular ligament; ACJ, acromioclavicular joint.

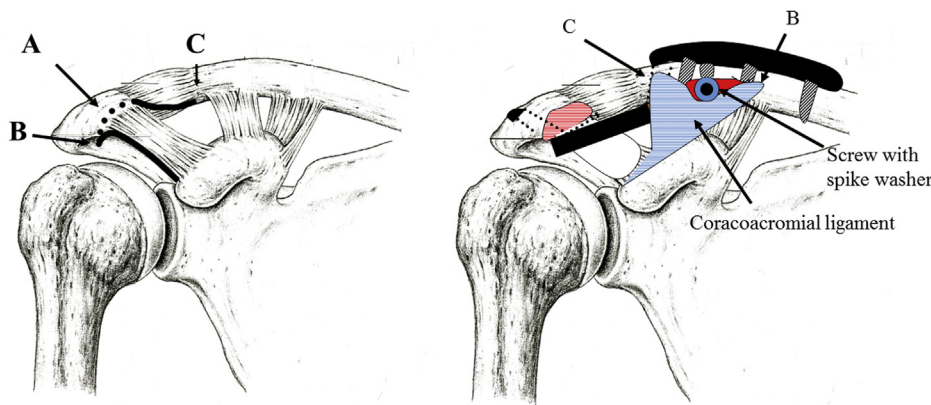


Figure 3 Surgical procedure by modified Cadenat method. Preparation of the transferred ligament is shown on the *left*: osteotomy of the anterior edge of the acromion with the coracoacromial ligament (A), lateral edge of the coracoacromial ligament (B), and medial edge of the coracoacromial ligament (C). Fixation of the transferred ligament to the clavicle is shown on the *right*. Release of the coracoacromial ligament is performed with a bone tip from the acromion (B-A-C). The detached coracoacromial ligament with the bone tip is fixed to the anterior side of the clavicle using a screw with a spike washer in a position that allows sufficient tension to be obtained.

considered for conservative treatment because posterior instability of the ACJ might remain. Sufficient follow-up is necessary, and surgical treatment may be required depending on the symptoms. However, regarding the main factors other than severity, occupation was more important than sports activity to 116 of 172 respondents (67%). Occupations such as plastering, carpentry, teaching, and farming, which require patients to maintain positions with the upper limbs raised, were regarded as important. This finding was consistent with the prevention of scapulothoracic joint dysfunction^{9,13} expected from surgery.

Song et al¹⁹ reported the importance of conducting surgery within 3 weeks of injury to achieve a successful outcome. Furthermore, in our study, 75 of 172 members had considered a switch to surgical treatment during conservative treatment, with 64% of respondents switching within 3 months and 99% switching within 1 year. The reasons for opting for surgery included the wishes of patients (about 20% of members who switched); however, about 50% indicated that painful symptoms were the reason. Although it was difficult to evaluate the severity and therapeutic results of patients who were switched from conservative treatment to surgical treatment through the questionnaire survey, the reason for the switch was that the pain in the distal clavicle remained during shoulder movements.

Various surgical methods exist for ACJ separations, and relatively good results have been reported. Typical open surgery methods include the Phemister method¹⁴ or Neviaser method¹¹ to

repair the acromioclavicular ligament, the Bosworth method⁵ for inter-coracoclavicular fixation, the Weaver-Dunn method²⁵ or Cadenat method⁶ using the coracoacromial ligament as a substitute ligament for the coracoclavicular ligament, and the Dewar method⁸ for treatment by dynamic stabilization with the conjoined tendon. In contrast, Salzmann et al,¹⁶ Scheibel et al,¹⁷ Balog et al,² De Beer et al,⁷ and Takase and Yamamoto²¹ have reported methods for anatomically reconstructing the trapezoid and conoid ligaments with arthroscopic surgery. Furthermore, Scheibel et al reported that posterior instability of the ACJ may remain with vertical stabilization alone and it is important to reconstruct the acromioclavicular ligament simultaneously, which reduces posterior instability. According to the results of our questionnaire, 67 of 172 members performed the modified Cadenat method (Figs. 3 and 4), which is an open operation. However, in recent years, owing to the advancement of arthroscopic technology, 48 of 172 members have been performing arthroscopic coracoclavicular ligament reconstruction; only 34 of these have added reconstruction of the acromioclavicular ligament to arthroscopic coracoclavicular ligament reconstruction.

Our study had several limitations. Given the low survey response rate, these findings may not be generalizable to the interventional community as a whole. However, a response rate of >90% was obtained among the shoulder surgeons (JSS councilors) who play a leading role in the JSS. Furthermore, the results of this study did not clearly show why treatment was switched from

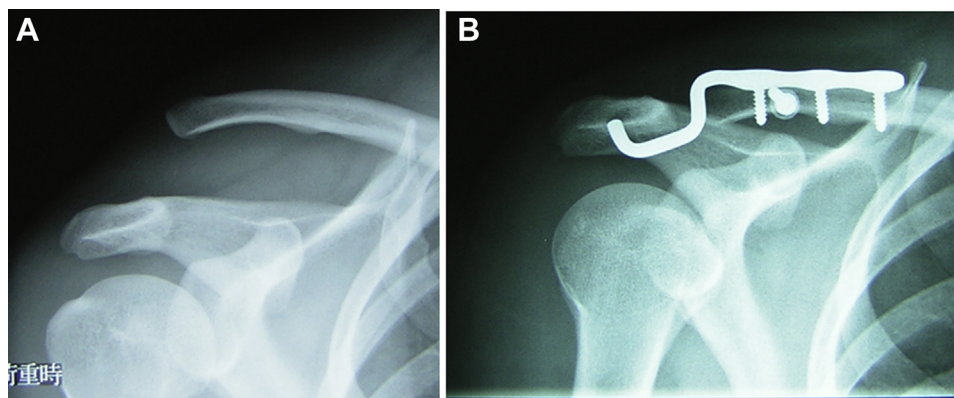


Figure 4 Representative case: 29-year-old male patient. (A) Preoperative radiograph. (B) Postoperative radiograph.

conservative to surgical and delineate the choice of surgical procedure when transitioning to address old ACJ injuries. In addition, the effect of severity on the choice of surgical methods could not be examined.

Conclusion

For the treatment of ACJ separations, only 11 members performed conservative treatment regardless of severity and approximately 95% of respondents performed surgery as appropriate. Furthermore, >70% of members considered a Rockwood classification of type 3 or higher as an indication for surgery, and 37% of the total respondents chose the modified Cadenat method. However, the selection of surgical methods may change in the future owing to the popularization of arthroscopic surgery.

Disclaimer

The authors, their immediate families, and any research foundations with which they are affiliated have not received any financial payments or other benefits from any commercial entity related to the subject of this article.

References

- Balke M, Schneider MM, Shafizadeh S, Bathis H, Bouillon B, Banerjee M. Current state of treatment of acute acromioclavicular joint injuries in Germany: is there a difference between specialists and non-specialists? A survey of German trauma and orthopaedic department. *Knee Surg Sports Traumatol Arthrosc* 2015;23:1447–52. <https://doi.org/10.1007/s00167-013-2795-2>.
- Balog TP, Min KS, Rumley JC, Wilson DJ, Arrington ED. Arthroscopic anatomic coracoclavicular ligament repair using a 6-strand suture tape and cortical button construct. *Arthrosc Tech* 2015;4:e757–61. <https://doi.org/10.1016/j.eats.2015.07.023>.
- Beitzel K, Cole MP, Apostolakis J, Solovyova O, Judson CH, Ziegler CG, et al. Current concepts in the treatment of acromioclavicular joint dislocations. *Arthroscopy* 2013;29:387–97. <https://doi.org/10.1016/j.arthro.2012.11.023>.
- Bishop JY, Kaeding C. Treatment of the acute traumatic acromioclavicular separation. *Sports Med Arthrosc Rev* 2006;14:237–45. <https://doi.org/10.1097/01.jsa.0000212330.32969.6e>.
- Bosworth BM. Acromioclavicular separation: new method of repair. *Surg Gynecol Obstet* 1941;73:866–71.
- Cadenat FM. The treatment of dislocations and fractures of the outer end of the clavicle. *Int Clin* 1917;1:145–69.
- De Beer J, Schaer M, Latendresse K, Raniga S, Moor BK, Zumstein MA. BiPOD arthroscopic acromioclavicular repair restores bidirectional stability. *Orthopedics* 2017;40:e35–43. <https://doi.org/10.3928/01477447-20160915-01>.
- Dewar FP, Barrington TW. The treatment of chronic acromioclavicular dislocation. *J Bone Joint Surg Br* 1965;47:32–5.
- Gumina S, Carbone S, Postacchini F. Scapular dyskinesia and SICK scapula syndrome in patients with chronic type 3 acromioclavicular dislocation. *Arthroscopy* 2009;25:40–5. <https://doi.org/10.1016/j.arthro.2008.08.019>.
- Longo UG, Ciuffreda M, Rizzello G, Mannering N, Maffulli N, Denaro V. Surgical versus conservative management of type 3 acromioclavicular dislocation: a systematic review. *Br Med Bull* 2017;122:31–49. <https://doi.org/10.1093/bmb/ldx003>.
- Neviaster JS. Acromioclavicular dislocation treated by transfer of coracoacromial ligament. *Arch Surg* 1952;64:292–7.
- Nissen CW, Chatterjee A. Type 3 acromioclavicular separation: results of a recent survey on its management. *Am J Orthop (Belle Mead NJ)* 2007;36:89–93.
- Oki S, Matsumura N, Iwamoto W, Ikegami H, Kiriya Y, Nakamura T, et al. The function of the acromioclavicular and coracoclavicular ligaments in shoulder motion: a whole-cadaver study. *Am J Sports Med* 2012;40:2617–26. <https://doi.org/10.1177/0363546512458571>.
- Phemister DB. The treatment of dislocation of the acromioclavicular joint by open reduction and threaded wire fixation. *J Bone Joint Surg* 1942;24:166–8.
- Rockwood CA Jr. Injuries to the acromioclavicular joint: subluxations and dislocations about the shoulder. In: Rockwood Jr CA, Green DP, editors. *Fractures in adults*. Philadelphia: JB Lippincott–Raven; 1984. p. 860–910.
- Salzmann GM, Walz L, Buchmann S, Glabgyl P, Venjakob A, Imhoff AB. Arthroscopically assisted 2-bundle anatomical reduction of acute acromioclavicular joint separations. *Am J Sport Med* 2010;38:1179–87. <https://doi.org/10.1177/0363546509355645>.
- Scheibel M, Droschel S, Gerhardt C, Kraus N. Arthroscopically assisted stabilization of acute high-grade acromioclavicular joint separations. *Am J Sports Med* 2011;39:1507–16. <https://doi.org/10.1177/0363546511399379>.
- Song HS, Song SY, Yoo YS, Lee YB, See YJ. Systematic residual instability with grade II acromioclavicular injury. *J Orthop Sci* 2012;17:437–42. <https://doi.org/10.1007/s00776-012-0239-3>.
- Song T, Yan X, Ye T. Comparison of the outcome of early and delayed surgical treatment of complete acromioclavicular joint dislocation. *Knee Surg Sports Traumatol Arthrosc* 2016;24:1943–50. <https://doi.org/10.1007/s00167-014-3225-9>.
- Takase K. MRI evaluation of coracoclavicular ligament injury in acromioclavicular joint separation. *Eur J Orthop Surg Traumatol* 2011;21:563–8. <https://doi.org/10.1007/s00590-011-0760-7>.
- Takase K, Yamamoto K. Arthroscopic procedures and therapeutic results of anatomical reconstruction of the coracoclavicular ligaments for acromioclavicular joint dislocation. *Orthop Traumatol Surg Res* 2016;102:583–7. <https://doi.org/10.1016/j.orth.2016.04.011>.
- Tauber M. Management of acute acromioclavicular joint dislocation: current concepts. *Arch Orthop Trauma Surg* 2013;133:985–95. <https://doi.org/10.1007/s00402-013-1748-z>.
- Tosy MD, Mead NC, Sigmond HM. Acromioclavicular separations, useful and practical classification for treatment. *Clin Orthop Relat Res* 1963;28:111–9.
- Trainer G, Arciero RA, Mazzocca AD. Practical management of grade 3 acromioclavicular separations. *Clin J Sport Med* 2008;18:162–6. <https://doi.org/10.1097/JSM.0b013e318169f4c1>.
- Weaver JK, Dunn HK. Treatment of acromioclavicular injuries, especially complete acromioclavicular separation. *J Bone Joint Surg Am* 1972;54A:1187–94.