



Contents lists available at ScienceDirect

International Journal of Surgery Case Reports

journal homepage: www.casereports.com

Delayed duodenal stump blow-out following total gastrectomy for cancer: Heightened awareness for the continued presence of the surgical past in the present is the key to a successful duodenal stump disruption management. A case report



K. Vasiliadis^{a,*}, K. Fortounis^a, A. Kokarhidas^a, C. Papavasiliou^a, A. Al Nimer^a, S. Stratilati^b, C. Makridis^a

^a First Surgical Department, General Hospital Papageorgiou, West Ring Road, Nea Efkarpia, GR-56 403 Thessaloniki, Greece

^b Department of Radiology, General Hospital Papageorgiou, West Ring Road, Nea Efkarpia, GR-56 403 Thessaloniki, Greece

ARTICLE INFO

Article history:

Received 20 May 2014

Received in revised form 6 November 2014

Accepted 8 November 2014

Available online 13 November 2014

Keywords:

Duodenal stump blow out

Duodenal stump leakage

Difficult duodenum

Gastrectomy

Tube duodenostomy

ABSTRACT

INTRODUCTION: Duodenal stump disruption remains one of the most dreadful postgastrectomy complications, posing an overwhelming therapeutic challenge.

PRESENTATION OF CASE: The present report describes the extremely rare occurrence of a delayed duodenal stump disruption following total gastrectomy with Roux-en-Y esophagojejunostomy for cancer, because of mechanical obstruction of the distal jejunum resulting in increased backpressure on afferent limb and duodenal stump. Surgical management included repair of distal jejunum obstruction, mobilization and re-stapling of the duodenum at the level of its intact second part and retrograde decompressing tube duodenostomy through the proximal jejunum.

DISCUSSION: Several strategies have been proposed for the successful management post-gastrectomy duodenal stump disruption however; its treatment planning is absolutely determined by the presence or not of generalized peritonitis and hemodynamic instability with hostile abdomen. In such scenario, urgent reoperation is mandatory and the damage control principle should govern the operative treatment.

CONCLUSION: Considering that scientific data about duodenal stump disruption have virtually disappeared from the current medical literature, this report by contradicting the anachronism of this complication aims to serve as a useful reminder for gastrointestinal surgeons to be familiar with the surgical techniques that provide the ability to properly manage this dreadful postoperative complication.

© 2014 The Authors. Published by Elsevier Ltd. on behalf of Surgical Associates Ltd. This is an open access article under the CC BY-NC-ND license (<http://creativecommons.org/licenses/by-nc-nd/3.0/>).

1. Introduction

Duodenal stump disruption (DSD) remains one of the most dreadful postgastrectomy complications, posing an overwhelming therapeutic challenge. This is own not only to its low incidence, which renders it unlikely to be appropriate managed; but also to the devastating consequences resulting from its unsuccessful repair.¹ In fact, in recent studies, DSD associated morbidity rate has reached 84% while its mortality rate ranged between 5% and 16%.^{1,2}

The present study describes the rare occurrence of a delayed DSD following total gastrectomy for cancer because of an acute efferent limb obstruction syndrome resulting in increased

backpressure on afferent limb and duodenal stump. In this report the proximal jejunum to the jejunojejunal anastomosis will be referred as “afferent limb”; while the distal as “efferent limb”.

This case is interesting not only because of the rarity and delayed presentation of DSD, but also because it underlines the need for modern gastrointestinal surgeons to be familiar with the surgical techniques that can provide the ability to properly manage this dreadful postoperative complication.

2. Case presentation

A 66-year-old man was re-admitted to our Department because of colicky periumbilical pain, bilious emesis and frequent passage of loose stools over the previous 4 days. The patient had undergone 45 days earlier in our Department a radical total D2 gastrectomy with a Roux-en-Y esophagojejunostomy for a pT3 pN3a pM0 stage IIIB poorly differentiated adenocarcinoma of the gastric body with

* Corresponding author at: First Department of General Surgery, Papageorgiou Hospital, Nea Efkarpia, GR-56 403 Thessaloniki, Greece. Tel.: +30 2313 323556; fax: +30 2313 323587.

E-mail address: keva@med.auth.gr (K. Vasiliadis).

11/38 lymph node ratio. His postoperative course was uneventful and he was discharged on the 11th postoperative day.

On re-admission physical examination revealed hypovolemia, signs of dehydration, and a tympanous abdomen, tenderness in the epigastrium and periumbilical region with no however signs of peritonitis. Laboratory tests showed alkalosis, hypokalemia, hyponatremia and electrolyte disorders. He was immediately resuscitated with intravenous fluids and nasojejunal tube decompression which obtained large (1.5 L) amount of bilious discharge. Plain film radiography demonstrated findings consistent with mechanical small bowel obstruction (SBO), out of proportion to the colon. Based on clinical presentation, physical examination, and imaging findings a presumed diagnosis of a post-gastrectomy syndrome was made. The patient's symptoms and signs gradually worsened and an urgent abdominal computed tomography (CT) scan was ordered. Multidetector CT scan depicted efferent and afferent limb obstruction and findings suggestive of a DDS (Fig. 1a–d). Following CT, clinical reevaluation revealed abdominal rigidity and bile stained fluid extrusion through a small dehiscence of the upper pole of the patient's surgical wound! This development combined with the patient's clinical condition necessitated an urgent surgical exploration.

The peritoneal cavity was entered through an extended mid-line incision. After adhesiolysis, a markedly swollen afferent and efferent limb was noted in the submesocolic compartment; where there was no free peritoneal bile stained fluid. At the level of the jejunoileal junction a single adhesion was evident between the small bowel and abdominal wall causing kinking and intermittent obstruction to the efferent limb. Lysis of the adhesive band gave way to the bowel content that filled the Roux, efferent and

afferent limbs. Further inspection revealed an intact jejunojejunal anastomosis. Exploration continued to the right supramesocolic compartment. The transverse colon and Roux limb were mobilized exposing the left subphrenic space. The esophagojejunal anastomosis was intact however, the left subphrenic space was occupied with bile stained fluid, which was preoperatively extruding through the defect of the surgical wound. Copious and challenging dissection in a field of dense adhesions between the Roux limb, transverse colon–mesocolon, visceral surface of the liver, gallbladder and hepato-duodenal ligament enabled identification of a completely blown duodenal stump (Fig. 2).

Based on the absence of severe tissue inflammation, it was decided to adequately mobilize the duodenum in a challenging effort to resect the blown stump and re-stapling the duodenum at the level of its unimpaired proximal second part. An extended Lane–Kocher maneuver was performed followed by meticulous detachment of the remaining first and proximal second part of the duodenum from the pancreatic head by ligating small vessels and “fibrous” connections (Fig. 3). Following successful re-stapling of the duodenum, a retrograde decompressing tube duodenostomy was decided intending to lower the intraluminal pressures in the newly performed ultralow DS (Scheme 1). A closed suction drain was placed near the ultra-low DS and the duodenostomy tube was secured to the skin.

The postoperative course was uneventful. The patient tolerated well early postoperative normal oral diet. The duodenostomy catheter was left in dependent drainage for 15 days. Its mean daily output was 57 ml of bilious drainage (range: 135 ml to 10 ml). The output of the closed suction drain was serous having a very low daily output. On the 15th postoperative day a contrast

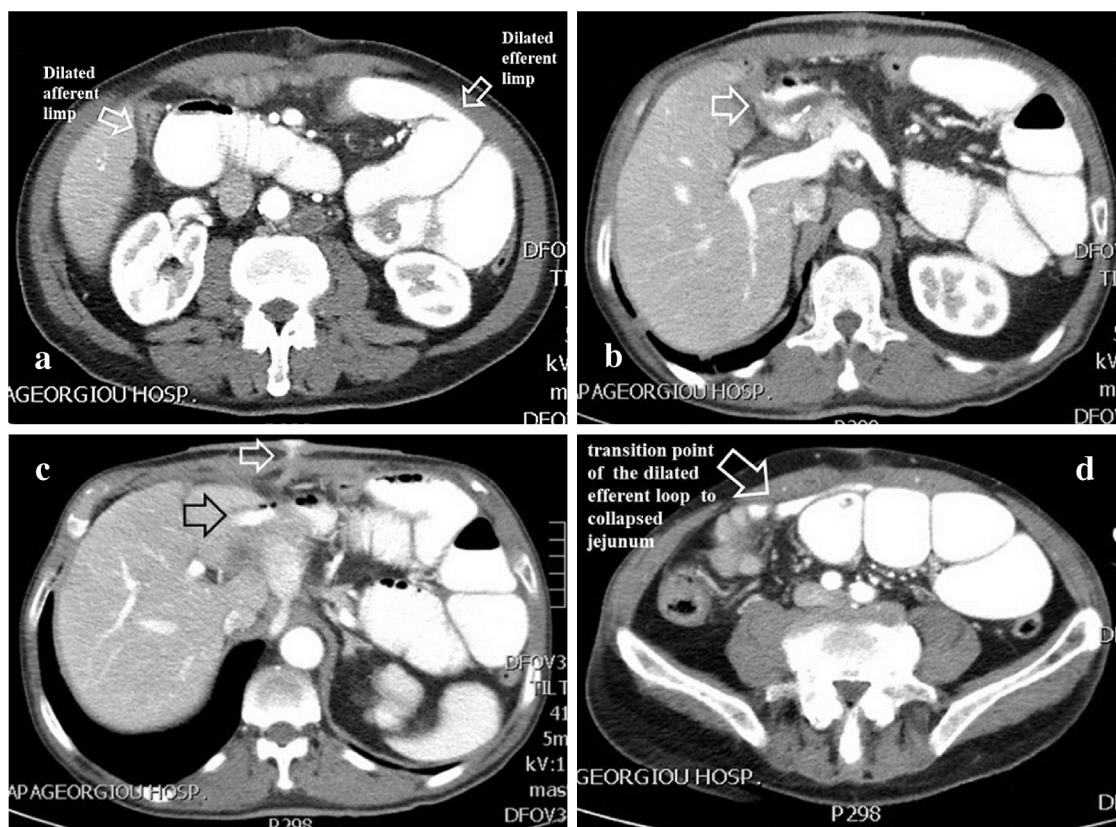


Fig. 1. (a) Multidetector CT scan shows excessive dilatation of the afferent and efferent limbs to the jejunojejunal anastomosis. The afferent limb is opacified by oral contrast while the jejunojejunal anastomosis was intact with no leak of positive oral contrast. (b) Multidetector CT scan depicting a right subhepatic fluid collection surrounding the duodenal stump's staple line infiltrated with air densities (white arrow) suggestive of a DDS. (c) The right subhepatic fluid collection surrounding the DS staple line (black arrow) corresponding to the extravasated oral contrast which is extruding (white arrow) through a small dehiscence in the upper pole of the upper midline surgical wound. (d) The dilated efferent loop is depicted to have a transition point to collapsed jejunum at approximately the level of jejunoileal junction.

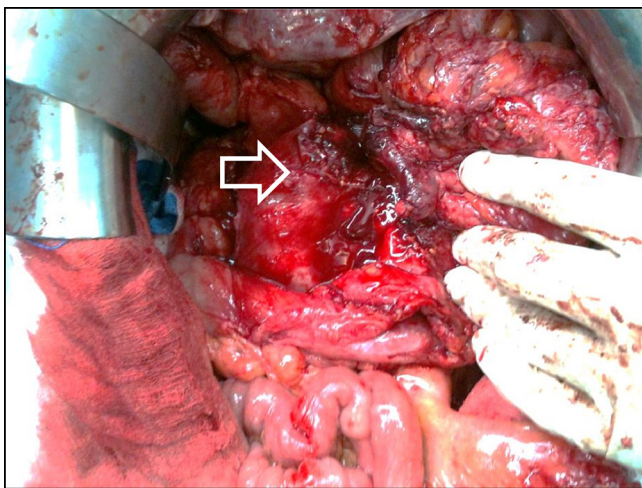


Fig. 2. Copious and challenging dissection in a field of dense adhesions between the Roux limb, transverse colon–mesocolon, visceral surface of the liver, gallbladder and hepatoduodenal ligament enabled identification of a completely blown duodenal stump.

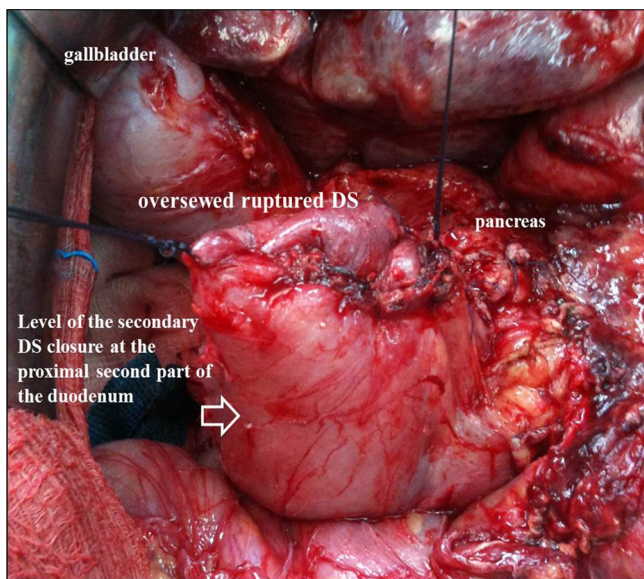
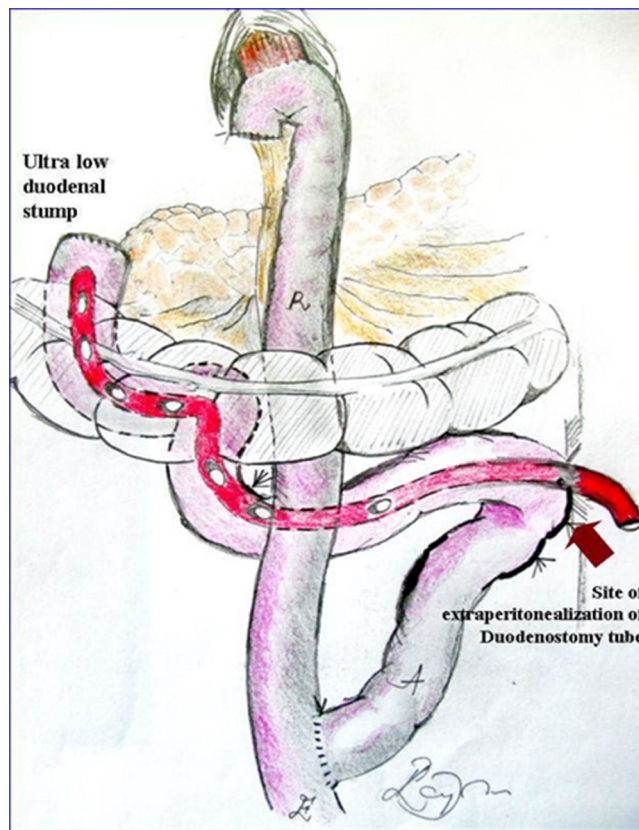


Fig. 3. After suturing the blown stump an extended Lane–Kocher maneuver mobilizing the pancreaticoduodenal complex was performed followed by the detachment of the remaining first and proximal second part of the duodenum from the pancreatic head by implementing meticulous dissection and ligation of small mesenteric vessels and “fibrous” connections.

study through the duodenostomy tube confirmed an intact duodenal stump allowing the complete removal of the duodenostomy catheter. The closed suction drain remained in place continuing to drain a minimal amount of serous fluid and was completely removed in the following day. The fistula tract of the duodenostomy tube closed spontaneously 24 h following tube removal and the patient was discharged on the 17th postoperative day. He is currently doing well, and he is under adjuvant therapy (Graphic 1).

3. Discussion

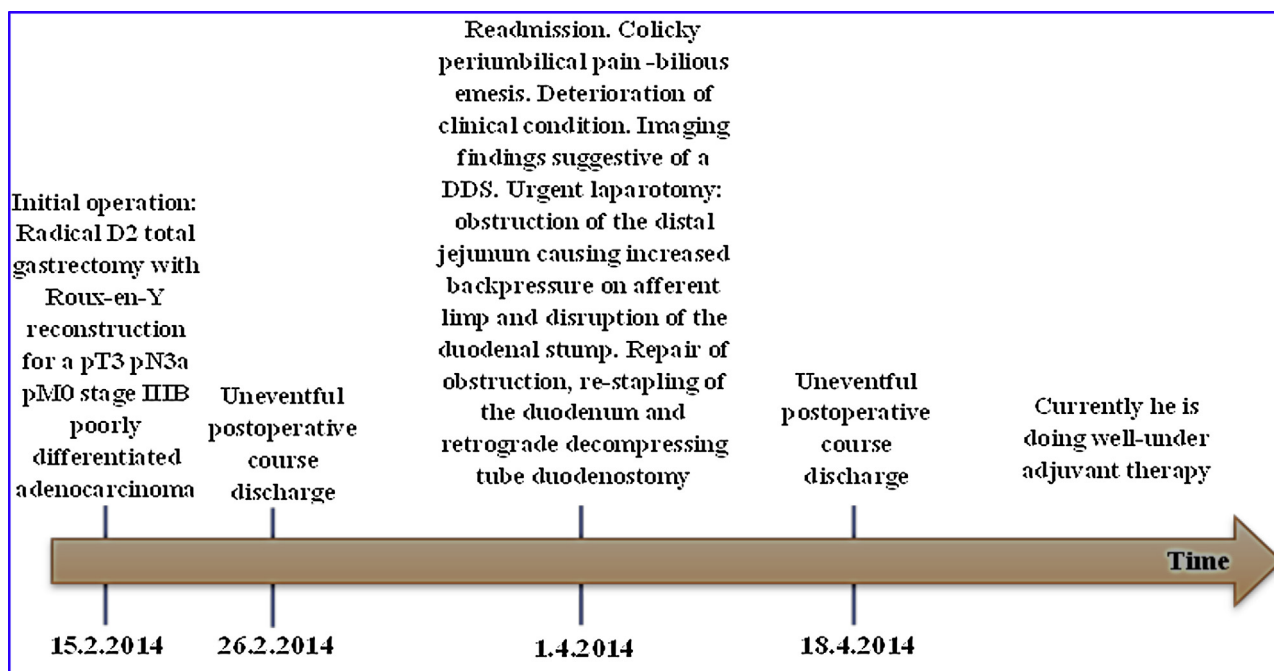
Various factors have been implicated in the pathogenesis of DSD following gastric resection. Inadequate duodenal stump (DS) closure, inappropriate usage of cautery, excessive dissection (skeletonization for more than 2 cm of the first part of the duodenum) or overzealous suturing of the DS resulting in ischemia and necrosis,



Scheme 1. Drawing of the modified retrograde decompressing tube duodenostomy performed as last step of the procedure. Approximately 15 cm distal to the ligament of Treitz, the antimesenteric border of the proximal jejunum was brought to the upper left lateral parietal peritoneum. A seromuscular triangular pursestring suture was then placed in the selected site of the proximal jejunum and the rubber tube was entered retrograde into the duodenal lumen via a small enterotomy in the center of the pursestring. Before passing the catheter into the duodenal lumen, multiple side holes were added to the intraluminal portion of the catheter to ensure effectual function. The pursestring was tied around the tube and the rubber tube was externalized through a tunnel in the left lateral abdominal wall. The pursestring suture was finally continued as a continuous circumferential stitch approximating the bowel wall and the parietal peritoneum, extraperitonealizing the entry site of the catheter into the bowel lumen. In order to avoid proximal jejunum volvulus its part immediately aborally to the duodenostomy, was sutured for a length of 5 cm to the left lateral parietal peritoneum.

submucosal hematoma in the resection line of the DS, local pancreatitis, incorrect drain position, and acute afferent limb syndrome resulting in hyper-peristalsis, increased pressure and tension on the DS are all included among the important operative factors, which can predispose to the development of DSD. Notwithstanding, these surgical pitfalls can be easily prevented on condition that well-established, proven surgical techniques are precisely employed.³

Invasion of the duodenum from gastric cancer necessitating a more distal resection, results inevitably in an ultralow DS.⁴ In such circumstances safe closure of the DS is tenuous and, therefore, prone to leakage. Despite the fact that the number of gastric cancer encounters with a difficult ultra-low DS is relatively low, upper gastrointestinal surgeons will still encounter this surgical challenge.⁵ Therefore, in such circumstances familiarity with alternative surgical methods such as Nissen closure, end or side tube-duodenostomy and Roux-en-Y end-to-end duodenojejunal anastomosis can provide the ability to successfully overcome the challenging surgical obstacle of the “difficult” DS.⁶ While effective however, all these techniques have certain drawbacks and limitations when indented to be applied to a given surgical scenario. Therefore, depending on intraoperative findings and patients’ condition



Graphic 1. Timeline of the clinical course of the patient.

these therapeutic alternatives must be carefully balanced against each other in order to decide on the appropriate technique that could successfully prevent an impending surgical catastrophe.

In the present case, a standardized surgical technique was employed and all requirements for a safe DS closure have been met. Furthermore, no intraoperative factors predisposing to the development of DSD were encountered. The duodenum was routinely transected with a three row linear stapler oriented parallel to the direction of the pancreatoduodenal arcades. Additionally, as part of our standardized technique; the stapled line was uneventfully buried with interrupted mattress PDS 4.0 sutures. Of note is the delayed occurrence of DSD, given the fact that this complication occurs usually in the immediate postoperative period (between the second and tenth postoperative days).² The delayed development of DSD in this case is probably related to its peculiar pathogenetic mechanism namely; the adhesion-induced kinking and intermittent obstruction of the efferent limb, resulting in increased backpressure on the duodenal stump, which is also an extremely uncommon cause of DSD following Roux-en-Y reconstruction.^{8,9} Unfortunately, adhesion-induced afferent limb obstruction is a rather unpreventable postoperative complication, given that there is no evidence in support of modifications in the type of operation, the method of reconstruction or the use of anti-adhesive agents that might reduce the risk of post-gastrectomy adhesions.

Scanty contemporary data on DSD treatment options are available. This is due to the significant decline in surgical treatment of peptic ulcer disease in the last few decades, which has made once commonplace gastric resections for ulcer disease and their associated complications very rare. In fact, the present day surgeons will operate much less for DSD as compared to their predecessors, which reflect the paucity of scientific data about DSD in the current medical literature. Therefore, much can be learnt from our predecessors' valuable experience. In addition to that, several strategies have been proposed for DSD treatment such as reoperation including tube duodenostomy,⁷ repair with a rectus abdominis muscle flap,¹⁰ closure by a Roux-en-Y duodenojejunostomy,¹¹ pancreatoduodenectomy (PD),¹² pancreas preserving total duodenectomy (PPTD),¹³ or minimally invasive methods including percutaneous

abscess drainage, transhepatic biliary drainage,¹⁴ fistuloscopy,¹⁵ and fistula obliteration by cyanoacrylate or prolamine,¹⁶ or percutaneous transhepatic biliary drainage and occlusion balloon.¹⁷

Virtually, the treatment planning of post-gastrectomy DSD is absolutely determined by the presence or not of generalized peritonitis and hemodynamic instability with hostile abdomen. In such scenario, urgent reoperation is mandatory and the damage control principle should govern the operative treatment as happened in the present case. Advanced and complex procedures such as PD or PPTD under these circumstances are associated with adverse outcomes and in general, they should be reserved as the last surgical resort.¹⁸ Roux en Y duodenojejunostomy,¹⁹ is regarded as a safer alternative to these complex procedures²⁰ however; its effectiveness in conditions with significant tissue inflammation in patients already suffering a hostile abdomen is controversial.²¹ However, Roux en Y duodenojejunostomy appears to be the appropriate choice in cases where the disrupted DS cannot be safely reclosed or the DSD is very large precluding the performance of tube duodenostomy.

End tube duodenostomy is a proved safe and effective alternative for the treatment of DSD following gastrectomy for cancer fitting well in the principle of damage control surgery. End duodenostomy, consisting of the placement of a tube through the secondary closure of the DS is creating a controlled duodenal fistula. This mode of treatment is indicated when the intraoperative conditions prevent safe secondary surgical closure of the DS. However, it should be noted that, following end duodenostomy, persistent fistula drainage may result, and most importantly; the placement of a duodenostomy tube through a secondary closed DS would potentially predispose it to re-leak.²² Nevertheless, tube duodenostomy is a simple technique, does not require an anastomosis and is quickly performed; dealing successfully with an abdominal catastrophe safer than a more complex operation, accomplishing excellent outcomes.⁷

In the present case, secondary peritonitis and wound dehiscence necessitated an urgent re-exploration. The absence of severe tissue inflammation in the operative field permitted adequate mobilization and safe secondary closure of the blown DS. Although

successful re-closure of a disrupted DS is known to be in the majority of cases impossible due to postoperative edema, inflammation, and dense adhesion however; it should be considered as the treatment of choice, provided that the operative conditions favor such a challenging surgical option. The rationale and main advantage of this approach is the fast restoration of the patient's normal daily life and timely administration of adjuvant therapy.

In the present case, following re-stapling of the DS, a modified retrograde decompressing tube duodenostomy was decided with the intention to lower the intraluminal pressures in the ultralow DS, thus preventing its re-leakage. According to this modified technique, the entry site of the catheter into the lumen of the proximal jejunum was extraperitonealized thus avoiding the possibility of intraperitoneal intestinal leakage and permitted safe early removal of the catheter with minimal drainage following its removal. In fact, the fistula tract of the duodenostomy tube closed spontaneously 24 h following tube removal. Although the effectiveness of retrograde decompressing tube duodenostomy is controversial,²³ it seems rather logical to claim that it should be used in a selective fashion as happened in the present case.

Currently, no level I evidence directly compares the various methods of DSD repair. However, historical surgical sense and familiarity with the various methods for the treatment of DSD can provide to the surgical team the ability to successfully manage this devastating complication. By paraphrasing TS Eliot's words in "Tradition and the Individual Talent", one can argue that a heightened awareness for the continued presence of the surgical past in the present is the key to a successful DSD management.

Conflict of interest

No conflict of interest.

Funding

None.

Ethical approval

The patient has been informed and written consent has been obtained from the patient.

Author contributions

Vasiliadis, K.: Study design, data analysis, performed the operation, drawing and writing.

Fortounis, K.: Data collections, data analysis, second operator.

Kokarhidas, A.: Data collections, third operator.

Papavasiliou, C.: Data analysis, study design.

Al Nimer, A.: Data analysis, study design.

Stratilati, S.: Analysis of imaging studies.

Makridis, C.: Approved the final version of the manuscript.

References

- Orsenigo E, Bissolati M, Socci C, Chiari D, Muffatti F, Nifosi J, et al. Duodenal stump fistula after gastric surgery for malignancies: a retrospective analysis of risk factors in a single centre experience. *Gastric Cancer* 2014;(January), <http://dx.doi.org/10.1007/s10120-013-0327-x> [Epub ahead of print].
- Cozzaglio L, Coladonato M, Biffi R, Coniglio A, Corso V, Dionigi P, et al. Duodenal fistula after elective gastrectomy for malignant disease. An Italian retrospective multicenter study. *J Gastrointest Surg* 2010;**14**:805–11.
- Androulakis J, Colborn GL, Skandalakis JE, Skandalakis PN. Embryologic and anatomic basis of duodenal surgery. *Surg Clin North Am* 2000;**80**:171–99.
- Kobayashi A, Nakagohri T, Konishi M, Inoue K, Takahashi S, Itou M, et al. Aggressive surgical treatment for T4 gastric cancer. *J Gastrointest Surg* 2004;**8**:464–70.
- Namikawa T, Hanazaki K. Clinicopathological features of early gastric cancer with duodenal invasion. *World J Gastroenterol* 2009;**15**:2309–13.
- Burch JM, Cox CL, Feliciano DV, Richardson RJ, Martin RR. Management of the difficult duodenal stump. *Am J Surg* 1991;**162**:522–6.
- Isik B, Yilmaz S, Kirimlioglu V, Sogutlu G, Yilmaz M, Katz D. A life-saving but inadequately discussed procedure: tube duodenostomy. Known and unknown aspects. *World J Surg* 2007;**31**:1616–24.
- Wada N, Seki M, Saikawa Y, Satoh M, Toizum A, Tamura Y, et al. Jejunal limb obstruction caused by a cholesterol stone 15 years after a total gastrectomy and 20 years after cholecystectomy: report of a case. *Surg Today* 2000;**30**:181–4.
- Joo YE, Kim HS, Choi SK, Rew JS, Kim HR, Cho CK, et al. Internal hernia presenting as obstructive jaundice and acute pancreatitis. *Scand J Gastroenterol* 2002;**37**:983–6.
- Chander J, Lal P, Ramteke VK. Rectus abdominis muscle flap for high-output duodenal fistula: novel technique. *World J Surg* 2004;**28**:179–82.
- Ujiki GT, Shields TW. Roux-en-Y operation in the management of postoperative fistulas. *Arch Surg* 1981;**116**:614–7.
- Musicant ME, Thompson JC. The emergency management of lateral duodenal fistula by pancreatoduodenectomy. *Surg Gynecol Obstet* 1969;**128**:108–14.
- Eisenberger CF, Knoefel WT, Peiper M. Pancreas-sparing duodenectomy in duodenal pathology: indications and results. *Hepato-Gastroenterology* 2004;**51**:727–31.
- Zarzur JG, Christein JD, Drelichman ER, Oser RF, Hawn MT. Percutaneous transhepatic duodenal diversion for the management of duodenal fistulae. *J Gastrointest Surg* 2008;**12**:1103–9.
- Wong SK, Lam YH, Lau JY, Lee DW, Chan AC, Chung SC. Diagnostic and therapeutic fistuloscopy: an adjuvant management in postoperative fistulas and abscesses after upper gastrointestinal surgery. *Endoscopy* 2000;**32**:311–3.
- Bianchi A, Solduga C, Ubach M. Percutaneous obliteration of a chronic duodenal fistula. *Br J Surg* 1988;**7**:572.
- Cozzaglio L, Cimino M, Mauri G, Ardito A, Pedicini V, Poretti D, et al. Percutaneous transhepatic biliary drainage and occlusion balloon in the management of duodenal stump fistula. *J Gastrointest Surg* 2011;**15**:1977–81.
- Asensio JA, Petrone P, Roldan G, Kuncir E, Demetriades D. Pancreaticoduodenectomy: a rare procedure for the management of complex pancreaticoduodenal injuries. *J Am Coll Surg* 2003;**197**:937–42.
- Cukingnan Jr RA, Culliford AT, Worth Jr MH. Surgical correction of a lateral duodenal fistula with the Roux-Y technique: report of a case. *J Trauma* 1975;**15**:519–23.
- Weigelt JA. Duodenal injuries. *Surg Clin North Am* 1990;**70**:529–39.
- Noble F, Curtis N, Harris S. Risk assessment using a novel score to predict anastomotic leak and major complications after oesophageal resection. *J Gastrointest Surg* 2012;**16**:1083–95.
- Woodman KS. Comment on management of the difficult duodenal stump. *Am J Surg* 1994;**167**:460.
- Tsuei BJ, Schwartz RW. Management of the difficult duodenum. *Curr Surg* 2004;**61**:166–71.

Open Access

This article is published Open Access at sciendo.com. It is distributed under the IJSCR Supplemental terms and conditions, which permits unrestricted non commercial use, distribution, and reproduction in any medium, provided the original authors and source are credited.