

Ultrasound risk evaluation of thyroid nodules that are “unspecified” in the 2015 American Thyroid Association management guidelines

A retrospective study

Luying Gao, MD, Xuehua Xi, MB, Juanjuan Wang, MB, Xiao Yang, MD, Ying Wang, MD, Shenling Zhu, MD, Xingjian Lai, MD, Xiaoyan Zhang, MD, Ruina Zhao, MD, Bo Zhang, MD*

Abstract

This study sought to assess the malignant risks of “unspecified” thyroid nodules; that is, nodules that were not of a type described in the 2015 American Thyroid Association (ATA) guidelines.

We retrospectively reviewed medical records and ultrasound (US) data for 1808 consecutive patients with 2614 thyroid nodules who underwent thyroidectomy between January 2015 and December 2015. Nodules with US features that did not satisfy the criteria for any risk category in the 2015 ATA guidelines were defined as “unspecified” nodules. These thyroid nodules were retrospectively assessed using the Thyroid Imaging, Reporting and Data System proposed by Kwak (Kwak-TIRADS) and the American College of Radiology Thyroid Imaging, Reporting and Data System (ACR-TIRADS).

There were 70 “unspecified” nodules (2.7%, 70/2614), and 18.6% (13/70) of these nodules were malignant. The percentages of nodules with Kwak-TIRADS grades 4a, 4b and 4c were 53.3%, 40.0%, and 6.7%, respectively. The percentages of nodules with ACR-TIRADS grades TR2, TR3, TR4, and TR5 were 5.7%, 2.9%, 70.0%, and 21.4%, respectively. Among the “unspecified” nodules, there were significantly more nodules in Kwak-TIRADS categories 4b and 4c in the malignant pathology group than in the benign pathology group ($P < .01$).

Our results imply that “unspecified” thyroid nodules based on the ATA guidelines could partly be evaluated using the Kwak-TIRADS and that the ATA guidelines could incorporate more accurate malignant risk stratification.

Abbreviations: ACR TI-RADS = American College of Radiology Thyroid Imaging Reporting and Data System, ATA = American Thyroid Association, FNAB = fine-needle aspiration biopsy, Kwak-TIRADS = Thyroid Imaging Reporting and Data Systems proposed by Kwak, ROC = receiver operating characteristic, TI-RADS = Thyroid Imaging Reporting and Data Systems, US = Ultrasound.

Keywords: 2015 American Thyroid Association management guideline, thyroid imaging reporting and data system, thyroid nodules, ultrasound

1. Introduction

Thyroid nodules are an extremely common medical problem with a prevalence of 19% to 68%, depending on the study population.^[1] Ultrasound (US) is useful not only for detecting nodules but also for discriminating between benign and

malignant lesions; it is also used to guide fine-needle aspiration biopsy (FNAB) and additional treatment.^[2,3] Recently, the 2015 American Thyroid Association (ATA) management guidelines provided up-to-date risk categorizations of thyroid nodules from very low to high suspicion of malignancy based on sonographic features.^[4] Studies have demonstrated the diagnostic efficiency of these guidelines.^[5,6] However, certain thyroid nodules with potentially worrisome US features (hyper-/isoechogenic solid or partially cystic nodules with irregular margins, microcalcifications, taller-than-wide shape, rim calcifications with a small extrusive soft tissue component and/or extra-thyroidal extension) cannot be categorized based on the 2015 ATA guidelines. These nodules were defined as “unspecified”. In this study, we attempted to stratify such nodules using other established guidelines, including the Thyroid Imaging, Reporting and Data System proposed by Kwak (Kwak-TIRADS) and the American College of Radiology Thyroid Imaging, Reporting and Data System (ACR-TIRADS).^[7,8]

2. Materials and methods

2.1. Patients

The work has been reported in line with the STROBE criteria.^[9]

Institutional review board approval of Peking Union Medical College Hospital ethics review committee was obtained for this

Editor: Valerio D'Orazi.

This study was supported by a grant from National Natural Science Foundation of China (No. 81541131)

The authors have nothing to disclose.

The authors report no conflicts of interest.

Department of Ultrasound, Chinese Academy of Medical Sciences & Peking Union Medical College Hospital, Beijing, China.

* Correspondence: Bo Zhang, Department of Ultrasound, Peking Union Medical College Hospital, 9 Dongdansantiao, Beijing 100730, China (e-mail: thyroidus@163.com).

Copyright © 2018 the Author(s). Published by Wolters Kluwer Health, Inc. This is an open access article distributed under the terms of the Creative Commons Attribution-Non Commercial-No Derivatives License 4.0 (CCBY-NC-ND), where it is permissible to download and share the work provided it is properly cited. The work cannot be changed in any way or used commercially without permission from the journal.

Medicine (2018) 97:52(e13914)

Received: 10 October 2018 / Received in final form: 28 November 2018 /

Accepted: 29 November 2018

<http://dx.doi.org/10.1097/MD.0000000000013914>

retrospective study, and the requirement for informed consent was waived.

We retrospectively reviewed medical records and US data for 1994 consecutive patients with 3004 thyroid nodules who underwent thyroidectomy at our center between January 2015 and December 2015. Among this initial cohort, only patients who satisfied the following criteria were included:

- (1) thyroidectomy was conducted;
- (2) complete preoperative US of thyroid nodules was performed; and
- (3) surgical pathology data were available.

A total of 1808 patients with 2614 nodules were included.

2.2. Thyroid US examination and retrospective evaluation

All US examinations were performed with a Philips HDI 5000 or iU 22 machine (Philips Healthcare, Eindhoven, Netherlands) or a GE Logiq 9 or Logiq 7 machine (GE Healthcare, Milwaukee, WI) equipped with a 5 to 12 MHz or 8 to 15 MHz linear-array transducer. US images were retrospectively reviewed and classified into different risk categories by 2 fellow radiologists who had experience with thyroid US and were blinded to the patients' clinical data and pathology results. Any inconsistencies were discussed until agreement was reached. All thyroid nodules were first evaluated using the US-based classifications in the 2015 ATA guidelines.^[4]

According to the 2015 ATA guidelines, irregular margins (infiltrative, microlobulated or spiculated), microcalcifications, taller-than-wide shape, rim calcifications with a small extrusive soft tissue component and extra-thyroidal extension are considered suspicious US features. Hyperechoic/isoechoic solid/partially-cystic nodules with 1 or more of these suspicious US features that did not satisfy the criteria for any risk category in the 2015 ATA guidelines were defined as "unspecified" thyroid nodules. (The suggested standards for thyroid nodule risk stratification in the ATA guidelines are as follows. High suspicion: a solid hypoechoic nodule or a solid hypoechoic component of a partially cystic nodule with at least 1 suspicious trait, including irregular margins (infiltrative or microlobulated), microcalcifications, taller-than-wide shape, rim calcifications with a small extrusive soft tissue component, and/or evidence of extra-thyroidal extension. Intermediate suspicion: a hypoechoic solid nodule with smooth margins without microcalcifications, extra-thyroidal extension, or taller-than-wide shape. Low suspicion: an isoechoic or hyperechoic solid nodule or partially cystic nodule with eccentric solid areas without microcalcifications, irregular margins, extra-thyroidal extension, or taller-than-wide shape. Very low suspicion: spongiform or partially cystic nodules without any of the sonographic features described in the low, intermediate or high suspicion patterns. Benign: purely cystic nodules.)

All "unspecified" thyroid nodules were reevaluated using the Kwak-TIRADS and the ACR-TIRADS.^[7,8] According to the Kwak-TIRADS, suspicious US features include solidity, hypoechoogenicity or marked hypoechoogenicity, microlobulation to irregular margins, microcalcifications or mixed calcifications, taller-than-wide shape, and nonparallel shape; only nodules with a longest dimension greater than 1 cm were assessed. Thyroid Imaging Reporting and Data System (TIRADS) category 2 includes benign lesions such as simple cysts, spongiform nodules, isolated macrocalcifications, and typical subacute thyroiditis. Nodules without any suspicious US features were classified as

TIRADS category 3, and other nodules were classified as TIRADS category 4a (with 1 suspicious US feature), 4b (with 2 suspicious US features), 4c (with 3 or 4 suspicious US features), or 5 (with 5 suspicious US features). In the ACR-TIRADS, points are assigned for each US feature in a nodule, with more suspicious features awarded additional points. The point total determines a nodule's ACR-TIRADS level, which ranges from TR1 (benign) to TR5 (high suspicion of malignancy). In this system, US features are categorized as benign (TR1, 0 points), not suspicious (TR2, 2 points), mildly suspicious (TR3, 3 points), moderately suspicious (TR4, 4–6 points), or highly suspicious (TR5, 7 points or more) for malignancy. Other points are awarded as follows. Composition: cystic or almost completely cystic, 0 points; spongiform, 0 points; mixed cystic and solid, 1 point; solid or almost completely solid, 2 points. Echogenicity: anechoic, 0 points; hyperechoic or isoechoic, 1 point; hypoechoic, 2 points; very hypoechoic, 3 points. Shape: wider than tall, 0 points; taller than wide, 3 points. Margin: smooth, 0 points; ill-defined, 0 points; lobulated or irregular, 2 points; extra-thyroidal extension, 3 points. Echogenic foci: no foci or large comet-tail artifacts, 0 points; macrocalcifications, 1 point; peripheral (rim) calcifications, 2 points; punctate echogenic foci, 3 points.

2.3. Statistical analysis

Quantitative data are presented as the mean \pm standard deviation (SD). Qualitative data are presented as frequencies. The Shapiro-Wilk test was used to determine whether data were normally distributed. For nonparametric data, differences between groups were analyzed using the Mann-Whitney *U* test. For parametric data, an unpaired *t* test was used to evaluate differences between groups. The chi-square test with Yates' correction and Fisher's exact test were used to compare categorical variables. Receiver operating characteristic (ROC) curve analyses were used to calculate diagnostic value. Differences with $P < .05$ were regarded as statistically significant. Statistical analyses were performed using SPSS software (version 19.0, SPSS, Chicago, IL).

3. Results

Seventy of the 2614 thyroid nodules (2.7%) did not satisfy the criteria for any category defined by the 2015 ATA guidelines and were classified as "unspecified". The "unspecified" thyroid nodules included 57 benign nodules and 13 malignant nodules; thus, 18.6% of these nodules were malignant.

3.1. Clinical features of patients with "unspecified" thyroid nodules

Clinical features of patients with "unspecified" nodules are listed in Table 1. There were 52 females (74.3%) and 18 males (25.7%) with such nodules; these patients' median age was 52.7 years. The mean age of patients with benign nodules was 55.8 years, and the mean age of patients with malignant nodules was 39.3 years. Patient age significantly differed between the malignant and benign groups ($P < .01$).

3.2. US features of "unspecified" thyroid nodules

We observed US features of nodules. The malignancy rate was higher for nodules that were partially cystic with eccentric solid areas than for nodules that were partially cystic with non-eccentric solid areas ($P < .05$). The malignancy rates for solid and

Table 1
Summary of clinical and US features.

Parameter	Final pathologic finding		Total	Malignancy rate (%)	P value
	Benign	Malignant			
No. of nodules	57	13	70		
Age (y, mean, range)	55.8 (27–78)	39.3 (27–58)	52.7		.00
Sex (male:female)	14:43	4:9	18:52		.73
Size, cm	2.6	1.9	2.5		.14
US features					
Composition					.17
Solid	20 (35.1%)	7 (53.8%)	27 (38.6%)	25.9	
Partially cystic	37 (64.9%)	6 (46.2%)	43 (61.4%)	14.0	
With eccentric solid	13 (35.1%)	5 (83.3%)	18 (41.9%)	27.8	.04
With non-eccentric solid	24 (64.9%)	1 (16.7%)	25 (58.1%)	4.0	
Echogenicity					.58
Isoechoic	50 (87.7%)	12 (92.3%)	62 (88.6%)	19.4	
Hyperechoic	7 (12.3%)	1 (7.7%)	8 (11.4%)	12.5	
Margin					.27
Microlobulated or irregular	30 (52.6%)	5 (38.5%)	35 (50%)	14.3	
Well circumscribed	27 (47.4%)	8 (61.5%)	35 (50%)	22.9	
Calcification					.73
None	15 (26.3%)	2 (15.4%)	17 (24.3%)	11.8	
Microcalcifications or mixed	38 (66.7%)	11 (84.6%)	49 (70%)	22.4	
Macrocalcifications or eggshell	4 (7.0%)	0	4 (5.7%)	0	
Shape					.34
Taller-than-wide shape	1 (1.7%)	1 (7.7%)	2 (2.9%)	50.0	
Wider-than-tall shape	56 (98.3%)	12 (92.3%)	68 (97.1%)	17.6	
Vascularity					.64
None	6 (10.5%)	2 (15.4%)	8 (11.4%)	25.0	
Peripheral	5 (8.8%)	1 (7.7%)	6 (8.6%)	16.7	
Internal	6 (10.5%)	2 (15.4%)	8 (11.4%)	25.0	
Peripheral and internal	40 (70.2%)	8 (61.5%)	48 (68.6%)	16.7	
Kwak-TIRADS					.03
TIRADS 4a	2 (20.0%)	30 (60.0%)	32 (53.3%)	6.3	
TIRADS 4b	7 (70.0%)	17 (34.0%)	24 (40.0%)	29.2	
TIRADS 4c	1 (10.0%)	3 (6.0%)	4 (6.7%)	25.0	
ACR-TIRADS					.00
TR2	0 (0.0%)	4 (7.0%)	4 (5.7%)	0.0	
TR3	0 (0.0%)	2 (3.6%)	2 (2.9%)	0.0	
TR4	9 (69.2%)	40 (70.2%)	49 (70.0%)	18.4	
TR5	4 (30.8%)	11 (19.3%)	15 (21.4%)	26.7	

ACR-TIRADS = American College of Radiology Thyroid Imaging Reporting and Data System, Kwak-TIRADS, Thyroid Imaging, Reporting and Data System proposed by Kwak, US = ultrasound.

partially cystic nodules did not statistically differ ($P > .05$). For the examined thyroid nodules, echogenicity, margin, calcification, shape, and vascularity did not affect malignancy rates (Table 1).

“Unspecified” nodules exhibited 3 US patterns (Fig. 1). Pattern A refers to iso-/hyperechoic solid nodules with at least 1 suspicious US feature; Pattern B refers to iso-/hyperechoic partially cystic nodules with eccentric solid areas and at least 1 suspicious US feature; Pattern C includes iso-/hyperechoic partially cystic nodules with non-eccentric solid areas and at least 1 suspicious US feature. The malignancy rates for nodules with Pattern A, Pattern B, and Pattern C were 25.9%, 27.8%, and 4.0%, respectively. The malignancy rate was higher for Pattern B nodules than for Pattern C nodules (27.8% vs 4.0%, $P = .04$). The malignancy rate was not statistically higher for Pattern A nodules than for Pattern B and Pattern C nodules (25.9% vs 14.0%, $P = .17$).

3.3. The diagnostic efficiency of Kwak-TIRADS and ACR-TIRADS for “unspecified” nodules

The “unspecified” nodules were categorized based on Kwak-TIRADS and ACR-TIRADS categories. The percentages of

thyroid nodules with Kwak-TIRADS grades of 4a, 4b and 4c were 53.3%, 40.0%, and 6.7%, respectively. The percentages of thyroid nodules categorized as ACR-TIRADS TR2, TR3, TR4, and TR5 were 5.7%, 2.9%, 70.0%, and 21.4%, respectively.

With respect to Kwak-TIRADS categories, the malignancy rates for nodules of Kwak-TIRADS categories 4a, 4b, and 4c were 6.3%, 29.2%, and 25.0%, respectively (Table 1). The ROC curves demonstrated that the area under the curve (AUC) of ACR TIRADS category were 0.70 (95% confidence interval, 0.53–0.87). Kwak-TIRADS category was not associated with the malignancy risk of “unspecified” nodules ($P = .052$). Malignancy rates were much higher for nodules of Kwak-TIRADS categories 4b and 4c than for nodules of Kwak-TIRADS category 4a ($P = .01$).

The malignancy rates for nodules in ACR-TIRADS categories TR2, TR3, TR4 and TR5 were 0.0%, 0.0%, 18.4%, and 26.7%, respectively (Table 1). The ROC curves demonstrated that the area under the curve (AUC) of ACR TIRADS category were 0.41 (95% confidence interval 0.24–0.57, $P = .29$). ACR-TIRADS category was not associated with the malignancy risk of “unspecified” nodules ($P = .29$). The malignancy risks for nodules in ACR-TIRADS categories TR4 and TR5 did not significantly differ ($P > .05$).

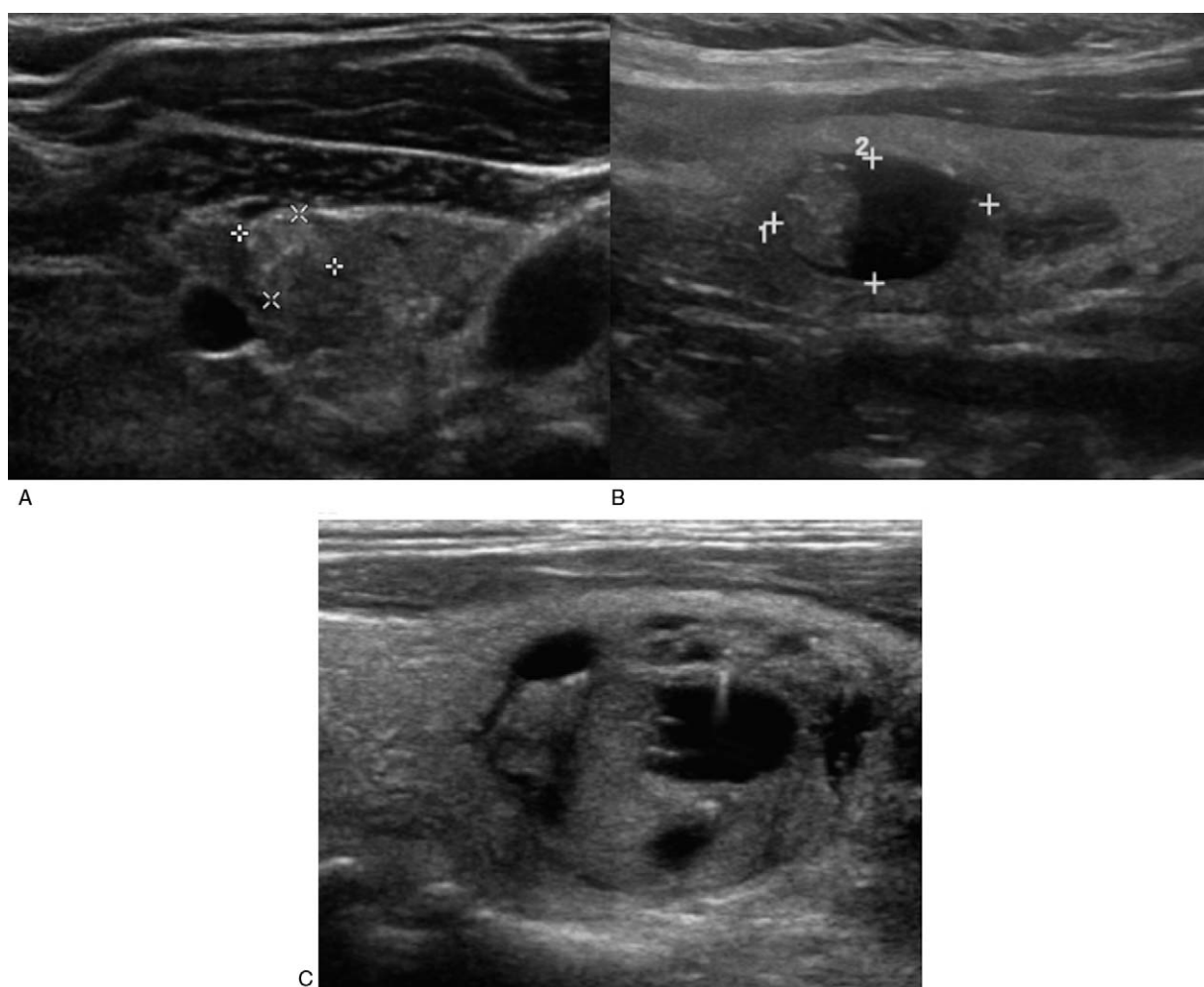


Figure 1. Three “unspecified” patterns. A. US shows a hyperechoic nodule with microcalcifications and taller-than-wide shape. B. US shows an isoechoic, partially cystic nodule with eccentric solid areas accompanied by microcalcifications. C. US shows an isoechoic, partially cystic nodule with non-eccentric solid areas accompanied by microcalcifications.

4. Discussion

Similarly to TIRADSs, the most recent ATA guidelines for thyroid nodules and thyroid cancer suggest that irregular margins, microcalcifications, and taller-than-wide shape are suspicious US features. The 2015 ATA guidelines, which include risk stratification, are useful for clinical practice; however, certain worrisome US features cannot be categorized using the risk stratification approach described in these guidelines. Our results showed that 2.7% of thyroid nodules did not satisfy the criteria for any risk category described in the 2015 ATA guidelines and were therefore classified as “unspecified”. This study also demonstrated that “unspecified” nodules exhibited a relatively high risk of malignancy (18.6%), which is within the 10% to 20% range proposed for intermediate suspicion patterns in the 2015 ATA guidelines. Similarly to our investigation, studies by Yoon and Xu have indicated that “unspecified” nodules have a relatively high risk of malignancy.^[5,6]

Since Kwak established a TIRADS, this system has been applied to assess thyroid nodules. In our study, the malignancy rates for “unspecified” nodules in Kwak-TIRADS categories 4a, 4b, and 4c were 6.3%, 29.2%, and 25.0%, respectively. The malignancy rate was much higher for nodules in Kwak-TIRADS categories 4b and 4c than for nodules in Kwak-TIRADS category 4a. Recently, the ACR-TIRADS suggested risk stratification

based on a constellation of sonographic features. In our study, the malignancy rates for nodules in ACR-TIRADS categories TR2, TR3, TR4, and TR5 were 0.0%, 0.0%, 18.4%, and 26.7%, respectively, but the number of nodules in ACR-TIRADS categories TR4 and TR5 in the malignant pathology group and the benign pathology group did not significantly differ. This result indicates that the ACR-TIRADS should not be adopted for differentiating “unspecified” nodules.

Hyper- to isoechoic features have been proven to be helpful for discriminating between benign and malignant nodules; such features, in particular, are regarded as relatively benign compared with hypoechogenicity.^[10–12] However, our results showed that hyper-/isoechoic solid nodules with suspicious US features had a relatively high risk of malignancy (25.9%). Our results are comparable to previously reported findings showing that iso-/hyperechoic solid nodules with any degree of calcification had a malignancy risk of 24.7%.^[13] With respect to risk stratification, such nodules should be regarded as nodules with intermediate suspicion patterns according to the present ATA guidelines. FNAB should be considered for “unspecified” nodules, using similar standards to those applied for nodules with indeterminate suspicion patterns.

The malignancy rate of non-eccentric iso-/hyperechoic partially cystic nodules with suspicious US features was 4.0%, which

was within the range expected for nodules with low suspicion patterns. Lee found that the risk of malignancy was lower if the solid portion of a nodule was non-eccentric.^[14] Eccentric iso-/hyperechoic partially cystic nodules with suspicious US features had a malignancy risk of 27.8%, which was within the range expected for nodules with intermediate suspicion patterns. Therefore, it is important to distinguish partially cystic nodules with non-eccentric solid areas from other partially cystic nodules.

There are several limitations of our study. First, all analyses were based on recorded static images; therefore, nodules may have been misclassified when assessed using the TIRADSs and the ATA guidelines. Second, all of the nodules were from patients who underwent thyroidectomy, which may have led to selection bias.

5. Conclusions

Our study showed that more accurate malignancy risk stratification could be incorporated into the 2015 ATA guidelines, and this change could help improve the performance of these guidelines.

Author contributions

Conceptualization: Bo Zhang.

Data curation: Luying Gao, Xuehua Xi, Juanjuan Wang, Ying Wang, Ruina Zhao.

Formal analysis: Luying Gao, Juanjuan Wang, Ying Wang.

Funding acquisition: Bo Zhang.

Methodology: Juanjuan Wang.

Project administration: Bo Zhang.

Supervision: Ying Wang, Xiaoyan Zhang.

Writing – original draft: Luying Gao.

Writing – review & editing: Xuehua Xi, Xiao Yang, Shenling Zhu, Xingjian Lai, Xiaoyan Zhang, Ruina Zhao, Bo Zhang.

References

- [1] Guth S, Theune U, Aberle J, et al. Very high prevalence of thyroid nodules detected by high frequency (13 MHz) ultrasound examination. *Eur J Clin Invest* 2009;39:699–706.

- [2] Leenhardt L, Erdogan MF, Hegedus L, et al. European thyroid association guidelines for cervical ultrasound scan and ultrasound-guided techniques in the postoperative management of patients with thyroid cancer. *Eur Thyroid J* 2013;2:147–59.
- [3] Yi KH. The revised 2016 Korean thyroid association guidelines for thyroid nodules and cancers: differences from the 2015 American thyroid association guidelines. *Endocrinol Metab* 2016; 31:373–8.
- [4] Haugen BR, Alexander EK, Bible KC, et al. American thyroid association management guidelines for adult patients with thyroid nodules and differentiated thyroid cancer: the American thyroid association guidelines task force on thyroid nodules and differentiated thyroid cancer. *Thyroid* 2015;26:1–33.
- [5] Xu T, Gu JY, Ye XH, et al. Thyroid nodule sizes influence the diagnostic performance of TIRADS and ultrasound patterns of 2015 ATA guidelines: a multicenter retrospective study. *Sci Rep* 2017; 7:43183.
- [6] Yoon JH, Lee HS, Kim EK, et al. Malignancy risk stratification of thyroid nodules: comparison between the thyroid imaging reporting and data system and the 2014 American thyroid association management guidelines. *Radiology* 2016;278:917–24.
- [7] Kwak JY, Han KH, Yoon JH, et al. Thyroid imaging reporting and data system for US features of nodules: a step in establishing better stratification of cancer risk. *Radiology* 2011;260:892–9.
- [8] Tessler FN, Middleton WD, Grant EG, et al. ACR thyroid imaging, reporting and data system (TI-RADS): white paper of the ACR TI-RADS committee. *J Am Coll Radiol* 2017;14:587–95.
- [9] Von EE, Altman DG, Egger M, et al. STROBE Initiative: The Strengthening the Reporting of Observational Studies in Epidemiology (STROBE) statement: guidelines for reporting observational studies. *BMJ* 2014;336:35–135.
- [10] Horvath E, Majlis S, Rossi R, et al. An ultrasonogram reporting system for thyroid nodules stratifying cancer risk for clinical management. *J Clin Endocrinol Metab* 2009;94:1748–51.
- [11] Park JY, Lee HJ, Jang HW, et al. A proposal for a thyroid imaging reporting and data system for ultrasound features of thyroid carcinoma. *Thyroid* 2009;19:1257–64.
- [12] Moon WJ, Jung SL, Lee JH, et al. Thyroid Study Group, Korean Society of Neuro and Head and Neck Radiology: Benign and malignant thyroid nodules: US differentiation—multicenter retrospective study. *Radiology* 2008;247:762–70.
- [13] Seo H, Na DG, Kim JH, et al. Ultrasound-based risk stratification for malignancy in thyroid nodules: a four-tier categorization system. *Eur Radiol* 2015;25:2153–62.
- [14] Lee MJ, Kim EK, Kwak JY, et al. Partially cystic thyroid nodules on ultrasound: probability of malignancy and sonographic differentiation. *Thyroid* 2009;19:341–6.