

Case Report

Strawberry gingivitis: A diagnostic feature of gingival Wegener's granulomatosis!

R. Heera¹, Kanaram Choudhary², V. T. Beena³, Rency Simon³

¹Department of Oral Pathology and Microbiology, Government Dental College, Kottayam, ³Department of Oral Pathology and Microbiology, Government Dental College, Trivendrum, Kerala, ²Department of Oral Pathology and Microbiology, Vaidic Dental College and Research Centre, Daman (UT), India

ABSTRACT

Wegener's granulomatosis (WG) is an immunologically mediated inflammatory disease characterized by granulomatous vasculitis of the upper and lower aerodigestive tracts together with glomerulonephritis. We are reporting a rare case of gingival WG that presented with erythematous and painful generalized gingival enlargement. Correlation of histopathology with routine hematoxylin and eosin and special stains [Grocott-Gomori methenamine-silver nitrate and Periodic Acid Schiff (PAS)], Mantoux test, peripheral blood smear and clinical presentation were established in diagnosing this rare entity. By the above-mentioned procedures and methodology, we have arrived at the diagnosis of Wegener's granulomatosis limited to the upper aerodigestive tract. Therefore, the aim of reporting this case was to emphasize that, the dental surgeon often being the first person to examine the oral cavity, should be familiar with the typical appearance of gingival WG as "strawberry gingivitis," its clinical course as well as diagnostic parameters and adequate management. To the best of our knowledge, this is the first reported case of WG manifesting as "strawberry gingivitis" in the Indian population.

Key Words: Strawberry gingivitis, Wegener's granulomatosis, granulomatous inflammation

Received: January 2012

Accepted: July 2012

Address for correspondence:

Dr. Kanaram Choudhary,
Senior Lecturer, Department
of Oral Pathology and
Microbiology, Vaidic Dental
College and Research Centre
Daman (UT), India.
E-mail: drk84choyal@gmail.
com

INTRODUCTION

Wegener's granulomatosis (WG) is an immunologically mediated uncommon multisystem disorder, first described by Friedrich Wegener in 1936. However, detailed description of WG is given by Godman and Churg.^[1] While WG typically affects the upper and lower airways, and frequently the kidneys, it may involve any organ system. The granulomatous inflammation and vasculitis can affect the mouth, eyes, ear, nose, throat, lungs, skin and kidneys. The disease predominantly affects adults with mean age of 41 years, but there is no significant gender

predilection.^[2] In 1990, the American College of Rheumatology (ACR) proposed the following four specific criteria for the classification of WG: (1) oral ulcers or nasal discharge, (2) the presence of nodules, fixed infiltrates or cavities on a chest radiograph, (3) abnormal urinary sediment (red blood cell casts or more than five red blood cells per high power field) and (4) granulomatous inflammation on biopsy. For the diagnosis of WG, a minimum of two criteria should be fulfilled from the above-mentioned (ACR 1990) criteria.^[1,3] Because the dental surgeon is often the first person to examine the oral cavity, he should be familiar with the classical appearance of gingival WG as "strawberry gingivitis," its clinical course as well as diagnostic parameters and adequate management.

CASE REPORT

A 54-year-old male patient was referred to the Government Dental College, Trivandrum, South

Access this article online



Website: www.drj.ir

India in December 2010, with soreness of gingiva and malaise. Clinical examination revealed painful and erythematous generalized gingival enlargement involving the entire maxillary gingiva and focal areas of involvement in the mandibular gingiva, with the appearance simulating “ripe strawberry” [Figure 1]. The gingiva was very friable and easily bled on touch. There was grade III mobility of maxillary anterior teeth that had spontaneously exfoliated on the subsequent visit. The remaining teeth had grade I mobility. The oral hygiene status was poor and all teeth were stained with tobacco stain. The patient was a chronic smoker and alcoholic, but quit the habits 1 year back. Panoramic radiograph revealed generalized bone loss, which was more pronounced in the maxillary anterior region. Examination of specific organ systems revealed that the patient had prostatic hypertrophy with slight elevation of prostate-specific antigen. He was on medication

(Tamsulosin + Finasteride) for prostatic hypertrophy, but the serum creatinine level was normal. The patient was not on any other drugs except those mentioned above. There was no history of dyspnea, fever, night sweat or allergy to any substance. Evaluation of serum cytoplasmic antineutrophilic cytoplasmic antibody (cANCA) was done, and it was within normal limits. Peripheral blood smear showed neutrophilia and leucocytosis. Further, the patient was referred to the Department of Internal Medicine for systemic evaluation, but reports were inconclusive.

Microscopic evaluation of biopsy from the gingival tissue showed parakeratinised stratified squamous epithelium with pseudoepitheliomatous hyperplasia and intraepithelial abscess, as well as abscess penetrating into the surface of the epithelium. Connective tissue stroma was densely collagenous with dense diffuse infiltration of neutrophils, plasma

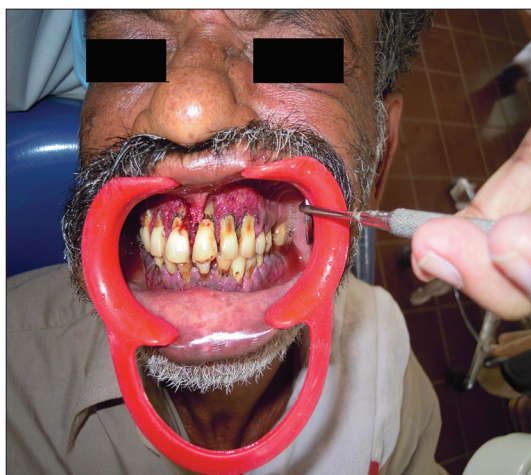

Figure 1: Clinical picture showing “ripe strawberry gingiva”

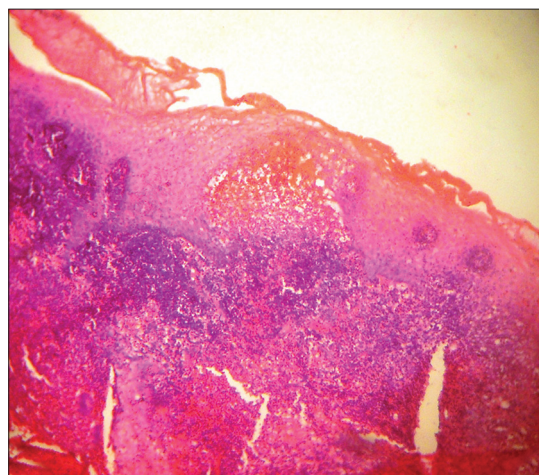


Figure 2: Histopathological picture showing intraepithelial abscess and abscess penetrating to the surface (×10)

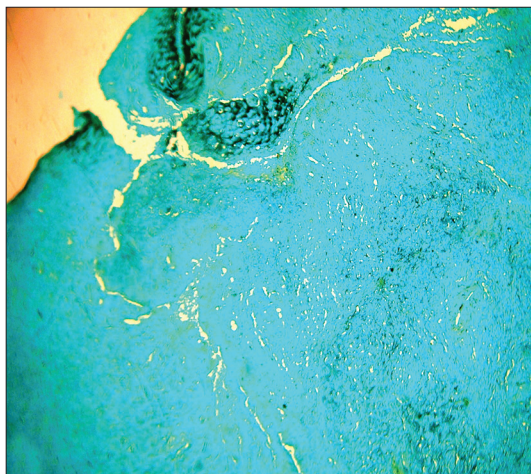


Figure 3: Grocott-Gomori methenamine-silver nitrate stain of section (×10)

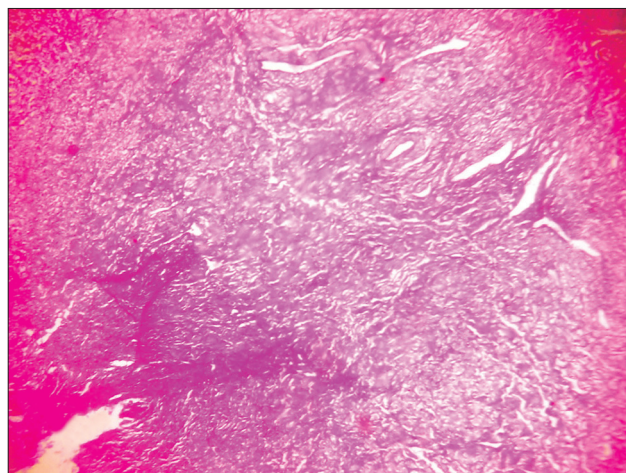


Figure 4: Periodic acid Schiff stain of section (×10)

cells and few macrophages, particularly around the blood vessels, with dilatation and thickening of blood vessels. At one end of the section, some multinucleate giant cells were also seen [Figure 2].

Histopathological differential diagnoses of tuberculosis, deep fungal infection and WG were made. Special staining by Grocott-Gomori methenamine-silver nitrate [Figure 3] and PAS [Figure 4] were done, which were negative for fungal organisms. Mantoux test was done, which was negative and thus tuberculosis was ruled out.

By the above-mentioned clinical features, lab investigations and histopathological examination with special stains, we arrived at the diagnosis of WG limited to the upper aerodigestive tract. The patient has been started on Prednisolone 20 mg/day on divided and tapering dose for 1 week with morning doses of 10 mg after proper systemic evaluation in the Department of Periodontology. To give symptomatic relief, local steroid as well astringing agents was also advised. The patient felt symptomatically better after 1 week of follow-up. After that, the dose of Prednisolone was tapered to 10 mg/day in dividing doses with 5 mg of morning dose; unfortunately, the patient did not turn up for the follow-up.

DISCUSSION

WG is a rare disease with multisystem involvement, although oral presentation is very rare. Only 6% of the cases were presented with oral manifestation, which were in advanced stage of the disease and are rarely an indicator of the disease. Otorhinolaryngological involvement is more common with destruction of nasal septum, resulting in palatal perforation and progressive sensorineural hearing loss. Ophthalmic symptoms may manifest as epiphora due to involvement of the nasolacrimal duct. Lesion of the skin manifests as purpura, nodules and ulcers, and has been reported in about 46% of the affected patients and in 13% of the affected patients at the onset of disease. However, limited forms of the disease have been reported, in which only one or two organ systems have been involved.^[1,3]

The oral lesions may manifest either as mucosal ulcer on the tongue, buccal mucosa, gums and palate, or as gingival hyperplasia with classical "strawberry gingivitis." However, Cawson^[4] suggested that other lesions may also occur, such as ulceration of the palate by extension from the nose, where destruction

of the nasal septum may develop. It may also occur as small ulcer-like apthae, diffuse ulcerative stomatitis and spontaneous exfoliation of the teeth, as seen in our case.^[1,3,4]

Crohn's disease and sarcoidosis, deep fungal infection (candida, histoplasmosis and paracoccidioidomycosis), tuberculosis, other granulomatous infections like midline lethal granuloma, midline NK/T-cell lymphomas, other anti-neutrophil cytoplasmic antibody (ANCA)-positive vasculitis, drug-induced gingival enlargement and, rarely, cicatricial pemphigoid (CP) or mucous membrane pemphigoid should be included in the differential diagnosis of WG.^[1,3-6]

Gingival manifestations of WG may have a clinical appearance similar to that of gingival leukemic infiltrates. In the reported case, a peripheral blood smear examination was performed and leukemia was ruled out. Presence of multinucleated giant cells in the histopathology prompted for ruling out tuberculosis and deep fungal infection; hence, Mantoux test, bacterial polymerase chain reaction, special staining with Grocott-Gomori methenamine-silver nitrate and PAS were performed.

In the case presented, diagnosis of WG was made according to the criteria given by the American Association of Rheumatology, after careful exclusion of the above-mentioned lesions by appropriate systemic evaluation, lab investigation and referring the previous reported case with similar clinical and histopathological reports. Our case also fulfilled two criteria of the ACR 1990, including gingival ulceration, which appeared like "strawberry gingivitis," and granulomatous lesion in gingival biopsy.

Most authors acknowledge that the clinicopathological complex of "strawberry gums" and the accompanying histopathological features of pseudoepitheliomatous hyperplasia, intraepithelial abscess penetrating the surface epithelium, microabscesses in connective tissue stroma and multinucleate giant cells are "highly suggestive" of WG. It was also suggested that there was no association of the features of this complex with any other disease process and, in an appropriate clinical setting, they are so characteristic of gingival WG as to be virtually diagnostic, particularly as the classic criteria of vasculitis, granulomata and necrosis occur only rarely in gingival biopsy specimens.^[6] The diagnosis of WG was made in the case presented based on these particular combination of clinical and histopathologic findings.

The serological tests helped only to reinforce the clinical impression of a systemic inflammatory process and did not confirm the diagnosis of WG. The cANCA titer, arguably the most useful investigation in cases of WG, was non-contributory in our case. Even the presence of the nasal lesion could not be considered diagnostic.^[1,6] Although few cases of WG have been reported with classical presentation of “strawberry gingivitis” in the literature, in the recent literature search, a case of gum hypertrophy initially diagnosed as acute myeloid leukemia turned out to be WG, which was reported by Kundu and Gadpayl in 2011.^[7] But, no case has been reported with classical presentation of strawberry gingivitis in the Indian population. Thus, the case reported herein turned out to be the first one.

Different treatment protocols were given, including prednisolone, prednisolone and cyclophosphamide (CYC) and azothiopurine (AZT). Glucocorticoids combined with CYC or methotrexate (MTX) are the only two regimens that have thus far been shown to induce remission of active WG affecting a major organ. Patients with alveolar hemorrhage, rapidly progressive glomerulonephritis, central nervous system disease or other manifestations that are immediately life threatening should initially be treated with CYC and glucocorticoids. Once remission has been induced, consideration can be given to stopping CYC and beginning AZA or MTX treatment to maintain remission. Maintenance therapy should be based on medication, contraindications and toxicity profiles, on the patient's relapse and disease history, and on the physician's experience with each medication. Monitoring and prevention of therapeutic toxicity play an important role in overall patient management. This includes pneumocystis prophylaxis and osteoporosis prevention regimens, with concurrent glucocorticoid treatment. Some authors also suggested co-trimoxazole to avoid the side-effects of immunosuppressive therapy. Although substantial progress has been made, challenges remain in the search for newer and better regimens that reduce disease relapse and therapeutic toxicity. Good prognosis with long-term remissions has been reported with combination therapy.^[8-10] The reported case responded with steroid therapy.

If left untreated, WG is often fatal within the first year of onset. Mean survival is reported as 5 years for

untreated cases. The condition has a more favorable prognosis in the absence of renal involvement.^[5]

CONCLUSION

The characteristic gingival lesion with the combination of histopathology might be diagnostic of WG, and early diagnosis accompanied by aggressive treatment is important for a better outcome in this potentially lethal disease.

ACKNOWLEDGMENT

The authors would like to thank Dr. Mangesh Datir, Junior Resident, Department of Periodontology, for providing the treatment details and clinical image of the patient.

REFERENCES

1. Stewart C, Cohen D, Bhattacharyya I, Scheitler L, Riley S, Calamia K, *et al.* Oral manifestations of Wegener's granulomatosis: A report of three cases and a literature review. *J Am Dent Assoc* 2007;138:338-48.
2. Hoffman GS, Kerr GS, Leavitt RY, Hallahan CW, Lebovics RS, Travis WD, *et al.* Wegener granulomatosis: An analysis of 158 patients. *Ann Intern Med* 1992;116:488-98.
3. Reboll-Ferrer RM, Zapater-Latorre E, Calabuig-Crespo C, Basterra-Alegria J. Wegener's granulomatosis: Description of a case with oral manifestation. *Med Oral Patol Oral Cir Bucal* 2010;15:e601-4.
4. Rajendran R, Sivapathsundharam B, editors. *Shafer Textbook of Oral Pathology*. 6th ed. Gurgaon: Elsevier; 2009. p. 670-1.
5. Lourenço SV, Nico MM. Strawberry gingivitis: An isolated manifestation of Wegener's granulomatosis? *Acta Derm Venereol* 2006;86:90-1.
6. Napier SS, Allen JA, Irwin CR, McCluskey DR. Strawberry gums: A clinicopathological manifestation diagnostic of Wegener's granulomatosis? *J Clin Pathol* 1993;46:709-12.
7. Kundu BK, Gadpayl AK. Gum hypertrophy – A manifestation. *J IACM* 2011;12:76-9.
8. Yılmaz A, Ocal S, Sezer E, İnönü H, Yemenici H, Seyfikli Z. An unusual case of Wegener's granulomatosis with tongue involvement. *Tuberk Toraks* 2009;57:352-5.
9. Kumar A, Pandhi A, Menon A, Sharma SK, Pande JN, Malaviya AN. Wegener's granulomatosis in India: Clinical features, treatment and outcome of twenty-five patients. *Indian J Chest Allied Sci* 2001;43:197-204.
10. Langford CA. Wegener's granulomatosis: Current and upcoming therapies. *Arthritis Res Ther* 2003;5:180-91.

How to cite this article: Heera R, Choudhary K, Beena VT, Simon R. Strawberry gingivitis: A diagnostic feature of gingival Wegener's granulomatosis!. *Dent Res J* 2012;9:123-6.

Source of Support: Nil. **Conflict of Interest:** None declared.