



Contents lists available at ScienceDirect

## International Journal of Surgery Case Reports

journal homepage: [www.casereports.com](http://www.casereports.com)

## Surgical management of late bullet embolization from the abdomen to the right ventricle: Case report



Ramos Mayo Alan Elison\*, Diaz Elizondo Jose Antonio, Segura Marin Hector, Lopez Garnica Dolores, Treviño Garza Francisco Xavier

Escuela de Medicina, Instituto Tecnológico y de Estudios Superiores de Monterrey, Monterrey, Avenida Morones Prieto 3000, Colonia Los Doctores, CP 64710, Mexico

### ARTICLE INFO

#### Article history:

Received 25 June 2017

Received in revised form 29 August 2017

Accepted 30 August 2017

Available online 4 September 2017

#### Keywords:

Bullet embolization

Right ventricle foreign body

Migrating foreign bodies

Case report

### ABSTRACT

**INTRODUCTION:** Secondary embolus from gun projectile is a rare entity, it represents a clinical and therapeutic dilemma because the potential complications involving central and peripheral circulation. Each case reported in the literature represents a challenge because their unique and different clinical scenarios. **PRESENTATION OF CASE:** We present the management of a 33-year-old man with past history of a gunshot wound on left flank with no evidence of any exit wounds, treated with exploratory laparotomy without removing the gunshot bullet from the abdomen. The patient presents 6 years later with non-productive cough and retrosternal pain with no other symptoms; the patient underwent a chest x-ray, electrocardiogram, thoracoabdominal CT, echocardiogram and cardiac catheterization and showed a bullet in the right ventricular floor. The projectile was extracted by sternotomy with extracorporeal circulation through the right atrium, without any complications.

**DISCUSSION:** In 1834, Thomas David reported for the first time a wood-fragment embolization. There have been reported less than 200 cases including embolization of other materials; most of the gunshot bullet embolization cases reported on literature were reported after war. Clinical manifestations are associated with the anatomical site of embolism and mortality rate for a retained bullet is 6% associated with complication in 25% of cases. Mortality rate decreases to 1–2% if the bullet is removed.

**CONCLUSION:** There are no established guidelines about the management of migrating foreign bodies or bullets, however, conservative, endovascular and surgical management have been proposed. In the cases of bullet embolization to the thoracic cavity, surgery represents a safe, low risk approach with high success rates.

© 2017 The Authors. Published by Elsevier Ltd on behalf of IJS Publishing Group Ltd. This is an open access article under the CC BY-NC-ND license (<http://creativecommons.org/licenses/by-nc-nd/4.0/>).

## 1. Introduction

Secondary embolus from gun projectile is a rare entity with few published cases in the literature. It represents a clinical and therapeutic dilemma because of the potential complications involving central and peripheral circulation, including pulmonary complications [1,2]. There have been reported less than 200 cases including embolization of other materials [3,4]. Clinical manifestations are associated with the anatomical site of embolism and mortality rate for a retained bullet is 6% associated with complication in 25% of cases. Mortality rate decreases to 1–2% if the bullet is removed [5]. We present a case of a retained and late bullet embolization, from the abdominal cavity to the right ventricle. Treated conservatively initially and six years later after receiving a penetrating gunshot

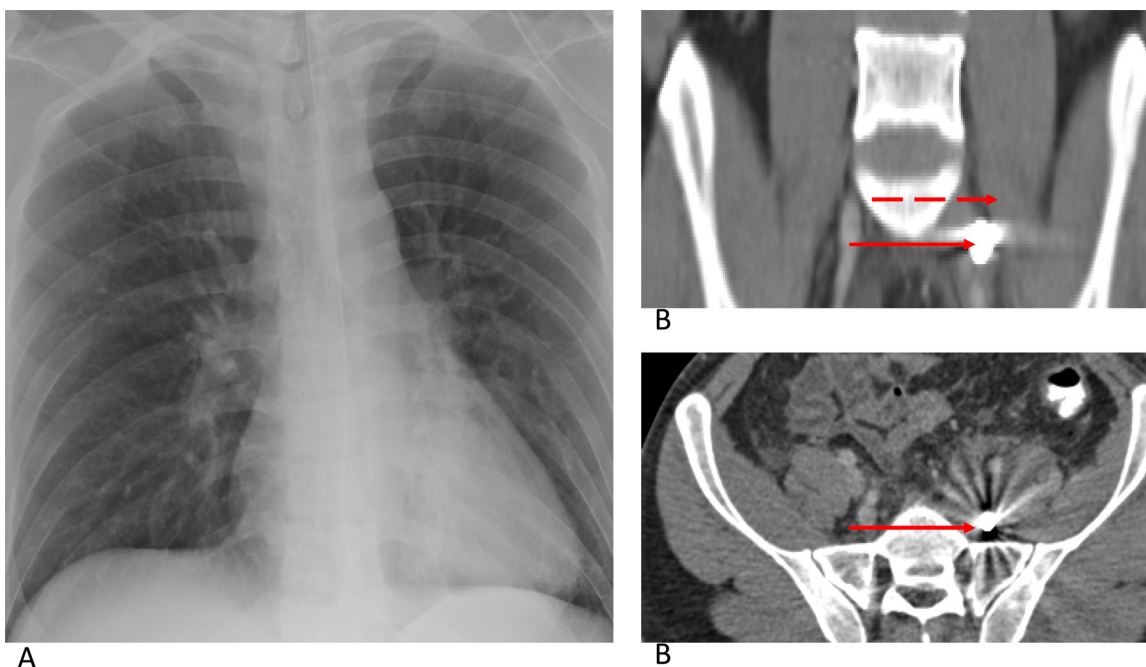
trauma, a sternotomy was performed. This patient was treated in a private practice hospital by a cardiothoracic surgeon.

## 2. Case report

A 33-year-old man with no personal, family or psychosocial history presented to the emergency department after receiving a gunshot wound on left flank with no evidence of any exit wounds. The patient had stable vital signs and no clinical data of abdominal tenderness at admission. Abdominal CT showed free intra-abdominal fluid and a gunshot bullet on the pelvic cavity medial to the iliopsoas muscle, the chest x-ray showed no abnormalities (Fig. 1). An exploratory laparotomy was performed finding 2500 ml of blood in the abdomen. A grade I and III vascular lesions were found in the jejunum mesentery and left iliac vein respectively; and a grade II intestinal lesion in the distal sigmoid. All the lesions were repaired and the gunshot bullet was not extracted because of hemodynamic instability at the moment. At that time,

\* Corresponding author at: Avenida Morones Prieto 3000, Colonia Los Doctores, CP 64710, Monterrey, Nuevo Leon, Mexico.

E-mail addresses: [alan.erm@hotmail.com](mailto:alan.erm@hotmail.com), [alanramos8524@gmail.com](mailto:alanramos8524@gmail.com) (R.M. Alan Elison).

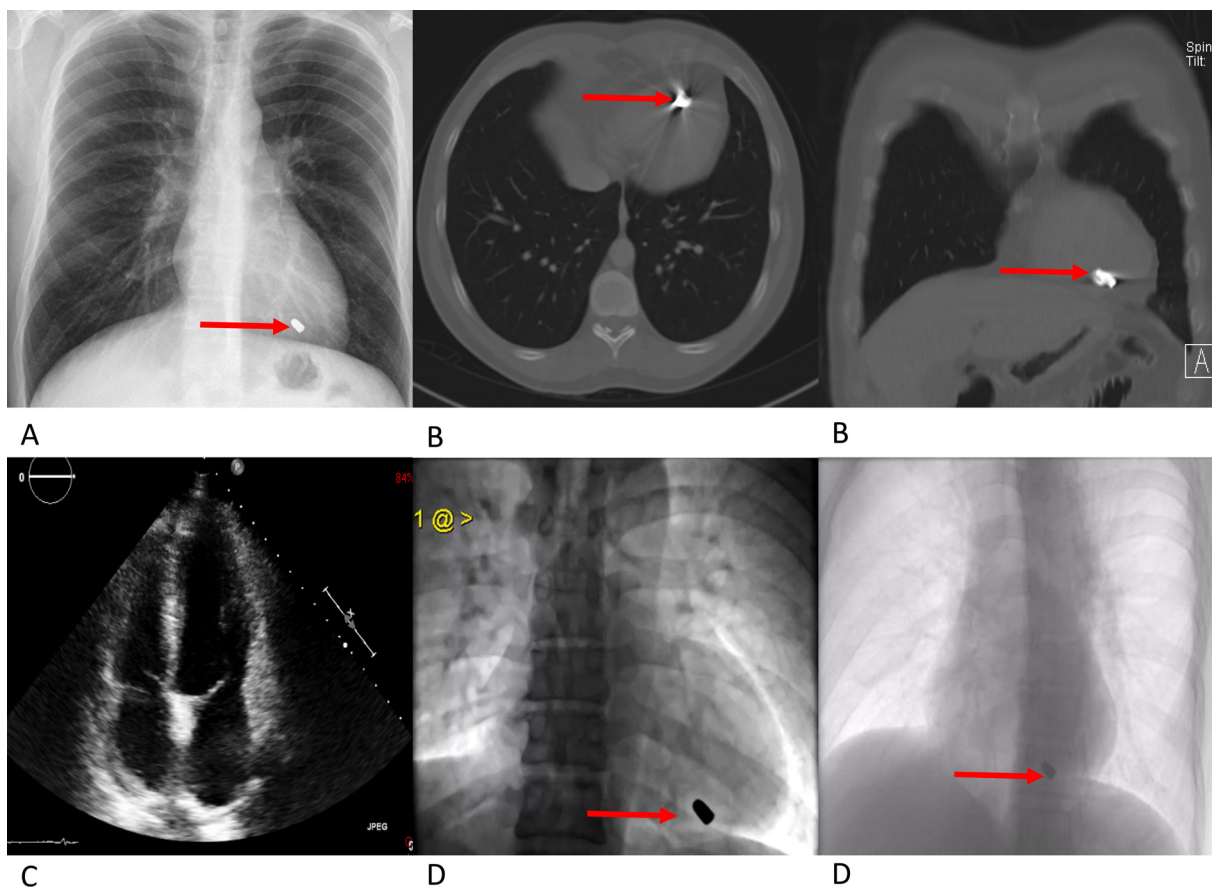


**Fig. 1.** (A) Chest X ray showing no abnormalities. (B) Abdominal CT showing a bullet (red arrow) medial to the iliopsoas muscle (red dashed arrow).

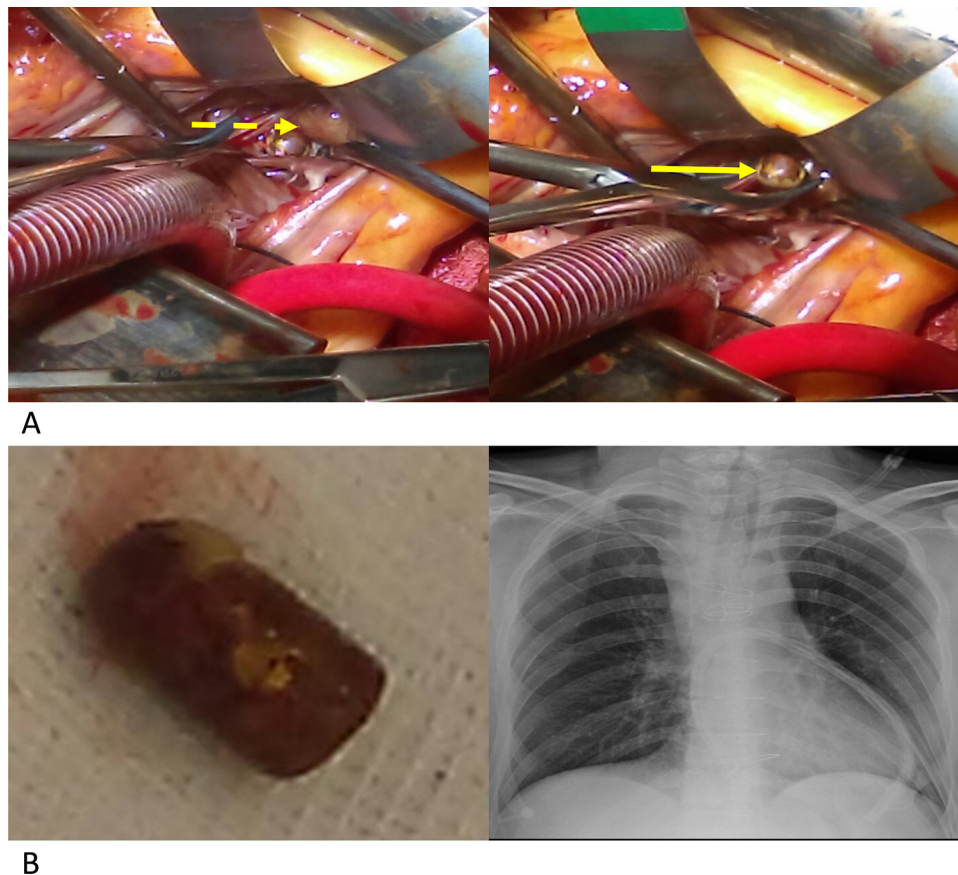the patient was treated by a general surgeon in a private practice hospital.

The patient presents 6 years later with non-productive cough and retrosternal pain with no other symptoms. Physical exploration was non-remarkable. A chest x-ray and thoracoabdominal

CT showed a radiopaque artefact on the ventricular floor. An EKG, transthoracic echocardiogram and cardiac catheterization were performed showing no disruptions or alterations in the cardiac anatomy and physiology (Fig. 2).



**Fig. 2.** (A) Chest X ray, (B) Thorax CT and (D) Cardiac catheterization showing and artefact or bullet on the ventricular floor (red arrow). (C) Echocardiogram and (D) Cardiac catheterization showed no abnormalities in cardiac anatomy or physiology.



**Fig. 3.** (A) Bullet (yellow arrow) extraction from ventricular septum (yellow dashed arrow). (B) Projectile 20 × 10 mm. (C) Chest X ray after surgical procedure.

Because of the high risk for pulmonary embolization, surgical exploration was planned. An sternotomy was performed by a cardiothoracic surgeon, the patient was submitted to extracorporeal circulation, the projectile was identified in the ventricular septum and it was extracted through an incision in the right atrium without presenting any complication associated to the procedure. The projectile measured 20 × 10 mm (Fig. 3).

The patient had complete recovery from surgery and didn't need ventilatory or dynamic support during its course. He was discharged 6 days after surgery with full resolution of the symptoms and without any complication. Six-month follow up at the clinic was uneventful.

### 3. Discussion

In 1834, Thomas David reported for the first time a wood-fragment embolization from the venous circulation to the right ventricle in a 10-year-old male patient [1,2]. There have been multiple reports from foreign bodies that migrate to the pulmonary artery or the right ventricle like hypodermic needles, intravenous catheters, bone fragments, and bullets [3]. There have been reported less than 200 cases including embolization of other materials; most of the gunshot bullet embolization cases reported on literature were reported after war. A revision during Vietnam war reported a 0.3% incidence [1,2,4]. Foreign bodies can enter venous system through a direct protrusion into the lumen or by a slower erosion of the vascular wall and can be presented up to 14 years later [1,10].

Clinical manifestations are associated with the anatomical site of embolism, arterial embolization is presented as ischemic distal disease while venous embolization is symptomatic in 70% of

cases, generally associated with occupation on left ventricle and pulmonary artery [2,4,6]. Imaging studies are primordial for diagnosis confirmation. X-rays from the site the projectile first impacted and the finding of it in another body cavity raises the suspicious for diagnosis [4]. Some authors recommend CT, transthoracic or transesophageal ecocardiogram and cardiac catheterism even though there is no consensus for an algorithm for diagnostic approach [7–9].

The mortality rate for a retained bullet is 6% associated with complication in 25% of cases. Mortality rate decreases to 1–2% if the bullet is removed [5]. Other authors suggest it should be removed only in patients that are symptomatic, with a size less than 5 mm, irregular structure, proximal to an artery, located at left cardiac cavities and those creating electrocardiographic, hemodynamic or systemic alterations [11,12]. A 40-case series reported after second world war with follow up to 20 years, showed 25% incidence of pericarditis with conservative management and observation. One case developed left-ventricle hypertrophy secondary to aortic valve lesion [13]. There are follow up cases with conservative management in which there was pulmonary artery embolization with no complications reported [14]. Another alternative for management is endovascular treatment, which is an option in those hemodynamically stable patients with gunshot embolization to the pulmonary artery, intraarterial or any of the cardiac chambers [2,15].

### 4. Conclusion

Even though an algorithm of treatment does not exist for this pathology, each patient should be individualized. Invasive treatment should be avoided unless necessary; each clinical scenario

should be analyzed by an expert team to propose the best therapeutic approach for the patient. The present paper follows the guidelines of the SCARE criteria [16] for publication.

#### Conflicts of interest

Nothing to declare.

#### Funding

Nothing to declare.

#### Ethical approval

Ethical approval was given to publish this case report.

#### Consent

Consent was obtained to publish this case report.

#### Author contribution

Alan Ramos Mayo, MD- study concept, writing paper, data collection.

Jose Antonio Diaz Elizondo, MD- study concept, writing paper, approval of final manuscript.

Francisco Xavier Treviño Garza, MD- study concept, approval of final manuscript.

Hector Segura Marin, MD- data collection, writing paper.

Dolores Lopez Garnica, MD- data collection, writing paper.

#### Registration of research studies

researchregistry2355.

#### Guarantor

The corresponding author and co-authors accept full responsibility for the work.

#### References

- [1] K.L. Mattox, A.C. Beall Jr., C.L. Ennix, M.E. DeBakey, Intravascular migratory bullets, *Am. J. Surg.* 137 (2) (1979) 192–195.
- [2] G.G. Fernandez-Ranvier, P. Mehta, U. Zaid, K. Singh, M. Barry, A. Mahmoud, Pulmonary artery bullet embolism—Case report and review, *Int. J. Surg. Case Rep.* 4 (5) (2013) 521–523.
- [3] E.P. Howanitz, K.D. Murray, T.A. Galbraith, P.D. Myerowitz, Peripheral venous bullet embolization to the heart: case report and review of the literature, *J. Vasc. Surg.* 8 (1) (1988) 55–58.
- [4] K.R. Miller, M.V. Bennis, J.D. Sciarretta, B.G. Harbrecht, C.B. Ross, G.A. Franklin, et al., The evolving management of venous bullet emboli: a case series and literature review, *Injury* 42 (5) (2011) 441–446.
- [5] R.T. Padula, S.C. Sandler, R.C. Camishion, Delayed bullet embolization to the heart following abdominal gunshot wound, *Ann. Surg.* 169 (4) (1969) 599–602.
- [6] X.H. Lu, Z.J. Lu, J. Hu, J.X. Song, S.L. Chen, Bullet migration from the knee to the heart after a gunshot injury: a case report, *Chin. Med. J. (Engl.)* 124 (10) (2011) 1590–1592.
- [7] R.T. Bonk, S.D. Harrison, M.H. Meissner, Intravascular bullet localization by sonography, *AJR Am. J. Roentgenol.* 167 (1) (1996) 152.
- [8] M.W. Hashimi, D.R. Jenkins, B.W. McGwier, C.V. Massey, M.A. Alpert, Comparative efficacy of transthoracic and transesophageal echocardiography in detection of an intracardiac bullet fragment, *Chest* 106 (1) (1994) 299–300.
- [9] G. LiMandri, L.A. Gorenstein, J.P. Starr, S. Homma, J. Auteri, A.S. Gopal, Use of transesophageal echocardiography in the detection and consequences of an intracardiac bullet, *Am. J. Emerg. Med.* 12 (1) (1994) 105–106.
- [10] F.L. Shannon, B.L. McCroskey, E.E. Moore, F.A. Moore, Venous bullet embolism: rationale for mandatory extraction, *J. Trauma* 27 (10) (1987) 1118–1122.
- [11] S.K. Gandhi, B.C. Marts, B.M. Mistry, J.W. Brown, R.M. Durham, J.E. Mazuski, Selective management of embolized intracardiac missiles, *Ann. Thorac. Surg.* 62 (1) (1996) 290–292.
- [12] J.B. Lundy, E.K. Johnson, J.M. Seery, T. Pham, J.D. Frizzi, A.B. Chasen, Conservative management of retained cardiac missiles: case report and literature review, *J. Surg. Educ.* 66 (4) (2009) 228–235.
- [13] E.F. Bland, G.W. Beebe, Missiles in the heart: a twenty-year follow-up report of World War II cases, *N. Engl. J. Med.* 274 (19) (1966) 1039–1046.
- [14] J.B. Kortbeek, J.A. Clark, R.C. Carraway, Conservative management of a pulmonary artery bullet embolism: case report and review of the literature, *J. Trauma* 33 (6) (1992) 906–908.
- [15] M. Ghanaat, C. Goldenberg, J. Walsh, S.J. Sclafani, Endovascular management of an intracardiac bullet, *Injury* 46 (1) (2015) 166–168.
- [16] R.A. Agha, A.J. Fowler, A. Saeta, I. Barai, S. Rajmohan, D.P. Orgill, et al., The SCARE Statement: consensus-based surgical case report guidelines, *Int. J. Surg.* 34 (2016) 180–186.

#### Open Access

This article is published Open Access at [sciedirect.com](http://sciedirect.com). It is distributed under the [IJSCR Supplemental terms and conditions](#), which permits unrestricted non commercial use, distribution, and reproduction in any medium, provided the original authors and source are credited.