



Contents lists available at ScienceDirect

## International Journal of Surgery Case Reports

journal homepage: [www.casereports.com](http://www.casereports.com)

# An unusual cause of chronic abdominal pain after laparoscopic Roux en Y gastric bypass: Case report of a penetrating fish bone causing adhesions at the biliary-digestive junction resulting in partial obstruction and chronic symptoms



Vincent Ochieng\*, Leo Hendrickx, Jody Valk

Academic Department of General and Bariatric Surgery, ZNA-Stuivenberg Hospital, Lange Beeldekensstraat 267, 2060 Antwerpen, Belgium

## ARTICLE INFO

## Article history:

Received 29 November 2015  
Received in revised form 6 April 2016  
Accepted 7 April 2016  
Available online 14 April 2016

## Keywords:

Laparoscopic Roux-en-Y gastric bypass  
Fish bone perforation  
Chronic abdominal pain  
Case report

## ABSTRACT

**BACKGROUND:** The management of chronic abdominal pain after laparoscopic Roux-en-Y gastric bypass (LRYGP) is complex and challenging. Foreign body intestinal perforation including that caused by fish bones has previously been reported in the literature and if clinically unrecognized, can cause significant morbidity and mortality. Fish bone perforation as a cause of chronic abdominal pain after LRYGP has rarely been reported.

**SUMMARY:** The unusual case of a 54 year old female presenting with recurrent episodes of postprandial pain 2 years after LRYGP is reported. Previous radiological and endoscopic investigations did not reveal any abnormality and after the most recent clinical presentation, a laparoscopic exploration was performed. A protruding fish bone at the biliary-digestive junction was discovered intra-operatively and successfully extracted. Dense adhesions between the involved intestinal loops were lysed in an attempt to improve intestinal transit and subsequently relieve post-prandial pain.

**CONCLUSION:** This case highlights the possibility of a missed fish bone perforation causing chronic postprandial abdominal pain and discomfort in a patient with a Roux-en-Y gastric bypass anatomy. Foreign body perforation is a rare cause of abdominal pain after gastric bypass that should be considered when evaluating chronic abdominal pain symptoms after LRYGP.

© 2016 The Authors. Published by Elsevier Ltd. on behalf of IJS Publishing Group Ltd. This is an open access article under the CC BY-NC-ND license (<http://creativecommons.org/licenses/by-nc-nd/4.0/>).

## 1. Introduction

The management of abdominal pain syndromes after LRYGP is complex and challenging because of a myriad of possible causes [1]. It is estimated that 15–30% of patients present to the emergency department or require admission within 3 years of gastric bypass majorly due to abdominal pain in more than half of the cases [1].

We present the case of a patient with history of LRYGP for morbid obesity and chronic abdominal pain resulting from a missed fish bone perforation. Current clinical guidelines and treatment algorithms for the management of known ingested foreign bodies are based on previous works published by the American Society for Gastrointestinal Endoscopy (ASGE) [2] and the European Society for Gastrointestinal Endoscopy (ESGE) [3]. There are to our knowledge no specific guidelines for the management of foreign body

intestinal perforations in gastric bypass patients. This manuscript is written in accordance with the CAse REport (CARE) guidelines [4]. Our aim is to inform clinicians, based on our experience, on the importance of exercising a high index of suspicion and a low threshold for laparoscopic evaluation when clinically indicated in similar cases.

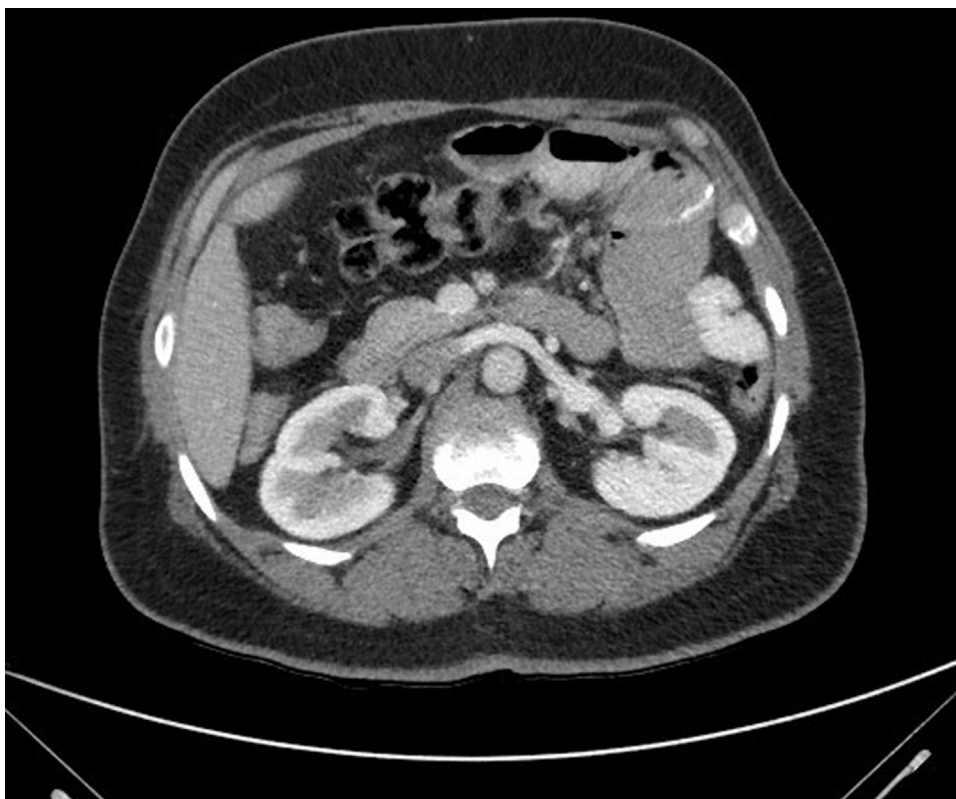## 2. Presentation of case

A 54 year old female of African descent presented at our emergency department with persistent abdominal pain in the left upper quadrant occurring frequently after meals. She had previously been evaluated at our bariatric outpatient clinic where she was on long term follow-up after undergoing a LRYGP 5 years previously. She reported a satisfactory weight loss (112–78 kg) with no significant pain problems in the first year after the operation. The postprandial pain began gradually about 2 years after the initial operation with apparently no known trigger. Several imaging studies, including Computerised Tomography (CT) scans, an abdominal ultrasound and a Barium swallow in the intervening period were non-conclusive. Gastroscopy was perfectly normal with no visual

Abbreviations: LRYGP, laparoscopic Roux-en-Y gastric bypass; PPI's, proton pump inhibitor's; CT, computed tomography; ERCP, endoscopic retrograde cholangiopancreatography.

\* Corresponding author.

E-mail address: [votienoatinga@yahoo.com](mailto:votienoatinga@yahoo.com) (V. Ochieng).



**Fig. 1.** Contrast CT-scan at the presumed level of the fish bone showing dilated intestinal loops..

evidence of active peptic ulcer disease (PUD). A trial therapy of high dose proton pump inhibitor's (PPI's) did not provide relief.

Her past medical history included a laparoscopic cholecystectomy, arterial hypertension, non-insulin dependent diabetes and a history of PUD satisfactorily managed with proton pump inhibitors. She neither smoked nor drank alcohol.

During her current admission, she presented at our emergency department with sharp pain in the left upper quadrant with radiation to her left shoulder. There were no accompanying symptoms such as nausea or vomiting. She reported normal bowel movements. Clinical examination showed a healthy young adult patient in painful distress. Her blood pressure was 130/90 mmHg, her pulse 110/min regularly regular and her oxygen saturation was 98%. Auscultation of the heart and lungs was essentially normal. Her abdomen was soft with no palpable masses. The left upper quadrant was tender to deep palpation, but without guarding and rebound tenderness. There was no percussion pain and abdominal auscultation revealed normal bowel sounds. Our differential diagnosis included PUD, bowel perforation, internal hernia and gastroenteritis. Blood chemistry showed a CRP of 35 mg/dl,  $7.22 \times 10^9$  leucocytes and a lactate value of 2,8 mmol/l. An abdominal X-ray showed only dilated intestinal loops in the left upper quadrant and no significant increase in calibre. A contrast CT-scan of the abdomen was non-conclusive (Fig. 1).

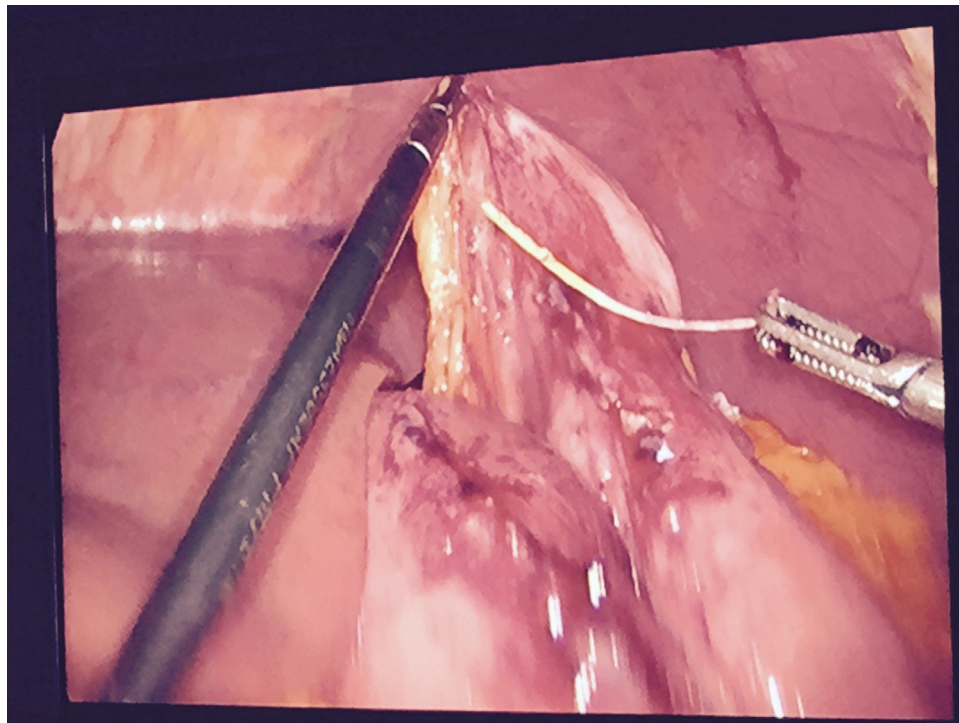
An explorative laparoscopy was decided upon and was planned for the next elective list. We set ourselves up to perform an intra-operative endoscopic retrograde cholangiopancreatography (ERCP) because of a positive Morphine-Prostigmine provocation test a few months previously. The operation was performed under general anaesthesia in a beach chair position. A thirty degree camera was introduced via the previous optic port to enable easy access and view of the abdomen. Inspection of the abdomen showed an impressive pattern of adhesions, the alimentary and biliary intestinal loops were almost matted together and very difficult to

separate. Both these loops were then adhered to the abdominal wall which made initial abdominal entry quite precarious. A coagulation hook was used successfully to release the adhesions without the need for energy devices. At some point during the lysis of adhesions, we came upon a foreign body protruding out of the biliary intestinal loop. On closer inspection it turned out to be a fish bone which had apparently punctured through the alimentary and biliary limbs and had caused dense adhesions to form between these 2 limbs (Fig. 2). The fish bone was successfully extracted without any iatrogenic damage to bowel structures. The exit and entry points on the bowel wall were closed intra-corporeally with Vicryl 2/0. The patient was discharged the next day on a liquid diet. At the first postoperative follow-up consultation, she reported no abdominal pain whatsoever. In the months following the operation she has done well and can currently tolerate both liquid and solid meals without any discomfort (Fig. 3).

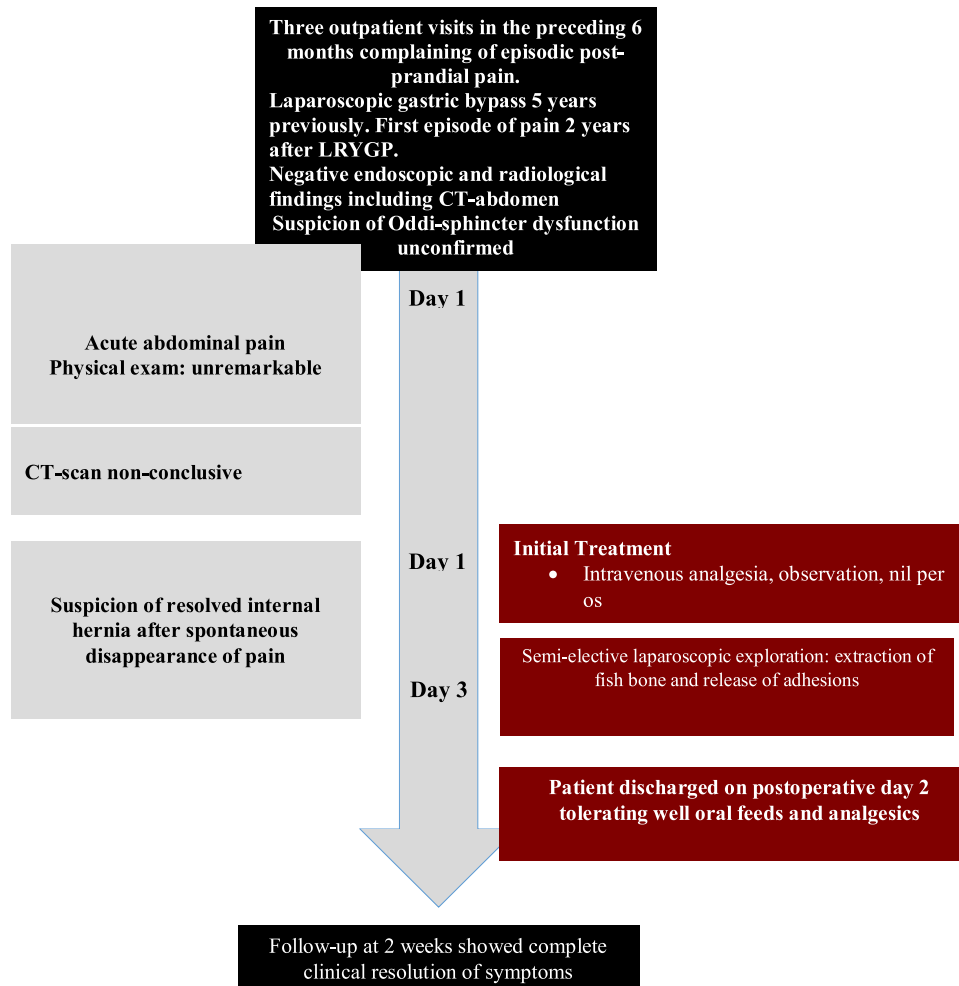
### 3. Discussion

We report the case of a 54 year old female patient who presented to us with chronic abdominal pain in the left upper quadrant 2 years after a LRYGP. In the intervening 3 year period prior to her current admission she was evaluated several times at our outpatient clinic without much progress in elucidating her problem. Despite several radiological and endoscopic investigation we were largely unable to explain her symptoms. The only pointer towards a functional gastrointestinal abnormality was a positive Morphine-Prostigmine provocation test a few months prior to her current presentation. This test of Sfincter of Oddi dysfunction is reportedly low in specificity and as such unreliable in offering guidance in difficult clinical cases [5].

Fish bones causing intestinal perforation have been reported in the literature and if unrecognized in the acute setting, can cause significant morbidity and mortality. Most fish bones however nav-



**Fig 2.** Intraoperative photo showing extraction of the fish bone.



**Fig 3.** Timeline depicting the patient's clinical course.

igate the digestive tract without causing any significant damage [6]. Most patients however cannot remember swallowing such bones potentially leading to a diagnostic quagmire in the absence of a high index of suspicion [6]. Perforation can occur in any segment of the gastrointestinal tract, however, the most common sites of perforation are in the distal ileum, the cecum and the left colon due to their great angulation [6–8]. The presence of two additional angulations at the biliary-digestive and enteric anastomoses can potentially increase the risk of perforation in a patient with a gastric bypass anatomy. Fish bones located in a narrow segment of the bowel can erode the mucosa, causing bacterial dissemination, perforation and extramural abscesses. Plain abdominal films are helpful in locating metallic foreign bodies and free air. The latter is surprisingly a rare occurrence as the puncture hole is usually small and is rapidly covered with fibrin and omentum. CT scanning is the most accurate exam with fish bones appearing like linear calcified densities within an area of inflammation [6]. CT-scans in this context are however difficult to interpret if there is no clinical suspicion and especially after the use of oral and/or intravenous contrast [8,9].

The management consist of conservative or interventional methods such as endoscopic removal, laparoscopic exploration or laparotomy. Surgery is the treatment of choice for acute bowel perforation. Laparoscopy is increasingly becoming the surgical approach of choice in selected cases because of its significantly lower morbidity and equivalent surgical outcomes [6].

#### 4. Conclusion

This case illustrates the importance of exercising a low threshold for laparoscopic evaluation in patients presenting with abdominal pain after LRYGP. In our case, we initially hesitated to perform a diagnostic laparoscopic evaluation because of the chronic nature of the symptomatology coupled with the negative radiological and endoscopic findings. We sought, like most clinicians would do given the circumstances, for evidence of acute pathology requiring rapid intervention such as internal herniation and marginal ulcers. However our experience in this case supports the idea that is always wise to consider other general causes of abdominal pain and/or obstruction in such cases and not only lay focus on pathological causes of abdominal pain specific to the bariatric population. Foreign body ingestion is well described in the general population and may increasingly be encountered in the bariatric population as the practice expands.

A secondary point is to ask ourselves if the standard dietary prescriptions recommended to patients after LRYGP need to consciously take into account the cultural needs and eating habits of our increasingly culturally diverse bariatric population. This is less of a problem when a bariatric intervention occurs within the context of a healthcare system of a homogeneous population where the dietary follow-up is tailored to match the local needs and eating patterns. In an increasingly globalized world, this is unlikely to always be the case and as such, dietary prescriptions after bariatric surgery need to take this into account. It is simply not enough to tell bariatric patients what they can consume but it is equally important to dissuade patients from eating habits that are likely to cause them problems.

#### Open Access

This article is published Open Access at [scimedirect.com](http://scimedirect.com). It is distributed under the [IJSCR Supplemental terms and conditions](#), which permits unrestricted non commercial use, distribution, and reproduction in any medium, provided the original authors and source are credited.

#### Disclosures

None.

#### Conflicts of interest

None.

#### Funding

None.

#### Ethical approval

Not applicable.

#### Consent

Written informed consent obtained from the patient.

#### Author contribution

Dr. Vincent Ochieng is the corresponding author who prepared the manuscript.

Dr. Jody Valk operated on the patient together with Dr. Ochieng and also assisted in preparation of the manuscript.

Dr. Hendrickx Leo read, edited and approved the manuscript.

#### Guarantor

Dr. Leo Hendrickx.  
Chief of Bariatric and General surgery.  
ZNA-Stuivenberg.  
Antwerpen.

#### References

- [1] A.J. Greenstein, R.W. O'Rourke, Abdominal pain following gastric bypass: suspects & solutions, *Am J Surg.* 201 (June (6)) (2011) 819–827.
- [2] S.O. Ikenberry, T.L. Jue, M.A. Anderson, V. Appalaneni, S. Banerjee, T. Ben-Menachem, et al., Management of ingested foreign bodies and food impactions, *Gastrointest. Endosc.* 73 (2011) 1085–1091.
- [3] M. Birk, P. Bauerfeind, P.H. Deprez, M. Hafner, D. Hartmann, C. Hassan, et al., Removal of foreign bodies in the upper gastrointestinal tract in adults: European society of gastrointestinal endoscopy (ESGE) clinical guideline, *Endoscopy* (2016).
- [4] J.J. Gagnier, G. Kienle, D.G. Altman, D. Moher, H. Sox, D. Riley, The CARE guidelines: consensus-based clinical case report guideline development, *J. Clin. Epidemiol.* 67 (2014) 46–51.
- [5] D.N. Lobo, A.S. Takhar, A. Thaper, M.G. Dube, B.J. Rowlands, The morphine-prostigmine provocation (Nardi) test for sphincter of Oddi dysfunction: results in healthy volunteers and in patients before and after transduodenal sphincteroplasty and transampullary septectomy, *Gut* 56 (10) (2007 Oct) 1472–1473.
- [6] W. Chuan-Xing, W. Bao-Qiang, D. Yun-Fei, S. Dong-Lin, J. Yong, Rare case of omentum-wrapped abscess caused by a fish bone penetrating the terminal ileum, *World J. Gastroenterol.* 20 (32) (2014) 11456–11459.
- [7] S. Joglekar, I. Rajput, S. Kamat, S. Downey, Sigmoid perforation caused by an ingested chicken bone presenting as right iliac fossa pain mimicking appendicitis: a case report, *J. Med. Case Rep.* 3 (2009) 7385.
- [8] B.K. Goh, P.K. Chow, H.M. Quah, H.S. Ong, K.W. Eu, L.L. Ooi, W.K. Wong, Perforation of the gastrointestinal tract secondary to ingestion of foreign bodies, *World J. Surg.* 30 (2006) 372–377.
- [9] B. Coulier, M.H. Tancredi, A. Ramboux, Spiral CT and multidetector-row CT diagnosis of perforation of the small intestine caused by ingested foreign bodies, *Eur. Radiol.* 14 (2004) 1918–1925 (18).