

# High-Dose Lanreotide in the Treatment of Poorly Differentiated Pancreatic Neuroendocrine Carcinoma: A Case Report

Frank Van Fraeyenhove<sup>a</sup> Nathalie Meireson<sup>b</sup> Luc Terriere<sup>c</sup>  
Paul Willemsen<sup>d</sup> Jan Kunnen<sup>e</sup> Caroline Mattelaer<sup>f</sup> Frank Van Acker<sup>g</sup>  
Dirk Schrijvers<sup>a</sup>

Departments of <sup>a</sup>Medical Oncology, <sup>b</sup>Radiation Oncology, <sup>c</sup>Gastroenterology, <sup>d</sup>General and Abdominal Surgery, <sup>e</sup>Radiology, <sup>f</sup>Pathology and <sup>g</sup>Nuclear Medicine, Ziekenhuisnetwerk Antwerpen, Antwerp, Belgium

## Key Words

Neuroendocrine tumor · Pancreas · High-dose lanreotide · Carcinoid

## Abstract

Pancreatic neuroendocrine tumors (NETs), including poorly differentiated carcinomas (NECs), are rarely encountered. The majority of these tumors do not secrete excess hormones, but functioning NETs produce large amounts of vasoactive peptides and may cause carcinoid syndrome. Synthetic somatostatin analogs (SSAs) have been widely used in NETs for control of hormonal syndromes. Here, we present a case of poorly differentiated, grade 3 pancreatic NEC associated with carcinoid syndrome, for which adequate symptom control was achieved for 2 years and 4 months using the long-acting SSA lanreotide Autogel<sup>®</sup>. In February 2009, a 55-year-old woman presented with episodes of flushing, diarrhea and epigastric pain. Imaging techniques revealed the presence of a metabolically active mass expressing somatostatin receptors in the hilar area of the liver. Histopathological examination confirmed the malignant nature of the mass, which was identified as a poorly differentiated grade 3 pancreatic NEC (TNM staging: T4NxM0). Therapeutic options were limited for the patient because of the extent of the primary mass involving the celiac axis, severe gastrointestinal toxicity experienced as a side effect of chemotherapy with cisplatin-etoposide and, later in the course of the disease, extensive liver metastases and carcinoid heart syndrome. Along with a palliative debulking surgery and right portal vein embolization, biotherapy with a high dose of lanreotide Autogel (120 mg/14 days) contributed to alleviation of symptoms caused

Dr. Frank Van Fraeyenhove  
Department of Medical Oncology, Ziekenhuisnetwerk Antwerpen  
Lindendreef 1  
BE-2020 Antwerp (Belgium)  
E-Mail [frank.vanfraeyenhove@zna.be](mailto:frank.vanfraeyenhove@zna.be)

by hormone overproduction, even after the development of liver metastases. These results suggest that patients with poorly differentiated NECs who exhibit signs of carcinoid syndrome can benefit from treatment with somatostatin analogs. © 2014 S. Karger AG, Basel

## Introduction

Neuroendocrine tumors (NETs), including poorly differentiated carcinomas (NECs), arise from cells of the neuroendocrine system and can occur in various anatomical sites in the body, with the majority of tumors having a gastroenteropancreatic origin. NETs are relatively infrequent, with 1–3 cases reported per 100,000 [1]. The incidence of NETs has been increasing in the last 20 years, probably due to heightened physician awareness and improved diagnostic techniques [2].

The majority of NETs are nonfunctioning tumors which do not secrete excess hormones. In contrast, functioning NETs produce large amounts of vasoactive peptides such as serotonin and tachykinins. These hormones may cause carcinoid syndrome characterized by symptoms including flushing (30–80% of patients), diarrhea (50–70%), abdominal pain (40–70%) or valvular heart disease (30–40%) [1, 3].

Somatostatin is an inhibitory peptide of gastrointestinal hormones [4]. Long-acting synthetic somatostatin analogues (SSAs) such as lanreotide (Somatuline Autogel®; Ipsen N.V.) are used to control symptoms in patients with functional NETs [5]. Nonrandomized open-label (reviewed in [4]) and randomized double-blind studies [6] have demonstrated that SSAs also have antiproliferative effects and prolong progression-free survival. Somatostatin receptors are present in 70–95% of NETs, but this percentage is lower in poorly differentiated NECs [1, 4].

Here, we report the use of a high dose of lanreotide Autogel in a patient with poorly differentiated pancreatic NEC and liver metastases. With this treatment, a fair quality of life was achieved for 2 years and 4 months.

## Case Report

In February 2009, a 55-year-old woman presented with complaints of loss of appetite and a painful sensation in the gastric region after meals. In the past 30 days, she had also experienced episodes of diarrhea (mean <1/day) and flushing (1–2/day). Because of her age and irregular menstrual cycles, these episodes of flushing were interpreted as a menopausal sign. The patient suffered from arterial hypertension, controlled with bisoprolol 10 mg per day. Clinical examination did not reveal any significant findings, except for a dull pain in the epigastric region. An abdominal computed tomography (CT) scan revealed a mass of about 8 × 5 cm in the hilar region of the liver, involving the head of the pancreas and encasing regional blood vessels (fig. 1). Dilated bile ducts were also observed, but there was no evidence of metastases. Dosing of serum chromogranin A (CgA) and neuron-specific enolase was performed. Potential diagnoses included pancreatic adenocarcinoma, cholangiocarcinoma, functional NET or NEC, colon cancer, lymphoma, metastases from melanoma or pheochromocytoma, and chronic pancreatitis.

Positron-emission tomography-CT (PET-CT) scan using 18F-fluorodeoxyglucose (<sup>18</sup>F-FDG) confirmed a metabolically active mass in the hilar region of the liver extending to the head of the pancreas. Even though a colonoscopy could have excluded colon cancer from the list of differential diagnoses, it was not performed because the oncologist estimated that

another pathology was more likely. CT-guided biopsy was performed; histopathology results revealed a neuroendocrine carcinoma with mitotic count based on 10 high-power fields of >20, and a Ki-67 proliferative index of 22%. Immunohistochemistry showed presence of chromogranin A (+++) and synaptophysin (+). According to the World Health Organization (WHO) 2010 classification, the tumor was graded as a poorly differentiated NEC (G3), small cell type [7], and staged as T4NxM0 [8]. An elevated CgA level of 385 µg/l (reference range: 40–170 µg/l) was noted; neuron-specific enolase level was normal. Somatostatin receptor scintigraphy confirmed that the tumor expressed somatostatin receptors, indicating that treatment with SSAs could be beneficial, despite the poorly differentiated nature of the tumor.

Surgical resection of the tumor was not an option due to the involvement of the celiac axis. Chemotherapy with carboplatin (target area under the curve = 5 mg/ml/min, administered intravenously on day 1) and etoposide (100 mg/m<sup>2</sup>, administered intravenously on days 1, 2 and 3) was initiated and repeated every 3 weeks. In addition, treatment with lanreotide Autogel (120 mg/4 weeks), injected deep subcutaneously, was initiated to control symptoms elicited by the secretion of hormones. After 6 cycles of chemotherapy, a partial response was observed: the size of the mass decreased to 2.3 cm, and was then interpreted as locally advanced, involving the epigastric and aortic area; no further lesions or PET activity were noticeable (fig. 2). However, the patient experienced important side effects (nausea and vomiting) during the chemotherapy administration.

As the tumor size had decreased, surgery became feasible. After consultation with the tumor board and based on minilaparotomy results showing no peritoneal lesions, resection of the PET-positive lesion was performed with maximal debulking. An additional lesion in segment 3 of the liver was also removed. Pathological examination revealed an R1 resection in the distal margin of the resected mass, but no viable tissue in the liver lesion. Intensity-modulated radiotherapy was proposed because of the R1 resection and aggressive histological appearance of the tumor, but the patient refused it due to fear of gastrointestinal toxicity. Biotherapy using lanreotide Autogel (120 mg/4 weeks) was continued by the general practitioner (GP).

Although monitoring of the disease progression using PET-CT and CgA dosing every 3 months was proposed, the patient was lost to follow-up for 10 months. During this time, lanreotide Autogel therapy was administered monthly by the GP. In August 2010, the GP referred the patient to the hospital with loss of appetite, 3–4 episodes of diarrhea per day since 1.5 months and up to 10 episodes of flushes per day since 3.5 months. Clinical examination revealed dull pain in the right hypochondrial and epigastric area and hepatomegaly. Laboratory results revealed CgA levels of 3,568 µg/l; bilirubin was elevated and hepatobiliary enzyme levels (ALT, AST, LDH, GGT) were 3–4 times over the upper limit of normal. A PET-CT scan showed that despite no local recurrence, the right liver lobe was extensively affected by a complex pattern of metastases (fig. 3), making surgical resection impossible.

At that time, adequate symptom control could no longer be maintained by once per month administration of lanreotide Autogel; thus, biotherapy was continued at a double dose (120 mg/14 days). Fearing gastrointestinal toxicity, the patient refused to undergo chemotherapy with carboplatin and etoposide. An echocardiography was performed because the patient had signs of exercise-induced dyspnea and peripheral edema. The echocardiography revealed dilated right heart cavities, tricuspid valve insufficiency 4/4 (retracted valves, retrograde flow into dilated inferior vena cava and liver veins) and a normal left heart system. Based on these results, carcinoid heart disease was diagnosed, limiting further chemotherapeutic options (e.g. anthracyclines, fluid administration

associated with cisplatinum). Treatment with diuretics, angiotensin-converting enzyme inhibitors and low molecular weight heparin was initiated. Right portal vein embolization (RPVE) was performed to ensure fast reduction of the hormone levels causing carcinoid heart disease and the severe burden from flushing and diarrhea. No resection was performed after RPVE, as it had no curative purpose; in addition, the patient refused another abdominal surgery (table 1).

Valve replacement surgery was proposed, but was also refused. In September 2010, the patient asked for a pause in active therapy and only supportive treatments were continued. Adequate symptom control was achieved solely by administration of the double dose of lanreotide Autogel. Imaging showed a stable disease after 1.5 months. Three months after RVPE (December 2010), the liver metastases had progressed and bone metastases were also present. Molecular treatment with everolimus was administered at a dose of 10 mg per day. Biotherapy with double-dose lanreotide Autogel was continued and treatment with zoledronic acid at a dose of 4 mg for 4 weeks was initiated. After 6 months, the disease was documented as stable on imaging, but 1 month later the patient showed signs of hepatic failure and clinical disease progression became evident. The patient was switched to best supportive care and died in June 2011.

## Discussion

NETs are rarely diagnosed, thus the number of comprehensive studies addressing diagnostic and therapeutic issues are still limited. Several groups such as ESMO (European Society for Medical Oncology), NCCN (National Comprehensive Cancer Network) and ENETS (European Neuroendocrine Tumor Society) have elaborated diagnosis and treatment guidelines for NETs, but most of these are consensus texts and do not reach level A evidence. In this context, case reports can provide valuable information for directing future research and raise compelling questions on current treatment strategies.

Patients with poorly differentiated pancreatic NECs usually present with jaundice, weight loss, abdominal pain and hepatomegaly. Functioning NETs are often discovered earlier than nonfunctioning tumors, but symptoms due to overproduction of hormones are rare in patients with poorly differentiated NECs. Patients with NECs have a poor prognosis, with an expected survival of less than 2 years, and 6–12 months for patients with liver metastases [9].

Here, we present the case of a patient with poorly differentiated pancreatic NEC exhibiting hormone overproduction that caused carcinoid syndrome. Even if NECs are typically nonfunctional, in this patient it was presumed that the tumor contained a mixture of poorly differentiated cells, explaining its aggressive character, and moderately differentiated cells responsible for the clinical signs.

Both functioning and nonfunctioning NETs can secrete bioactive peptides that can be used as biomarkers [10]. Serum CgA levels are considered to offer a more sensitive assessment compared to other biomarkers [2]. However, CgA is not a specific indicator of NETs, since CgA elevation can be associated with chronic atrophic gastritis, impaired renal function, hypertension, Parkinson's disease or pregnancy. Furthermore, steroid treatment, glucocorticoid excess and use of proton pump inhibitors may cause 2- to 3-fold increase in CgA levels [11]. Therefore, once a patient is suspected of having a NET based on clinical signs and elevated biomarker levels, the definitive diagnosis is made by corroborating the results of imaging techniques and histological confirmation [2].

CT or magnetic resonance imaging scans are sensitive and specific techniques used to determine the location of the primary tumor and to evaluate its extent, including identification of metastases, while  $^{18}\text{F}$ -FDG PET-CT scans detect hypermetabolic masses, and are especially useful for imaging poorly differentiated NECs [10, 12]. Somatostatin receptor scintigraphy is not generally recommended in poorly differentiated NECs [9], but in the case of functioning tumors, confirming the expression of somatostatin receptors warrants the use of SSA treatment to control symptoms caused by hormone overproduction.

Histological classification of NETs and adequate tumor grading and staging are essential for defining an optimal therapeutic strategy. The updated 2010 WHO classification distinguishes between well differentiated NETs and poorly differentiated NECs [7]. In the patient presented here, the tumor presented all histopathological characteristics of a G3 NEC: invasion of adjacent organs and blood vessels, a mitotic count of >20 per 10 high-power fields (40× magnification) and a Ki-67 proliferation index of >20% [7, 10, 13].

Wide surgical resection of the primary tumor is the first-line treatment in patients with NEC, especially if no metastases are evident at the time of diagnosis [2, 9]. Palliative debulking surgery is recommended to facilitate symptom control only when complete resection is not possible [9]. In our patient, although initially no metastases were present, the extent of the primary tumor and involvement of celiac axis made surgical resection unfeasible. For patients with inoperable high-grade tumors (Ki-67 >20%) first-line chemotherapy with cisplatin-etoposide is recommended [9]. This approach was partially effective in the current case, reducing tumor size to such an extent that debulking surgery became feasible.

Classical carcinoid syndrome usually occurs in the presence of serotonin-producing NETs [14]. Depending on the severity of symptoms caused by hormone overproduction, the patients' quality of life can be severely affected. In addition, exposure to high levels of vasoactive substances leads to the development of carcinoid heart disease in up to 50% of patients with liver metastases [2, 14]. Carcinoid heart disease can lead to right-sided heart failure and may preclude the use of some therapeutic alternatives such as anthracycline. This burden of carcinoid syndrome advocates the use of biotherapy to achieve symptom control, besides palliative debulking surgery and RVPE. The long-acting SSA lanreotide, Somatuline Autogel, is available as a prefilled syringe to be administered deep subcutaneously once a month. In a study involving administration of lanreotide Autogel for 6 months, 65% of the 71 patients with carcinoid syndrome had a  $\geq 50\%$  reduction in flushing episodes and 18% had a  $\geq 50\%$  reduction in diarrhea episodes [15]. In our patient, a dose of 120 mg/4 weeks of lanreotide Autogel was successful in controlling symptoms related to hormone overproduction, and even after the development of liver metastases, a high dose of 120 mg/14 days offered adequate symptom control.

## Conclusion

In the case presented here, biotherapy with lanreotide Autogel contributed to a fair quality of life for 2 years and 4 months, despite the aggressive nature of the tumor. These results suggest that patients with poorly differentiated NECs who exhibit symptoms caused by hormone overproduction can benefit from SSA biotherapy.

## Acknowledgements

We thank Vincent de Ruyter (Ipsen) for the relecture and information on Somatuline for this case report. We also thank Timea Kiss (XPE Pharma and Science) who provided medical writing services for this case report. Medical writing services were funded by Ipsen.

## Disclosure Statement

The authors have no conflicts of interest to disclose.

## References

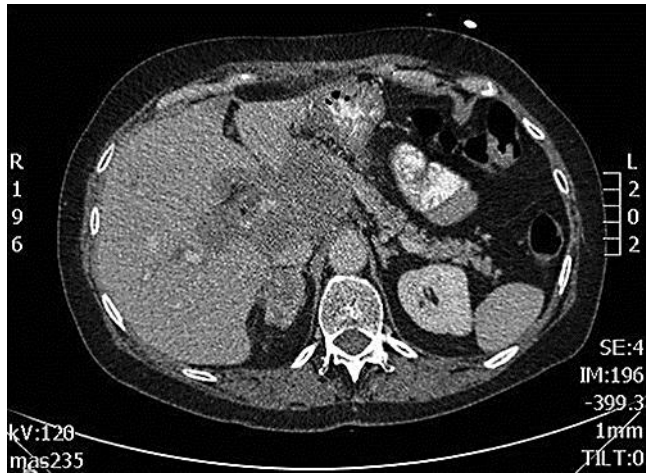- 1 Ramage JK, Davies AH, Ardill J, Bax N, Caplin M, Grossman A, Hawkins R, McNicol AM, Reed N, Sutton R, Thakker R, Aylwin S, Breen D, Britton K, Buchanan K, Corrie P, Gillams A, Lewington V, McCance D, Meeran K, Watkinson A; UKNETwork for Neuroendocrine Tumours: Guidelines for the management of gastroenteropancreatic neuroendocrine (including carcinoid) tumours. *Gut* 2005;54:iv1–iv16.
- 2 Öberg KE: The management of neuroendocrine tumours: current and future medical therapy options. *Clin Oncol* 2012;24:282–293.
- 3 Öberg K: Management of neuroendocrine tumours. *Ann Oncol* 2004;15:iv293–iv298.
- 4 Modlin IM, Pavel M, Kidd M, Gustafsson BI: Review article: somatostatin analogues in the treatment of gastroenteropancreatic neuroendocrine (carcinoid) tumours. *Aliment Pharmacol Ther* 2010;31:169–188.
- 5 Eriksson B, Klöppel G, Krenning E, Ahlman H, Plöckinger U, Wiedenmann B, Arnold R, Auernhammer C, Körner M, Rindi G, Wildi S; Frascati Consensus Conference participants: Consensus guidelines for the management of patients with digestive neuroendocrine tumors – well-differentiated jejunal-ileal tumor/carcinoma. *Neuroendocrinology* 2008;87:8–19.
- 6 Caplin M, Ruzsniwski P, Pavel M, Cwikla J, Phan A, Raderer M, Sedlackova E, Cadiot G, Wall L, Rindi G, Liyanage N, Blumberg J: A randomized, double-blind, placebo-controlled study of lanreotide antiproliferative response in patients with gastroenteropancreatic neuroendocrine tumors (CLARINET). *ECC 2013*. <http://eccamsterdam2013.ecco-org.eu/Scientific-Programme/Abstract-search.aspx?abstractid=8982>.
- 7 Bosman FT, Carniero F, Hruban RH, Theise ND (eds): WHO classification of tumours of the digestive system, 4th ed. Geneva, World Health Organization; 2010.
- 8 Sobin LH, Gospodarowicz MK, Wittekind C (eds): TNM classification of malignant tumours, 7th ed. Wiley-Blackwell, 2009.
- 9 Nilsson O, Van Cutsem E, Delle Fave G, Yao JC, Pavel ME, McNicol AM, Sevilla Garcia MI, Knapp WH, Keleştimur F, Sauvanet A, Pauwels S, Kwekkeboom DJ, Caplin M; Frascati Consensus Conference, ENTS: Poorly differentiated carcinomas of the foregut (gastric, duodenal and pancreatic). *Neuroendocrinology* 2006;84:212–215.
- 10 Falconi M, Bartsch DK, Eriksson B, Klöppel G, Lopes JM, O'Connor JM, Salazar R, Taal BG, Vullierme MP, O'Toole D; Barcelona Consensus Conference participants: ENETS Consensus guidelines for the management of patients with digestive neuroendocrine neoplasms of the digestive system: well-differentiated pancreatic non-functioning tumors. *Neuroendocrinology* 2012;95:120–134.
- 11 O'Toole D, Grossman A, Gross D, Delle Fave G, Barkmanova J, O'Connor J, Pape UF, Plöckinger U; Mallorca Consensus Conference participants: ENETS Consensus guidelines for the standards of care in neuroendocrine tumors: biochemical markers. *Neuroendocrinology* 2009;90:194–202.
- 12 Sundin A, Vullierme MP, Kaltsas G, Plöckinger U; Mallorca Consensus Conference participants: ENETS consensus guidelines for the standards of care in neuroendocrine tumors: radiological examinations. *Neuroendocrinology* 2009;90:167–183.
- 13 Rindi G, Klöppel G, Ahlman H, Caplin M, Couvelard A, de Herder WW, Eriksson B, Falchetti A, Falconi M, Komminoth P, Körner M, Lopes JM, McNicol AM, Nilsson O, Perren A, Scarpa A, Scoazec JY, Wiedenmann B; European Neuroendocrine Tumor Society (ENETS): TNM staging of foregut (neuro)endocrine tumors: a consensus proposal including a grading system. *Virchows Arch* 2006;449:395–401.
- 14 Dero I, De Pauw M, Borbath I, Delaunoy T, Demetter P, Demolin G, Hendlitz A, Pattyn P, Pauwels S, Roeyen G, Van Cutsem E, Van Hootehem P, Van Laethem JL, Verslype C, Peeters M: Carcinoid heart disease – a hidden complication of neuroendocrine tumours. *Acta Gastroenterol Belg* 2009;72:34–38.
- 15 Ruzsniwski P, Ish-Shalom S, Wymenga M, O'Toole D, Arnold R, Tomassetti P, Bax N, Caplin M, Eriksson B, Glaser B, Ducreux M, Lombard-Bohas C, de Herder WW, Delle Fave G, Reed N, Seitz JF, Van Cutsem E, Grossman A, Rougier P, Schmidt W, Wiedenmann B: Rapid and sustained relief from the symptoms of

carcinoid syndrome: results from an open 6-month study of the 28-day prolonged-release formulation of lanreotide. *Neuroendocrinology* 2004;80:244–251.

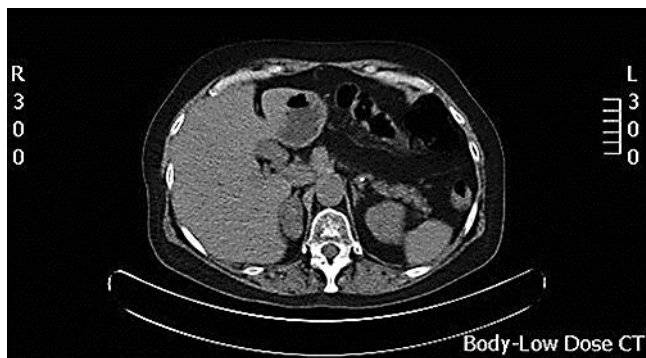**Table 1.** Timeline

February 2009	Patient presented with loss of appetite, epigastric pain and symptoms of carcinoid syndrome (flushing, diarrhea) CT scan: large tumor in the hilar region of the liver involving the pancreatic head and regional blood vessels PET-CT scan: metabolically active lesion SRS: somatostatin receptors present CT-guided biopsy: G3 pancreatic NEC, small cell type
February to August 2009	Chemotherapy: carboplatin (AUC 5, d1/3 weeks) and etoposide (100 mg/m <sup>2</sup> , d1, d2, d3/3 weeks) Biotherapy: lanreotide Autogel® 120 mg/4 weeks
August 2009	R1 resection of the tumor and partial hepatectomy
September 2009	Biotherapy: lanreotide Autogel 120 mg/4 weeks
October 2009 to August 2010	Patient lost to follow-up Treatment with lanreotide Autogel (120 mg/4 weeks) administered by the GP
August 2010	PET-CT scan: extensive metastases in the liver, no local recurrence Lanreotide Autogel 120 mg/14 days Right portal vein embolization
September 2010	Pause from chemotherapy (only supportive treatment) Lanreotide Autogel 120 mg/14 days
October 2010 to November 2010	Stable disease Lanreotide Autogel 120 mg/14 days
December 2010	Progression of liver metastases, bone metastases Molecular therapy: everolimus 10 mg/day Biotherapy: lanreotide Autogel 120 mg/14 days Zoledronic acid 4 mg/4 weeks
December 2010 to May 2011	Stable disease
June 2011	Clinical progression, patient switched to best supportive care Patient dies

G3 = Grade 3.



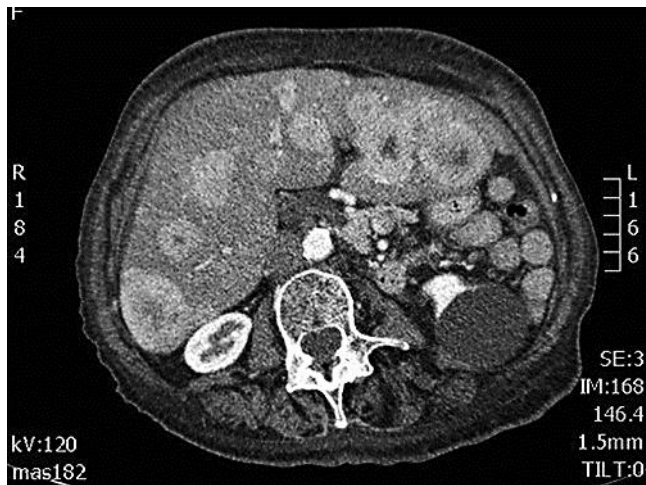
**Fig. 1.** CT scan image showing a mass of 8 × 5 cm in the hilar area of the liver, involving the pancreas head and encasing regional blood vessels.



**Fig. 2.** PET-CT scan image showing partial response after 6 cycles of cisplatin-etoposide chemotherapy. The smaller size of the tumor (2 × 3 cm) and its epigastric and preaortic localization makes surgical treatment feasible.



Van Fraeyenhove et al.: High-Dose Lanreotide in the Treatment of Poorly Differentiated Pancreatic Neuroendocrine Carcinoma: A Case Report



**Fig. 3.** PET-CT scan image showing a complex pattern of multiple liver metastases.