

One lung ventilation in a patient with an upper and lower airway abnormality

Address for correspondence:

Dr. Madan Mohan Maddali,
Department of Anesthesia,
Royal Hospital, PB.No; 1331,
PC: 111, Seeb, Muscat, Oman.
E-mail: madan@omantel.net.
com

Sangita R Kaza, Madan M Maddali, Maher J Albahrani, Adel A Vaghari

Department of Anesthesia, Royal Hospital, Muscat, Oman

ABSTRACT

One-lung ventilation for a thoracotomy procedure was achieved with the help of a endobronchial blocker in a young girl with limited mouth opening, minimal neck extension, and a distorted tracheo-bronchial anatomy. As the patient would not cooperate for an awake nasotracheal intubation despite adequate preparation, an inhalational anesthetic was used to make the patient unconscious, taking care that spontaneous breathing was maintained. Nasotracheal intubation was done with the help of a fiberoptic bronchoscope. A wire-guided Arndt endobronchial blocker was placed coaxially through the endotracheal tube using a fiberoptic bronchoscope. This case report highlights that in a scenario of both upper and lower airway distortion, a bronchial blocker positioned through a nasotracheal tube under fiberoptic guidance might be the best option when one-lung ventilation is required.

Key words: Bronchoscopy, fiberoptic, Intratracheal intubation, nasotracheal, thoracic surgical procedures

Access this article online

Website: www.ijaweb.org

DOI: 10.4103/0019-5049.104578

Quick response code



INTRODUCTION

One-lung ventilation (OLV) for thoracic surgical procedures is usually achieved with a double-lumen endobronchial tube (DLT) or a bronchial blocker.^[1] Earlier on, some reports have described the use of bronchial blockers for providing OLV in patients with restricted mouth opening.^[2,3] Ours is probably the first case report where OLV was provided with an Arndt blocker positioned through a nasotracheal tube under fiberoptic bronchoscopy guidance in a patient with both upper and lower airway abnormalities, ie, restricted mouth opening, minimal neck extension, and a distorted tracheobronchial anatomy.

CASE REPORT

A 17-year-old girl with severe kyphoscoliosis presented with breathlessness and productive cough of one week duration. She was referred to our institute as a case of non-resolving left pneumothorax. Significant history included open heart surgery for ventricular septal defect closure at 4 years of age and spinal instrumentation for

correction of kyphoscoliosis at the age of 15 years. On examination, she was emaciated, weighing 35 kg, and had severe thoracic kyphoscoliosis and generalized muscle wasting. Airway evaluation revealed limited mouth opening with inter-incisor distance of 1 cm, Mallampati Score was IV, and Atlanto-occipital joint extension was grade IV (<12). Respiratory system examination revealed a decreased air entry on the left chest. Chest radiography and computed tomography displayed a large pneumothorax with complete atelectasis of the left lung and airway distortion with deviated trachea and bilaterally narrowed bronchi [Figure 1]. Transthoracic echocardiography showed good biventricular function with no evidence of pulmonary hypertension.

Despite conservative management for two weeks, which involved insertion of intercostal drains, there was no improvement in the left lung status. The possible aetiology for the non-resolving left pneumothorax was multiple bullae in a hypoplastic lung. The hypoplasia of the left lung was probably due to the spinal deformity that the patient had. Due to

How to cite this article: Kaza SR, Maddali MM, Albahrani MJ, Vaghari AA. One lung ventilation in a patient with an upper and lower airway abnormality. *Indian J Anaesth* 2012;56:567-9.

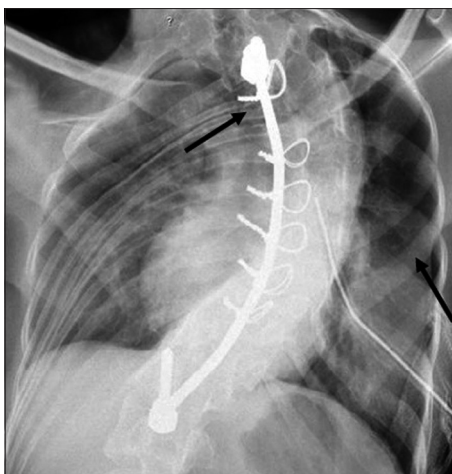


Figure 1: Chest radiography displaying a large pneumothorax with complete atelectasis of the left lung and airway distortion with deviated trachea and bilaterally narrowed bronchi

the non-resolving nature of the left pneumothorax, an informed consent was obtained and the patient was taken up for a pleurectomy.

In view of anticipated difficult airway access, an awake fiberoptic tracheal intubation was planned. After premedication with oral midazolam, under standard American Society of Anaesthesia (ASA) monitoring guidelines, the right radial artery was cannulated under topical anesthesia for invasive arterial pressure monitoring. Despite topicalization of the upper airways with local anesthetic, the patient remained uncooperative for any kind of airway instrumentation. After further sedation with intravenous fentanyl (50 µg) and midazolam (1 mg), general anesthesia was induced with titrated concentrations of sevoflurane taking care to maintain spontaneous breathing. A lubricated nasopharyngeal airway was inserted in the left nostril to administer oxygen and sevoflurane. A 7.0-size cuffed endotracheal tube was successfully introduced into the patient's trachea through the right nostril under the guidance of a 4.0-mm diameter fiberoptic scope (LF-1 Olympus).

Once airway control was achieved, a muscle relaxant (cis-atracurium) was administered. In view of distorted trachea & bronchi it was decided to use an endobronchial blocker for achieving OLV as was the request from the surgical side. Using the special multiport adaptor provided, a five-size Arndt wire-guided endobronchial blocker (Cook, Inc., Bloomington, IN) was introduced coaxially through the nasotracheal tube. Under fiberoptic guidance, the blocker was placed in the left main bronchus. A left thoracotomy was performed. Standard lung-deflation technique was used and OLV

was instituted. The surgical procedure proceeded uneventfully with good visualization of the operative field. Pressure control ventilation with positive end expiratory pressure (4 cm H₂O) and peak airway pressures up to 24 cm H₂O were used throughout the surgery. Inspired oxygen concentration (FiO₂) and the respiratory rate were adjusted based on serial arterial blood gas analysis, pulse oximetry (SpO₂) and end tidal carbon dioxide concentration (EtCO₂) values during both lung ventilation and OLV. The patient remained haemodynamically stable with adequate oxygenation and ventilation. After completion of surgery, the blocker balloon was deflated and the left lung was expanded. The blocker was then removed with the nasotracheal tube left *in situ*.

In view of the chest deformities and difficulties with airway access, the patient was gradually weaned off artificial ventilation after four hours of elective mechanical ventilation in the post-cardiothoracic surgery intensive care unit. Postoperative analgesia was provided with fentanyl infusion and the patient's trachea was extubated successfully with satisfactory arterial blood gases. Serial chest radiographs showed good left lung expansion and, after an uneventful postoperative course, the patient was discharged home on seventh postoperative day.

DISCUSSION

Bronchial blockers have been used to achieve OLV in patients with restricted mouth opening^[2,3] and in paediatric patients for scoliosis surgery.^[4] Bronchial blockers have an established role in patients with abnormal tracheobronchial tree and requiring thoracic surgery.^[5] However, the successful use of an Arndt bronchial blocker for the provision of OLV in a patient with difficult both upper and lower airway access has not been described, thus making this case report novel.

As described by several authors as the technique of choice,^[3,6] we also secured the patients airway with a single-lumen nasotracheal tube under fiberoptic bronchoscope guidance. We opted for fiberoptic bronchoscope-assisted nasotracheal intubation, as it conforms to the natural airway passages and is relatively easier than orotracheal intubation in patients with restricted mouth opening. Once the patient's trachea was intubated, lung separation was achieved with a bronchial blocker.

In clinical practice, OLV can be achieved using DLT

or bronchial blockers. We did not prefer a DLT in our patient due to the following reasons: 1) Nasal intubation is not easy with a DLT due to its large outer diameter and the distal curvature.^[3] 2) In patients with a difficult airway (Mallampati grade view 3 or 4), restricted mouth opening, limited neck extension, etc, it is difficult to place a DLT as it is bulkier and more rigid than a single-lumen endotracheal tube.^[7,8] 3) In our patient, there was, in addition, distortion of the tracheobronchial tree; hence, placement of a DLT would have posed additional difficulties. 4) Lastly, as we planned for postoperative mechanical ventilation, a bronchial blocker through an endotracheal tube was ideal. Usually, a DLT needs to be exchanged for a single-lumen tube at the end of the procedure, if the patient requires postoperative ventilatory support.

Apart from being the technique of choice,^[6] the selection of a wire-guided Arndt bronchial blocker was appropriate in this case, as there were additional advantages: The set has a special airway adaptor and ventilation is easily maintained during placement of the blocker. As the Arndt blocker requires a single-lumen endotracheal tube, it is more convenient to use in a difficult airway scenario as it maximizes the cross-sectional diameter of the airway.^[6]

CONCLUSION

Effective OLV was achieved using nasotracheal

intubation and a bronchial blocker placement. Nasotracheal intubation and a bronchial blocker, both of which are performed with the aid of a fiberoptic bronchoscope in patients with distorted upper and lower airway passages, appear to be the best option for achieving OLV. This technique would be useful in clinical situations where placement of double lumen endotracheal tubes is technically impractical or impossible.

REFERENCES

1. Brodsky JB. Lung separation and the difficult airway. *Br J Anaesth* 2009;103Suppl 1:i66-75.
2. Arndt GA, Buchika S, Kranner PW, DeLessio ST. Wire-guided endobronchial blockade in a patient with limited mouth opening. *Can J Anaesth* 1999;46:87-9.
3. Angie Ho CY, Chen CY, Yang MW, Liu HP. Use of the Arndt wire-guided endobronchial blocker via nasal for OLV in patient with anticipated restricted mouth opening for esophagectomy. *Eur J Cardiothorac Surg* 2005;28:174-5.
4. Bird GT, Hall M, Nel L, Davies E, Ross O. Effectiveness of Arndt endobronchial blockers in pediatric scoliosis surgery: A case series. *Paediatr Anaesth* 2007;17:289-94.
5. Campos JH. Update on selective lobar blockade during pulmonary resections. *Curr Opin Anaesthesiol* 2009;22:18-22.
6. Campos JH. Lung isolation techniques for patients with difficult airway. *Curr Opin Anaesthesiol* 2010;23:12-7.
7. Neustein SM. The use of bronchial blockers for providing one-lung ventilation. *J Cardiothorac Vasc Anesth* 2009; 23:860-8.
8. Cohen E. Pro: The new bronchial blockers are preferable to double-lumen tubes for lung isolation. *J Cardiothorac Vasc Anesth* 2008;22:920-4.

Source of Support: Nil, **Conflict of Interest:** None declared